



To,

The Coordinator,
Mediwheel (Arcofemi Healthcare Limited)
Helpline number: 011- 41195959

Dear Sir / Madam,

Sub: Annual Health Checkup for the employees of Bank of Baroda

This is to inform you that the following spouse of our employee wishes to avail the facility of Cashless Annual Health Checkup provided by you in terms of our agreement.

PARTICULARS OF HEALTH CHECK UP BENEFICIARY	
NAME	SUCHITA HANSRAJSHEWALE
DATE OF BIRTH	17-01-1985
PROPOSED DATE OF HEALTH CHECKUP FOR EMPLOYEE SPOUSE	11-08-2022
BOOKING REFERENCE NO.	22S122962100022980S
SPOUSE DETAILS	
EMPLOYEE NAME	MR. SHEWALE HANSRAJ NAMDEO
EMPLOYEE EC NO.	122962
EMPLOYEE DESIGNATION	ARMED GUARD
EMPLOYEE PLACE OF WORK	MUMBAI,BKC, BARODA CORPORATE C
EMPLOYEE BIRTHDATE	02-01-1975

This letter of approval / recommendation is valid if submitted along with copy of the Bank of Baroda employee id card. This approval is valid from **06-08-2022** till **31-03-2023**. The list of medical tests to be conducted is provided in the annexure to this letter. Please note that the said health checkup is a **cashless facility** as per our tie up arrangement. We request you to attend to the health checkup requirement of our employee's spouse and accord your top priority and best resources in this regard. The EC Number and the booking reference number as given in the above table shall be mentioned in the invoice, invariably.

We solicit your co-operation in this regard.

Yours faithfully,

Sd/-

Chief General Manager
HRM Department
Bank of Baroda

(Note: This is a computer generated letter. No Signature required. For any clarification, please contact Mediwheel (Arcofemi Healthcare Limited))



बैंक ऑफ़ बड़ौदा
Bank of Baroda



नाम

शेवाले हंसराज नामदेव

Name

Shewale Hansraj Namdeo

कर्मचारी कूट क्र.

E.C. No.

122962

जारीकर्ता प्राधिकारी

Issuing Authority

धारक के हस्ताक्षर

Signature of Holder



भारत सरकार

GOVERNMENT OF INDIA



सुचिता हंसराज शेवाळे
Suchita Hansraj Shevale

जन्म वर्ष / Year of Birth : 1985
महिला / Female



7420 0152 5951

आधार – आम आदमी का अधिकार



आधार

भारतीय विशिष्ट पहचान प्राधिकरण
UNIQUE IDENTIFICATION AUTHORITY OF INDIA

पता: निलगव्हाण, निलगव्हाण, नाशिक,
वजिरखेडा, महाराष्ट्र, 423105

Address: NILGAVHAN,
Nilgavhan, Nashik, Vajirkheda,
Maharashtra, 423105

1947
1800 180 1947

help@uidai.gov.in

www.uidai.gov.in

P.O. Box No.1947,
Bengaluru-560 001

DATE :- 25-8-22

HEIGHT -

WEIGHT :- 72.8



MAGNUM

MULTISPECIALITY HOSPITAL

S/B DR. MANOJ CHOPDA

PATIENT NAME :- Suchita Shewale

AGE /SEX :-

37 / F

BP - 114/80 mm/Hg

P - 88/min

SPO₂ - 97%

clo

- clinically better
- Came for health check up.

apt stable

good exercise toler

(veg)

↓ Hb 9.2

169/281

Hb A1c 7.4

208/111/139

Grd I fatty liver

Longer ⁵² ~~100~~ ^{9.2} ~~11~~ ^{9.2} ~~11~~

30x30x9m

clut

Glucosyl m(1/100) x 600

Asst — After dinner

Glucosyl m(1/100)

orlanonin

Cepid m(0.57 m)

2x15 ¹⁰⁰

or Bilateral

free mofis

stom amthor

} had low
①
?ditch



37/111 x 9.2

30d

ગીર - માલવ, ગુજ.

ગીર, પોરે, વાકા, ૨૦૧૪

અવધાનને વધાર્યા

(x)

વાણી, ગુજ

(ગીર) ?

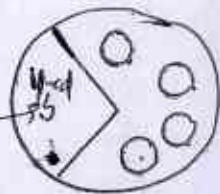
લાલ/લાલો, ડાહો

તેમ

(ગીર) x

ગુજરાત, રાજ્ય

(x) (x) (x)



(ગીર)

4 - 2.127 (mg/ml)

2 - 1.152 / ml

331

(ગીર)

5-7કી વાકા

1.50mm

8-12કી

100 gm

(ગીર)

16કી

100g

(ગીર)

(ગીર)

Lifestyle modification



200

(2mm)

Glucosuria (Acute)

દા.ત

8.1



Chopda Medicare & Research Centre Pvt. Ltd.

MAGNUM

HEART INSTITUTE

NAME: MRS. SUCHITA SHEWALE	ISO 9001 : 2008 CERTIFIED HOSPITAL	DATE: 24/08/2022
AGE/ SEX: 37 YEARS/ FEMALE		REFERRED BY: SELF.

ULTRASOUND OF ABDOMEN & PELVIS

Findings:

Liver is normal in size, shape & show raised parenchymal echogenicity, suggestive of fatty infiltrations. No parenchymal focal lesion. No sign of intrahepatic biliary dilatation. Portal vein & common bile duct is normal.

Gall bladder is well distended. The wall is normal. No mass/ calculus. No perichole-cystic collection.

Spleen is normal in size, shape & echotexture. No parenchymal focal lesion. Splenic hilum is normal.

Pancreas are normal in size & echotexture. No parenchymal calcification/ mass / cystic lesion. Pancreatic duct is normal.

Right kidney measures: 9.8 X 3.8 cm.

Left kidney measures: 10.4 x 5.5 cm.

Both kidneys are normal size, shape & echotexture. No cyst / lesion/ calculus.

Cortico-medullary differentiation is normal. No Perinephric collection.

Urinary bladder is well distended. The wall is normal. No intraluminal mass / calculus.

Uterus measures: 4.9 x 7.7 cm. it is normal in size, shape & echotexture.

Endometrium measures 5 mm. It is midline. No endometrial collection/ lesion.

Myometrium is normal. No focal lesion.

Right ovary measures: 2.9 x 2.6 cm. Left ovary measures 3.4 x 1.7 cm.

Both ovaries are normal. No cyst.

No abdominal lymphadenopathy. No ascites. Bowels are normal.

Abdominal aorta & IVC are normal.

IMPRESSION:

- *Grade I fatty liver.*
- *No other significant abnormality noted.*

Thank-you.



DR. KUNAL KALYANRAO PATIL
MBBS, MD (RADIOLOGY)

CONSULTANT RADIologist
HELPLINE
02532550100
9527750100



Chopda Medicare & Research Centre Pvt. Ltd.

MAGNUM

HEART INSTITUTE
ISO 9001 : 2008 CERTIFIED HOSPITAL

Patient's Name : Mrs. Sucheta.H. Shewale

Date : 24/08/2022

Ref. By : Dr. Manoj Chopda (MD,DM)

Age/Sex : 37 yrs / F

THYROID FUNCTION TEST REPORT

<u>TEST</u>	<u>OBSERVED VALUE</u>	<u>NORMAL RANGE</u>
T 3	1.320 ng/ml	0.69 – 2.15 ng/ml
T 4	10.46 ug/dl	5.2 – 12.7 ug/dl
TSH	1.793 uIU/ml	0.4 – 4.5 uIU/ml

METHOD : By Chemiluminescence System



[Signature]
Pathologist
Dr. Sudhar Sankalecha
MD (Path)
Reg. No - 70405

3/5, Patil Lane No. 1, Laxmi Nagar, Near K. B. H. Vidyalaya, Canada Corner, Nashik-422005.
Phone : 0253 2316200/01/02/03/04, Email : magnumheartinstitute@gmail.com
www.magnumheartinstitute.com





Chopda Medicare & Research Centre Pvt. Ltd.

MAGNUM

HEART INSTITUTE
ISO 9001 : 2008 CERTIFIED HOSPITAL

Patient's Name : Mrs. Sucheta.H. Shewale

Date : 24/08/2022

Ref. By : Dr. Manoj Chopda (MD,DM)

Age/Sex : 37 yrs / F

URINE EXAMINATION REPORT

PHYSICAL CHARACTERISTICS

Volume : 20 ml
Colour : Yellow
Appearance : Clear
Reaction : Acidic

CHEMICAL EXAMINATION

Albumin : Nil
Sugar : Nil
Ketones : Nil
Bile Salts : Absent
Bile Pigments : Absent

MICROSCOPIC EXAMINATION

Epithelial Cells : 1 - 3/hpf
Pus Cells : 0 - 2/hpf
Crystals : Absent
Other : Absent
R.B.C.s : Absent
Casts : Absent
Bacilli : Absent



3/5, Patil Lane No. 1, Laxmi Nagar, Near K. B. H. Vidyalaya, Canada Bunder, Nashik-422005.
Phone : 0253 2316200/01/02/03/04, Email : magnumheartinstitute@gmail.com
www.magnumheartinstitute.com





Chopda Medicare & Research Centre Pvt. Ltd.

MAGNUM

HEART INSTITUTE
ISO 9001 : 2008 CERTIFIED HOSPITAL

Patient's Name : Mrs. Sucheta.H. Shewale

Date : 24/08/2022

Ref. By : Dr. Manoj Chopda (MD,DM)

Age/Sex : 37 yrs / F

BIOCHEMISTRY REPORT

<u>TEST</u>	<u>OBSERVED VALUE</u>	<u>NORMAL RANGE</u>
<u>KIDNEY</u>		
S.Creatinine :	1.0 mg/dl	0.6 - 1.4 mg/dl
Blood Urea Nitrogen :	9.43 mg/dl	5 - 45 mg/dl
S.Uric acid :	5.2 mg/dl	2.5 - 7.2 mg/dl
<u>LFT</u>		
S.G.O.T. :	21.8 IU/L	8 - 40 IU/L
S.G.P.T. :	19.3 IU/L	5 - 50 IU/L
S.Alk PO4 :	118.8 IU/L	40 - 130 IU/L
<u>S.Bilirubin</u>		
Total :	0.3 mg/dl	0.2 - 1.1 mg/dl
Direct :	0.1 mg/dl	0.0 - 0.4 mg/dl
Indirect :	0.2 mg/dl	0.2 - 0.6 mg/dl
<u>S.Proteins</u>		
Total :	7.0 g/dl	6 - 7.8 g/dl
Albumin :	4.2 g/dl	3.2 - 4.6 g/dl
Globulin :	2.8 g/dl	2.3 - 3.5 g/dl
A/G Ratio :	1.5	
Gamma -GT :	27.1 IU/L	0 - 45 IU/L



[Signature]
Pathologist
Dr. Sudhir Sankalecha

3/5, Patil Lane No. 1, Laxmi Nagar, Near K. B. H. Vidyalaya, Canada Corner, Nashik-422005.
Phone : 0253 2316200/01/02/03/04, Email : magnumheartinstitute@gmail.com
www.magnumheartinstitute.com

MAGNUM HEART INSTITUTE

HELPLINE
9527650100
9527750100



Chopda Medicare & Research Centre Pvt. Ltd.

MAGNUM

HEART INSTITUTE

ISO 9001 : 2008 CERTIFIED HOSPITAL

Patient's Name : Mrs. Sucheta.H. Shewale

Date : 24/08/2022

Ref. By : Dr. Manoj Chopda (MD,DM)

Age/Sex : 37 yrs / F

LIPID PROFILE REPORT

<u>TEST</u>	<u>OBSERVED VALUE</u>	<u>NORMAL VALUE</u>
S. Cholesterol	208.2 mg/dl	Up to 200 mg/dl
S. Triglyceride	141.7 mg/dl	Up to 160 mg/dl
HDL Cholesterol	40.1 mg/dl	30 – 65 mg/dl
LDL Cholesterol	139.8 mg/dl	75 – 165 mg/dl
VLDL Cholesterol	28.34 mg/dl	6.0 – 38.0 mg/dl
LDL/HDL Ratio	3.48	2.5 – 4
Chol/HDL Chol Ratio	5.19	3 – 5.5



Pathologist
Dr. Sudhir Sankalecha
MD (Path)

3/5, Patil Lane No. 1, Laxmi Nagar, Near K. B. H. Vidyalaya, Canada Corner, Nashik-422005.
Phone : 0253 2316200/01/02/03/04, Email : magnumheartinstitute@gmail.com
www.magnumheartinstitute.com





Chopda Medicare & Research Centre Pvt. Ltd.

MAGNUM

HEART INSTITUTE

ISO 9001 : 2008 CERTIFIED HOSPITAL

Patient's Name : Mrs. Sucheta.H. Shewale

Date : 24/08/2022

Ref. By : Dr. Manoj Chopda (MD,DM)

Age/Sex : 37 yrs / F

HAEMATOLOGY

<u>Test</u>	<u>Result</u>	<u>Reference Range</u>
HBA1C :	7.4 %	4.0 - 6.0 %
METHOD :	HPLC METHOD	

Reference Range As per ADA

Normal : Below 5.7%

Pre-Diabetes : 5.7% - 6.4%

Diabetes : \geq 6.5%

Guidance For Known Diabetes

Good Control : Below 6.5%

Fair Control : 6.5% - 7.0%

Unsatisfactory Control : 7.0% - 8.0%

Poor Control : $>$ 8.0%

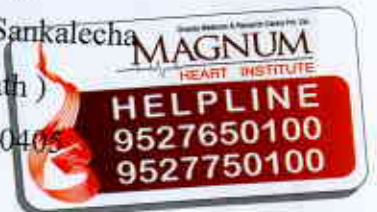

for path
Pathologist

Dr. Sudhir Sankalecha

MD (Path)

3/5, Patil Lane No. 1, Laxmi Nagar, Near K. B. H. Vidyalaya, Canada Corner, Nashik-422005
Phone : 0253 2316200/01/02/03/04, Email : magnumheartinstitute@gmail.com
www.magnumheartinstitute.com





Chopda Medicare & Research Centre Pvt. Ltd.

MAGNUM

HEART INSTITUTE

ISO 9001 : 2008 CERTIFIED HOSPITAL

Patient's Name : Mrs. Sucheta.H. Shewale

Date : 24/08/2022

Ref. By : Dr. Manoj Chopda (MD,DM)

Age/Sex : 37 yrs / F

BIOCHEMISTRY REPORT

TEST

OBSERVED VALUE

NORMAL VALUE

Blood Sugar (Fasting) :

169.7 mg/dl

60 – 110 mg/dl

Urine Sugar :

Absent

Urine Ketones :

Absent

Blood Sugar (PP) :

281.0 mg/dl

60 – 140 mg/dl

Urine Sugar :

SNR

Urine Ketones :

SNR



Pathologist
Dr. Sudha Sankalecha
MD (Path)
Reg.No - 70405





Chopda Medicare & Research Centre Pvt. Ltd.

MAGNUM

HEART INSTITUTE

ISO 9001 : 2008 CERTIFIED HOSPITAL

Patient's Name : Mrs. Sucheta.H. Shewale

Date : 24/08/2022

Ref. By : Dr. Manoj Chopda (MD,DM)

Age/Sex : 37 yrs / F

BLOOD EXAMINATION REPORT

Test

Result

Blood Group

: ' B '

Rh Factor

: Positive



Pathologist
Dr. Sudhir Sankalecha
MD (Path)
Reg. No. 70405





Chopda Medicare & Research Centre Pvt. Ltd.

MAGNUM

HEART INSTITUTE

ISO 9001 : 2008 CERTIFIED HOSPITAL

Patient's Name : Mrs. Sucheta.H. Shewale

Date : 24/08/2022

Ref. By : Dr. Manoj Chopda (MD,DM)

Age/Sex : 37 yrs / F

BLOOD EXAMINATION REPORT

(By Fully Automated cell counter)

Haemoglobin : 9.2 gm % (11.0 – 17.0 gm %)

White Blood Cells

Total Count : 5900 / cmm (4500 – 10500 / cmm)

Differential Count

Neutrophils : 70 % (45 – 75 %)
Lymphocytes : 20 % (20 – 48 %)
Eosinophils : 04 % (01 – 04 %)
Monocytes : 06 % (04 – 10 %)
Basophils : 00 % (00 – 01 %)

Platelets : 3.77 Lacs/cmm (1.5 – 4.5 Lacs/cmm)

R.B.C. : 4.10 mil/cmm (4.00 – 6.00 mil/cmm)

Haematocrit (P.C.V.) : 29.4 % (35 - 50 %)

M.C.V. : 72 fL (80 – 99 fL)

M.C.H. : 22.5 pg (27 – 32 pg)

M.C.H.C. : 31.5 g/dl (31.5 – 36 g/dl)

R.D.W. : 16.1 % (10.0 – 15.0 %)

E.S.R : 29 mm/hrs 0 - 15 mm/hrs

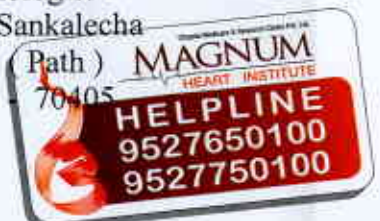

Pathologist
Dr. Sudhir Sankalecha

MD

Reg.No

70405





Chopda Medicare & Research Centre Pvt. Ltd.

MAGNUM

HEART INSTITUTE

ISO 9001 : 2008 CERTIFIED HOSPITAL

Patient Name: Mr. SUCHITA SHEWALE

Age / Gender: 37Yr /FEMALE

Req. Doctor: Dr. MANOJ CHOPDA

Request Date : 25.08.2022

Reporting Date : 25.08.2022

Report Status : Finalized

2D ECHO-CARDIOGRAPHY WITH PRINT.

OBSERVATION:

NORML SIZED LV WITH GOOD LV FUNCTION EF=60%

LEFT VENTRICLE - NORMAL SIZED
NO REGIONAL WALL MOTION ABNORMALITY
NO S/O LV HYPERTROPHY IVS = mm ,PW = mm PRESENT-
NO S/O DIASTOLIC DYSFUNCTION.
OVERALL GOOD LV FUNCTION.

LEFT ATRIUM - NORMAL, NO CLOT .

RIGHT ATRIUM /VENTRICLE -NORMAL SIZED
OVERALL GOOD RV FUNCTION.

ALL VALVES NORMAL

NO S/O PULMONARY HYPERTENSION PRESENT
PULMONARY ARTERY SYSTOLIC PRESSURE = mm Hg

NO S/O PERICARDIAL EFFUSION NOTED


DR. MANOJ CHOPDA
INTERVENTIONAL CARDIOLOGIST
M.D. (Medicine)
D.M. (Cardiology)
Consulting Cardiology
Reg.No.58940

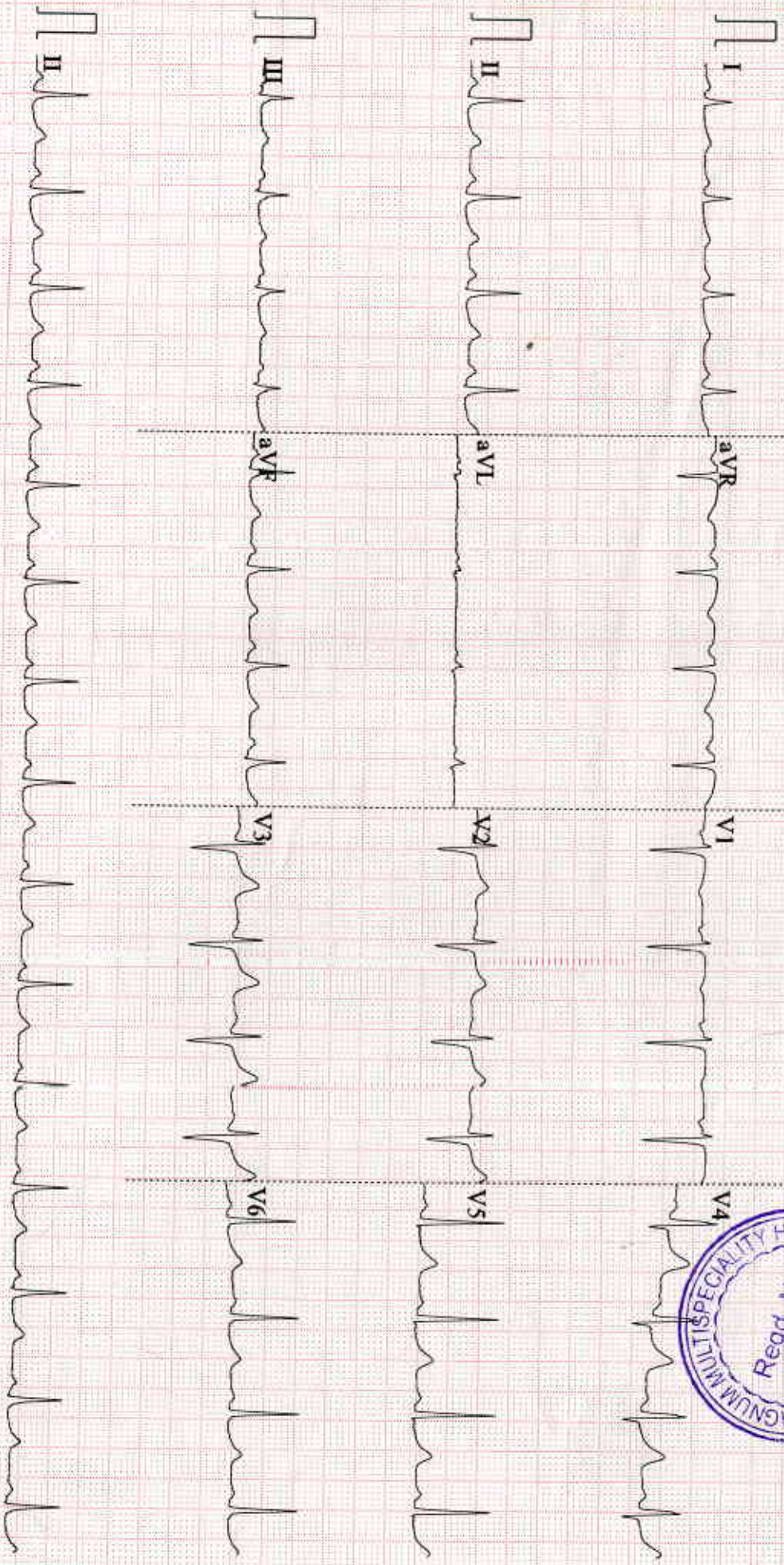


ID: 174
suchita shewale
Female 37Years
Department: casualty

24-08-2022 10:02:08 AM
HR : 89 bpm
P : 106 ms
PR : 124 ms
QRS : 86 ms
QT/QTc : 394/480 ms
P/QRS/T : 43/54/57
RV5/SV1 : 1.265/0.920 mV

Diagnosis Information:
Sinus rhythm
Prolonged QT - consider ischemia, electrolyte imbalance, drug effects
Borderline ECG

Report Confirmed by:



NAME: MRS. SUCHITA SHEWALE	DATE: 24/08/2022
AGE/ SEX: 37 YEARS/ FEMALE	REFERRED BY: -

XRAY CHEST PA (VIEW)

Findings

Both the lung fields are equally translucent.

The costo-phrenic angles are clear.

No hilar or mediastinal mass is seen.

Domes of diaphragm are normal in position and contour.

The cardiac outlines are normal.

No obvious skeletal abnormality is seen.

Impression

- **No significant abnormality is seen.**

Thank-you.



DR KUNAL KALYANRAO PATIL
MBBS. MD (RADIODIAGNOSIS)
CONSULTANT RADIOLOGIST.



डॉ. धर्मेंद्र चांदवाणी (एम.एस.)

बिनटाके नेत्र भिंगतज्ञ व कॉन्टॅक्टलेन्स तज्ञ

एकता आय हॉस्पिटल एन्ड लेझर सेंटर

देवळाली प्लाझा, पहिला मजला, एचडीएफसी. बँक समोर,
लॅम रोड, देवळाली कॅम्प, फोन : २४९७२३४
वेळ : सका १०.३० ते १.३०, सांय ५.३० ते ७.३०

श्रीलीला नेत्रालय

शिवम कॉम्प्लेक्स, पहिला मजला, मुक्तीधाम समोर,
नासिक रोड, फोन : २४५४९९७
वेळ - दु. १.३० ते ३.०० व सांय. ८.०० ते ९.००

मानद नेत्रतज्ञ - जयराम हॉस्पिटल, नाशिक रोड. फोन : २४६३४९४

रजि. नं. 62917

Mr. Sushra Shewale 24/08/2021
Mr. 37mf, MR

BE Extra
PMSM

2017

6/20 Sp. Wided
6/6 Sp

No Wided

findy BMS

Adv to use Spect

Tests R2 - 025-0752 80

12 - 05 - 10 2902
Aphor M
Chandraw



सुविधा : बिना टाक्यानी मोतीबिंदू शस्त्रक्रिया

Dr. SK Chandraw

• कॉन्टॅक्टलेन्स • काचबिंदू, तिरळेपणा इतर शस्त्रक्रिया