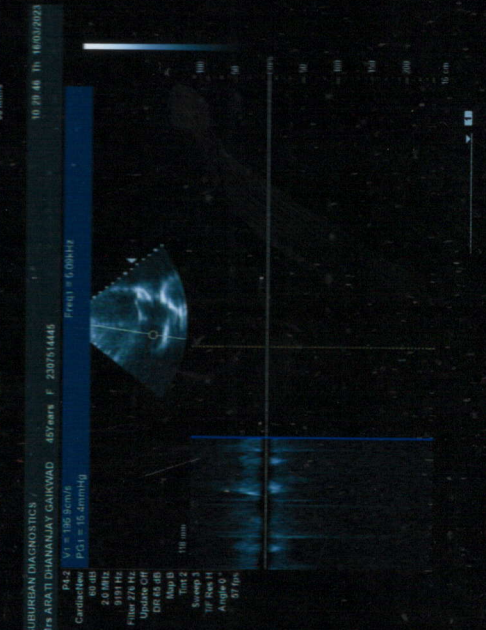
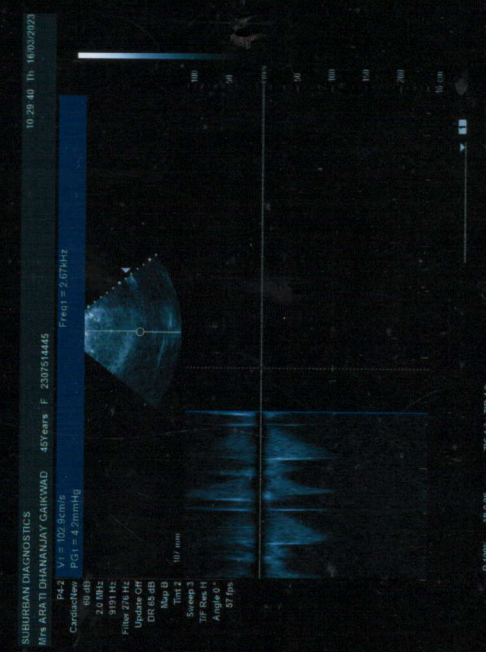
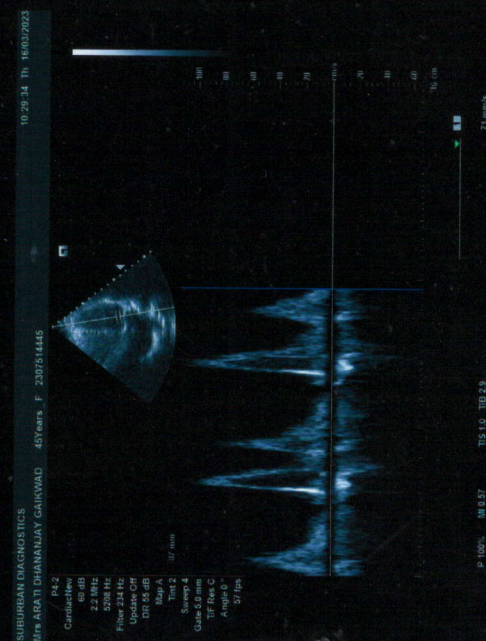
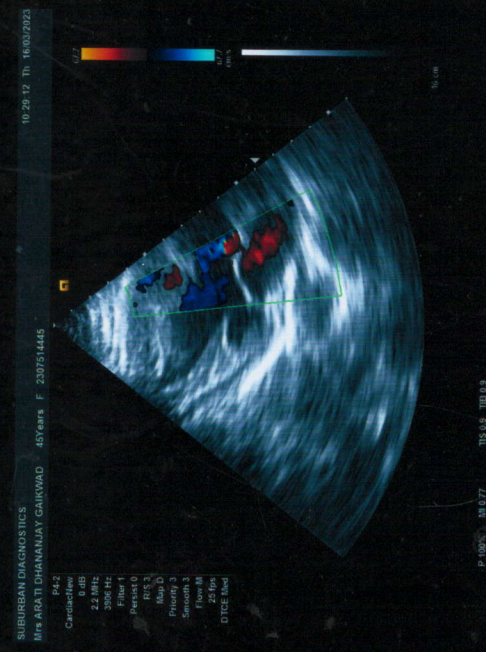
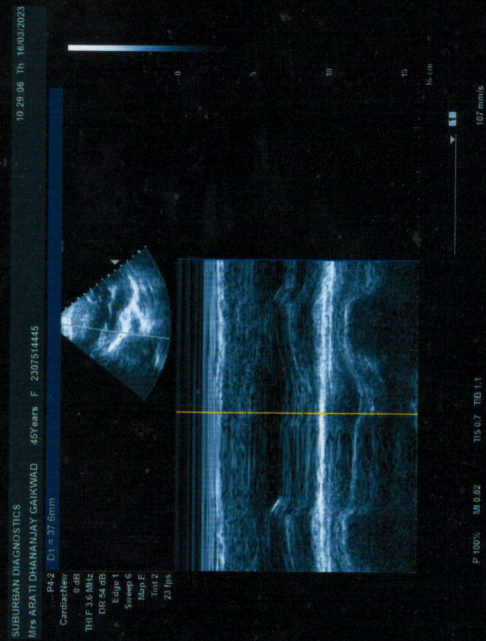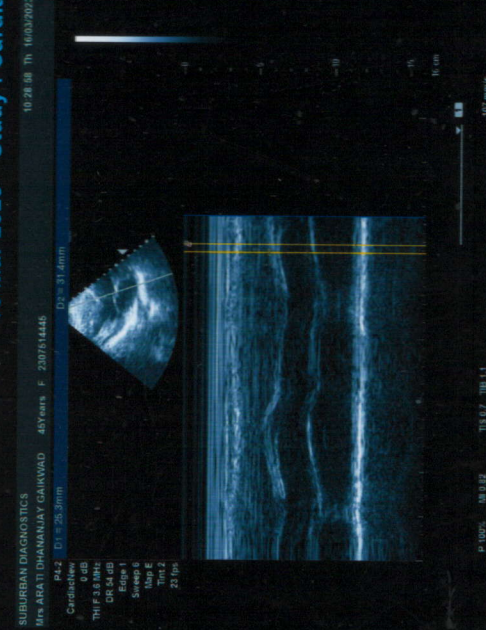
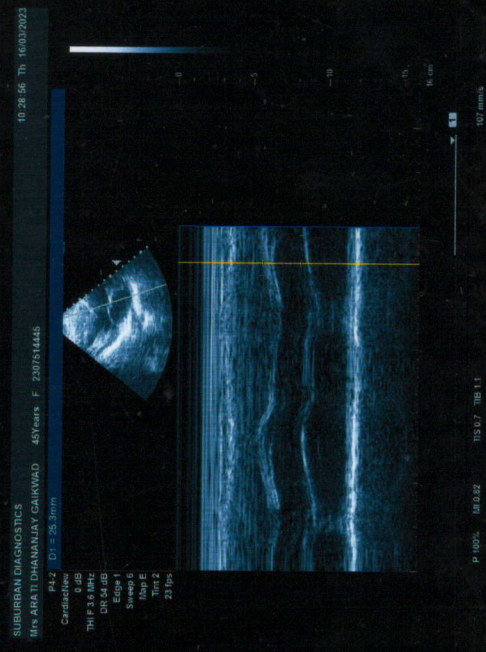

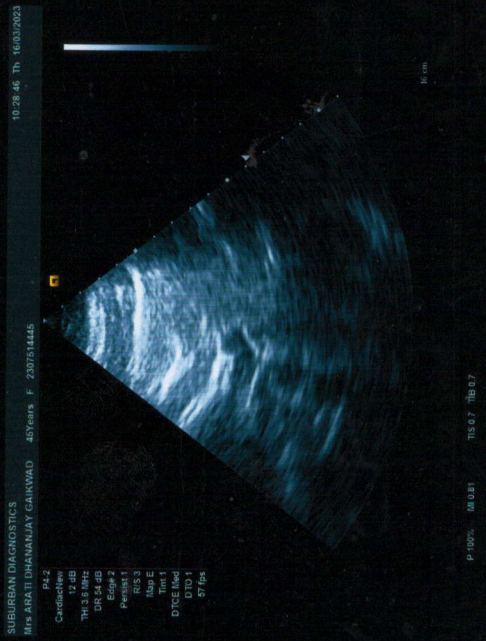
# SUBURBAN DIAGNOSTIC CENTRE

Name : Mrs ARATI DHANANJAY GAIKWAD 045Y / F

16 Mar 2023 Study : Cardiac





Asati Gaikwad  
45/F

~~PHYS~~ 2D

16-3-23

R  
E  
P  
O  
R  
T

**PHY2.**

**History and Complaints:**

NIL

**EXAMINATION FINDINGS:**

Height (cms):	148	Weight (kg):	56	BMI
Temp (0c):	Afebrile	adrb	Skin: Normal	J G M D
Blood Pressure (mm/hg):	100/70	Nails: Healthy		
Pulse:	68	Lymph Node: Not Palpable		

**Systems**

- Cardiovascular: S1,S2 Normal No Murmurs
- Respiratory: Air Entry Bilaterally Equal
- Genitourinary: Normal
- GI System: Soft non tender No Organomegaly
- CNS: Normal

**IMPRESSION:**

Grade I <sup>FIT</sup> fatty liver  
Borderline ↑ in TG, non HDL, LDL

**ADVICE:** Diet + Regular exercise.

**CHIEF COMPLAINTS:**

1)	Hypertension:	J G M D  NIL
2)	IHD:	
3)	Arrhythmia:	
4)	Diabetes Mellitus :	
5)	Tuberculosis :	
6)	Asthama:	
7)	Pulmonary Disease :	
8)	Thyroid/ Endocrine disorders :	

9)	Nervous disorders :	
10)	GI system :	
11)	Genital urinary disorder :	
12)	Rheumatic joint diseases or symptoms :	
13)	Blood disease or disorder :	nil
14)	Cancer/lump growth/cyst :	
15)	Congenital disease :	
16)	Surgeries :	(2015) # (L) Ankle - plate inserted & removed. 2017 Cx injection - H+ - 2022
<b>PERSONAL HISTORY:</b>		
1)	Alcohol	
2)	Smoking	no
3)	Diet	mixed
4)	Medication	nil



Dr. KRUTIKA INGLE  
 MBBS, D.DM, PG in Diabetology (USA)  
 MMC Regd - 2012 103018

CID : 2307513784  
Name : Mrs ARATI DHANANJAY GAIKWAD  
Age / Sex : 45 Years/Female  
Ref. Dr :  
Reg. Location : Pimple Saudagar, Pune Main Centre  
Reg. Date : 16-Mar-2023  
Reported : 16-Mar-2023 / 10:36

Use a QR Code Scanner  
Application To Scan the Code

### ULTRASOUND ABDOMEN AND PELVIS

**Liver-** Normal in size (14.7cm), size shape and raised echo pattern. No focal lesion. Intrahepatic biliary and portal radicals appear normal. Visualized portion of CBD appears normal in caliber. Portal vein appears normal.  
**Areas of focal fat sparing seen in segment VI & VII, largest seen 45 x 36 x 35mm in seg VI.**

**Gall bladder-** partially distended with normal wall thickness. No calculus or mass lesion is visualized. No pericholecystic collection.

**Pancreas-** Head and body are visualized and appear normal in size, shape and echo pattern. No focal lesion seen. No peripancreatic collection noted.

**Spleen -** Appears normal in size (8.1cm), shape & echo pattern. No focal lesion seen.

**Kidneys-** Right kidney -9.3 x 3.5cm, Left kidney -9.3 x 3.3cm, both kidneys appear normal in size, shape, position & echo pattern with maintained corticomedullary differentiation. No hydronephrosis, hydroureter or calculus noted.

**Urinary bladder-** Is partially distended & shows normal wall thickness. No calculus or mass lesion is noted.

**Uterus & Ovaries-** The uterus- 66 x 31 x 38mm is anteverted and appears normal. The endometrial thickness is 6.3mm. Right ovary = 28.3 x 19.2mm MSF. Left ovary is not seen on TAS, likely obscured, suggested follow up imaging.

No free fluid in abdomen and pelvis. Visualized bowel loops are distended appear grossly normal and show normal peristalsis. No evidence of enlarged lymph nodes.

#### IMPRESSION:

- Grade I fatty liver with focal areas of fat sparing in seg VII/ VI.
- No significant sonological abnormality detected.

Advice - Clinical correlation and further evaluation if clinically indicated.

-----End of Report-----

Dr. Divya Chaudhary  
MBBS, M.D. RADIODIAGNOSIS,  
DNB, RADIOLOGIST  
MMC Reg - 2016/01/0064

Click here to view images <<ImageLink>>

CENTRAL PROCESSING LAB: 2<sup>nd</sup> Floor, Aston, Sundervan Complex, Above Mercedes Showroom, Andheri West, Mumbai - 400058

HEALTHLINE - MUMBAI: 022-6170-0000 | OTHER CITIES: 1800-266-4343 | For Feedback - customerservice@suburbandiagnosics.com | www.suburbandiagnosics.com

Disclaimer: (1)Suburban Diagnostics ensures that the tests are conducted with utmost care and safety and are performed on samples received as per the sample collection guide of Suburban Diagnostics. (2) Test results are not acceptable for the requested tests. (3)Test results may vary from laboratory to laboratory and also in some parameters from time to time. (4)Test results are for informational purposes only. (5)Patient information or data will not be shared with any third party without the consent of the patient. (6)Patient information or data will not be shared with any third party without the consent of the patient.

**2D ECHO / COLOUR DOPPLER**

NAME : MRS ARATI GAIKWAD  
REF BY: CORP  
CID NO: 2307514445

Age:45 /Y FEMALE  
DATE :16.03.2023  
REG LOC: PIMPLE SAUDAGAR PUNE

**M - Mode values**

**Doppler Values**


AORTIC ROOT (mm)	22	PULMONARY VEL (m/sec)	0.8
LEFT ATRIUM (mm)	32	PG (mmHg)	3
RV (mm)	28	AORTIC VALVE M/SEC	1.5
IVS - D (mm)	11	PG (mmHg)	4
LVID - D (mm)	40	MITRAL E VEL (m/sec)	0.8
LVID - S (mm )	20	A VEL (m/ sec)	0.5
LVPW - D (mm)	11	TRICUSPID VEL. (m/sec)	1.5
EJECTION FRACTION (%)	60	PG (mmHg)	10

**OBSERVATION:**

All four cardiac valves are structurally normal.  
All four cardiac chambers normal in dimensions.  
Normal left ventricle size with Good ventricle systolic function .(LVEF-65%)  
No Regional wall motion abnormality.  
Left atrium, Right atrium & Right ventricle are normal in size.  
No pulmonary artery hypertension. RVSP = 20 mmHg.  
Interatrial septum & Interventricular septum are intact.  
No clot/vegetation /pericardial effusion.  
Doppler study revealed mild mitral regurgitation , mild tricuspid regurgitation.  
IVC 1.5 cm, more than 50% pulsatile.  
Left sided aortic arch, No coarctation of aorta.  
No diastolic dysfunction.

**CONCLUSION:**

Normal left ventricle size with Good ventricle systolic function .(LVEF-65%)  
No pulmonary artery hypertension. RVSP = 20 mmHg.

  
**DR SONAM SHAH**  
MD DM CARDIOLOGY  
INTERVENTIONAL CARDIOLOGIST

Dr. Sonam Shah  
MBBS MD DM Cardiology  
Interventional Cardiologist  
MMC 2010 / 06 / 2218

Authenticity Check



Use a QR Code Scanner  
Application To Scan the Code

CID : 2307513784  
Name : Mrs ARATI DHANANJAY GAIKWAD  
Age / Sex : 45 Years/Female  
Ref. Dr :  
Reg. Location : Pimple Saudagar, Pune Main Centre

Reg. Date : 16-Mar-2023  
Reported : 16-Mar-2023 / 10:17

**X-RAY CHEST PA VIEW**

Trachea is central.

Slightly prominent bronchovascular markings are noted bilaterally.

Visualized bilateral lung fields otherwise appear grossly normal.

Both hila appear normal.

Cardiac silhouette has grossly normal appearance for age.

Bilateral costophrenic and cardiophrenic angles appear grossly normal.

Visualized bony thorax and soft-tissues are grossly normal for age.

**IMPRESSION :**

- Normal CXR.

*Advice - Clinical correlation and further evaluation if clinically indicated.*

-----End of Report-----

Dr. Divya Chaudhary  
MBBS, M.D. RADIODIAGNOSIS,  
DNB, RADIOLOGIST  
MMC Reg - 2016/01/0064

Preventive Health Check-up | Pathology | Digital X-Ray | Sonography | Colour Doppler | Mammography | BMD (DXA Scan) | OCT |  
Stress Test/TMT | 2D Echo | Spirometry | Eye Examination | Dental Examination | Diet Consultation | Audiometry | OT Sterility | Water Sterility | Clinical Res

Date:- 16.3.21

CID:

Name:- Anjali Gaikwad

Sex / Age: 48 / F

**EYE CHECK UP**

Chief complaints:

Systemic Diseases:

Past history:

Unaided Vision:

Aided Vision:

Refraction:

3 ml

\_\_\_\_\_ 1 ml

1 ml

(Right Eye)

(Left Eye)

	Sph	Cyl	Axis	Vn	Sph	Cyl	Axis	Vn
Distance	_____	_____	_____	6/6	_____	_____	_____	6/6
Near	_____	_____	_____	12/6	_____	_____	_____	12/6

Colour Vision: Normal / ~~Abnormal~~

Remark:

nil

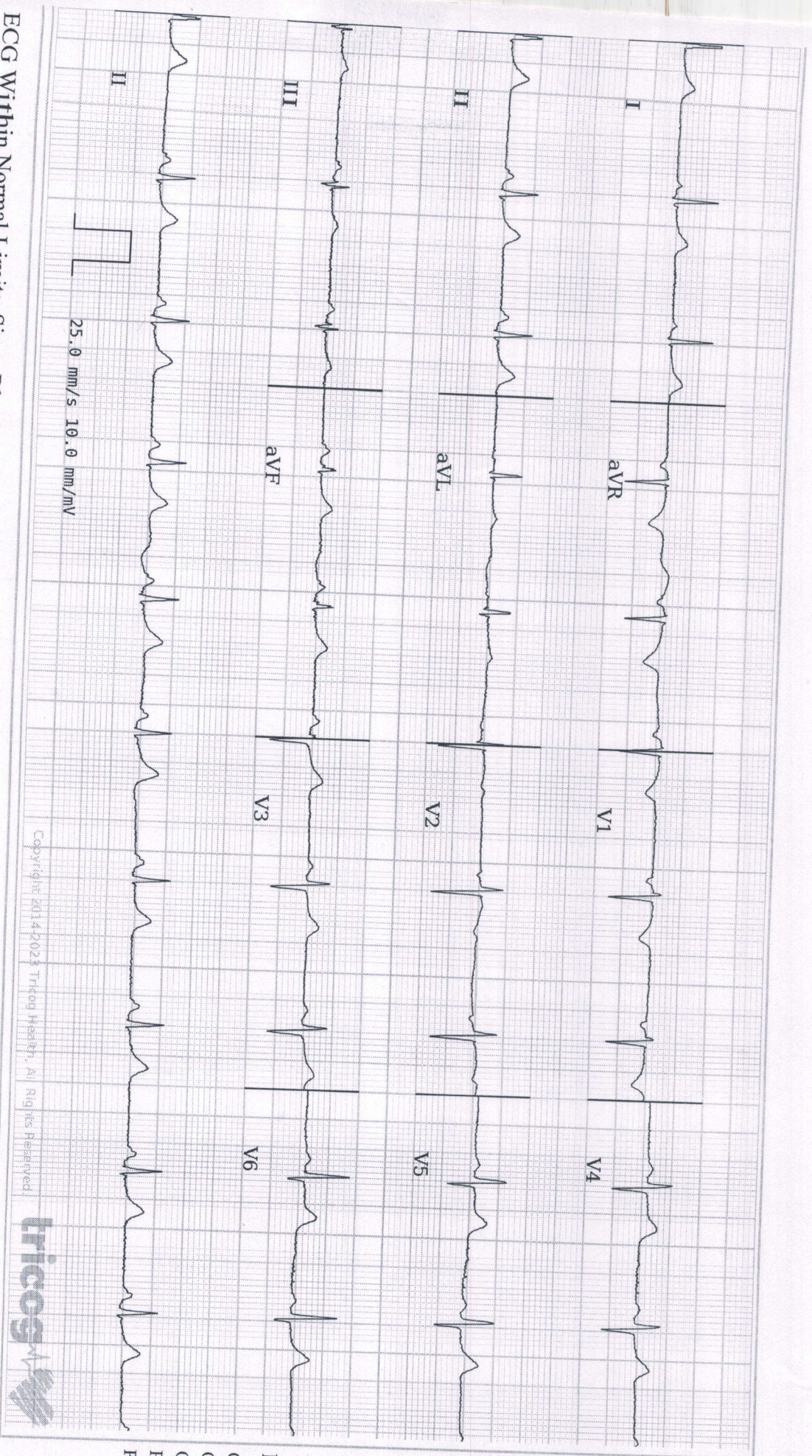
*[Signature]*

DE. KRISHNAIAH

MBBS, D.DM, PG in Diabetology (USA)  
MMC Regd - 2012 103018



**SUBURBAN DIAGNOSTICS - TWIFLE SAUDAGAR, FUNE**  
Patient Name: ARATI DHANANJAY GAIKWAD Date and Time: 16th Mar 23 8:50 AM  
Patient ID: 2307513784



ECG Within Normal Limits: Sinus Rhythm. Please correlate clinically.

Age **45** 5  
years months

Gender **Female**

Heart Rate **62bpm**

Patient Vitals

BP: 100/70 mmHg

Weight: 56 kg

Height: 148 cm

Pulse: 68 bpm

SpO2: NA

Resp: NA

Others:

**Measurements**

QRSD: 76ms

QT: 418ms

QTc: 424ms

PR: 134ms

P-R-T: 70° 27° 47°

REPORTED BY

*[Signature]*

Dr. Kritika Ingole  
MBBS, DDM, PG in Diabetology (USA)  
2012103018


Disclaimer: 1) Analysis in this report is based on ECG alone and should be used as an adjunct to clinical history, symptoms, and results of other invasive and non-invasive tests and must be interpreted by a qualified physician. 2) Patient vitals are as entered by the clinician and not derived from the ECG.

भारत सरकार  
आरती धनंजय गायकवाड  
Arati Dhananjay Gaikwad  
जन्म तारीख/DOB: 06/10/1977  
लिंग/SEX: FEMALE  
Mobile No: 9850090104  
**2074 2894 1770**  
VID : 9145 5833 3165 1688

माझे आधार, माझी ओळख



**SUBURBAN DIAGNOSTIC (I) PVT. LTD.**  
"Fortuna" Ground Floor, Near Shivar  
Garden Chowk, Next to Radha Krishna  
Hotel, Pimple Saudagar, Pune-411 027.

*Arati*

**आधार**  
भारतीय विशिष्ट पहचान प्राधिकरण  
UNIQUE IDENTIFICATION AUTHORITY OF INDIA

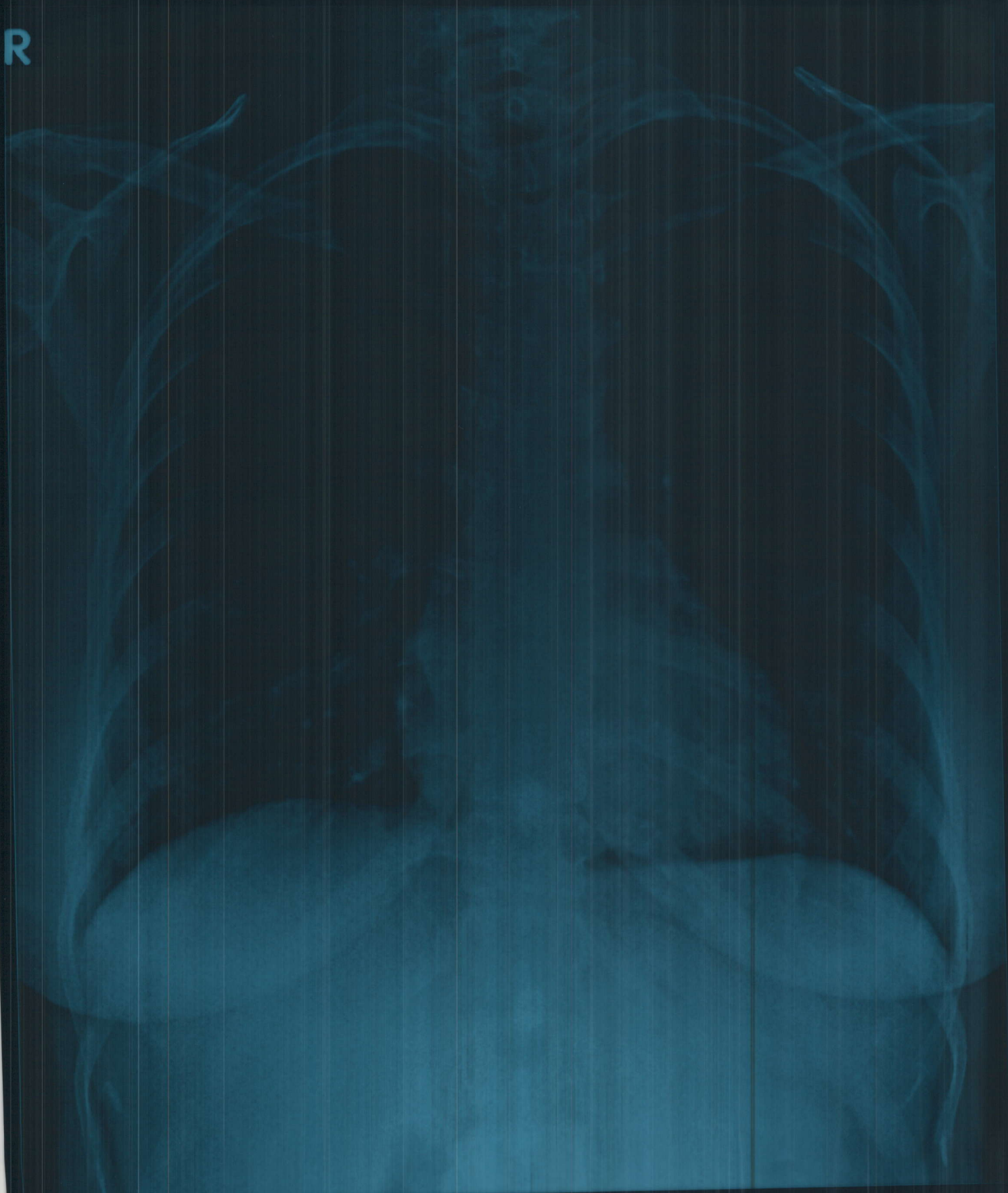
पत्ता:  
W/O: धनंजय गायकवाड, फ्लॉट नं 13, बिल्डिंग नं बी-2,  
सुखवानी इंपेरियल, फेज-2, हॉटेल घरोदा मागे, मोरवाडी,  
पिंपरी, पुणे शहर, पुणे,  
महाराष्ट्र - 411018

**Address :**  
W/O: Dhananjay Gaikwad, Flat No 13, Building No  
B-2, Sukhawani Imperial, Phase- 2, Behind Hotel  
Gheronda, Morwadi, Pimpri, Pune City, Pune,  
Maharashtra - 411018



1847 1200 300 1847 help@uidai.gov.in www.uidai.gov.in P.O. Box No. 1847, Bengaluru-560 001

R



Mrs ARATI DHANANJAY GAIKWAD F 045Y 2307513784 CHEST PA  
SUBURBAN DIAGNOSTICS PIMPLE SAUDAGAR