

Veena Nagar Phase II, Tulsi Pipe Line Road,
Near Swapna Nagri Road, Mulund (W) Mumbai 400 080.
email: info@apexhospitals.in | www.apexgroupofhospitals.com



Tele.:
022-41624000 (100 Line)

11/3/24

Name - Vishal Alishetty
Age - 49y/M

No H/O major illness

P1STH - Inguinal hernia operated (2020)
(details not available)

O/E - T - Afebrile
P - 64/min
BP - 100/60 mmHg
RR - 18/min
SpO₂ - 99% @ RA


S/P - CNS - S₁, S₂ (+)
RS - BSBE
P/A - S₁th
CNS - conscious & oriented

Height - 161 cm } BMI - 20.87
Weight - 49 kg }

Dental check up - Normal

Eye check up - To do optometrist opinion
S/I/O spectacles.

Ear check up - Normal



Veena Nagar Phase II, Tulsi Pipe Line Road,
Near Swapna Nagri Road, Mulund (W) Mumbai 400 080.
email: info@apexhospitals.in | www.apexgroupofhospitals.com



Tele.:
022-41624000 (100 Lines)

Patient Name	: MR. VISHAL ALISHETTY	Patient ID	: 85217
Age/Sex	: 49 Years /Male	Sample Collected on	: 11-3-24, 12:00 pm
Ref Doctor	: APEX HOSPITAL	Registration On	: 11-3-24, 12:00 pm
Client Name	: Apex Hospital	Reported On	: 11-3-24, 8:39 pm

Test Done	Observed Value	Unit	Ref. Range
Complete Blood Count(CBC)			
HEMOGLOBIN	15.4	gm/dl	12 - 16
Red Blood Corpuscles			
PCV (HCT)	45.3	%	42 - 52
RBC COUNT	5.09	x10 ⁶ /uL	4.70 - 6.50
RBC Indices			
MCV	89.0	fl	78 - 94
MCH	30.2	pg	26 - 31
MCHC	33.9	g/L	31 - 36
RDW-CV	14.8	%	11.5 - 14.5
White Blood Corpuscles			
TOTAL LEUCOCYTE COUNT	7800	/cumm	4000 - 11000
Differential Count			
NEUTROPHILS	69	%	40 - 75
LYMPHOCYTES	28	%	20 - 45
EOSINOPHILS	02	%	0 - 6
MONOCYTES	01	%	1 - 10
BASOPHILS	0	%	0 - 1
Platelets			
PLATELET COUNT	237000	Lakh/cumm	150000 - 450000
MPV	8.6	fl	6.5 - 9.8
RBC MORPHOLOGY	Normochromic, Normocytic		
WBC MORPHOLOGY	No abnormality detected		
PLATELETS ON SMEAR	Adequate on Smear		

Instrument : Mindray BC 3000 Plus

Dr. Hrishikesh Chevle
(MBBS . DCP .)

Veena Nagar Phase II, Tulsi Pipe Line Road,
Near Swapna Nagri Road, Mulund (W) Mumbai 400 080.
email: info@apexhospitals.in | www.apexgroupofhospitals.com



Tele.:
022-41624000 (100 Line)

Patient Name	: MR. VISHAL ALISHETTY	Patient ID	: 85217
Age/Sex	: 49 Years /Male	Sample Collected on	: 11-3-24,12:00 pm
Ref Doctor	: APEX HOSPITAL	Registration On	: 11-3-24,12:00 pm
Client Name	: Apex Hospital	Reported On	: 11-3-24, 8:39 pm

Test Done	Observed Value	Unit	Ref. Range
-----------	----------------	------	------------

Blood Group & RH Factor

SPECIMEN	WHOLE BLOOD
ABO GROUP	'O'
RH FACTOR	POSITIVE
INTERPRETATION	

The ABO system consists of A, B, AB, and O blood types. People with type AB blood are called universal recipients, because they can receive any of the ABO types. People with type O blood are called universal donors, because their blood can be given to people with any of the ABO types. Mismatches with the ABO and Rh blood types are responsible for the most serious, sometimes life-threatening, transfusion reactions. But these types of reactions are rare.

Rh system
The Rh system classifies blood as Rh-positive or Rh-negative, based on the presence or absence of Rh antibodies in the blood. People with Rh-positive blood can receive Rh-negative blood, but people with Rh-negative blood will have a transfusion reaction if they receive Rh-positive blood. Transfusion reactions caused by mismatched Rh blood types can be serious.

Dr. Hrishikesh Chevle
(MBBS . DCP.)

Veena Nagar Phase II, Tulsi Pipe Line Road,
Near Swapna Nagri Road, Mulund (W) Mumbai 400 080.
email: info@apexhospitals.in | www.apexgroupofhospitals.com

visit website
googlemap



Tele.:
022-41624000 (100 Lines)

Patient Name	: MR. VISHAL ALISHETTY	Patient ID	: 85217
Age/Sex	: 49 Years /Male	Sample Collected on	: 11-3-24,12:00 pm
Ref Doctor	: APEX HOSPITAL	Registration On	: 11-3-24,12:00 pm
Client Name	: Apex Hospital	Reported On	: 11-3-24, 8:39 pm

Test Done	Observed Value	Unit	Ref. Range
ESR (ERYTHROCYTES SEDIMENTATION RATE)			
ESR	13	mm/1hr.	0 - 20
METHOD - WESTERGREN			

Dr. Hrishikesh Chevle
(MBBS.DCP.)

Veena Nagar Phase II, Tulsi Pipe Line Road,
Near Swapna Nagri Road, Mulund (W) Mumbai 400 080.
email: info@apexhospitals.in | www.apexgroupofhospitals.com




Tele.:
022-41624000 (100 Line)

Patient Name : **MR. VISHAL ALISHETTY**
Age/Sex : 49 Years /Male
Ref Doctor : APEX HOSPITAL
Client Name : Apex Hospital

Patient ID : 85217
Sample Collected on : 11-3-24, 12:00 pm
Registration On : 11-3-24, 12:00 pm
Reported On : 11-3-24, 8:39 pm

Test Done	Observed Value	Unit	Ref. Range
BLOOD GLUCOSE FASTING & PP			
FASTING BLOOD GLUCOSE	86.5	mg/dL	70 - 110
URINE GLUCOSE	NO SAMPLE		ABSENT
URINE KETONE	NO SAMPLE		ABSENT
POST PRANDIAL BLOOD GLUCOSE	98.0	mg/dL	70 - 140
URINE GLUCOSE	NO SAMPLE		ABSENT
URINE KETONE	NO SAMPLE		ABSENT

Method - GOD-POD



Dr. Hrishikesh Chevle
(MBBS . DCP .)

Veena Nagar Phase II, Tulsi Pipe Line Road,
Near Swapna Nagri Road, Mulund (W) Mumbai 400 080.
email: info@apexhospitals.in | www.apexgroupofhospitals.com



Tele.:
022-41624000 (100 Line)

Patient Name	: MR. VISHAL ALISHETTY	Patient ID	: 85217
Age/Sex	: 49 Years /Male	Sample Collected on	: 11-3-24,12:00 pm
Ref Doctor	: APEX HOSPITAL	Registration On	: 11-3-24,12:00 pm
Client Name	: Apex Hospital	Reported On	: 11-3-24, 8:39 pm

Test Done	Observed Value	Unit	Ref. Range
LIVER FUNCTION TEST			
TOTAL BILLIRUBIN	0.65	mg/dL	UP to 1.2
DIRECT BILLIRUBIN	0.23	mg/dL	UP to 0.5
INDIRECT BILLIRUBIN	0.42	mg/dL	UP to 0.7
SGOT(AST)	27.0	U/L	UP to 40
SGPT(ALT)	14.4	U/L	UP to 40
ALKALINE PHOSPHATASE	216.9	IU/L	64 to 306
S. PROTIEN	5.99	g/dl	6.0 to 8.3
S. ALBUMIN	3.14	g/dl	3.5 - 5.0
S. GLOBULIN	2.85	g/dl	2.3 to 3.6
A/G RATIO	1.10		0.9 to 2.3

METHOD - EM200 Fully Automatic



Dr. Hrishikesh Chevle
(MBBS.DCP.)

Veena Nagar Phase II, Tulsi Pipe Line Road,
Near Swapna Nagri Road, Mulund (W) Mumbai 400 080.
email: info@apexhospitals.in | www.apexgroupofhospitals.com



Tele.:
022-41624000 (100 Line)


Patient Name : **MR. VISHAL ALISHETTY**
Age/Sex : 49 Years /Male
Ref Doctor : APEX HOSPITAL
Client Name : Apex Hospital

Patient ID : 85217
Sample Collected on : 11-3-24, 12:00 pm
Registration On : 11-3-24, 12:00 pm
Reported On : 11-3-24, 8:39 pm

Test Done	Observed Value	Unit	Ref. Range
RENAL FUNCTION TEST			
BLOOD UREA	27.4	mg/dL	10 - 50
BLOOD UREA NITROGEN	12.80	mg/dL	0.0 - 23.0
S. CREATININE	1.09	mg/dL	0.7 to 1.4
S. SODIUM	140.2	mEq/L	135 - 155
S. POTASSIUM	4.07	mEq/L	3.5 - 5.5
S. CHLORIDE	108.8	mEq/L	95 - 109
S. URIC ACID	3.56	mg/dL	3.5 - 7.2
S. CALCIUM	9.96	mg/dL	8.4 - 10.4
S. PHOSPHORUS	3.97	mg/dL	2.5 - 4.5
S. PROTIEN	5.99	g/dl	6.0 to 8.3
S. ALBUMIN	3.14	g/dl	3.5 to 5.3
S. GLOBULIN	2.85	g/dl	2.3 to 3.6
A/G RATIO	1.10		1.0 to 2.3

METHOD - EM200 Fully Automatic

INTERPRETATION -



Dr. Hrishikesh Chevle
(MBBS.DCP.)



APEX HOSPITALS MULUND DIAGNOSTIC

ALL
CASHLESS
FACILITY

Veena Nagar Phase II, Tulsi Pipe Line Road,
Near Swapna Nagri Road, Mulund (W) Mumbai 400 080.
email: info@apexhospitals.in | www.apexgroupofhospitals.com



Tele.:
022-41624000 (100 Line)

Patient Name : **MR. VISHAL ALISHETTY**
Age/Sex : 49 Years / Male
Ref Doctor : APEX HOSPITAL
Client Name : Apex Hospital

Patient ID : 85217
Sample Collected on : 11-3-24, 12:00 pm
Registration On : 11-3-24, 12:00 pm
Reported On : 11-3-24, 8:39 pm

Test Done	Observed Value	Unit	Ref. Range
LIPID PROFILE			
TOTAL CHOLESTEROL	160.2	mg/dL	200 - 240
S. TRIGLYCERIDE	104.7	mg/dL	0 - 200
S.HDL CHOLESTEROL	42.9	mg/dL	30 - 70
VLDL CHOLESTEROL	21	mg/dL	Up to 35
S.LDL CHOLESTEROL	96.36	mg/dL	Up to 160
LDL CHOL/HDL RATIO	2.25		Up to 4.5
CHOL/HDL CHOL RATIO	3.73		Up to 4.8
Transasia-EM200 FULLY AUTOMATIC			

INTERPRETATION

Above reference ranges are as per ADULT TREATMENT PANEL III RECOMMENDATION by NCEP (May 2015).



Where Healing & Care Comes Naturally

APEX HOSPITALS MULUND

A Superspeciality Hospital

Veena Nagar Phase II, Tulsi Pipe Line Road,
Near Swapna Nagri Road, Mulund (W) Mumbai 400 080.
email: info@apexhospitals.in | www.apexgroupofhospitals.com

visit website
googlemap



ALL
CASHLESS
FACILITY

Tele.:
022-41624000 (100 Line)

NAME: Mr. Vishal Alishetty

M/49

Date - 11/03/2024

REF.BY: mediwheel

COLOR DOPPLER 2D ECHOCARDIOGRAPHY SECTOR ECHOCARDIOGRAPHY

Left ventricle normal in size and function

Right ventricle normal in size and Function

Other Cardiac chambers appear normal in dimension.

Mitral and Aortic valve normal

No RWMA

LV systolic function is good at rest. LVEF 55-60%

No e/o coarctation.No e/o clot / Vegetation / Effusion seen.

IVC 11 mm , Collapsing with inspiration.

Intact IAS and IVS .

COLOR FLOW.CW,PW & HAEMODYNAMIC DATA.

Aortic valve gradient 10 mmHg.

No MS / Trivial TR

Normal flow across all other cardiac valves.

Pulmonary pressure of 18 mm of Hg.

CONCLUSION.-

Normal Biventricular Systolic and diastolic function

LVEF-55-60%

Trivial TR

No e/o pulmonary hypertension

DR.Ravindra Ghule

(Consultant cardiologist)

DR. RAVINDRA GHULE
DNB (Medicine), DNB (Cardiology)
Reg. No. 2009 / 08 / 3093



Where Healing & Care Comes Naturally

APEX HOSPITALS MULUND DIAGNOSTIC

ALL
CASHLESS
FACILITY

Veena Nagar Phase II, Tulsi Pipe Line Road,
Near Swapna Nagri Road, Mulund (W) Mumbai 400 080.
email: info@apexhospitals.in | www.apexgroupofhospitals.com



Tele.:
022-41624000 (100 Line)

NAME : MR. VISHAL ALISHETTY

49/M

11/03/2024

REF.BY : MEDIWHEEL

USG ABDOMEN AND PELVIS SONOGRAPHY

Liver is of normal size and show normal echo texture. No evidence of focal lesion in Liver. Portal vein appears normal, No dilated I.H.B.R. No evidence pleural effusion.

Gall bladder is well distended. No Evidence of cholelithiasis.

C.B.D appears normal, and No evidence of calculi in it.

Pancreas shows normal echogenicity. No signs of acute or chronic Pancreatitis.

Spleen shows normal echogenicity and it is of normal size.
No evidence of Para aortic Lymphadenopathy or Ascites.

Right kidney measures : 9.2 x 3.2 cm.

Left kidney measures : 7.7 x 4.2 cm.

No evidence of renal calculi or Hydronephrosis. No evidence of S.O.L.
Cortical echogenicity on ether side appears normal.

No dilated upper or lower ureters are seen.

Bladder show smooth margin and there is no evidence of vesicle calculi.

Prostate measures : 2.9 x 3.9 x3.5 (volume =22 cc)

Normal in size and echotexture.No focal lesion.

REMARK :

- No Abnormality seen.


Dr. Kamlesh Jain

(Consultant Radiologist)

DR. KAMLESH JAIN
DMRD (RADIOLOGY)
2002/03/1656

Patient Name : MR VISHAL ALISHETTY	Gender : Male
Age : 49 Y	Date : 11/03/2024
Referring Doctor : APEX HOSPITAL	Patient ID :

X-RAY CHEST PA VIEW (PORTABLE)

FINDINGS:

Normal bronchovascular markings in bilateral lung fields.
Bilateral hila are normal.
Trachea appears normal.
Cardiac shadow is within normal limits.
The domes of diaphragm are normal in position and shows smooth outline.
Bilateral costophrenic angles are clear.
Visualized bones are grossly normal.
Visualised soft tissue shadows are normal.

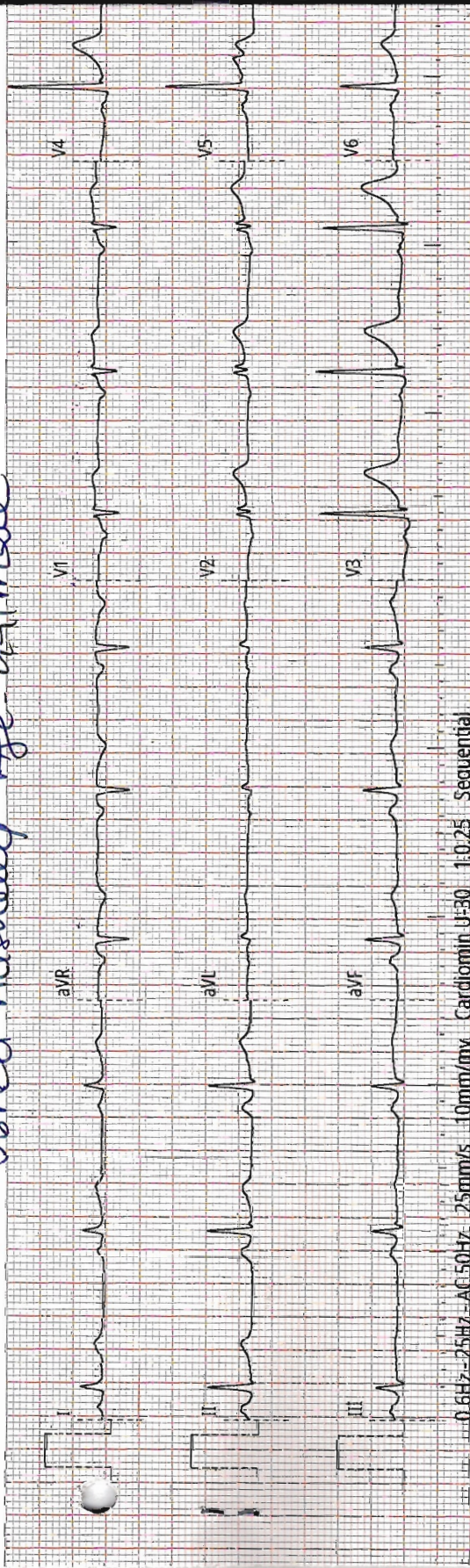
IMPRESSION:

- No significant abnormality detected

Hemant Pralhad Pakhale

DR. Hemant Pralhad Pakhale
MBBS DMRD DNB
Reg - 89365

Wishal Aishetty Age: 41/male



0.6Hz-25Hz-AC 50Hz-25mm/s 10mm/mv Cardiomin U-30 1:0.25 Sequential

ECG report

ID : 2024031104819
Name :
Gender :
Age :
Dept :
Bed No :

HR : 70 bpm
PR : 148 ms
QRS : 78 ms
QT/QTc : 378/396 ms
P/QRS/T : 67/61/48°
RV5/SV1 : 1.20/1.0.281 mv
RV5+SV1 : 1.482 mv

< Interpretations >>

Apex Hospitals (Pvt) Ltd
Veeru Nagar, Phase 2,
Tubai Pipe Line Road, Near Sankar,
Nagar Road, Akurdi, Pune 411 004, Maharashtra,
India (IN) Mumbai - 411 004

Confirm and sign:
Examination time: 2024-03-11 10:48:19

