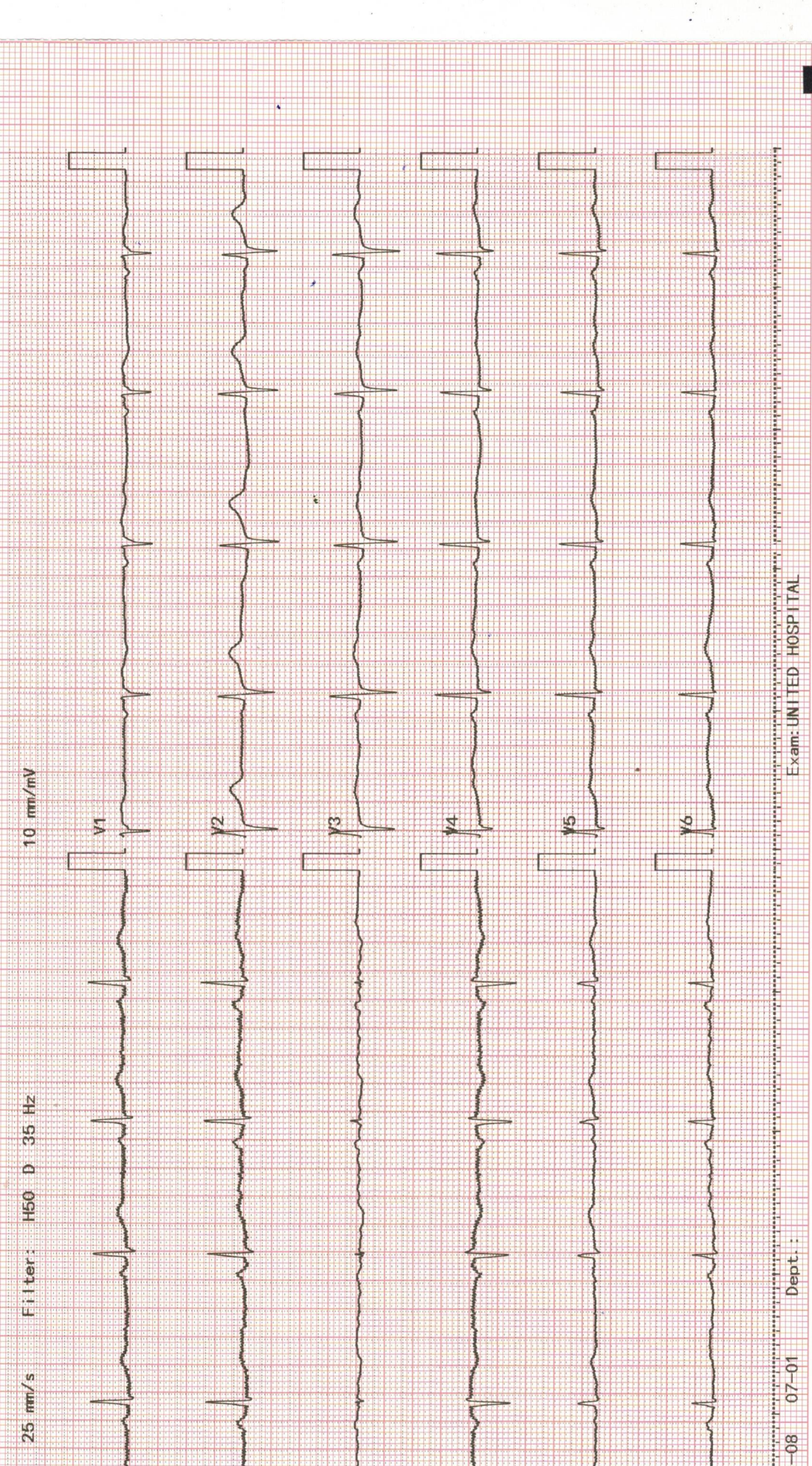


Name: gayatri
 Birth date: /
 Birth date: 49 years
 Weight: kg
 Height: cm
 Blood pressure: mmHg
 Heart rate: bpm
 PR interval: ms
 QRS duration: ms
 QTc(E) interval: ms
 ST axis: 54/ 40/ 19
 SV1 amp: 0.72/ 0.54 mV
 SV1 amp: 1.26 mV





NABH



NABL



No.1

**UNITED
HOSPITAL**Care Par Excellence
Jayanagar, Bangalore

Patient name :	Mrs. GAYATHRI	Date :	13/01/24
Age :	49 years GENDER: FEMALE	Patient ID :	15385
Ref by :	DR. CMO	OP/ IP :	HEALTH CHECKUP

2D- ECHOCARDIOGRAPHY**M - MODE AND DOPPLER MEASUREMENTS**

(c.m)	(c.m)	(cm/sec)		
AO : 2.4 (2.5-3.7)	LVIDD : 4.5 (3.5-5.5)	MV EV : 82.9	AV : 68.9	MR : NORMAL
LA : 3.2 (1.9-4.0)	LVIDS : 2.7 (2.4-4.2)	AV : 114		AR : NORMAL
RA : 2.4 (<4.4)	IVSD : 0.8 (0.6-1.1)	PV : 71.8		PR : NORMAL
RV : 2.0 (<3.5)	IVSS : 1.0 (0.9-1.2)	TV EV : ----	AV : ----	TR : TRIVIAL TR
TAPSE: 1.8 (>1.6)	LVPWD : 0.9 (0.6-1.1)	Diastolic Function : NO LVDD		
	LVPWS : 1.0 (0.9-1.2)			
	EF : 60%			

DESCRIPTIVE FINDINGS

Left Ventricle	: NORMAL
Right Ventricle	: NORMAL
Left Atrium	: NORMAL
Right Atrium	: NORMAL
Wall motion analysis	: NO RWMA
Mitral Valve	: NORMAL
Aortic Valve	: NORMAL
Tricuspid Valve	: NORMAL, TRIVIAL TR, PASP-30mmHg
Pulmonary Valve	: NORMAL
IAS	: INTACT
IVS	: INTACT
Pericardium	: NORMAL
Other Findings	: IVC NORMAL AND COLLAPSING

IMPRESSION:

NORMAL CHAMBER DIMENSIONS
 NORMAL LV SYSTOLIC FUNCTION EF : 60%
 NORMAL LV DIASTOLIC FUNCTION
 NO PULMONARTERY HYPERTENSION
 NO REGIONAL WALL MOTION ABNORMALITIES
 NO CLOTS/ PERICARDIAL EFFUSION /VEGETATION

DR. RAHUL S PATIL
 CONSULTANT CARDIOLOGIST



NABH



NABL



No.1



UNITED HOSPITAL

Care Par Excellence
Jayanagar, Bangalore

ms Gayatri 49y

13/1/24

Dr. Yoga Lakshmi SK
MBBS, MS OBG, FMAS
Consultant Obstetrician and
Gynecologist, Laparoscopy
and IVF Specialist
KMC Reg. No. 90384

for health check up.

BD-127/82 spi-85

99 chd y

Depend of exercise
as of respiratory, type
as of age 9y

P/A where checkup

P/S - E. Vegal
mild @ white dull @

P/L
All over
Cholesterol
Cervical
~~prognosis~~
C/S - 3000
PMS 20g

Brat R



NABH



NABL



No.1



UNITED HOSPITAL

Care Par Excellence
Jayanagar, Bangalore

Out Patient Record

Patient Name : Mrs.GAYATRI UHID : UHJA23015385
 Age / Sex : 49 Years / Female OP NO/Reg Dt : 13-01-2024 08:43 AM
 Spouse / Father Name : GOPAL R Département :
 Address : 813, JANANA BHARATHI 2ND BLOCK, Bengaluru Urban, Karnataka, INDIA, Referred By :
 Consultant : Dr.Preventive Health Check Up
 KMC No. :

Complaints / Findings / Observations :

Vi (glau) } blgp } my. } nil systemic
 blgp }
 blgp }

Investigations:

MI S OU normal

Treatment / Care of Plan / Provisional Diagnosis :

Endo's OU (Data 0.3:1 60:4:1)
 (undilted) FA 1

Follow Up Advice :

Tubrim OU Ref Endo.
 (Progenie glau.)

RE: -0.50 DC X 45° 6/6

LE: -0.25 DC X 150 6/6

BE Add +2.00 DS for near.

Signature of the Doctor

Dr. Shweta

13/1/24

DEPARTMENT OF RADIODIAGNOSIS

Name	Gayatri	Date	13/01/24
Age	49 years	Hospital ID	UHJA23015385
Sex	Female	Ref.	Health check

SONOMAMMOGRAPHY OF BILATERAL BREASTS

FINDINGS:

Skin and subcutaneous fat of bilateral breasts appear normal.

Heterogeneous background echotexture is seen in both breasts.

Small cyst measuring 6 x 4 mm with thin walls and anechoic contents is seen in the 10 o'clock position of right breast.

There is mild dilatation of one of the duct in the 8-9 o'clock position of right breast, lumen measuring upto 2.9 mm. Contents are anechoic. No obvious lesion is seen.

There is large lipoma measuring 8.2 x 4.3 x 7.2 cms in the upper outer quadrant of the left breast.

No focal solid lesions seen.

No significant lymphnodes noted in bilateral axilla.

IMPRESSION:

- Mild dilatation of one of the duct in the 8-9 o'clock position of right breast as mentioned above. BIRADS 3 – Probably benign. Suggested followup scan in 3-6 months.
- Small anechoic cyst in the right breast. BIRADS 2 – Benign.
- Large lipoma in the upper outer quadrant of the left breast.



Dr. Elluru Santosh Kumar
Consultant Radiologist

DEPARTMENT OF RADIODIAGNOSIS

Name	Gayatri	Date	13/01/24
Age	49 years	Hospital ID	UHJA23015385
Sex	Female	Ref.	Health check

ULTRASOUND ABDOMEN AND PELVIS

FINDINGS:

Liver is enlarged in size (16.4 cms) and shows moderate increased echopattern. No intra or extra hepatic biliary duct dilatation. No focal lesions. **Portal vein** is normal in size, course and caliber. **CBD** is not dilated.

Gall bladder is normal without evidence of calculi, wall thickening or pericholecystic fluid.

Pancreas - Visualized part of the pancreatic head and body appears normal in size, contour and echogenicity. Rest of the pancreas is obscured by bowel gas.

Spleen is normal in size, shape, contour and echopattern. No evidence of mass or focal lesions.

Right Kidney is normal in size (9.4 x 3.0 cms), position, shape and echopattern. Corticomedullary differentiation is maintained. No evidence of calculi or hydronephrosis.

Left Kidney is normal in size (11.3 x 3.5 cms), position, shape and echopattern. Corticomedullary differentiation is maintained. No evidence of calculi or hydronephrosis.

Retroperitoneum- Visualized aorta appeared normal. No obvious enlarged para-aortic nodes.

Urinary Bladder is well distended. Wall thickness is normal. No evidence of calculi, mass or mural lesion.

Uterus is anteverted and atrophic, measures 6.6 x 2.7 x 4.7 cms. **Endometrium** measures 3.6 mm.

Both ovaries are atrophic.

There is no ascites or pleural effusion. Appendix could not be localized. No RIF probe tenderness.

IMPRESSION:

- **Mild hepatomegaly with moderate fatty infiltration (Grade II).**
- **No other definite sonological abnormality detected.**



Dr. Elluru Santosh Kumar
Consultant Radiologist



NABH



NABL



No.1



**UNITED
HOSPITAL**

Care Par Excellence
Jayanagar, Bangalore

DEPARTMENT OF RADIODIAGNOSIS

Name	Gayatri	Date	13/01/24
Age	49 years	Hospital ID	UHJA23015385
Sex	Female	Ref.	Health check

RADIOGRAPH OF THE CHEST (PA – VIEW)

FINDINGS:

Bilateral lung fields are normal.

Bilateral costo-phrenic angles are normal.

Cardia and mediastinal contours are normal.

The bony thorax is grossly normal.

IMPRESSION:

- **No radiographic abnormality.**

Dr. Elluru Santosh Kumar
Consultant Radiologist

DEPARTMENT OF LABORATORY MEDICINE

Patient Name : Mrs. GAYATRI	Order No : 1000066219
UHID : UHJ A23015385	Registered On : 13/01/2024 08:44:00 AM
Age/Sex : 49/Years Female	Collected On : 13/01/2024 08:53:56 AM
Ward / Bed No :	Reported On : 13/01/2024 12:35:13 PM
Reference : Dr. Preventive Health Check Up	Bill No : OPBJ A230019362
Station : At Hospital	Mobile No : 9449313199
Payer Name : Mediwheel	Report Status : Final Report

Test Name	Result	Unit	Bio. Ref. Interval
<u>BIOCHEMISTRY</u>			
FASTING GLUCOSE (Method: Hexokinase)	94	mg/dL	ADA Guidelines < 100 mg/dl - Normal 100 to 125 mg/dl - Prediabetes ≥ 126 mg/dl - Diabetes
POST PRANDIAL GLUCOSE (Method: Hexokinase)	110	mg/dL	70-140
GLYCOSYLATED HAEMOGLOBIN (HBA1C)			Sample: Whole blood (EDTA)
HBA1C (Method: HPLC)	5.7	%	ADA Guidelines < 5.7% - Normal 5.7 to 6.4% - Prediabetes ≥ 6.5% - Diabetes
Estimated Average Glucose (eAG) (Method: Calculated)	116.89	mg/dL	
THYROID PROFILE (TOTAL T3, TOTAL T4 & TSH)			Sample: Serum
TOTAL T3 (Method: CLIA)	1.06	ng/mL	0.87-1.78
TOTAL T4 (Method: CLIA)	7.87	µg/dL	5.1-14.1
THYROID STIMULATING HORMONE (TSH) (Method: CLIA: Ultra-sensitive)	2.89	µIU/mL	0.34-5.60
LIPID PROFILE			Sample: Serum
TOTAL CHOLESTEROL (Method: CHOD-POD)	177	mg/dL	ATP III Guidelines < 200 - Desirable 200-239 - Borderline high ≥ 240 - High
TRIGLYCERIDES (Method: Enzymatic GPO-POD)	201	mg/dL	< 150 - Normal 150-199 - Borderline High 200-499 - High ≥ 500 - Very High
HDL CHOLESTEROL (Method: ENZYMATIC METHOD)	34.3	mg/dL	< 40 - Low ≥ 60 - High

DEPARTMENT OF LABORATORY MEDICINE

Patient Name	: Mrs. GAYATRI	Order No	: 1000066219
UHID	: UHJ A23015385	Registered On	: 13/01/2024 08:44:00 AM
Age/Sex	: 49/Years Female	Collected On	: 13/01/2024 08:53:56 AM
Ward / Bed No	:	Reported On	: 13/01/2024 12:35:13 PM
Reference	: Dr. Preventive Health Check Up	Bill No	: OPBJ A230019362
Station	: At Hospital	Mobile No	: 9449313199
Payer Name	: Mediwheel	Report Status	: Final Report

Test Name	Result	Unit	Bio. Ref. Interval
LDL CHOLESTEROL (Method: ENZYMATIC METHOD)	102.5	mg/dL	<100 - Optimal 100-129 - Near or above optimal 130-159 - Borderline high 160-189 - High ≥190 - Very high
VLDL CHOLESTEROL (Method: Calculated)	40.20	mg/dL	< 30
TOTAL CHOLESTEROL : HDL RATIO (Method: Calculated)	5.1		Low Risk: 3.3 - 4.4 Average Risk: 4.5 - 7.1 Moderate Risk: 7.2 - 11.0
LDL/HDL CHOLESTEROL RATIO (Method: Calculated)	2.9		< 2.5 Optimal
NON HDL CHOLESTEROL (Method: Calculated)	142.7	mg/dL	< 130
URIC ACID (Method: Uricase - POD(Enzymatic))	4.4	mg/dL	2.6-6.0
UREA/CREATININE RATIO	14.2		
LIVER FUNCTION TEST			Sample: Serum
TOTAL BILIRUBIN (Method: Dichlorophenyl Diazotization)	0.53	mg/dL	0.3-1.2
DIRECT BILIRUBIN (Method: Dichlorophenyl Diazotization)	0.10	mg/dL	0.0-0.2
INDIRECT BILIRUBIN (Method: Calculated)	0.44	mg/dL	0.2-1.0
TOTAL PROTEIN (Method: BIURET)	7.9	g/dL	6.6-8.3
ALBUMIN (Method: BCG)	4.11	g/dL	3.5-5.2
GLOBULIN (Method: Calculated)	3.79	g/dL	2.3-3.5
AG RATIO (Method: Calculated)	1.08		2:1

DEPARTMENT OF LABORATORY MEDICINE

Patient Name	: Mrs. GAYATRI	Order No	: 1000066219
UHID	: UHJ A23015385	Registered On	: 13/01/2024 08:44:00 AM
Age/Sex	: 49/Years Female	Collected On	: 13/01/2024 08:53:56 AM
Ward / Bed No	:	Reported On	: 13/01/2024 12:35:13 PM
Reference	: Dr. Preventive Health Check Up	Bill No	: OPBJ A230019362
Station	: At Hospital	Mobile No	: 9449313199
Payer Name	: Mediwheel	Report Status	: Final Report

Test Name	Result	Unit	Bio. Ref. Interval
SERUM SGOT (Method:IFCC without P5P)	16	U/L	< 35
SERUM SGPT (Method:IFCC without P5P)	19	U/L	< 35
ALKALINE PHOSPHATASE, SERUM (Method:PNPP AMP Buffer)	87	U/L	46-122
GGT (Method:IFCC)	17	U/L	< 38
UREA (Method:Urease GLDH - Kinetic)	9.1	mg/dL	17-43



Dr. Shanthakumar Muruda
Sr CONSULTANT BIOCHEMIST
KMC No : 54192

DEPARTMENT OF LABORATORY MEDICINE

Patient Name : Mrs. GAYATRI	Order No : 1000066219
UHID : UHJ A23015385	Registered On : 13/01/2024 08:44:00 AM
Age/Sex : 49/Years Female	Collected On : 13/01/2024 08:53:56 AM
Ward / Bed No :	Reported On : 13/01/2024 12:35:13 PM
Reference : Dr. Preventive Health Check Up	Bill No : OPBJ A230019362
Station : At Hospital	Mobile No : 9449313199
Payer Name : Mediwheel	Report Status : Final Report

Test Name	Result	Unit	Bio. Ref. Interval
-----------	--------	------	--------------------

HAEMATOLOGY

COMPLETE BLOOD COUNT(CBC)

Sample: Whole blood (EDTA)

HAEMOGLOBIN (Method:Photometric Measurement: Oxyhemoglobin method)	13.62	g/dL	12-16
PACKED CELL VOLUME/HEMATOCRIT (PCV/HCT) (Method: Calculated)	41.8	%	37-47
TOTAL WBC COUNT (TLC) (Method:Coulter Principle)	8940	Cells/Cum	4000-11000
DIFFERENTIAL COUNT			
NEUTROPHILS (Method:Optical/Impedance)	59.41	%	40-75
LYMPHOCYTES (Method:Optical/Impedance)	33.05	%	20-45
EOSINOPHILS (Method:Optical/Impedance)	1.21	%	0-6
MONOCYTES (Method:Optical/Impedance)	6.14	%	2-10
BASOPHILS (Method:Optical/Impedance)	0.19	%	0-2
RED BLOOD CORPUSCLES(RBC) (Method:Coulter Principle)	5.09	million/cum	4.0-5.2
MCV (Method:Derived from RBC Histogram)	82.1	fL	78-100
MCH (Method: Calculated)	26.8	pg	27-31
MCHC (Method: Calculated)	32.6	g/dL	31-37
RDW - CV (Method: Calculated)	14.7	%	11.5-14.5
PLATELET COUNT (Method:Electrical Impedance)	3.17	Lakhs/Cum	1.5-4.5

DEPARTMENT OF LABORATORY MEDICINE

Patient Name : Mrs. GAYATRI	Order No : 1000066219
UHID : UHJ A23015385	Registered On : 13/01/2024 08:44:00 AM
Age/Sex : 49/Years Female	Collected On : 13/01/2024 08:53:56 AM
Ward / Bed No :	Reported On : 13/01/2024 12:35:13 PM
Reference : Dr. Preventive Health Check Up	Bill No : OPBJ A230019362
Station : At Hospital	Mobile No : 9449313199
Payer Name : Mediwheel	Report Status : Final Report

Test Name	Result	Unit	Bio. Ref. Interval
MEAN PLATELET VOLUME(MPV) (Method:Derived from PLT Histogram)	7.10	fl	9-13
PLATELET DISTRIBUTION WIDTH (PDW) (Method: Calculated)	20.4	fl	9-19
ERYTHROCYTE SEDIMENTATION RATE(ESR) (Method:Modified Westergren Method)	14	mm/hour	1-20
BLOOD GROUPING & RH TYPING			Sample: Whole blood (EDTA)
ABO Group (Method:Agglutination Gel Method)	AB		
Rh Factor (Method:Agglutination Gel Method)	Positive		

Interpretation Notes

Note: Both forward and reverse grouping performed

Naveen N

Dr. Naveen Kumar
CONSULTANT PATHOLOGIST
KMC NO : 71418

DEPARTMENT OF LABORATORY MEDICINE

Patient Name	: Mrs. GAYATRI	Order No	: 1000066219
UHID	: UHJ A23015385	Registered On	: 13/01/2024 08:44:00 AM
Age/Sex	: 49/Years Female	Collected On	: 13/01/2024 08:53:56 AM
Ward / Bed No	:	Reported On	: 13/01/2024 12:35:13 PM
Reference	: Dr. Preventive Health Check Up	Bill No	: OPBJ A230019362
Station	: At Hospital	Mobile No	: 9449313199
Payer Name	: Mediwheel	Report Status	: Final Report

Test Name	Result	Unit	Bio. Ref. Interval
-----------	--------	------	--------------------

CLINICAL PATHOLOGY

URINE EXAMINATION, ROUTINE

Sample: Urine

PHYSICAL EXAMINATION

VOLUME	25	mL	
COLOUR	Pale Yellow		
APPEARANCE	Clear		
PH	5.0		5.0-8.0
SPECIFIC GRAVITY	1.020		1.005-1.030

CHEMICAL EXAMINATION

PROTEIN (Method:Protein Error of pH Indicator)	Absent		Absent
GLUCOSE (Method:GOD-POD)	Absent		Absent
KETONE BODIES (Method:Nitroprusside method/ Rothera's test)	Absent		Absent
BILIRUBIN (Method:DIAZO/FOUCHET'S TEST)	Negative		Negative
BILE SALT (Method:Hay's sulfur test)	Absent		Absent
NITRITE (Method:Griess method)	Negative		Negative
UROBILINOGEN (Method:Azo coupling method)	Normal		
LEUKOCYTE ESTERASE (Method:Leukocyte Esterase activity)	Negative		Negative
BLOOD (Method:Peroxidase Reaction)	Negative		Negative

MICROSCOPIC EXAMINATION

DEPARTMENT OF LABORATORY MEDICINE

Patient Name	: Mrs. GAYATRI	Order No	: 1000066219
UHID	: UHJ A23015385	Registered On	: 13/01/2024 08:44:00 AM
Age/Sex	: 49/Years Female	Collected On	: 13/01/2024 08:53:56 AM
Ward / Bed No	:	Reported On	: 13/01/2024 12:35:13 PM
Reference	: Dr. Preventive Health Check Up	Bill No	: OPBJ A230019362
Station	: At Hospital	Mobile No	: 9449313199
Payer Name	: Mediwheel	Report Status	: Final Report

Test Name	Result	Unit	Bio. Ref. Interval
EPITHELIAL CELLS	0-2	/HPF	0-5
PUS CELLS	0-2	/HPF	0-5
RBCs	Nil	/HPF	0-2
CASTS	Nil	/LPF	
CRYSTALS	Nil		
OTHERS	NIL		

URINE SUGAR, FASTING
(Method:GOD-POD)

Absent

Verified By
Parameshwar B

---End of Report---

Naveen M

Dr. Naveen Kumar
CONSULTANT PATHOLOGIST
KMC NO : 71418