



Moni
32/F

94/9/22

H comes for regular dental checkup

P/E → Stomach, Calent

Caries wise $\frac{87}{87} / \frac{8}{78}$, Sensitivity wise $\frac{75}{}$

Advice:- Scaling and Polishing.

Filling wise $\frac{87}{87} / \frac{8}{8}$

Rx

Shy was tooth paste
Shy OR mouth wash

→ → / x 15 days



(This is only professional opinion and not the diagnosis, Please correlate clinically)

Q Block South City 11, Sohna Road, Main Sector-47, Gurgaon, Haryana

Ph.: 0124-4900000 (100 Lines) Fax : 0124-2218733 E-mail : parkmedicenters@gmail.com

PARK GROUP OF HOSPITALS : West Delhi • South Delhi • Gurgaon • Karnal • Panipat • Hodal • Ambala • Behror

the **health** care providers

the **health** care providers






For medical check up

Vitals :

BP = 90/60
wt = 65.6 Kg
HT = 150 cm
PR 2 72-7

Chief Complaints :

Ear



H/O Present Illness :

Past History :

oral } - non
Non } - non

Investigation :

Drug Allergies : (if any)

Treatment

ASW
Pure Tone audiometry

24/9/22



24/9/2022

12pm

- white discharge.
- Itching perineum.] 6-7 month.
- H/O Brownish discharge after menses.

Vitals :

Chief Complaints :

LMP - 28/8/2022.

H/O Present Illness :

MH - 6-7 days (H) flow 3 days
22 ± 2 days rest spotting.

Past History :

OH - 1 FTUSC - 2013 - died after 4 days (boy).
2 FTUSC - 2016 - Boy - A&H.

Investigation :

Drug Allergies : (if any)

Past M/S/H - NAD.
Family H/O - Father - DM ⊕
Hypothyroidism.

Treatment :

GC - fair, Afebrile, conc, oriented.
P I O C L

Ps - slight serous discharge ⊕.

Pr - ut Av, (N) size.
B/L for free.

Pap smear taken

Pap's smear



Actu

TFT

CBC

FBS

PPBS

D₂ of menses

→ FSH
→ LH

- VSG pelvis gynae

Rx

Vaginal Tab Clingenfoorte -HS-PV.
- 6 days.

T. Doxycycline 100mg BD - 14 days
Cap Metrogyl 400mg BD - 7 days
T. pantop - OD - 14 day.
Lactifem Itch / Candid-CL-oint.
R/V c reports

Rajnik



DEPARTMENT OF PATHOLOGY

Patient Name : Mrs. MONI KUMARI
MR No : 662275
Age/Sex : 32 Years / Female
Type : OPD
TPA/Corporate : MEDIWHEEL PVT LTD

Bill Date : 24/09/2022 / 9.18 AM
Reporting Date : 24/09/2022
Sample ID : 45388
Bill/Req. No. : 22965428
Ref Doctor : Dr.RMO

Test	Result	Bio. Ref. Interval	Units	Method
BLOOD SUGAR FASTING				
PLASMA GLUCOSE FASTING	77	60 - 100	mg/dl	GOD TRINDERS

***** END OF THE REPORT *****



Dr.NALANDA BUKTARE
MD (Pathology)

Dr.PRADIP KUMAR
Consultant (Microbiology)

Dr.NISHA TIWARI
MBBS, MD (Microbiology)
USER NM AMIT

(This is only professional opinion and not the diagnosis. Please correlate clinically)

Q Block South City 11, Sohna Road, Main Sector-47, Gurgaon, Haryana
Ph.: 0124-4900000 (100 Lines) Fax : 0124-2218733 E-mail : parkmedicenters@gmail.com

PARK GROUP OF HOSPITALS : West Delhi • South Delhi • Gurgaon • Karnal • Panipat • Hodal • Ambala • Behror

the health care providers

the health care providers





DEPARTMENT OF PATHOLOGY

Patient Name : Mrs. MONI KUMARI
MR No : 662275
Age/Sex : 32 Years / Female
Type : OPD
TPA/Corporate : MEDIWHEEL PVT LTD

Bill Date : 24/09/2022 / 9.18 AM
Reporting Date : 24/09/2022
Sample ID : 45388
Bill/Req. No. : 22965428
Ref Doctor : Dr.RMO

Test	Result	Bio. Ref. Interval	Units	Method
BLOOD SUGAR 2 HR. PP				
BLOOD SUGAR P.P.	111	80 - 150	mg/dl	

***** END OF THE REPORT *****



Dr.NALANDA BUKTARE
MD (Pathology)

Dr.PRADIP KUMAR
Consultant (Microbiology)

Dr.NISHA TIWARI
MBBS, MD (Microbiology)
USER NM AMIT

(This is only professional opinion and not the diagnosis, Please correlate clinically)

Q Block South City 11, Sohna Road, Main Sector-47, Gurgaon, Haryana
Ph.: 0124-4900000 (100 Lines) Fax : 0124-2218733 E-mail : parkmedicenters@gmail.com

PARK GROUP OF HOSPITALS : West Delhi • South Delhi • Gurgaon • Karnal • Panipat • Hodal • Ambala • Behror

the **health** care providers

the **health** care providers





DEPARTMENT OF PATHOLOGY

Patient Name : Mrs. MONI KUMARI
MR No : 662275
Age/Sex : 32 Years / Female
Type : OPD
TPA/Corporate : MEDIWHEEL PVT LTD

Bill Date : 24/09/2022
Reporting Date : 25/09/2022
Sample ID : 45388
Bill/Req. No. : 22965428
Ref Doctor : Dr.RMO

Test	Result	Bio. Ref. Interval	Units
------	--------	--------------------	-------

URINE ROUTINE AND MICROSCOPY

PHYSICAL CHARACTERISTICS

QUANTITY	30ml	5 - 100	
COLOUR	Pale Yellow	Pale Yellow	
TURBIDITY	Clear		
SPECIFIC GRAVITY	1.020		
PH	6.0		

CHEMICAL EXAMINATION-1

UROBILINOGEN	NIL	NIL	
URINE PROTEIN	NIL		mg/dl
BLOOD	NIL		
TOTAL BILIRUBIN	NIL	0.1 - 1.2	mg/dL
GLUCOSE	NIL		mg/dL
URINE KETONE	Negative	Negative	

MICRO.EXAMINATION

PUS CELL	1-2/hpf	<1	
RED BLOOD CELLS	NIL	NIL	
EPITHELIAL CELLS	1-2/hpf	4-5/HPF	
CASTS	NIL	NIL	
CRYSTALS	NIL	NIL	

***** END OF THE REPORT *****



Sample no.



Dr.NALANDA BUKTARE
MD (Pathology)

Dr.PRADIP KUMAR
Consultant (Microbiology)

Dr.NISHA TIWARI
MBBS, MD (Microbiology)

USER NM AMIT

(This is only professional opinion and not the diagnosis, Please correlate clinically)

Q Block South City 11, Sohna Road, Main Sector-47, Gurgaon, Haryana

Ph.: 0124-4900000 (100 Lines) Fax : 0124-2218733 E-mail : parkmedicenters@gmail.com

PARK GROUP OF HOSPITALS : West Delhi • South Delhi • Gurgaon • Karnal • Panipat • Hodal • Ambala • Behror Page 1 of 1

the **health** care providers

the **health** care providers





DEPARTMENT OF PATHOLOGY

Patient Name : Mrs. MONI KUMARI
MR No : 662275
Age/Sex : 32 Years / Female
Type : OPD
TPA/Corporate : MEDIWHEEL PVT LTD

Bill Date : 24/09/2022
Reporting Date : 24/09/2022
Sample ID : 45388
Bill/Req. No. : 22965428
Ref Doctor : Dr.RMO

Test	Result	Bio. Ref. Interval	Units
BLOOD GROUPING AND RH FACTOR			
BLOOD GROUP	"AB" RH POSITIVE		

***** END OF THE REPORT *****



Sample no.

Dr.NALANDA BUKTARE
MD (Pathology)

Dr.PRADIP KUMAR
Consultant (Microbiology)

Dr.NISHA TIWARI
MBBS, MD (Microbiology)

USER NM AMIT



(This is only professional opinion and not the diagnosis, Please correlate clinically)

Q Block South City 11, Sohna Road, Main Sector-47, Gurgaon, Haryana

Ph.: 0124-4900000 (100 Lines) Fax: 0124-2218733 E-mail: parkmedicenters@gmail.com

PARK GROUP OF HOSPITALS : West Delhi • South Delhi • Gurgaon • Karnal • Panipat • Hodal • Ambala • Behror Page 1 of 1





DEPARTMENT OF PATHOLOGY

Patient Name : Mrs. MONI KUMARI
MR No : 662275
Age/Sex : 32 Years / Female
Type : OPD
TPA/Corporate : MEDIWHEEL PVT LTD

Bill Date : 24/09/2022 / 9.18 AM
Reporting Date : 24/09/2022
Sample ID : 45388
Bill/Req. No. : 22965428
Ref Doctor : Dr.RMO

Test	Result	Bio. Ref. Interval	Units	Method
CBC				
HAEMOGLOBIN	9.6 L	12 - 15	gm/dL	COLORIMETRY
TOTAL LEUCOCYTE COUNT	5600	4000 - 10000	/ μ L	ELECTRICAL IMPEDANCE
DIFFERENTIAL COUNT				
NEUTROPHILS	52	40.0 - 80.0	%	FLOW CYTOMETRY
LYMPHOCYTES	40	20.0 - 40.0	%	FLOW CYTOMETRY
MONOCYTES	06	2.0 - 10.0	%	FLOW CYTOMETRY
EOSINOPHILS	02	0.0 - 5.0	%	FLOW CYTOMETRY
BASOPHILS	00	0.0 - 2.0	%	FLOW CYTOMETRY
RED BLOOD CELL COUNT	3.7	3.5 - 5.5	millions/ μ L	ELECTRICAL IMPEDANCE
PACKED CELL VOLUME	28.8 L	35.0 - 50.0	%	ELECTRICAL IMPEDANCE
MEAN CORPUSCULAR VOLUME	77.3 L	83 - 101	fL	ELECTRICAL IMPEDANCE
MEAN CORPUSCULAR HAEMOGLOBIN	25.7 L	27 - 31	Picogrammes	CALCULATED
MEAN CORPUSCULAR HB CONC	33.3	33 - 37	g/dl	CALCULATED
PLATELET COUNT	270	150 - 450	thou/ μ L	ELECTRICAL IMPEDANCE
RDW	17.6 H	11.6 - 14.5	%	CALCULATED

***** END OF THE REPORT *****

Dr.NALANDA BUKTARE
MD (Pathology)

Dr.PRADIP KUMAR
Consultant (Microbiology)

Dr.NISHA TIWARI
MBBS, MD (Microbiology)
USER NM AMIT



(This is only professional opinion and not the diagnosis, Please correlate clinically)

Q Block South City 11, Sohna Road, Main Sector-47, Gurgaon, Haryana
Ph.: 0124-4900000 (100 Lines) Fax : 0124-2218733 E-mail : parkmedicenters@gmail.com

PARK GROUP OF HOSPITALS : West Delhi • South Delhi • Gurgaon • Karnal • Panipat • Hodal • Ambala • Behror

the health care providers

the health care providers





DEPARTMENT OF PATHOLOGY

Patient Name : Mrs. MONI KUMARI
 MR No : 662275 Bill Date : 24/09/2022
 Age/Sex : 32 Years / Female Reporting Date : 24/09/2022
 Type : OPD Sample ID : 45388
 TPA/Corporate : MEDIWHEEL PVT LTD Bill/Req. No. : 22965428
 Ref Doctor : Dr.RMO

Test	Result	Bio. Ref. Interval	Units
ESR (WESTERGREN)			
E.S.R.	25 H	0 - 15	mm at the end of 1st hr

***** END OF THE REPORT *****



Sample no.



Dr.NALANDA BUKTARE
MD (Pathology)

Dr.PRADIP KUMAR
Consultant (Microbiology)

Dr.NISHA TIWARI
MBBS, MD (Microbiology)
USER NM AMIT

(This is only professional opinion and not the diagnosis, Please correlate clinically)

Q Block South City 11, Sohna Road, Main Sector-47, Gurgaon, Haryana
 Ph.: 0124-4900000 (100 Lines) Fax : 0124-2218733 E-mail : parkmedicenters@gmail.com

PARK GROUP OF HOSPITALS : West Delhi • South Delhi • Gurgaon • Karnal • Panipat • Hodal • Ambala • Behror

the **health** care providers

the **health** care providers





DEPARTMENT OF PATHOLOGY

Patient Name : Mrs. MONI KUMARI
MR No : 662275
Age/Sex : 32 Years / Female
Type : OPD
TPA/Corporate : MEDIWHEEL PVT LTD

Bill Date : 24/09/2022
Reporting Date : 26/09/2022
Sample ID : 45388
Bill/Req. No. : 22965428
Ref Doctor : Dr.RMO

Test	Result	Bio. Ref. Interval	Units
------	--------	--------------------	-------

URINE C/S

NAME OF SPECIMEN	URINE
ORGANISM IDENTIFIED	NO GROWTH SEEN IN CULTURE AFTER 48HRS OF INCUBATION AT 37 C DEGREE.

***** END OF THE REPORT *****



Sample no.



Dr.NALANDA BUKTARE
MD (Pathology)

Dr.PRADIP KUMAR
Consultant (Microbiology)

Dr.NISHA TIWARI
MBBS, MD (Microbiology)

USER NM MOHIPA159

(This is only professional opinion and not the diagnosis, Please correlate clinically)

Q Block South City 11, Sohna Road, Main Sector-47, Gurgaon, Haryana

Ph.: 0124-4900000 (100 Lines) Fax : 0124-2218733 E-mail : parkmedicenters@gmail.com

Page 1 of 1

PARK GROUP OF HOSPITALS : West Delhi • South Delhi • Gurgaon • Karnal • Panipat • Hodal • Ambala • Behror

the **health** care providers

the **health** care providers





DEPARTMENT OF PATHOLOGY

Patient Name : Mrs. MONI KUMARI
 MR No : 662275
 Age/Sex : 32 Years / Female
 Type : OPD
 TPA/Corporate : MEDIWHEEL PVT LTD

Bill Date : 24/09/2022 / 9.18 AM
 Reporting Date : 25/09/2022
 Sample ID : 45388
 Bill/Req. No. : 22965428
 Ref Doctor : Dr.RMO

Test	Result	Bio. Ref. Interval	Units	Method
THYROID PROFILIE				
TRI-IODOTHYRONINE (T3)	1.04	0.60 - 1.81	ng/ml	Chemiluminescence
THYROXINE (T4)	9.5	5.01 - 12.45	µg/dL	Chemiluminescence
THYROID STIMULATING HORMONE (TSH)	1.47	0.5-5.50	µIU/ml	
SPECIMEN TYPE	SERUM			

Method : chemiluminescent immunoassay

Note : Clinical Significance:

Thyroid function tests (TFTs) is a collective term for blood tests used to check the function of the thyroid. TFTs may be requested if a patient is thought to suffer from hyperthyroidism (overactive thyroid) or hypothyroidism (underactive thyroid), or to monitor the effectiveness of either thyroid-suppression or hormone replacement therapy. It is also requested routinely in conditions linked to thyroid disease, such as atrial fibrillation and anxiety disorder. A TFT panel typically includes thyroid hormones such as thyroid-stimulating hormone (TSH, thyrotropin) and thyroxine (T4), and triiodothyronine (T3) depending on local laboratory policy.

Note: Please correlate with clinical condition

***** END OF THE REPORT *****



Dr. NALANDA BUKTARE
 MD (Pathology)

Dr. PRADIP KUMAR
 Consultant (Microbiology)

Dr. NISHA TIWARI
 MBBS, MD (Microbiology)
 USER NM DINESH

(This is only professional opinion and not the diagnosis. Please correlate clinically)

Q Block South City 11, Sohna Road, Main Sector-47, Gurgaon, Haryana
 Ph.: 0124-4900000 (100 Lines) Fax : 0124-2218733 E-mail : parkmedicenters@gmail.com

PARK GROUP OF HOSPITALS : West Delhi • South Delhi • Gurgaon • Karnal • Panipat • Hodal • Ambala • Behror

the **health** care providers

the **health** care providers



Park Hospital

GROUP SUPER SPECIALITY HOSPITAL



DEPARTMENT OF PATHOLOGY

Patient Name : Mrs. MONI KUMARI
 MR No : 662275
 Age/Sex : 32 Years / Female
 Type : OPD
 TPA/Corporate : MEDIWHEEL PVT LTD

Bill Date : 24/09/2022 / 9.18 AM
 Reporting Date : 24/09/2022
 Sample ID : 45388
 Bill/Req. No. : 22965428
 Ref Doctor : Dr.RMO

Test	Result	Bio. Ref. Interval	Units	Method
LFT (LIVER FUNCTION TEST)				
LFT				DIAZO
TOTAL BILIRUBIN	1.2	0.1 - 1.2	mg/dL	DIAZO
DIRECT BILIRUBIN	0.6 <i>H</i>	0 - 0.4	mg/dL	CALCULATED
INDIRECT BILIRUBIN	0.6	0.10 - 0.6	mg/dL	CALCULATED
SGOT (AST)	21	0 - 45	U/L	IFCC WITHOUT PYRIDOXAL PHOSPHATE
SGPT (ALT)	13	0 - 45	U/L	IFCC WITHOUT PYRIDOXAL PHOSPHATE
ALKALINE PHOSPHATASE	70	30 - 170	IU/L	MODIFIED IFCC
TOTAL PROTEINS	6.7	6.4 - 8.0	g/dL	BIURET
ALBUMIN	4.0	3.3 - 5.5	g/dL	BCG DYE
GLOBULIN	2.7	2.3 - 4.5	g/dL	CALCULATED
A/G RATIO	1.48	1.1 - 2.2		CALCULATED

***** END OF THE REPORT *****



Dr.NALANDA BUKTARE
 MD (Pathology)

Dr.PRADIP KUMAR
 Consultant (Microbiology)

Dr.NISHA TIWARI
 MBBS, MD (Microbiology)
 USER NM AMIT

(This is only professional opinion and not the diagnosis, Please correlate clinically)

Q Block South City 11, Sohna Road, Main Sector-47, Gurgaon, Haryana
 Ph.: 0124-4900000 (100 Lines) Fax : 0124-2218733 E-mail : parkmedicenters@gmail.com

PARK GROUP OF HOSPITALS : West Delhi • South Delhi • Gurgaon • Karnal • Panipat • Hodal • Ambala • Behror

the **health** care providers

the **health** care providers



Scanned with OKEN Scanner



DEPARTMENT OF PATHOLOGY

Patient Name : Mrs. MONI KUMARI
 MR No : 662275
 Age/Sex : 32 Years / Female
 Type : OPD
 TPA/Corporate : MEDIWHEEL PVT LTD

Bill Date : 24/09/2022 / 9.18 AM
 Reporting Date : 24/09/2022
 Sample ID : 45388
 Bill/Req. No. : 22965428
 Ref Doctor : Dr.RMO

Test	Result	Bio. Ref. Interval	Units	Method
LIPID PROFILE				
LIPID PROFILE				
TOTAL CHOLESTEROL	144	0 - 250	mg/dL	CHOD -Trinder
SERUM TRIGLYCERIDES	100	60 - 165	mg/dl	GPO-TRINDER
HDL-CHOLESTEROL	49	30 - 70	mg/dl	DIRECT
VLDL CHOLESTEROL	20	6 - 32	mg/dL	calculated
LDL	75	50 - 135	mg/dl	calculated
LDL CHOLESTEROL/HDL RATIO	1.5	1.0 - 3.0	mg/dL	calculated
TOTAL CHOLESTEROL/HDL RATIO	2.9	2.0 - 5.0	mg/dl	calculated

***** END OF THE REPORT *****



Dr.NALANDA BUKTARE
 MD (Pathology)

Dr.PRADIP KUMAR
 Consultant (Microbiology)

Dr.NISHA TIWARI
 MBBS, MD (Microbiology)
 USER NM AMIT

(This is only professional opinion and not the diagnosis, Please correlate clinically)

Q Block South City 11, Sohna Road, Main Sector-47, Gurgaon, Haryana
 Ph.: 0124-4900000 (100 Lines) Fax : 0124-2218733 E-mail : parkmedicenters@gmail.com

PARK GROUP OF HOSPITALS : West Delhi • South Delhi • Gurgaon • Karnal • Panipat • Hodal • Ambala • Behror

the **health** care providers

the **health** care providers





DEPARTMENT OF PATHOLOGY

Patient Name : Mrs. MONI KUMARI
MR No : 662275
Age/Sex : 32 Years / Female
Type : OPD
TPA/Corporate : MEDIWHEEL PVT LTD

Bill Date : 24/09/2022 / 9.18 AM
Reporting Date : 24/09/2022
Sample ID : 45388
Bill/Req. No. : 22965428
Ref Doctor : Dr.RMO

Test	Result	Bio. Ref. Interval	Units	Method
KFT (RENAL PROFILE)				
KFT				
SERUM UREA	12	10 - 45	mg/dL	UREASE-GLDH
SERUM CREATININE	0.9	0.4 - 1.4	mg/dL	MODIFIED JAFFES
SERUM URIC ACID	3.9	2.5 - 7.0	mg/dL	URICASE
SERUM SODIUM	146 H	136 - 145	meq/l	ISE
SERUM POTASSIUM	4.3	3.5 - 5.5	meq/l	ISE
SERUM CALCIUM	8.6	8.5 - 10.5	mg/dL	ARSENazo III
SERUM PHOSPHORUS	2.7	2.5 - 4.5	mg/dL	AMMONIUM MOLYBDATE

***** END OF THE REPORT *****



Dr.NALANDA BUKTARE
MD (Pathology)

Dr.PRADIP KUMAR
Consultant (Microbiology)

Dr.NISHA TIWARI
MBBS, MD (Microbiology)

USER NM AMIT

(This is only professional opinion and not the diagnosis, Please correlate clinically)

Q Block South City 11, Sohna Road, Main Sector-47, Gurgaon, Haryana
Ph.: 0124-4900000 (100 Lines) Fax : 0124-2218733 E-mail : parkmedicenters@gmail.com

PARK GROUP OF HOSPITALS : West Delhi • South Delhi • Gurgaon • Karnal • Panipat • Hodal • Ambala • Behror

the **health** care providers

the **health** care providers





DEPARTMENT OF RADIOLOGY

Patient Name	Mrs. MONI KUMARI	Billed Date	: 24/09/2022	9.18 AM
Reg No	662275	Reported Date	: 24/09/2022	
Age/Sex	32 Years / Female	Req. No.	: 22965428	
Type	OPD	Consultant Doctor	: Dr. RMO	

USG WHOLE ABDOMEN

The real time, B mode, gray scale sonography of the abdominal organs was performed.

LIVER : The liver is normal in size 15.0cm with fatty infiltration. No evidence of any focal lesion. IHBR is not dilated.

GALL BLADDER : The gall bladder is well distended . No evidence any calculus or mass seen.

GB wall thickness with in normal limits.No evidence of pericholecystic fluid is seen.

BILE DUCT :The common bile duct is normal in caliber. No evidence of calculus is noted in common bile duct.

SPLEEN :The spleen is normal in size 8.9cm and shape.Its echotexture is homogeneous.No evidence of focal lesion is noted.

PANCREAS :The pancreas is normal in size, shape, contours and echotexture.No evidence of solid or cystic mass lesion is noted.MPD is not dilated. No evidence of peripancreatic collection.

KIDNEYSR:K:9.4x4.6cm.

LK:8.8x4.5cm.

The bilateral kidneys are normal in size and echotexture. Cortico-medullary differentiation is maintained.There is no evidence of obvious calculus or hydronephrosis.

URINARY BLADDER :The urinary bladder is well distended.It shows uniformly thin walls and sharp mucosa.No evidence of calculus is seen. No evidence of mass or diverticulum is noted.

UTERUS: The uterus is anteverted. It measures 5.8x4.9x4.3 cms. in the longitudinal, anteroposterior and transverse dimensions respectivelyThe uterine margins is smooth and does not reveal any contour abnormalities.

The uterine myometrium shows homogeneous echotexture.

No evidence of leiomyoma is noted. No solid or cystic mass lesion is noted.

The endometrial echo is in the midline and measures 5.3mm.

The ovaries on the either side show normal echotexture.

No adnexal mass is seen.No cyst is seen in ovaries.

No evidence of ascites or interbowel free fluid is seen.

No evidence of obvious retroperitoneal or mesentric lymphadenopathy is seen.

IMPRESSION- Fatty liver grade-I

To be correlated clinically.

Dr. ANSHU K. SHARMA
MBBS, MD
CONSULTANT RADIOLOGIST

Dr. MANJEET SEHRAWAT
MBBS, MD, PDCC
CONSULTANT RADIOLOGIST

Dr. NEENA SIKKA
MBBS, DNB
CONSULTANT RADIOLOGIST



(This is only professional opinion and not the diagnosis, Please correlate clinically)

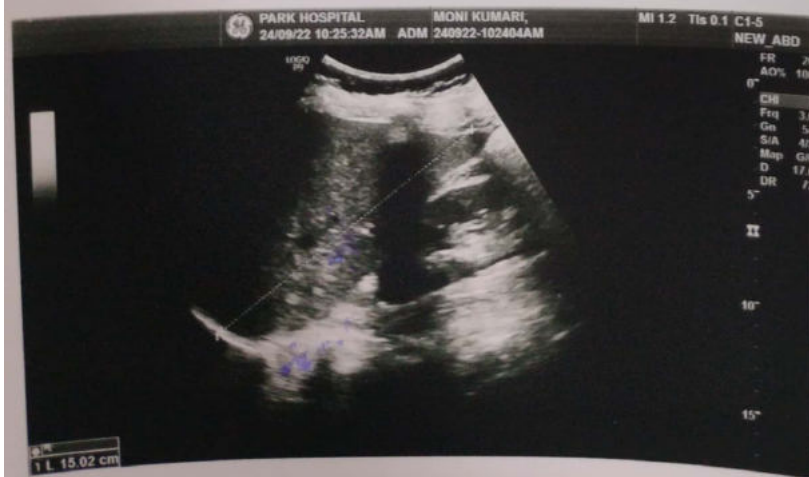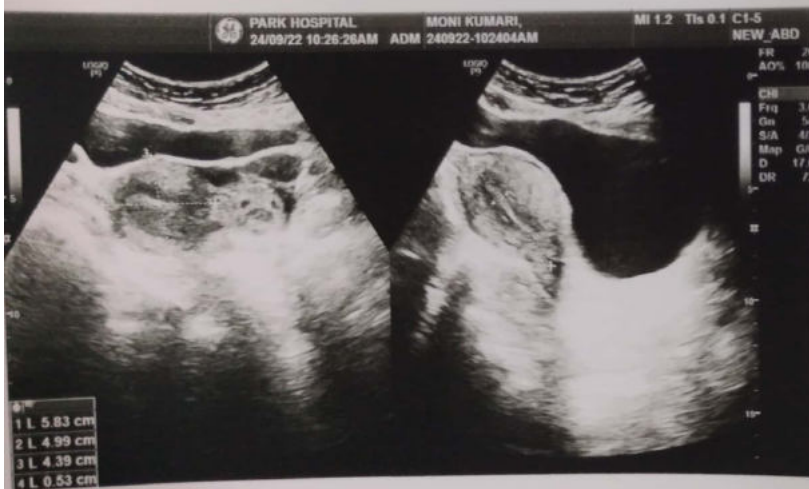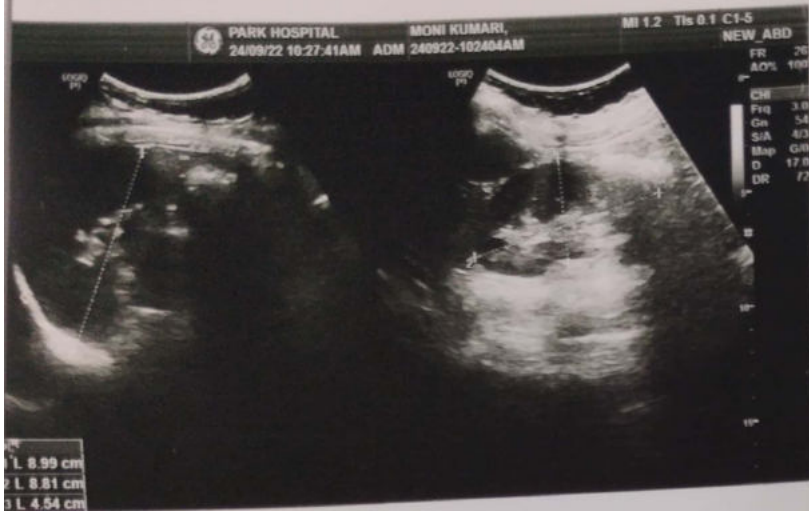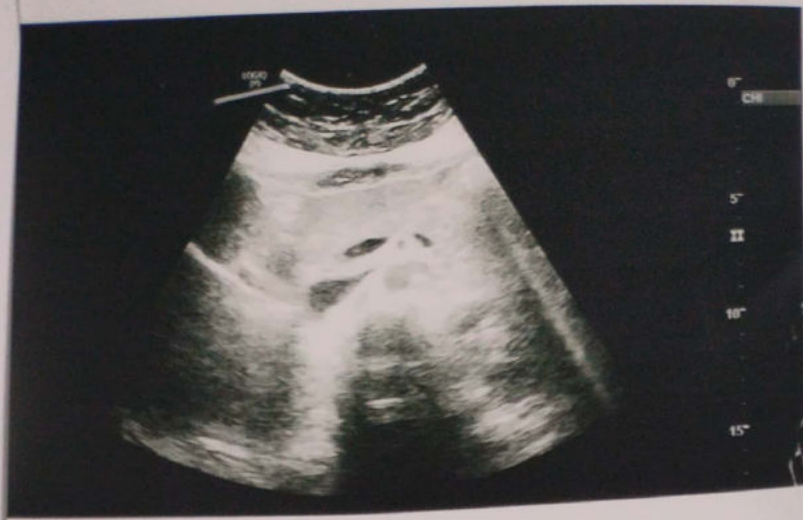Q Block South City 11, Sohna Road, Main Sector-47, Gurgaon, Haryana

Ph.: 0124-4900000 (100 Lines) Fax : 0124-2218733 E-mail : parkmedicenters@gmail.com

PARK GROUP OF HOSPITALS : West Delhi • South Delhi • Gurgaon • Karnal • Panipat • Hodal • Ambala • Behror

the health care providers

the health care providers





DEPARTMENT OF RADIOLOGY

Cert. No. MC - 4830 Cert. No. H-2015-0369

Patient Name	Mrs. MONI KUMARI	Billed Date	24/09/2022	9 18 AM
Reg No	662275	Reported Date	24/09/2022	
Age/Sex	32 Years / Female	Req. No.	22965428	
Type	OPD	Consultant Doctor	Dr. RMO	

X-RAY CHEST AP/PA

X-RAY CHEST P.A. VIEW

Bilateral lungs appears normal.

No focal lung lesion seen.

No evidence of free fluid is seen.


Both hila are normal in size, have equal density and bear normal relationship.

The heart and trachea are central in position and no mediastinal abnormality is visible.

The cardiac size is normal for patient age and view.

The domes of the diaphragms are normal in position, and show smooth outline.

To be correlated clinically


Dr. ANSHU K. SHARMA
MBBS, MD
CONSULTANT RADIOLOGIST

Dr. MANJEET SEHRAWAT
MBBS, MD, PDCC
CONSULTANT RADIOLOGIST



Dr. NEENA SIKKA
MBBS, DNB
CONSULTANT RADIOLOGIST

(This is only professional opinion and not the diagnosis, Please correlate clinically)

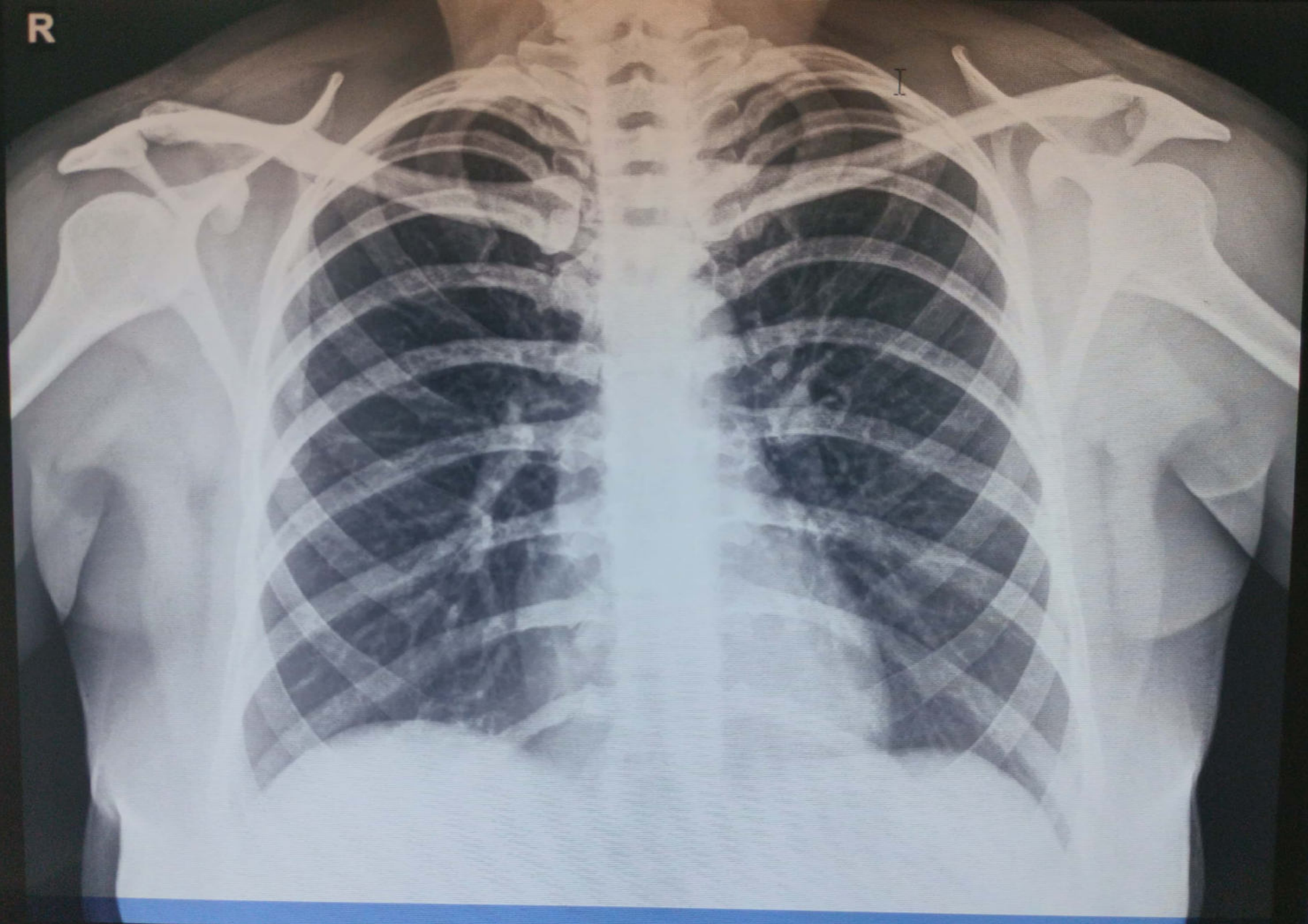
Q Block South City 11, Sohna Road, Main Sector-47, Gurgaon, Haryana
Ph.: 0124-4900000 (100 Lines) Fax : 0124-2218733 E-mail : parkmedicenters@gmail.com

PARK GROUP OF HOSPITALS : West Delhi • South Delhi • Gurgaon • Karnal • Panipat • Hodal • Ambala • Behror

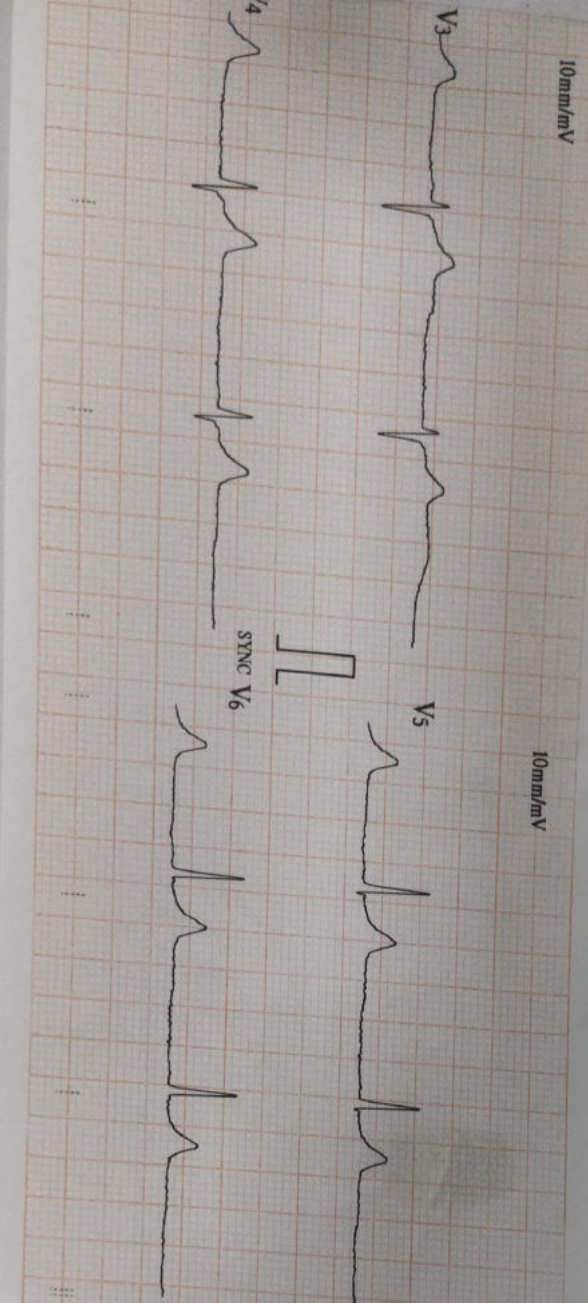
the **health** care providers

the **health** care providers

R



MONI KUMARI 32Y REQ-22965428 F 9/24/2022 10:15 AM
PARK HOSPITAL, SOUTH CITY II, GURGAON, HARYANA



ID : 0001

Name: _____

Sex : _____

Age : _____

Unconfirmed report Verified by: _____

HR	: 56	bpm
R-R	: 1066	ms
P-R	:	ms
QRS	: 81	ms
QT/QTc	: 384/371	ms
P/QRS/T	: /62/45	°
RV5/SV1	: 0.850/0.430	mV
RV5/SV1	: 1.280	mV

----- Supraventricular BradyCardia
 ----- Low Voltage (Chest Leads)

