



**DEPARTMENT OF PATHOLOGY**

Patient Name : Mr. NITIN GARG  
MR No : 656731  
Age/Sex : 35 Years / Male  
Type : OPD  
TPA/Corporate : MEDIWHEEL PVT LTD

Bill Date : 23/07/2022  
Reporting Date : 23/07/2022  
Sample ID : 21491  
Bill/Req. No. : 22931445  
Ref Doctor : Dr.RMO

Test	Result	Bio. Ref. Interval	Units
<b>BLOOD SUGAR FASTING</b>			
PLASMA GLUCOSE FASTING	118 H	60 - 100	mg/dl

\*\*\*\*\* END OF THE REPORT \*\*\*\*\*



Sample no.

Dr.NALANDA BUKTARE  
MD (Pathology)

Dr.PRADIP KUMAR  
Consultant (Microbiology)

Dr.BHAVANA CHAUHAN  
MBBS, MD (Microbiology)

USER NM NEERAJPA752

(This is only professional opinion and not the diagnosis, Please correlate clinically)

Q Block South City 11, Sohna Road, Main Sector-47, Gurgaon, Haryana  
Ph.: 0124-4900000 (100 Lines) Fax : 0124-2218733 E-mail : parkmedicenters@gmail.com

**PARK GROUP OF HOSPITALS : West Delhi • South Delhi • Gurgaon • Karnal • Panipat • Hodal • Ambala • Behror**

the **health** care providers

the **health** care providers





Cert. No. MC - 4830



Cert. No. H-2016-0369


**DEPARTMENT OF PATHOLOGY**

Patient Name : Mr. NITIN GARG  
MR No : 656731  
Age/Sex : 35 Years / Male  
Type : OPD  
TPA/Corporate : MEDIWHEEL PVT LTD

Bill Date : 23/07/2022  
Reporting Date : 23/07/2022  
Sample ID : 21491  
Bill/Req. No. : 22931445  
Ref Doctor : Dr.RMO

Test	Result	Bio. Ref. Interval	Units
<b>BLOOD SUGAR 2 HR. PP</b>			
BLOOD SUGAR P.P.	129	80 - 150	mg/dl

\*\*\*\*\* END OF THE REPORT \*\*\*\*\*



Sample no.

Dr.NALANDA BUKTARE  
MD (Pathology)

Dr.PRADIP KUMAR  
Consultant (Microbiology)

Dr.NISHA TIWARI  
MBBS, MD (Microbiology)

USER NM SHOIBPA166

(This is only professional opinion and not the diagnosis, Please correlate clinically)

Q Block South City 11, Sohna Road, Main Sector-47, Gurgaon, Haryana  
Ph.: 0124-4900000 (100 Lines) Fax : 0124-2218733 E-mail : parkmedicenters@gmail.com

**PARK GROUP OF HOSPITALS : West Delhi • South Delhi • Gurgaon • Karnal • Panipat • Hodal • Ambala • Behror**







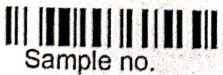**DEPARTMENT OF PATHOLOGY**

Patient Name : Mr. NITIN GARG  
MR No : 656731  
Age/Sex : 35 Years / Male  
Type : OPD  
TPA/Corporate : MEDIWHEEL PVT LTD

Bill Date : 23/07/2022  
Reporting Date : 23/07/2022  
Sample ID : 21491  
Bill/Req. No. : 22931445  
Ref Doctor : Dr.RMO

Test	Result	Bio. Ref. Interval	Units
<b>LIPID PROFILE</b>			
<b>LIPID PROFILE</b>			
TOTAL CHOLESTEROL	181	0 - 200	mg/dL
SERUM TRIGLYCERIDES	<b>169</b> H	60 - 165	mg/dl
HDL-CHOLESTEROL	42	30 - 70	mg/dl
VLDL CHOLESTEROL	<b>33</b> H	6 - 32	mg/dL
LDL	106	50 - 135	mg/dl
LDL CHOLESTEROL/HDL RATIO	2.5	1.0 - 3.0	mg/dL
TOTAL CHOLESTEROL/HDL RATIO	4.3	2.0 - 5.0	mg/dl

\*\*\*\*\* END OF THE REPORT \*\*\*\*\*



Sample no.

Dr.NALANDA BUKTARE  
MD (Pathology)

Dr.PRADIP KUMAR  
Consultant (Microbiology)

Dr.BHAVANA CHAUHAN  
MBBS, MD (Microbiology)

USER NM, SHO AIBPA166

(This is only professional opinion and not the diagnosis, Please correlate clinically)

Q Block South City 11, Sohna Road, Main Sector-47, Gurgaon, Haryana  
Ph.: 0124-4900000 (100 Lines) Fax : 0124-2218733 E-mail : parkmedicenters@gmail.com

**PARK GROUP OF HOSPITALS : West Delhi • South Delhi • Gurgaon • Karnal • Panipat • Hodal • Ambala • Behror**





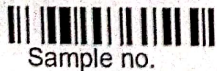**DEPARTMENT OF PATHOLOGY**

Patient Name : Mr. NITIN GARG  
MR No : 656731  
Age/Sex : 35 Years / Male  
Type : OPD  
TPA/Corporate : MEDIWHEEL PVT LTD

Bill Date : 23/07/2022  
Reporting Date : 23/07/2022  
Sample ID : 21491  
Bill/Req. No. : 22931445  
Ref Doctor : Dr.RMO

Test	Result	Bio. Ref. Interval	Units
<b>KFT (RENAL PROFILE)</b>			
<b>KFT</b>			
SERUM UREA	30	10 - 45	mg/dL
SERUM CREATININE	<b>2.1</b> <i>H</i>	0.4 - 1.4	mg/dL
SERUM URIC ACID	5.1	2.5 - 7.0	mg/dL
SERUM SODIUM	143	136 - 145	meq/l
SERUM POTASSIUM	4.5	3.5 - 5.5	meq/l
SERUM CALCIUM	9.1	8.5 - 10.5	mg/dL
SERUM PHOSPHORUS	3.1	2.5 - 4.5	mg/dL

\*\*\*\*\* END OF THE REPORT \*\*\*\*\*



Sample no.

Dr.NALANDA BUKTARE  
MD (Pathology)

Dr.PRADIP KUMAR  
Consultant (Microbiology)

Dr.BHAVANA CHAUHAN  
MBBS, MD (Microbiology)

USER NM SHOAIBPA166

(This is only professional opinion and not the diagnosis, Please correlate clinically)

Q Block South City 11, Sohna Road, Main Sector-47, Gurgaon, Haryana  
Ph.: 0124-4900000 (100 Lines) Fax : 0124-2218733 E-mail : parkmedicenters@gmail.com

**PARK GROUP OF HOSPITALS : West Delhi • South Delhi • Gurgaon • Karnal • Panipat • Hodal • Ambala • Behror**







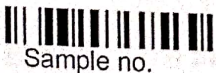**DEPARTMENT OF PATHOLOGY**

Patient Name : Mr. NITIN GARG  
MR No : 656731  
Age/Sex : 35 Years / Male  
Type : OPD  
TPA/Corporate : MEDIWHEEL PVT LTD

Bill Date : 23/07/2022  
Reporting Date : 23/07/2022  
Sample ID : 21491  
Bill/Req. No. : 22931445  
Ref Doctor : Dr.RMO

Test	Result	Bio. Ref. Interval	Units
<b>STOOL ROUTINE AND MICROSCOPY</b>			
<b>STOOL ROUTINE AND MICROSCOPY</b>			
COLOUR	Pale Yellow	Pale Yellow	
CONSISTENCY	Semi Solid	Formed	
BLOOD	NIL	NIL	
MUCUS	NIL	NIL	
PUS CELL	1-2/hpf	2---3/HPF	
RBCS	NIL	NIL	
CYSTS/OVA	NIL	NIL	

\*\*\*\*\* END OF THE REPORT \*\*\*\*\*



Sample no.

Dr.NALANDA BUKTARE  
MD (Pathology)

Dr.PRADIP KUMAR  
Consultant (Microbiology)

Dr.NISHA TIWARI  
MBBS, MD (Microbiology)

USER NM NEERAJPA752

(This is only professional opinion and not the diagnosis, Please correlate clinically)

Q Block South City 11, Sohna Road, Main Sector-47, Gurgaon, Haryana  
Ph.: 0124-4900000 (100 Lines) Fax : 0124-2218733 E-mail : parkmedicenters@gmail.com

**PARK GROUP OF HOSPITALS : West Delhi • South Delhi • Gurgaon • Karnal • Panipat • Hodal • Ambala • Behror**





**DEPARTMENT OF PATHOLOGY**

Patient Name : Mr. NITIN GARG  
MR No : 656731  
Age/Sex : 35 Years / Male  
Type : OPD  
TPA/Corporate : MEDIWHEEL PVT LTD

Bill Date : 23/07/2022  
Reporting Date : 23/07/2022  
Sample ID : 21491  
Bill/Req. No. : 22931445  
Ref Doctor : Dr.RMO

Test	Result	Bio. Ref. Interval	Units
------	--------	--------------------	-------

**URINE ROUTINE AND MICROSCOPY**

**PHYSICAL CHARACTERISTICS**

QUANTITY	30ml	5 - 100	
COLOUR	Pale Yellow	Pale Yellow	
TURBIDITY	Clear		
SPECIFIC GRAVITY	1.025		
PH	6.0		

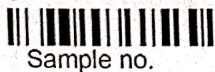**CHEMICAL EXAMINATION-1**

UROBILINOGEN	NIL	NIL	
URINE PROTEIN	NIL		mg/dl
BLOOD	NIL		
TOTAL BILIRUBIN	NIL	0.1 - 1.2	mg/dL
GLUCOSE	NIL		mg/dL
URINE KETONE	Negative	Negative	

**MICRO.EXAMINATION**

PUS CELLS	4-5/hpf	NIL	
RED BLOOD CELLS	NIL	NIL	
EPITHELIAL CELLS	2-3/hpf	4---5/HPF	
CASTS	NIL	NIL	
CRYSTALS	NIL	NIL	

\*\*\*\*\* END OF THE REPORT \*\*\*\*\*



Sample no.

Dr.NALANDA BUKTARE  
MD (Pathology)

Dr.PRADIP KUMAR  
Consultant (Microbiology)

Dr.BHAVANA CHAUHAN  
MBBS, MD (Microbiology)

USER NM NEERAJPA752

(This is only professional opinion and not the diagnosis, Please correlate clinically)

Q Block South City 11, Sohna Road, Main Sector-47, Gurgaon, Haryana  
Ph.: 0124-4900000 (100 Lines) Fax : 0124-2218733 E-mail : parkmedicenters@gmail.com

**PARK GROUP OF HOSPITALS : West Delhi • South Delhi • Gurgaon • Karnal • Panipat • Hodal • Ambala • Behror**

the **health** care providers

the **health** care providers







**DEPARTMENT OF PATHOLOGY**

Patient Name : Mr. NITIN GARG

MR No : 656731

Age/Sex : 35 Years / Male

Type : OPD

TPA/Corporate : MEDIWHEEL PVT LTD

Bill Date : 23/07/2022

Reporting Date : 23/07/2022

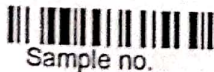Sample ID : 21491

Bill/Req. No. : 22931445

Ref Doctor : Dr.RMO

Test	Result	Bio. Ref. Interval	Units
<b>LFT (LIVER FUNCTION TEST)</b>			
LFT			
TOTAL BILIRUBIN	0.5	0.1 - 1.2	mg/dL
DIRECT BILIRUBIN	0.2	0 - 0.4	mg/dL
INDIRECT BILIRUBIN	0.3	0.10 - 0.6	mg/dL
SGOT (AST)	36	0 - 45	U/L
SGPT (ALT)	46	0 - 45	U/L
ALKALINE PHOSPHATASE	169	30 - 170	IU/L
TOTAL PROTEINS	7.4	6.4 - 8.0	g/dL
ALBUMIN	4.6	3.3 - 5.5	g/dL
GLOBULIN	2.8	2.3 - 4.5	g/dL
A/G RATIO	1.64	0 - 16.5	pg/ml

\*\*\*\*\* END OF THE REPORT \*\*\*\*\*



Sample no.

Dr.NALANDA BUKTARE  
MD (Pathology)

Dr.PRADIP KUMAR  
Consultant (Microbiology)

Dr.BHAVANA CHAUHAN  
MBBS, MD (Microbiology)

(This is only professional opinion and not the diagnosis, Please correlate clinically) USER:NM\_SHO AIBPA 166

Q Block South City 11, Sohna Road, Main Sector-47, Gurgaon, Haryana  
Ph.: 0124-4900000 (100 Lines) Fax : 0124-2218733 E-mail : parkmedicenters@gmail.com

**PARK GROUP OF HOSPITALS : West Delhi • South Delhi • Gurgaon • Karnal • Panipat • Hodal • Ambala • Behror**





**DEPARTMENT OF PATHOLOGY**

Patient Name : Mr. NITIN GARG  
MR No : 656731  
Age/Sex : 35 Years / Male  
Type : OPD  
TPA/Corporate : MEDIWHEEL PVT LTD

Bill Date : 23/07/2022  
Reporting Date : 23/07/2022  
Sample ID : 21491  
Bill/Req. No. : 22931445  
Ref Doctor : Dr.RMO

Test	Result	Bio. Ref. Interval	Units
<b>ESR (WESTERGREIN)</b>			
ESR.	15	0 - 15	mm at the end of 1st hr

\*\*\*\*\* END OF THE REPORT \*\*\*\*\*



Sample no.

Dr.NALANDA BUKTARE  
MD (Pathology)

Dr.PRADIP KUMAR  
Consultant (Microbiology)

Dr.NISHA TIWARI  
MBBS, MD (Microbiology)

USER NM NEERAJPA752

(This is only professional opinion and not the diagnosis, Please correlate clinically)

Q Block South City 11, Sohna Road, Main Sector-47, Gurgaon, Haryana  
Ph.: 0124-4900000 (100 Lines) Fax : 0124-2218733 E-mail : parkmedicenters@gmail.com

**PARK GROUP OF HOSPITALS : West Delhi • South Delhi • Gurgaon • Karnal • Panipat • Hodal • Ambala • Behror**







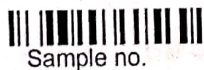## DEPARTMENT OF PATHOLOGY

Patient Name : Mr. NITIN GARG  
 MR No : 656731  
 Age/Sex : 35 Years / Male  
 Type : OPD  
 TPA/Corporate : MEDIWHEEL PVT LTD

Bill Date : 23/07/2022  
 Reporting Date : 23/07/2022  
 Sample ID : 21491  
 Bill/Req. No. : 22931445  
 Ref Doctor : Dr RMO

Test	Result	Bio. Ref. Interval	Units
<b>CBC</b>			
HAEMOGLOBIN	14.8	11.5 - 17.0	gms/dL
TOTAL LEUCOCYTE COUNT	5800	4000 - 11000	/ $\mu$ L
<b>DIFFERENTIAL COUNT</b>			
NEUTROPHILS	55	50.0 - 80.0	%
LYMPHOCYTES	35	20.0 - 40.0	%
MONOCYTES	08	2.0 - 10.0	%
EOSINOPHILS	02	0.0 - 5.0	%
BASOPHILS	00	0.0 - 2.0	%
RED BLOOD CELL COUNT	5.2	3.5 - 5.5	millions/ $\mu$ L
PACKED CELL VOLUME	43.1	35.0 - 50.0	%
MEAN CORPUSCULAR VOLUME	82.7	75 - 95	fL
MEAN CORPUSCULAR HAEMOGLOBIN	28.4	27 - 31	Picogrames
MEAN CORPUSCULAR HB CONC	34.3	33 - 37	%
PLATELET COUNT	171	150 - 450	lakhs
RDW	13.2	11.6 - 13.7	%

\*\*\*\* END OF THE REPORT \*\*\*\*



Sample no.

Dr.NALANDA BUKTARE  
 MD (Pathology)

Dr.PRADIP KUMAR  
 Consultant (Microbiology)

Dr.BHAVANA CHAUHAN  
 MBBS, MD (Microbiology)

USER NM NEERAJPA752

(This is only professional opinion and not the diagnosis, Please correlate clinically)

Q Block South City 11, Sohna Road, Main Sector-47, Gurgaon, Haryana  
 Ph.: 0124-4900000 (100 Lines) Fax : 0124-2218733 E-mail : parkmedicenters@gmail.com

PARK GROUP OF HOSPITALS : West Delhi • South Delhi • Gurgaon • Karnal • Panipat • Hodal • Ambala • Behror





**DEPARTMENT OF PATHOLOGY**

Patient Name : Mr. NITIN GARG  
MR No : 656731  
Age/Sex : 35 Years / Male  
Type : OPD  
TPA/Corporate : MEDIWHEEL PVT LTD

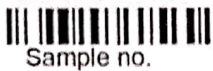Bill Date : 23/07/2022  
Reporting Date : 23/07/2022  
Sample ID : 21491  
Bill/Req. No. : 22931445  
Ref Doctor : Dr.RMO

Test	Result	Blo. Ref. Interval	Units
------	--------	--------------------	-------

**BLOOD GROUPING AND RH FACTOR**

BLOOD GROUP	" B " RH POSITIVE
-------------	-------------------

\*\*\*\*\* END OF THE REPORT \*\*\*\*\*



Sample no.

Dr.NALANDA BUKTARE  
MD (Pathology)

Dr.PRADIP KUMAR  
Consultant (Microbiology)

Dr.NISHA TIWARI  
MBBS, MD (Microbiology)

USER NM SHOABPA166

(This is only professional opinion and not the diagnosis, Please correlate clinically)

Q Block South City 11, Sohna Road, Main Sector-47, Gurgaon, Haryana

Ph.: 0124-4900000 (100 Lines) Fax : 0124-2218733 E-mail : parkmedicenters@gmail.com

**PARK GROUP OF HOSPITALS : West Delhi • South Delhi • Gurgaon • Karnal • Panipat • Hodal • Ambala • Behror**

the **health** care providers

the **health** care providers

Page 1 of 1







**DEPARTMENT OF PATHOLOGY**

Patient Name : Mr. NITIN GARG

MR No : 656731

Age/Sex : 35 Years / Male

Type : OPD

TPA/Corporate : MEDIWHEEL PVT LTD

Bill Date : 23/07/2022

Reporting Date : 24/07/2022

Sample ID : 21491

Bill/Req. No. : 22931445

Ref Doctor : Dr.RMO

Test	Result	Bio. Ref. Interval	Units
<b>THYROID PROFILIE</b>			
TRHODOTHYRONINE (T3)	1.07	0.60 - 1.81	ng/ml
THYROXINE (T4)	7.2	5.01 - 12.45	µg/dL
THYROID STIMULATING HORMONE (TSH)	2.71	0.5-5.50	µIU/ml

\*\*\*\*\* END OF THE REPORT \*\*\*\*\*



Sample no.

Dr.NALANDA BUKTARE  
MD (Pathology)

Dr.PRADIP KUMAR  
Consultant (Microbiology)

Dr.NISHA TIWARI  
MBBS, MD (Microbiology)

USER NM : DINESH

(This is only professional opinion and not the diagnosis, Please correlate clinically)

Q Block South City 11, Sohna Road, Main Sector-47, Gurgaon, Haryana

Ph.: 0124-4900000 (100 Lines) Fax : 0124-2218733 E-mail : parkmedicenters@gmail.com

PARK GROUP OF HOSPITALS : West Delhi • South Delhi • Gurgaon • Karnal • Panipat • Hodal • Ambala • Behror





# Park Hospital

GROUP SUPER SPECIALITY HOSPITAL



Atin 35/14

23/7/22

O/E → Stant<sup>n</sup>, calculat<sup>n</sup>


Adv:- Scaling and Polishing.



D.P. - 11/8088110

Wepohl 80/10

177 ebn



(This is only professional opinion and not the diagnosis, Please correlate clinically)

Q Block South City 11, Sohna Road, Main Sector-47, Gurgaon, Haryana

Ph.: 0124-4900000 (100 Lines) Fax : 0124-2218733 E-mail : parkmedicenters@gmail.com

**PARK GROUP OF HOSPITALS** : West Delhi • South Delhi • Gurgaon • Karnal • Panipat • Hodal • Ambala • Behror

the **health** care providers


the **health** care providers







For regular check up  
no go ear pain / discharge  
no nasal implants  
Go on & off some (unabs) @



Oral - B/L pillars anesthetized  
but MOD

Nose - septum medullary  
but MOD

Adv  
Pure true audiology

Adv  
Cefzil lozenges TRD  
Warm saline gargles TRD



23/7/22

(This is only professional opinion and not the diagnosis, Please correlate clinically)

Q Block South City 11, Sohna Road, Main Sector-47, Gurgaon, Haryana  
Ph.: 0124-4900000 (100 Lines) Fax : 0124-2218733 E-mail : parkmedcenters@gmail.com

**PARK GROUP OF HOSPITALS** : West Delhi • South Delhi • Gurgaon • Karnal • Panipat • Hodal • Ambala • Behror





PRE-EMPLOYMENT HEALTH CHECK UP REPORT

DATE 23/07/22

PATIENT NAME- Mrs. Nitin Garg AGE- 35 Years  
WEIGHT(KG) 80 Kgs HEIGHT- 177cm

GENDER- Male

PHYSICAL EXAMINATION

PULSE

BP

110/80

BLOOD SUGAR(RANDOM)

FINDINGS

Investigations: Investigation reports are attached

FITNESS CERTIFICATE

It is fit, but need  
further evaluation & management  
of urine routine & microscopy  
report mentioning pus cell and.  
[4+5]



SIGNATURE

*[Handwritten Signature]*

(This is only professional opinion and not the diagnosis, Please correlate clinically)

Q Block South City 11, Sohna Road, Main Sector-47, Gurgaon, Haryana  
Ph.: 0124-4900000 (100 Lines) Fax : 0124-2218733 E-mail : parkmedicenters@gmail.com

PARK GROUP OF HOSPITALS : West Delhi • South Delhi • Gurgaon • Karnal • Panipat • Hodal • Ambala • Behror

the **health** care providers

the **health** care providers





NABL  
Cert. No. MC - 4830



NABH  
Cert. No. H-2016-0369

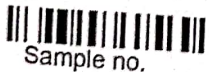**DEPARTMENT OF PATHOLOGY**

Patient Name : Mr. NITIN GARG  
MR No : 656731  
Age/Sex : 35 Years / Male  
Type : OPD  
TPA/Corporate : MEDIWHEEL PVT LTD

Bill Date : 23/07/2022  
Reporting Date : 25/07/2022  
Sample ID : 21491  
Bill/Req. No. : 22931445  
Ref Doctor : Dr.RMO

Test	Result	Bio. Ref. Interval	Units
<b>URINE C/S</b>			
NAME OF SPECIMEN	URINE C/S		
ORGANISM IDENTIFIED	NO MICRO ORGANISM GROWN IN CULTURE AFTER 48 HRS OF INCUBATION AT 37 C DEGREE..		

\*\*\*\*\* END OF THE REPORT \*\*\*\*\*



Sample no.

Dr.NALANDA BUKTARE  
MD (Pathology)

Dr.PRADIP KUMAR  
Consultant (Microbiology)

Dr.NISHA TIWARI  
MBBS, MD (Microbiology)

(This is only professional opinion and not the diagnosis, Please consult your physician)  
Q Block South City 11, Sohna Road, Main Sector-47, Gurgaon, Haryana  
Ph.: 0124-4900000 (100 Lines) Fax : 0124-2218733 E-mail : parkmedicenters@gmail.com

USER NM: NEE RAJPA752

**PARK GROUP OF HOSPITALS : West Delhi • South Delhi • Gurgaon • Karnal • Panipat • Hodal • Ambala • Behror**

the **health** care providers

the **health** care providers





NAME	: MR. NITIN GARG	DATE	: 23 / 7 / 22
Age Sex	: 35Years/ Male	Inpatient No	:
PERFORMED BY	: Dr. ELA MADAAN	BILL NO.	: 22931445

## TRANS THORACIC ECHO CARDIOGRAPHY REPORT

### MITRAL VALVE

**Morphology** AML: Normal / Thickening / Calcification / Flutter / Vegetation / Non significant Prolapse / SAM  
PML: Normal / Thickening / Calcification / Prolapse / Paradoxical Motion / Fixed.  
Subvalvular deformity: Present / Absent

**Doppler** Normal / Abnormal  
Mitral Stenosis Present / Absent  
Mitral Regurgitation; Absent / Normal / Mild / Trace / Moderate / Severe.

### TRICUSPID VALVE

**Morphology** Normal / Atresia / Thickening / Calcification / Prolapse / Vegetation / Doming.

**Doppler** Normal / Abnormal  
Tricuspid Stenosis : Present / Absent.  
Tricuspid Regurgitation: Absent / Mild / Trace / Moderate

### PULMONARY VALVE

**Morphology** Normal / Atresia / Thickening / Calcified / Doming / Vegetation.

**Doppler** Normal / Abnormal.  
Pulmonary stenosis: Present / Absent  
Pulmonary regurgitation: Present / Absent

### AORTIC VALVE

**Morphology** Normal / Thickened / Mildly / Calcified / Flutter / Vegetation / Restricted / Opening

No. of Cusps 1 / 2 / 3 / 4  
**Doppler** Normal / Abnormal  
Aortic Stenosis : Present / Absent  
Aortic regurgitation : Present / Absent / Mild / Trace

(This is only professional opinion and not the diagnosis, Please correlate clinically)

Q Block South City 11, Sohna Road, Main Sector-47, Gurgaon, Haryana  
Ph.: 0124-4900000 (100 Lines) Fax : 0124-2218733 E-mail : parkmedicenters@gmail.com

**PARK GROUP OF HOSPITALS** : West Delhi • South Delhi • Gurgaon • Karnal • Panipat • Hodal • Ambala • Behror





# Park Hospital

GROUP SUPER SPECIALITY HOSPITAL



<u>Measurements</u>	<u>Normal Values</u>	<u>Measurements</u>	<u>Normal Value</u>
IVSD : 1.1cm	(0.6-1.1cm))	LA : 3.8cm	(1.9-4.0cm)
LVID : 4.5cm	(3.7-5.6cm)	LVOT : 1.3cm	
LVPW : 1.1cm	(0.6-1.1cm)	AORTA : 2.8cm	(2.0-3.7cm)
EF : 60%	(55% - 80%)	IVSmotion :	Normal / Flat / Paradoxical

Any Other

### CHAMBERS:-

LV Normal / Enlarged / Clear / Thrombus /  
 Contraction Normal LV shows concentric LVH, no gradient across LVOT /Inetic / Intra capillary  
 Regional wall motion abnormality: Absent/ Present

LA Normal /Enlarged / Clear /Thrombus / Myxoma; LAA: Clear / Thrombus

RA Normal / Clear / Thrombus, Dilated.

RV Normal / Mildly Dilated / Enlarged / Clear / Thrombus / Hypertrophied/  
 PERICARDIUM Normal / Thickening / Calcification / Effusion.

### COMMENTS & SUMMARY:-

- All Cardiac Chamber Dimensions are within normal limits.
- Global LVEF 60%
- No RWMA (regional wall motion abnormality at rest)
- TRACE MR
- NO AR / NO AS
- TRACE TR
- GOOD RV FUNCTION
- IAS/IVS. No Flow seen across IAS/IVS.
- No Thrombus/Mass in any chamber.
- No Pericardial Effusion.

Please correlate clinically

Dr. ELA MADAAN  
 MBBS, PGDCC  
 Fellowship in non Invasive  
 Cardiology

Dr. JAGDISH KUMAR SHARMA  
 M.D.(Medicine) D.M (Cardiology). FCSI, FACC,FESC  
 HOD & Director Interventional cardiology.

(This is only professional opinion and not the diagnosis, Please correlate clinically)

Q Block South City 11, Sohna Road, Main Sector-47, Gurgaon, Haryana  
 Ph.: 0124-4900000 (100 Lines) Fax : 0124-2218733 E-mail : parkmedicenters@gmail.com

**PARK GROUP OF HOSPITALS : West Delhi • South Delhi • Gurgaon • Karnal • Panipat • Hodal • Ambala • Behror**

the **health** care providers

the **health** care providers



Scanned with OKEN Scanner

DEPARTMENT OF RADIOLOGY

Patient Name	Mr NITIN GARG	Billed Date	: 23/07/2022	9.12 AM
Reg No	656731	Reported Date	: 23/07/2022	
Age/Sex	35 Years / Male	Req. No.	: 22931445	
Type	OPD	Consultant Doctor	: Dr. RMO	

X-RAY CHEST AP/PA

X-RAY CHEST P.A. VIEW

Bilateral lungs appears normal.

No focal lung lesion seen.

No evidence of free fluid is seen.

Both hila are normal in size, have equal density and bear normal relationship.


The heart and trachea are central in position and no mediastinal abnormality is visible.

The cardiac size is normal for patient age and view.

The domes of the diaphragms are normal in position, and show smooth outline.

To be correlated clinically



  
Dr. ANSHU J. SHARMA  
MBBS, MD  
CONSULTANT RADIOLOGIST

Dr. SAKET RUPRAMKA  
MBBS, MD  
CONSULTANT RADIOLOGIST

Dr. MANJEET SEHRAWAT  
MBBS, MD, PDCC  
CONSULTANT RADIOLOGIST

Dr. NEENA SIKKA  
MBBS, DNB  
CONSULTANT RADIOLOGIST

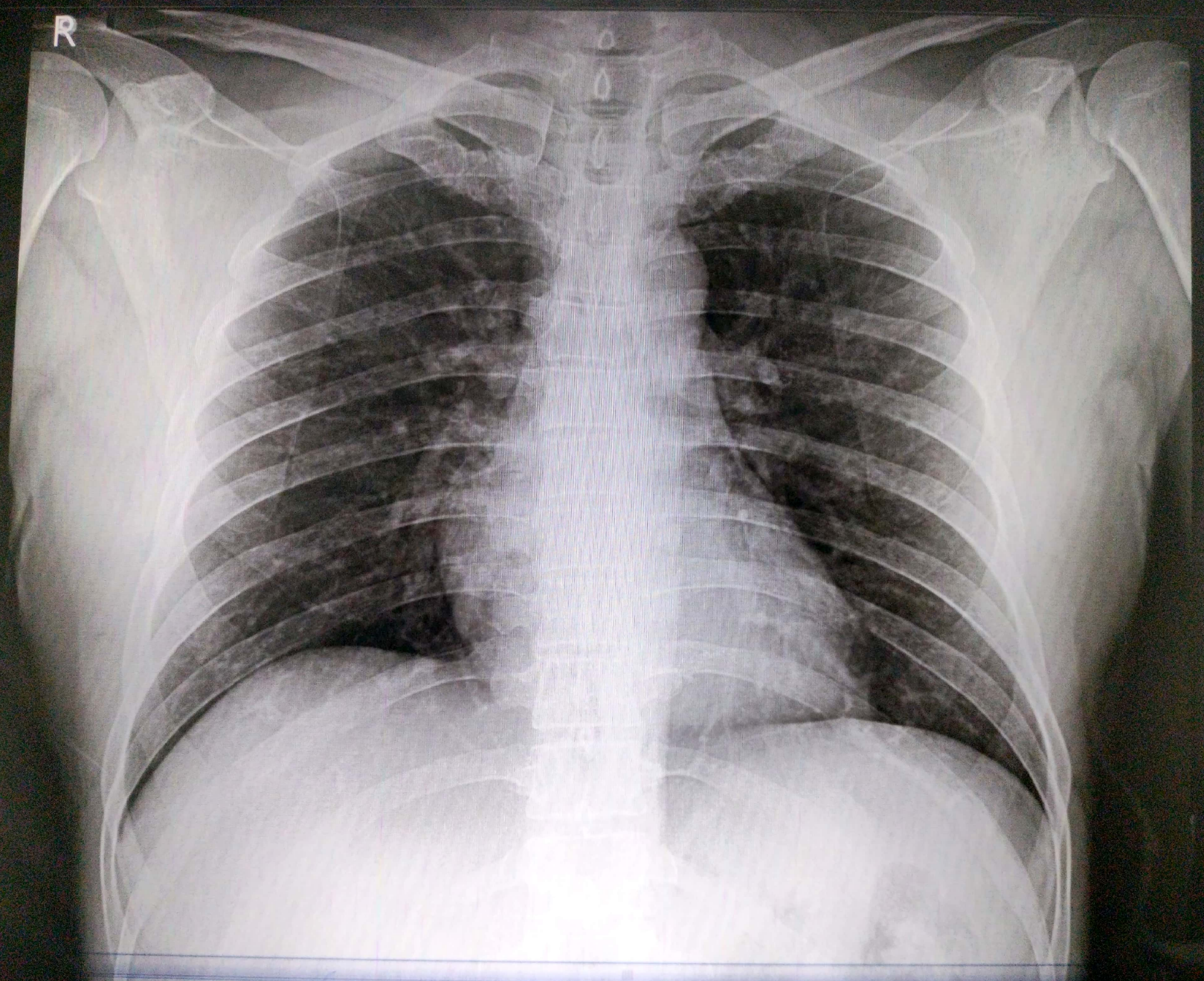
(This is only professional opinion and not the diagnosis, Please correlate clinically.)

Gurgaon : Q Block, South City-II, Sohna Road, Sector-47, Gurugram-122002, (Haryana)  
Faridabad : J-Block, Sector - 10, Near Court, Faridabad - 121004, (Haryana)

• Helpline : 0129-4200000  
• Helpline : 0129-4200000



R



**NITIN GARG 35Y REQ-22931445 M CXR AP 7/23/2022 09:43 AM  
PARK HOSPITAL SOUTH CITY II GURGAON HARYANA**



**DEPARTMENT OF RADIOLOGY**

Patient Name	Mr NITIN GARG	Billed Date	: 23/07/2022	9.12 AM
Reg No	656731	Reported Date	: 23/07/2022	
Age/Sex	35 Years / Male	Req. No.	: 22931445	
Type	OPD	Consultant Doctor	: Dr. RMO	

**USG WHOLE ABDOMEN**

The Real time, B mode, gray scale sonography of the abdominal organs was performed.

**LIVER** : The liver is enlarged in size, 16.9 cm with fatty infiltration. No evidence of any focal lesion. IHBR is NOT dilated.

**GALL BLADDER** : The gall bladder is well distended. No evidence any calculus or mass seen. No evidence of pericholecystic fluid is seen.

**BILE DUCT** : The common bile duct is normal in caliber. No evidence of calculus is noted in common bile duct.

**SPLEEN** : The spleen is normal in size 8.5cm and shape. Its echotexture is homogeneous. No evidence of focal lesion is noted.

**PANCREAS** : The pancreas is normal in size, shape, contours and echotexture. No evidence of solid or cystic mass lesion is noted. MPD is not dilated. No evidence of peripancreatic collection.

**KIDNEYS** : The bilateral kidneys are normal in size and echotexture. Cortico-medullary differentiation is maintained. There is no evidence of obvious calculus or hydronephrosis.

**URINARY BLADDER** : The urinary bladder is well distended. Wall thickness within normal limits. No evidence of calculus is seen. No evidence of mass or diverticulum is noted.

**PROSTATE** : Prostate appears normal in shape, size and echotexture.

No evidence of ascites or interbowel free fluid is seen.  
No evidence of obvious retroperitoneal or mesenteric lymphadenopathy is seen.

**IMPRESSION-** Hepatomegaly with fatty liver grade-II

To be correlated clinically

Dr. ANSHU K. SHARMA  
MBBS, MD  
CONSULTANT RADIOLOGIST

Dr. SAKET RUPRAMKA  
MBBS, MD  
CONSULTANT RADIOLOGIST

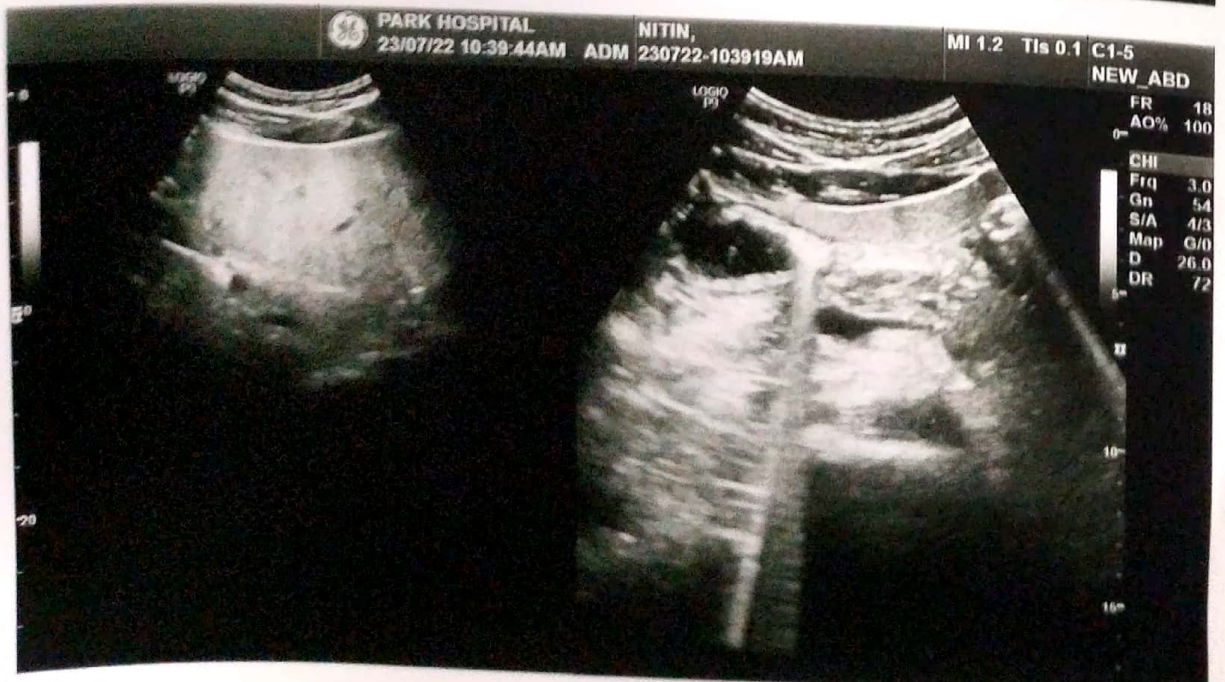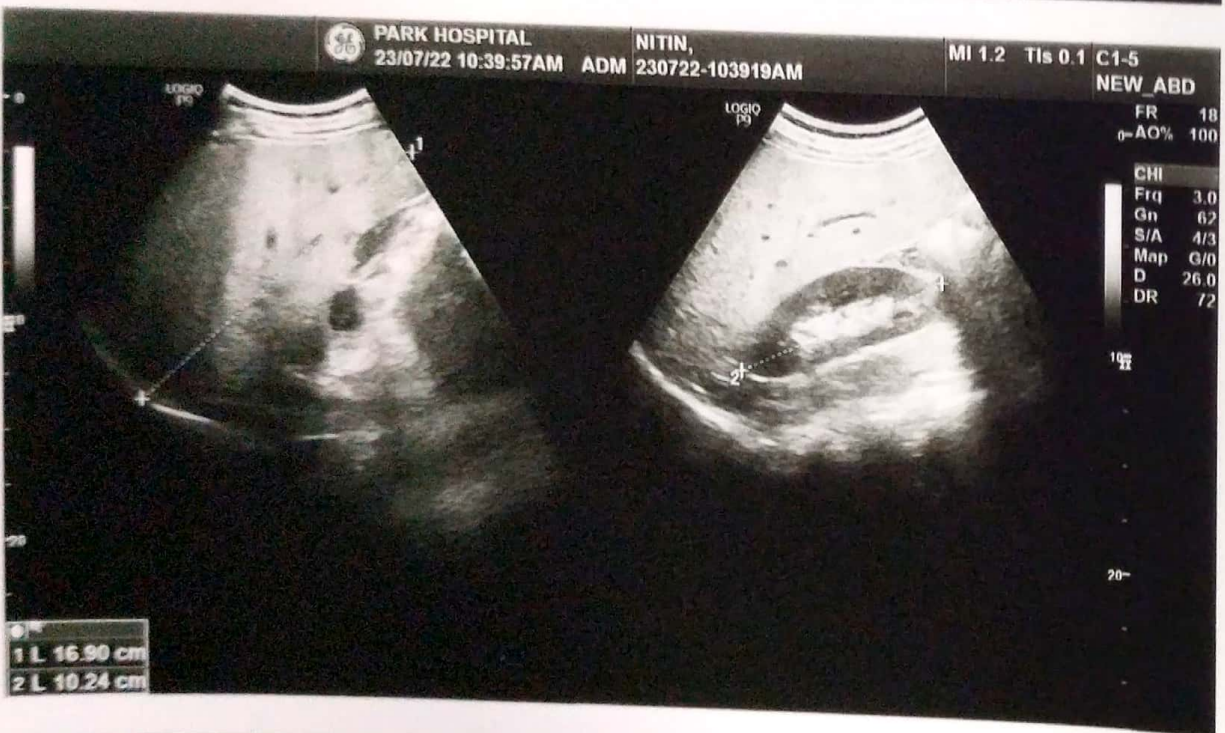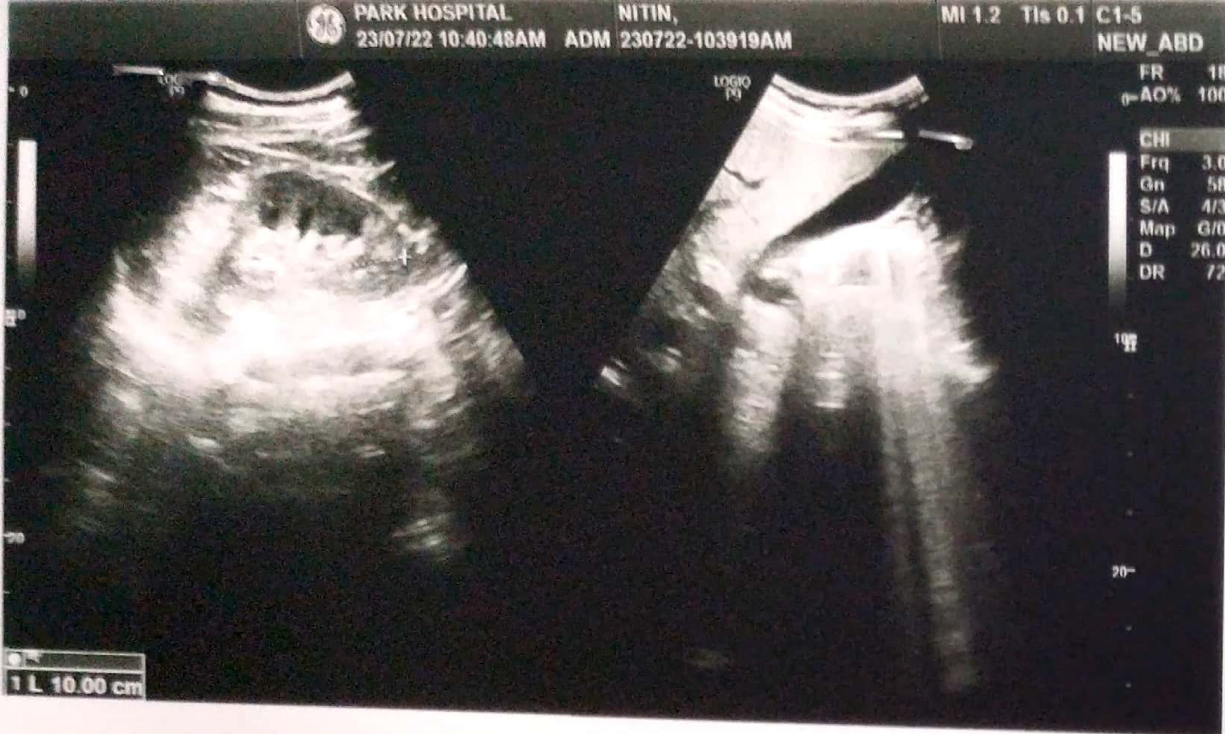Dr. MANJEET SEHRAWAT  
MBBS, MD, PDCC  
CONSULTANT RADIOLOGIST

Dr. NEENA SIKKA  
MBBS, DNB  
CONSULTANT RADIOLOGIST



(This is only professional opinion and not the diagnosis, Please correlate clinically.)







25mm/s 0.5-25Hz

I 10mm/mV

aVR 10mm/mV

V1 10mm/mV

II

aVL

V2

SYNC

SYNC

SYNC

III

aVF

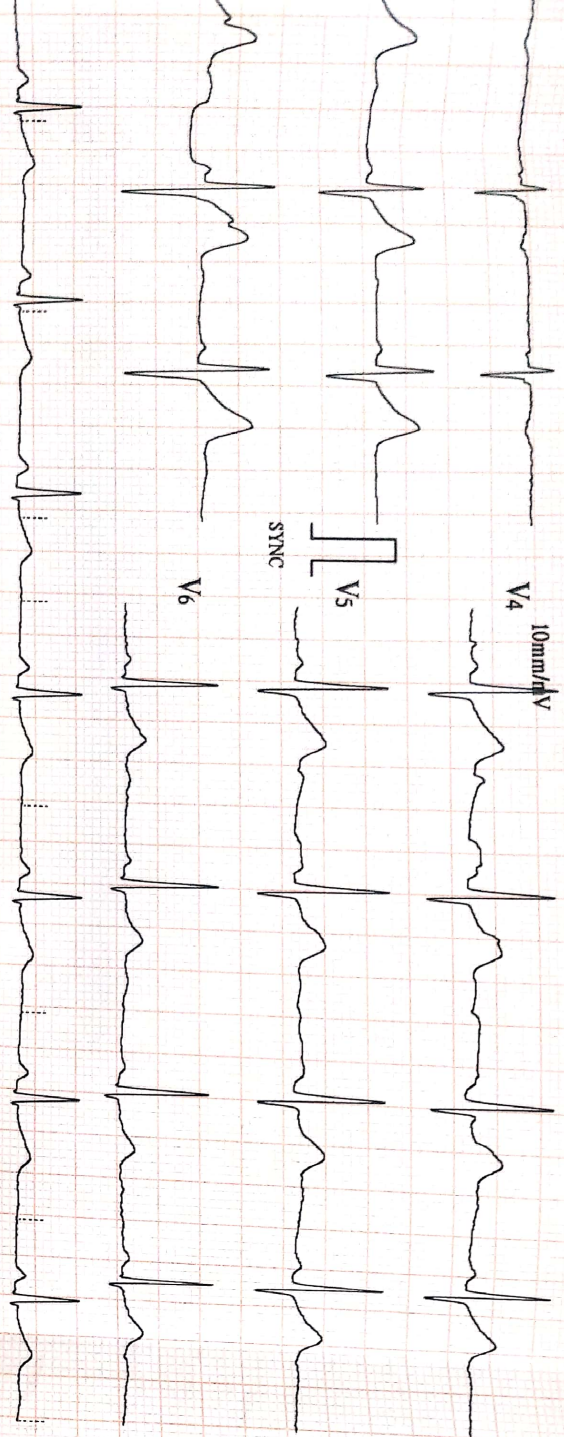
V3

10mm/mV

II

EKG-1203 V2.000 (B10S:V2.000/AMP:V1.001) 2016-01-01 00:01





ID : 1793

Name: Mr. A.H. H

Sex : M

Age : 38

23/07/22

Unconfirmed report Verified by:

HR	: 63	bpm
R-R	: 951	ms
P-R	: 136	ms
QRS	: 96	ms
QT/QTc	: 390/399	ms
P/QRS/T	: 39.47/12	°
RV5/SVI	: 1.100/0.590	mV
RV5+SVI	: 1.690	mV

----- Sinus Rhythm  
 ----- T Abnormality(Negative T)