



भारत सरकार

GOVERNMENT OF INDIA



कृती संजय कपूर
Kruti Sanjay Kapoor
जन्म तारीख/ DOB:
09/12/1995
महिला / FEMALE



7770 4108 4840

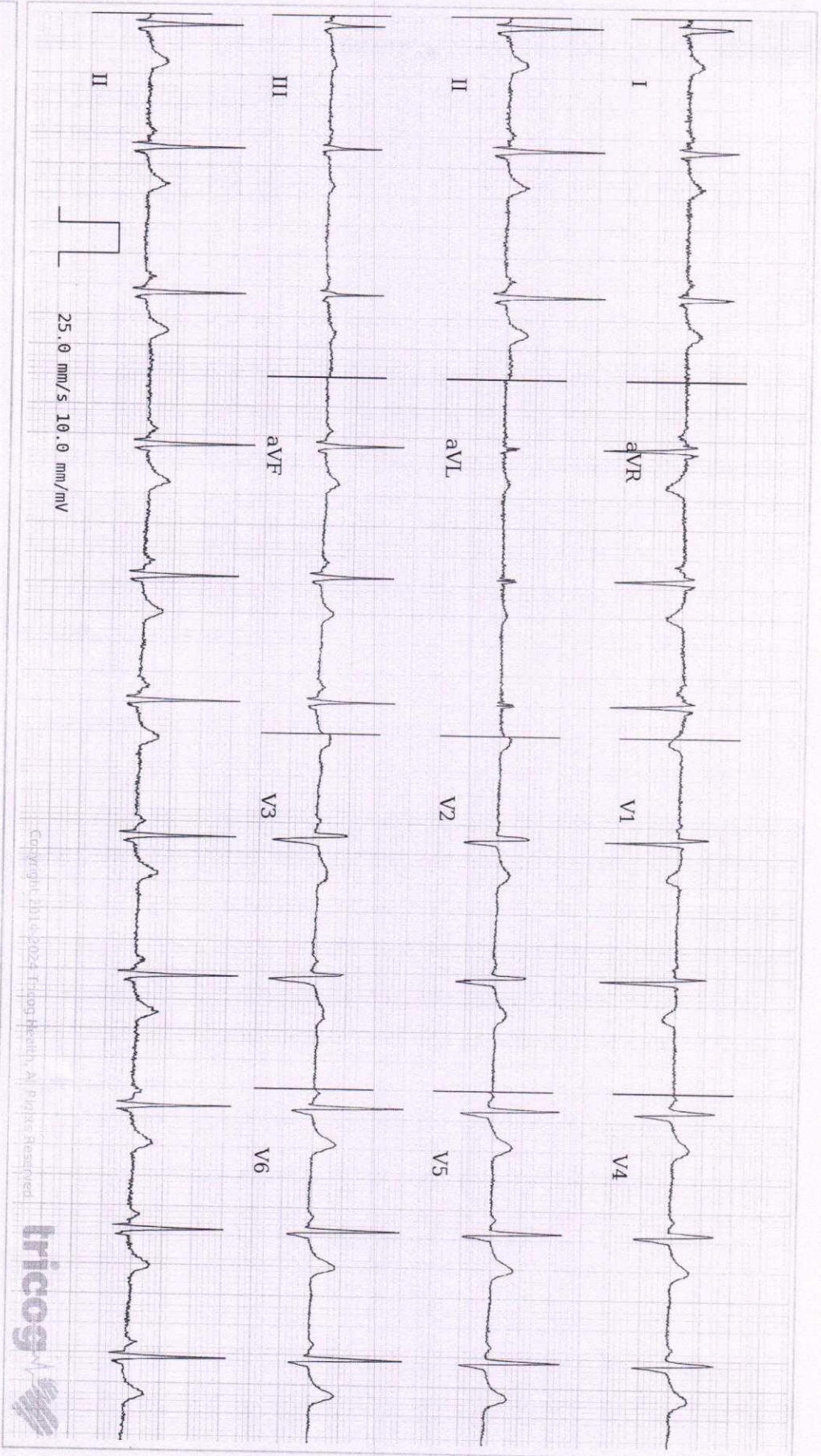
माझे आधार, माझी ओळख

Kruti

Patient Name: KRUTI KAPOOR
Patient ID: 2408913531

SUBURBAN DIAGNOSTICS - MALAD WEST

Date and Time: 29th Mar 24 12:44 PM



Copyright 2014-2024 TriCog Health, All Rights Reserved.



Age **28** NA
years months

Gender **Male**

Heart Rate **67bpm**

Patient Vitals

BP: 120/70 mmHg

Weight: 75 kg

Height: 159 cm

Pulse: NA

Spo2: NA

Resp: NA

Others:

Measurements

QRSD: 84ms
QT: 382ms
QTcB: 403ms
PR: 104ms
P-R-T: 61° 61° 44°

ECG Within Normal Limits: Sinus Rhythm Sinus Arrhythmia Seen Short PR Interval. Please correlate clinically.

REPORTED BY

[Signature]

DR SONALI HONRAO
MD (General Medicine)
Physician
2001/04/1882

Disclaimer: 1) Analysis in this report is based on ECG alone and should be used as an adjunct to clinical history, symptoms, and results of other invasive and non-invasive tests and must be interpreted by a qualified physician. 2) Patient vitals are as entered by the clinician and not derived from the ECG.

Date:- 29/3/24

CID: 2408913486

Name:- kruti kappor

Sex / Age: F / 28

EYE CHECK UP

Chief complaints:

Systemic Diseases:

Past history:

Unaided Vision:

Aided Vision: DV
 RE - 6/6
 LE - 6/6

NV
 RE - N16
 LE - N16

Refraction:

	(Right Eye)				(Left Eye)			
	Sph	Cyl	Axis	Vn	Sph	Cyl	Axis	Vn
Distance	_____				_____			
Near	_____				_____			

Colour Vision: Normal / Abnormal

Remark:

SUBURBAN DIAGNOSTICS (INDIA) PVT. LTD.
 102-104, Bhoomi Centre,
 Opp. Goregaon Sports Club,
 Road, Malad (W), Mumbai - 400 064.

Authenticity Check



Use a QR Code Scanner
Application To Scan the Code

CID : 2408913531
Name : Mrs Kruti Kapoor
Age / Sex : 28 Years/Female
Ref. Dr :
Reg. Location : Malad West Main Centre

Reg. Date : 29-Mar-2024
Reported : 29-Mar-2024 / 11:06

USG WHOLE ABDOMEN

LIVER:

The liver is normal in size, shape and smooth margins. It shows normal parenchymal echo pattern. The intra hepatic biliary and portal radical appear normal. No evidence of any intra hepatic cystic or solid lesion seen. The main portal vein and CBD appears normal.

GALL BLADDER:

The gall bladder is physiologically distended and appears normal. No evidence of gall stones or mass lesions seen.

PANCREAS:

The pancreas is well visualised and appears normal. No evidence of solid or cystic mass lesion.

KIDNEYS:

Both the kidneys are normal in size, shape and echotexture. No evidence of any calculus, hydronephrosis or mass lesion seen.
Right kidney measures 8.7 x 3.4 cm.
Left kidney measures 10.1 x 4.4 cm.

SPLEEN:

The spleen is normal in size and echotexture. No evidence of focal lesion is noted. There is no evidence of any lymphadenopathy or ascites.

URINARY BLADDER:

The urinary bladder is well distended and reveal no intraluminal abnormality.

UTERUS (TAS):

The uterus is anteverted and appears normal.
The endometrial thickness is 9.6 mm.

OVARIES (TAS):

Small hemorrhagic cyst measuring 3.3 x 2.3 cm is seen in right ovary.
Left ovary appears normal.
There is no evidence of any ovarian or adnexal mass seen.
Right ovary = 4.5 x 4.2 cm. Left ovary = 2.4 x 1.2 cm.

Click here to view images <http://3.111.232.119/iRISViewer/NeoradViewer?AccessionNo=2024032909572035>

Authenticity Check



Use a QR Code Scanner
Application To Scan the Code

CID : 2408913531
Name : Mrs Kruti Kapoor
Age / Sex : 28 Years/Female
Ref. Dr :
Reg. Location : Malad West Main Centre

Reg. Date : 29-Mar-2024
Reported : 29-Mar-2024 / 11:06

IMPRESSION:-

Small hemorrhagic cyst in right ovary.

Suggestion: Clinicopathological correlation.

Note : Investigations have their limitations. Solitary radiological investigations never confirm the final diagnosis. They only help in diagnosing the disease in correlation to clinical symptoms and other related tests. USG is known to have inter-observer variations. Further / Follow-up imaging may be needed in some case for confirmation of findings. Patient has been explained in detail about the USG findings including its limitations and need for further imaging if clinically indicated. Please interpret accordingly. All the possible precaution have been taken under covid-19 pandemic.

-----End of Report-----

Dr. Sunil Bhutka
DMRD DNB
MMC REG NO:2011051101

Click here to view images <http://3.111.232.119/iRISViewer/NeoradViewer?AccessionNo=2024032909572035>