

ONEPLUS ULTRASOUND LAB

47, HARSH VIHAR, PITAMPURA, DELHI- 110034

Mr. DHARMBIR
Age : 33/M

Ref. by : MEDIWHEEL

Indication1 :

Indication2 :

Indication3 :

COMMENTS : Normal ECG.

ID : 2268
HWT : 168/71

Recorded : 22-7-2023 11:11

Medication1 :

Medication2 :

Medication3 :

BPM : 68

BP : 114/82

P Axis : 1 deg

QRS Axis : 61 deg

T Axis : 43 deg

P duration : 80 msec

PR duration : 146 msec

QRS duration : 103 msec

QT interval : 316 msec

QTc interval : 330 msec

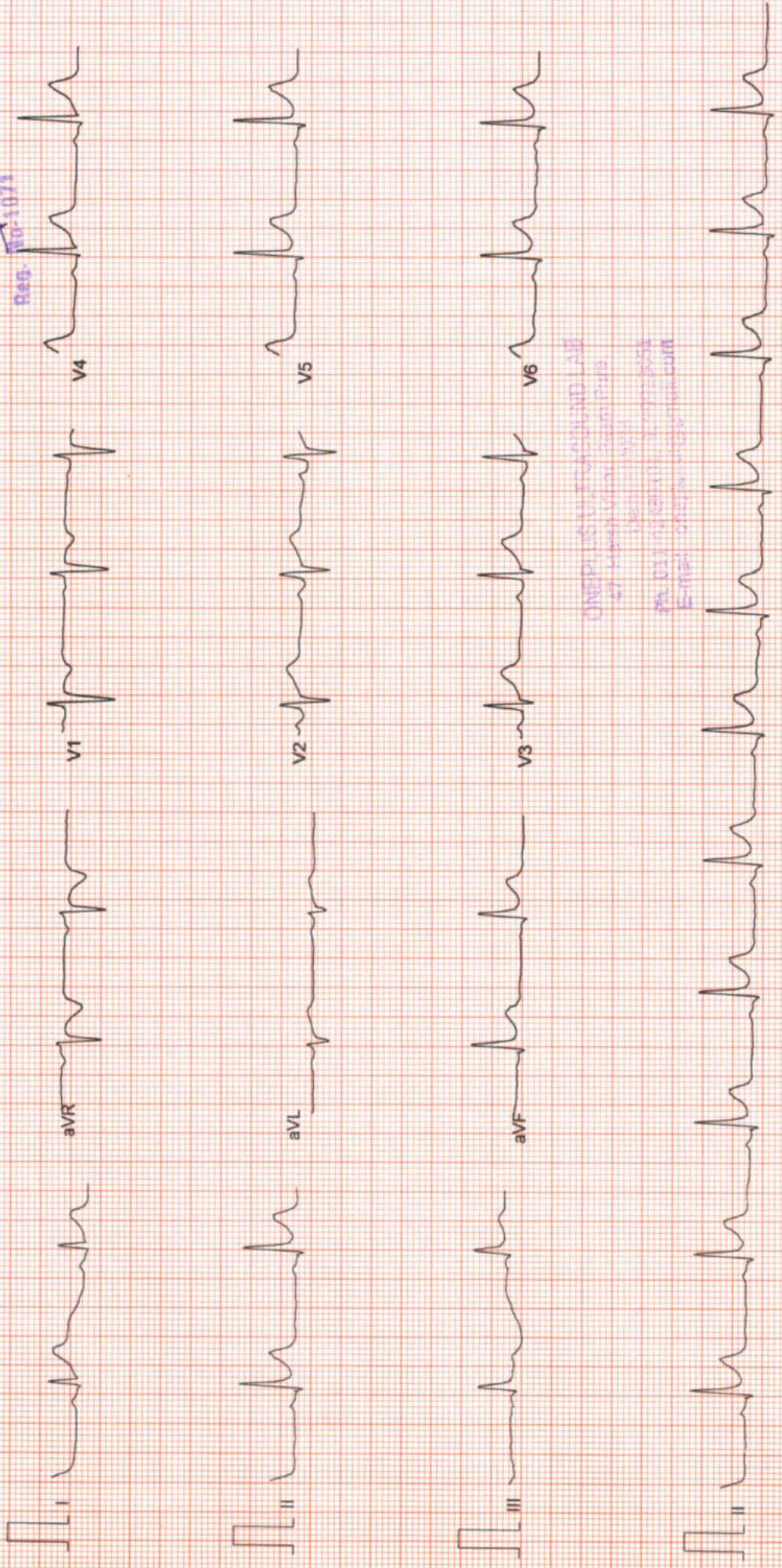
Raw E.C.G.(Seq)

Unconfirmed Report Reviewed By:

Cardiologist

Handwritten signature

Handwritten signature
Dr. P. K. GUPTA
No. 1071



ONEPLUS ULTRASOUND LAB
47, Harsh Vihar, Pitampura, Delhi-110034
Ph: 011-26281111, 26281112
E-Mail: oneplusultrasound.com

Filtered

25mm/sec 10mm/mV

CardiCom, INDIA

ONEPLUS ULTRASOUND LAB

47, HARSH VIHAR PITAMPURA DELHI 110034

Mr. DHARMBIR

Age/Sex : 33/M

Ref. by : MEDIWHEEL

Indication1 :

Indication2 :

Indication3 :

ID : 984

Ht/Wt : 168/71

Recorded : 22-7-2023 11:15

TREADMILL TEST SUMMARY REPORT

Protocol: BRUCE

History:

Medication1 :

Medication2 :

Medication3 :

| PHASE | PHASE TIME | STAGE TIME | SPEED (Km./Hr.) | GRADE (%) | H.R. (BPM) | B.P. (mmHg) | RPP X100 | II | ST LEVEL (mm) V2 | V5 | METS |
|-----------------|------------|------------|-----------------|-----------|------------|-------------|----------|------|------------------|-----|-------|
| SUPINE STANDING | | | | | 69 | 114/82 | 78 | 1.3 | 1.4 | 1.6 | |
| | | | | | 69 | 114/82 | 78 | 1.4 | 1.3 | 1.6 | |
| STAGE 1 | 2:59 | 2:59 | 2.70 | 10.00 | 101 | 114/82 | 115 | 0.6 | 1.1 | 1.3 | 4.80 |
| STAGE 2 | 5:59 | 2:59 | 4.00 | 12.00 | 125 | 130/88 | 162 | 0.1 | 0.0 | 0.5 | 7.10 |
| STAGE 3 | 8:59 | 2:59 | 5.40 | 14.00 | 139 | 140/90 | 194 | -0.6 | -0.7 | 0.1 | 10.00 |
| STAGE 4 | 10:29 | 1:29 | 6.70 | 16.00 | 161 | 150/94 | 241 | -0.2 | -0.7 | 0.2 | 11.99 |
| PEAK EXER | 10:43 | 1:43 | | | 167 | 150/94 | 250 | 0.1 | -0.5 | 0.0 | 12.30 |
| PEAK EXER | 10:44 | 1:44 | | | 167 | 150/94 | 250 | 0.1 | -0.5 | 0.0 | 12.32 |
| RECOVERY | 2:59 | 2:59 | 0.00 | 0.00 | 99 | 116/82 | 114 | -0.2 | -0.4 | 0.0 | |

RESULTS

Exercise Duration

Max Heart Rate

Max Blood Pressure

Max Work Load

Reason of Termination

10:44 Minutes
167 bpm 89 % of target heart rate 187 bpm
150/94 mmHg
12.32 METS

Negative for ischemia

IMPRESSIONS

ONEPLUS ULTRASOUND LAB
47 Harsh Vihar Pitampura
Delhi 110034
Ph: 011-22222222
0222222222
0222222222
0222222222

Dr. R. N. AGRIYA
MBBS, MD
1201101
Red Cross
Cardiologist

[Signature]

ONEPLUS ULTRASOUND LAB

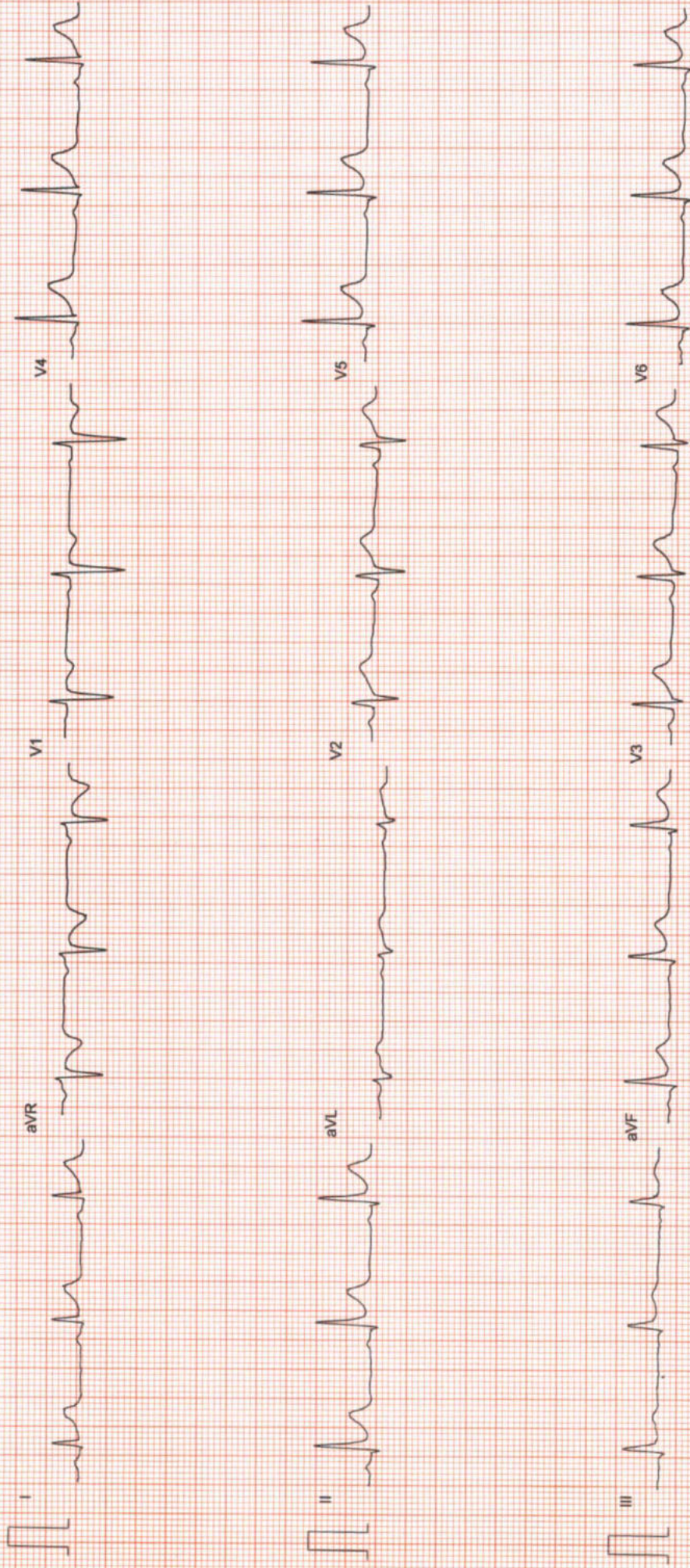
Mr. DHARMBIR
I.D. : 984
AGE/SEX : 33/M
RECORDED : 22-7-2023 11:15

RATE : 69 BPM
B.P. : 114/82 mmHg

ST @ 10mm/mV
80ms PostJ

SUPINE
PRETEST

RAW E.C.G.



ONEPLUS ULTRASOUND LAB
47 Harsh Vibhor Piplani
Delhi-110036
Ph. 011-26490331, 26490332, 26490333
E-mail: drdharmbir@gmail.com

ONEPLUS ULTRASOUND LAB

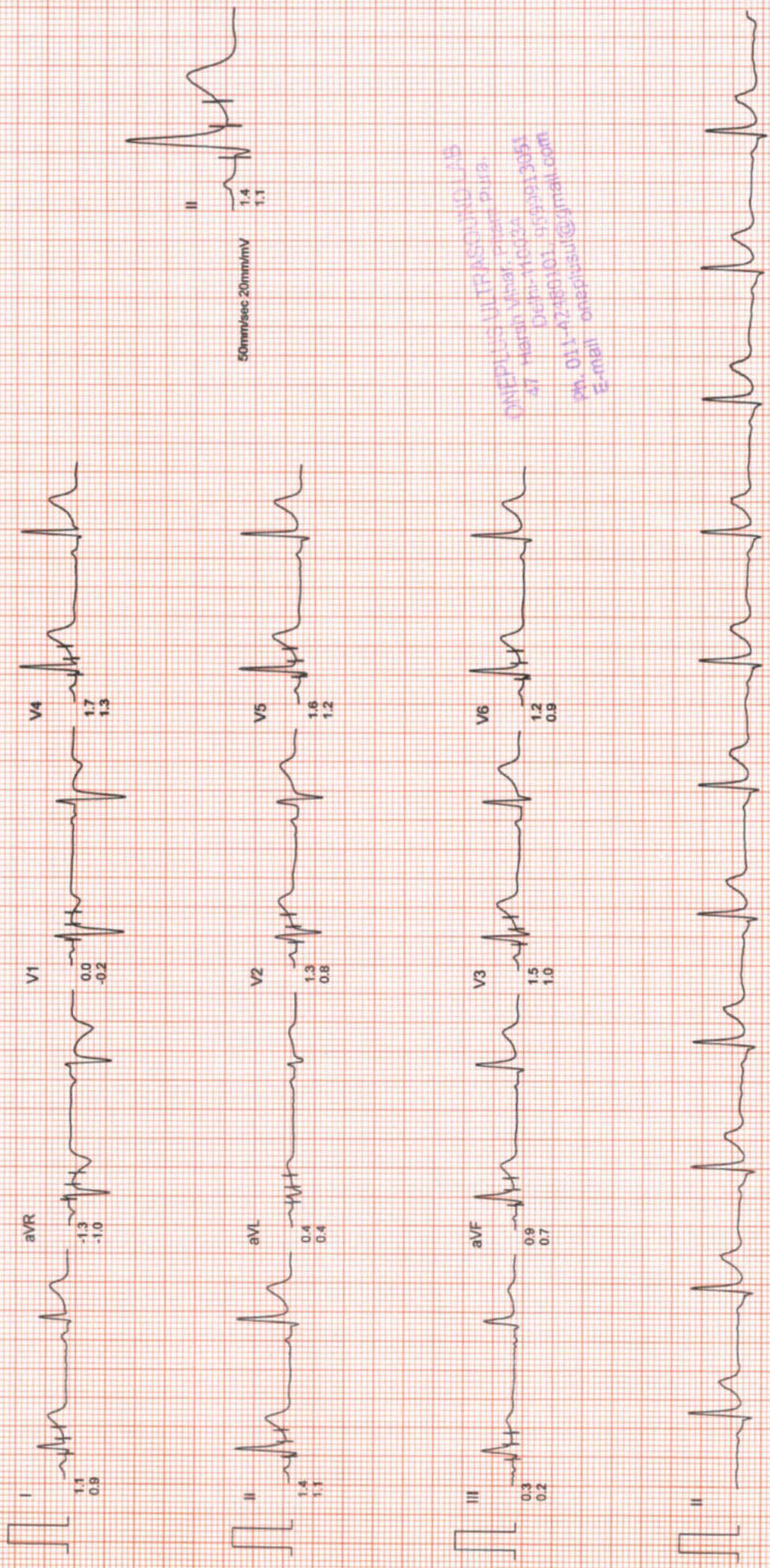
STANDING
PRETEST

ST @ 10mm/mV
80ms PostJ

Mr. DHARMBIR
I.D. : 984
AGE/SEX : 33/M
RECORDED : 22-7-2023 11:15

RATE : 69 BPM
B.P. : 114/82 mmHg

LINKED MEDIAN



ONEPLUS ULTRASOUND LAB

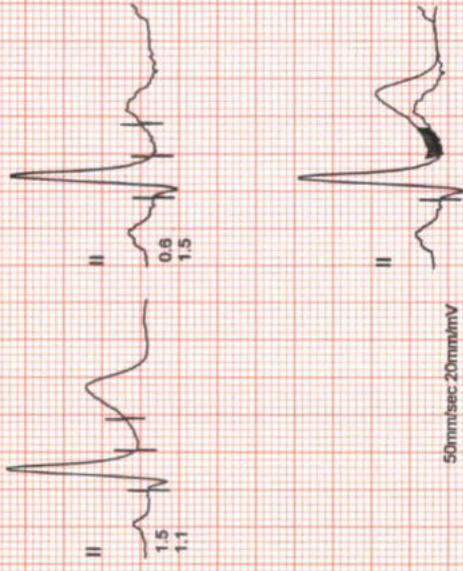
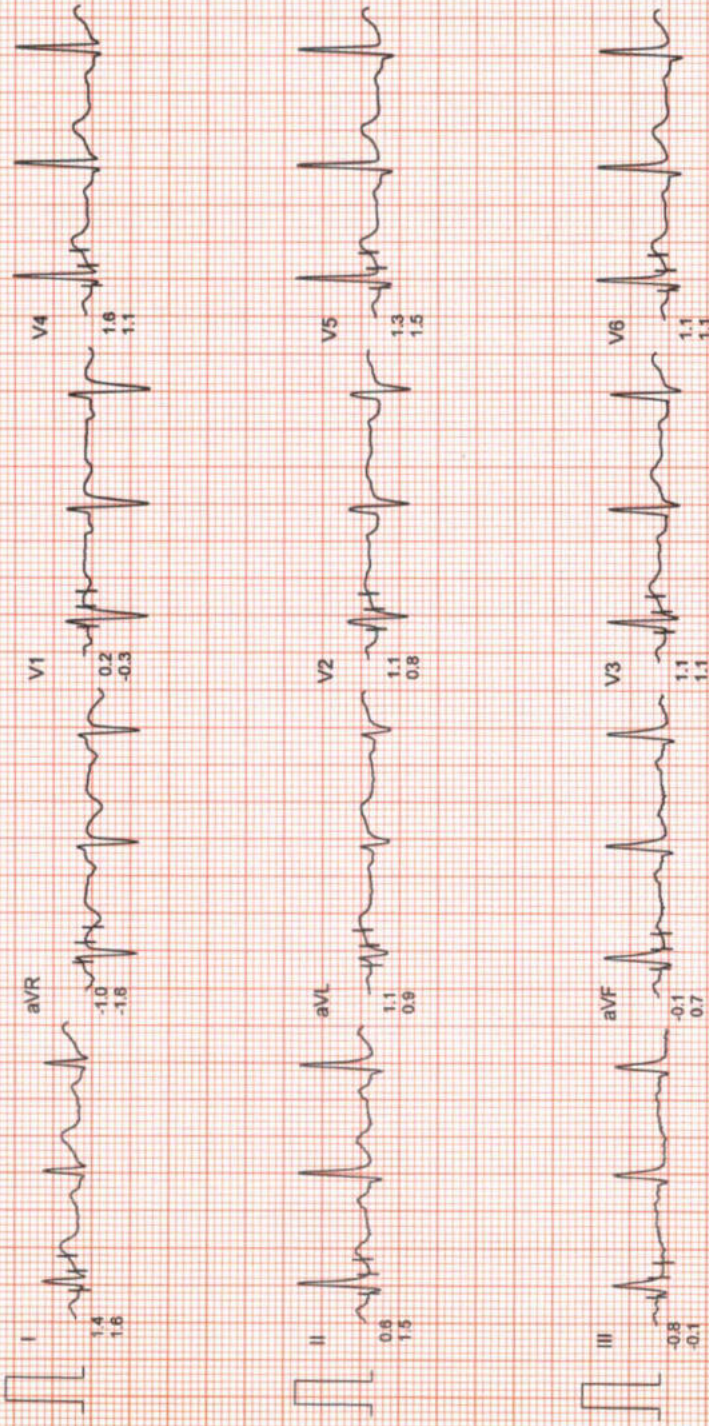
Mr. DHARMBIR
I.D. : 984
AGE/SEX : 33/M
RECORDED : 22-7-2023 11:15

RATE : 101 BPM
B.P. : 114/82 mmHg

BRUCE
EXERCISE 1
PHASE TIME : 2:59
STAGE TIME : 2:59

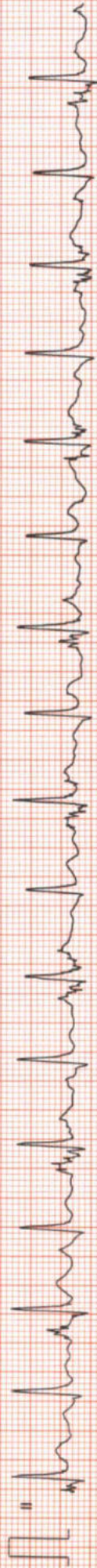ST @ 10mm/mV
80ms PostJ
SPEED : 2.7 Km./Hr.
GRADE : 10.0 %

LINKED MEDIAN



50mm/sec 20mm/mV

ONEPLUS ULTRASOUND LAB
Dr. Harsh Vihar, Pitampura
Delhi-110034
Ph: 011-42480101, 6597913051
E-mail: oneplusul@gmml.com



ONEPLUS ULTRASOUND LAB

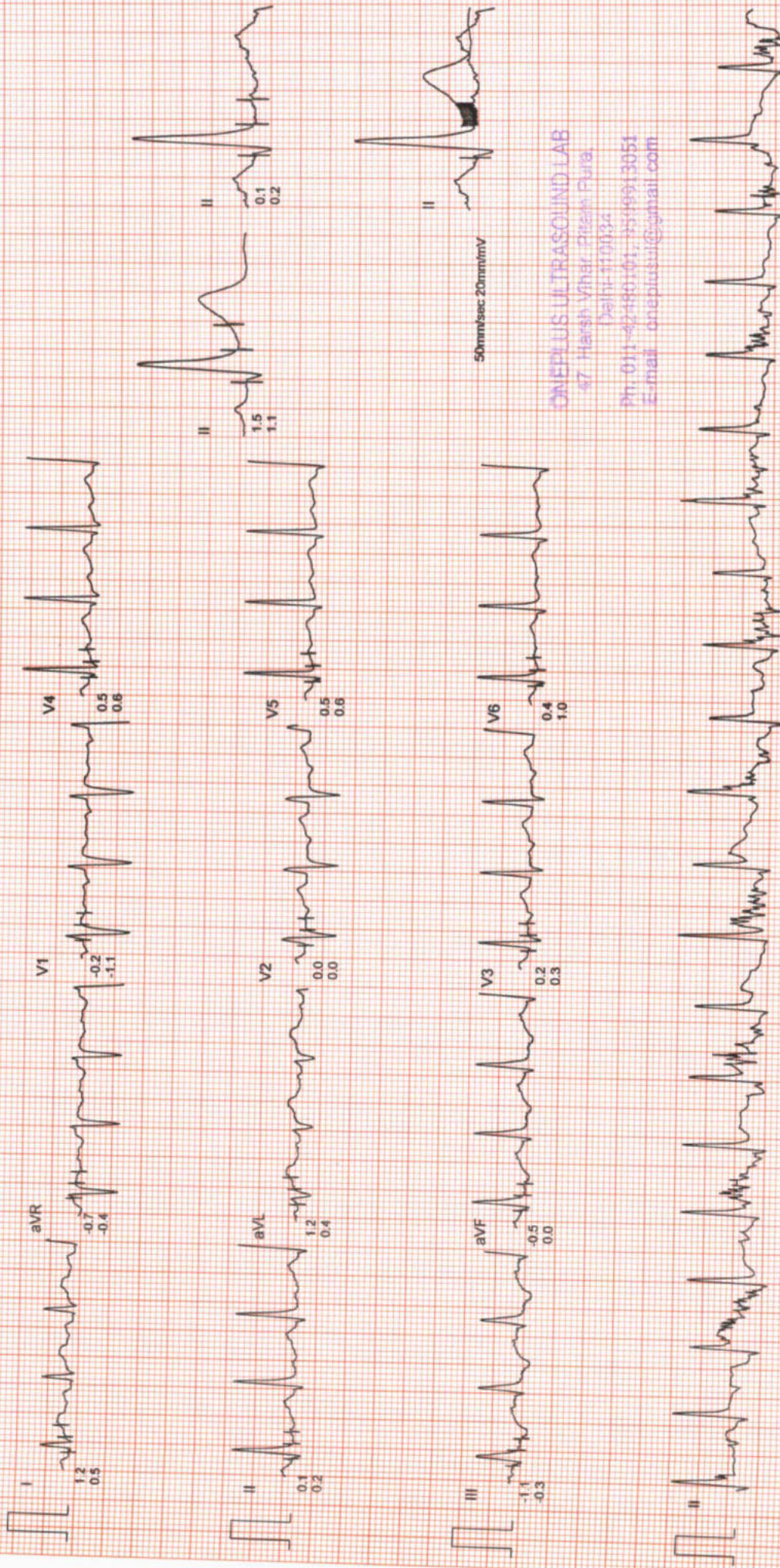
Mr. DHARBIR
I.D. : 984
AGE/SEX : 33/M
RECORDED : 22-7-2023 11:15

BRUCE
EXERCISE 2
PHASE TIME : 5:59
STAGE TIME : 2:59

ST @ 10mm/mV
80ms PostJ
SPEED : 4.0 Km./Hr.
GRADE : 12.0 %

RATE : 125 BPM
B.P. : 130/88 mmHg

LINKED MEDIAN



50mm/Sec 20mm/mV

ONEPLUS ULTRASOUND LAB
47 Herath Vihar, Piliem Pura,
Jaffna-110134
Ph: 011-62480161, 8599913051
E-mail: oneplusul@gmail.com

ONEPLUS ULTRASOUND LAB

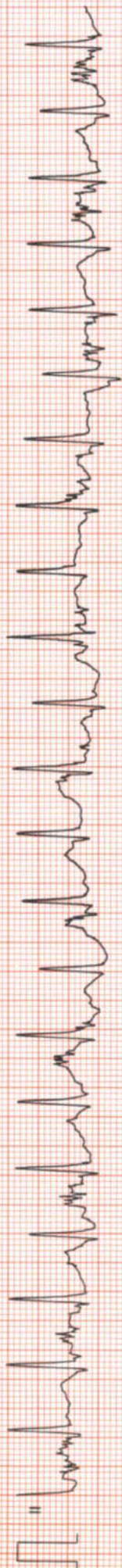
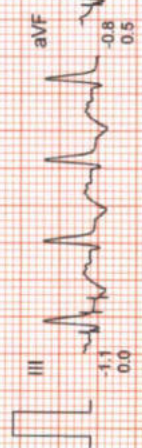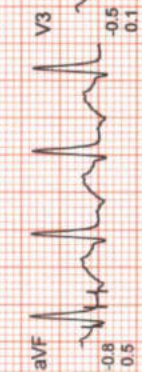
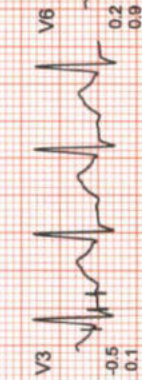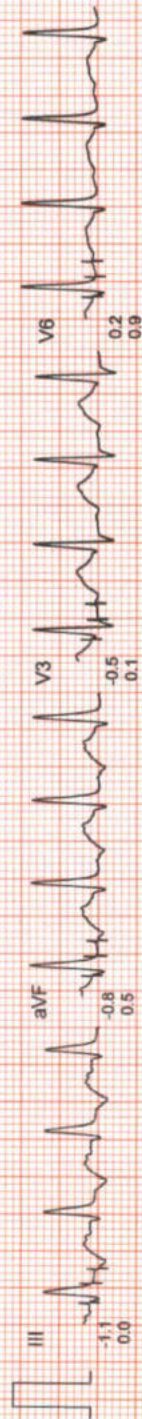
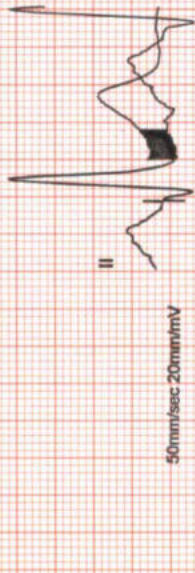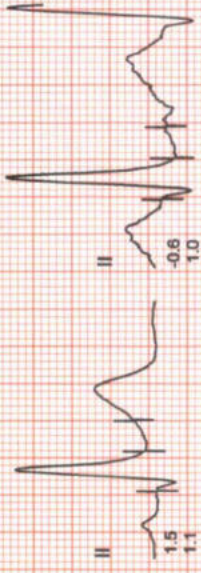
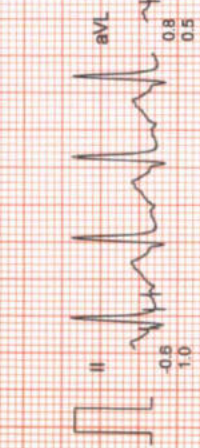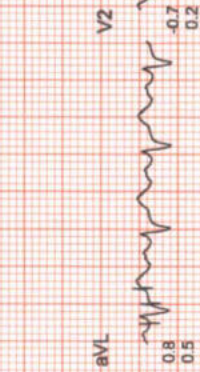
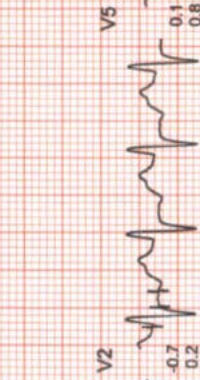
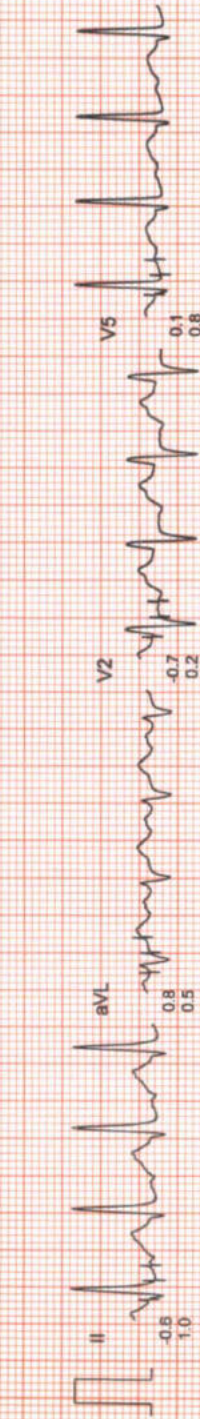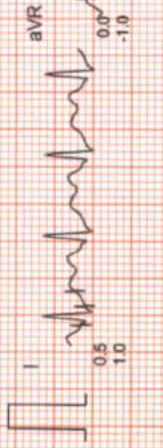
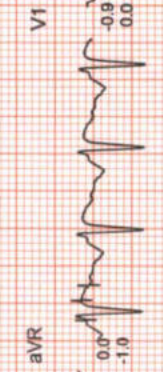
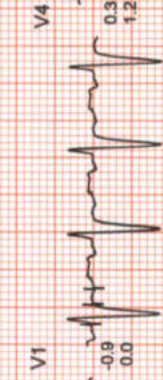
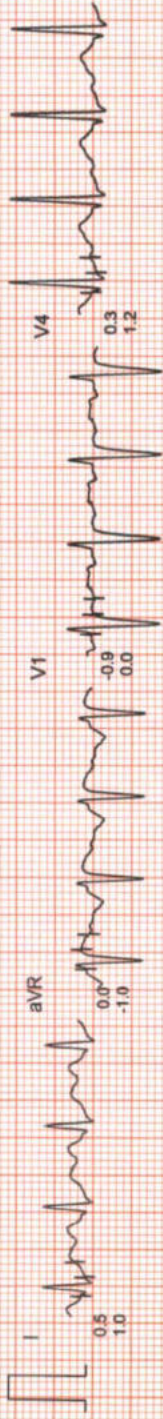
Mr. DHARMBIR
I.D. : 984
AGE/SEX : 33/M
RECORDED : 22-7-2023 11:15

BRUCE
EXERCISE 3
PHASE TIME : 8:59
STAGE TIME : 2:59

ST @ 10mm/mV
80ms PostJ
SPEED : 5.4 Km./Hr.
GRADE : 14.0 %

RATE : 139 BPM
B.P. : 140/90 mmHg

LINKED MEDIAN



ONEPLUS ULTRASOUND LAB
47 Harsh Vihar Phase 2, Gurgaon,
Delhi-1150034

Ph. 011-62481101-624913051
E-mail: oneplusul@ymail.com

50mm/sec 20mm/mV

ONEPLUS ULTRASOUND LAB

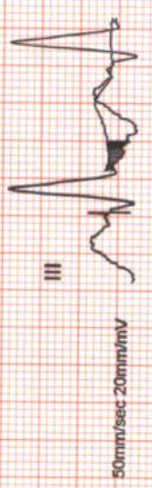
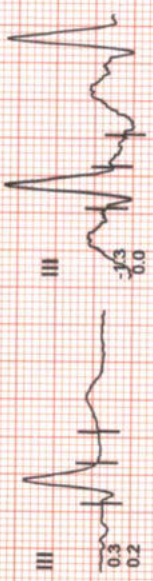
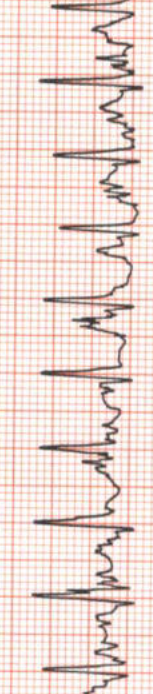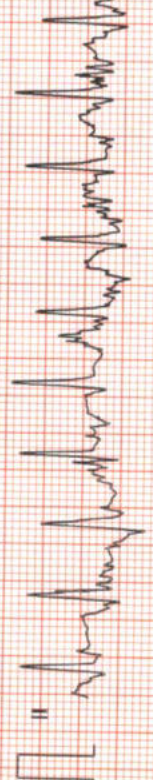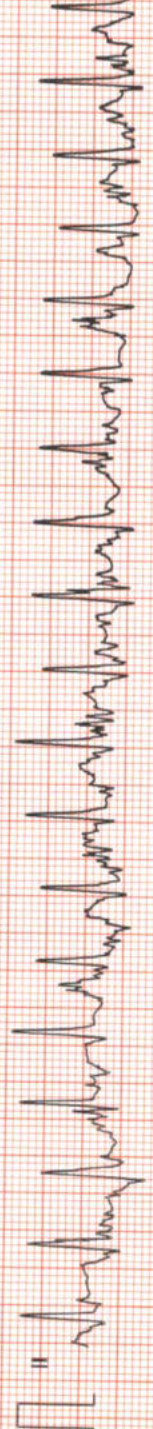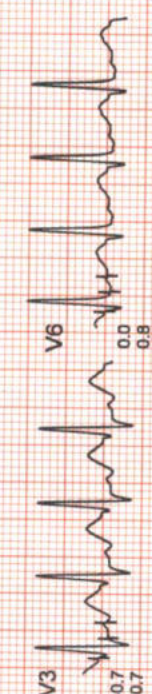

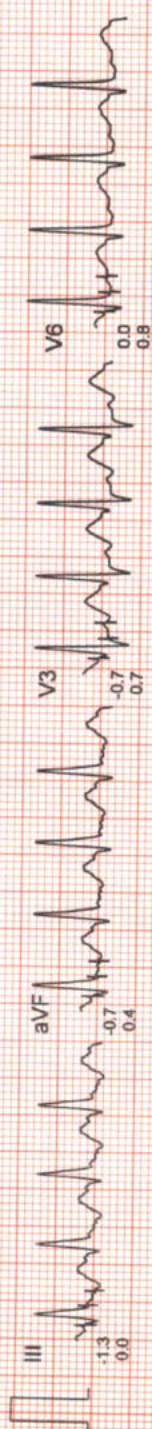
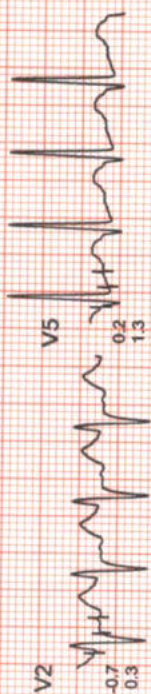
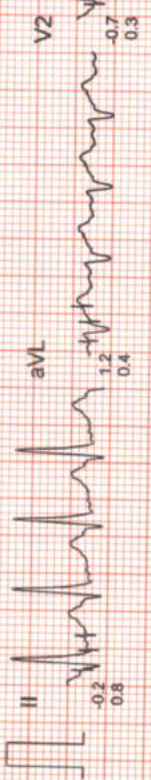
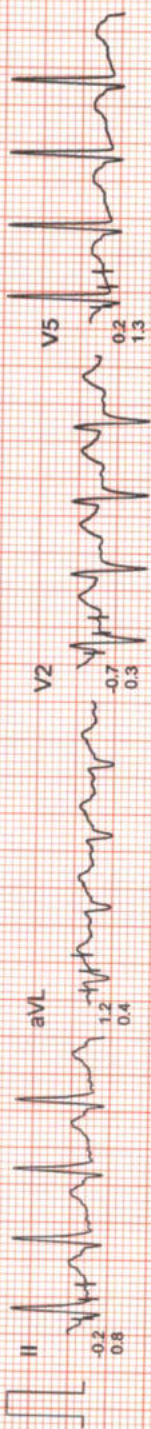
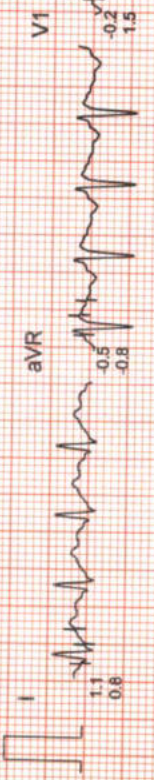
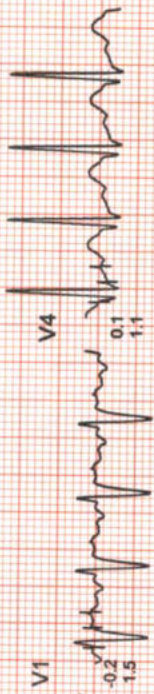
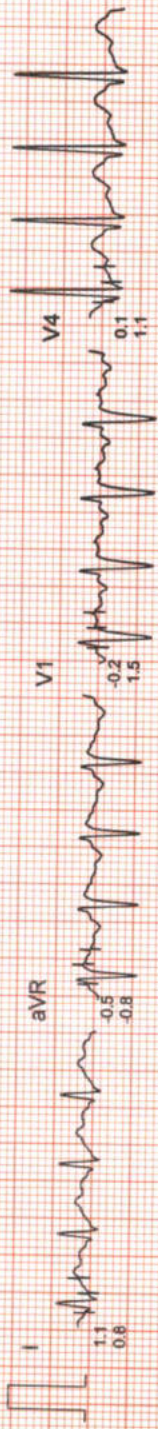
Mr. DHARMBIR
I.D. : 984
AGE/SEX : 33/M
RECORDED : 22-7-2023 11:15

BRUCE
EXERCISE 4
PHASE TIME : 10:29
STAGE TIME : 1:29

RATE : 161 BPM
B.P. : 150/94 mmHg

ST @ 10mm/mV
80ms PostJ
SPEED : 6.7 Km./Hr.
GRADE : 16.0 %

LINKED MEDIAN



50mm/sec 20mm/mV

ONEPLUS ULTRASOUND LAB
47, Harsa Vihar, Pitambara,
Delhi-110054
Ph. 011-4248119, 45999215054
E-mail: oneplus@onepluslab.com

ONEPLUS ULTRASOUND LAB

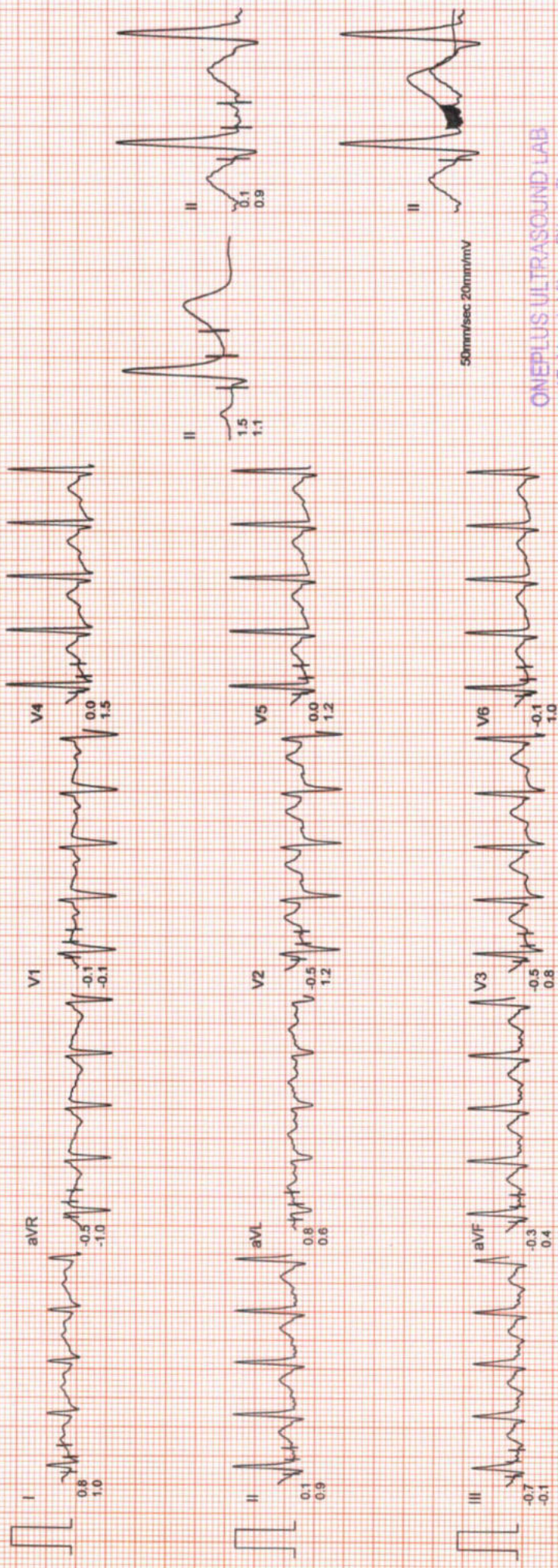
Mr. DHARBIR
I.D. : 984
AGE/SEX : 33/M
RECORDED : 22-7-2023 11:15

BRUCE
PEAK EXER
PHASE TIME : 10:43
STAGE TIME : 1:43

RATE : 167 BPM
B.P. : 150/94 mmHg

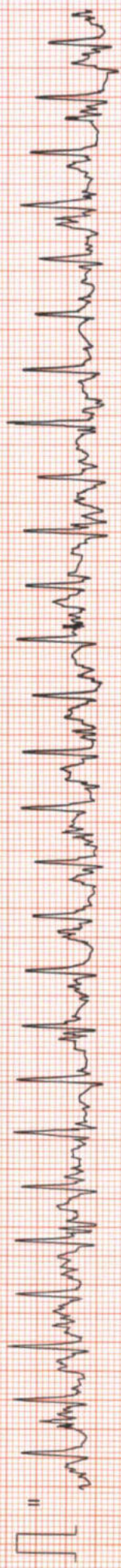
ST @ 10mm/mV
80ms PostJ
SPEED : 6.7 Km./Hr.
GRADE : 16.0 %

LINKED MEDIAN



50mm/sec 20mm/mV

ONEPLUS ULTRASOUND LAB
47 Harsh Vihar Pitam Pura,
Delhi-110014
Ph. 011 23831101 238313051
E-mail: onepus@oneplusultrasound.com



ONEPLUS ULTRASOUND LAB

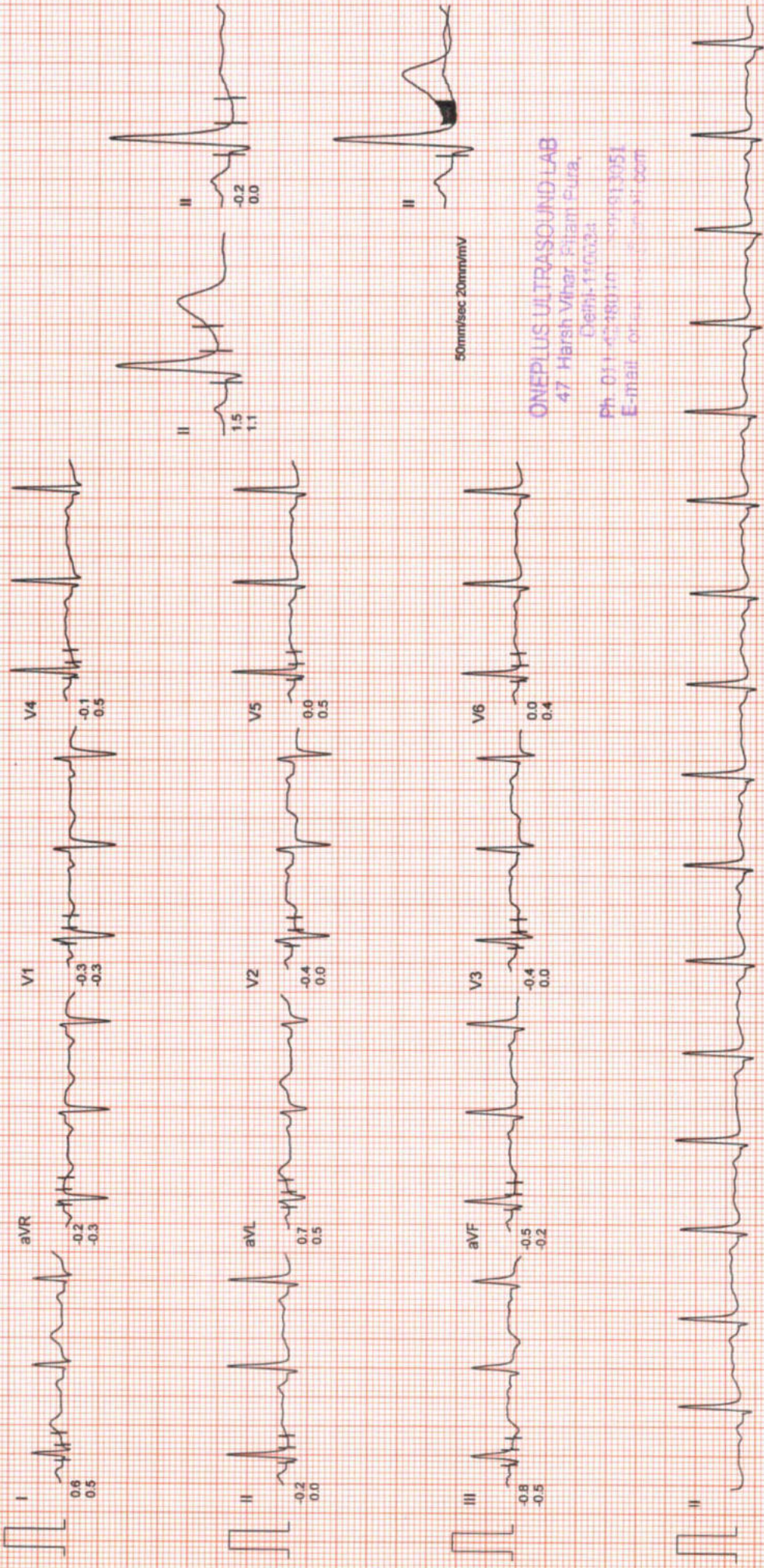
Mr. DHARMBIR
I.D. : 984
AGE/SEX : 33/M
RECORDED : 22-7-2023 11:15

BRUCE
RECOVERY
PHASE TIME : 2:59

RATE : 99 BPM
B.P. : 116/82 mmHg

ST @ 10mm/mV
80ms PostJ
SPEED : 0.0 Km./Hr.
GRADE : 0.0 %

LINKED MEDIAN



ONEPLUS ULTRASOUND LAB
47 Harsh Vihar Pitambara,
Ghaziabad
Ph: 011-45188101, 011-45188102
E-MAIL: oneplusultrasound@gmail.com

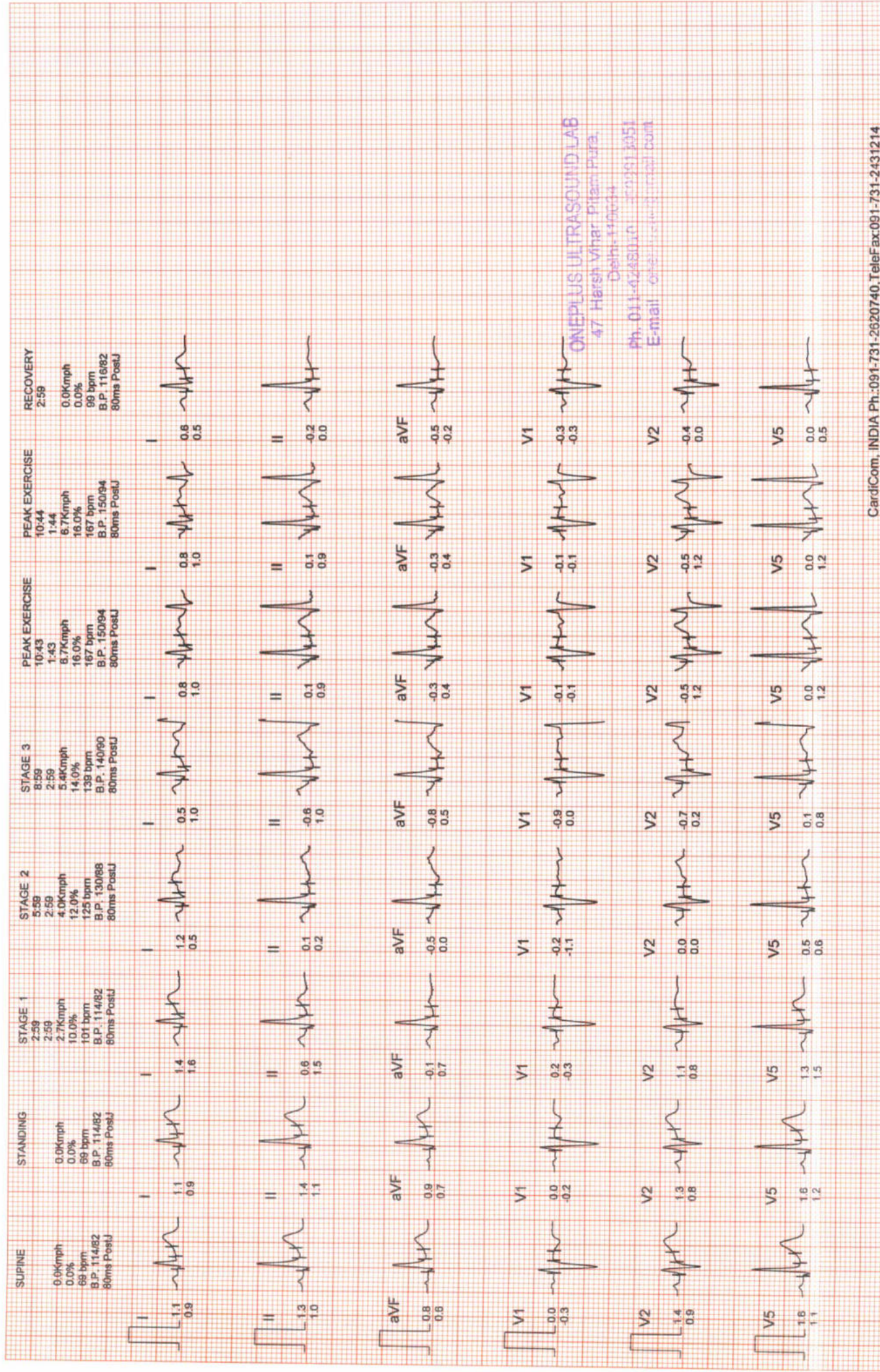
ONEPLUS ULTRASOUND LAB

I.D. : 984

RECORDED : 22- 7-2023 11:15

AGE/SEX : 33/M

AVG E.C.G.



ONEPLUS ULTRASOUND LAB

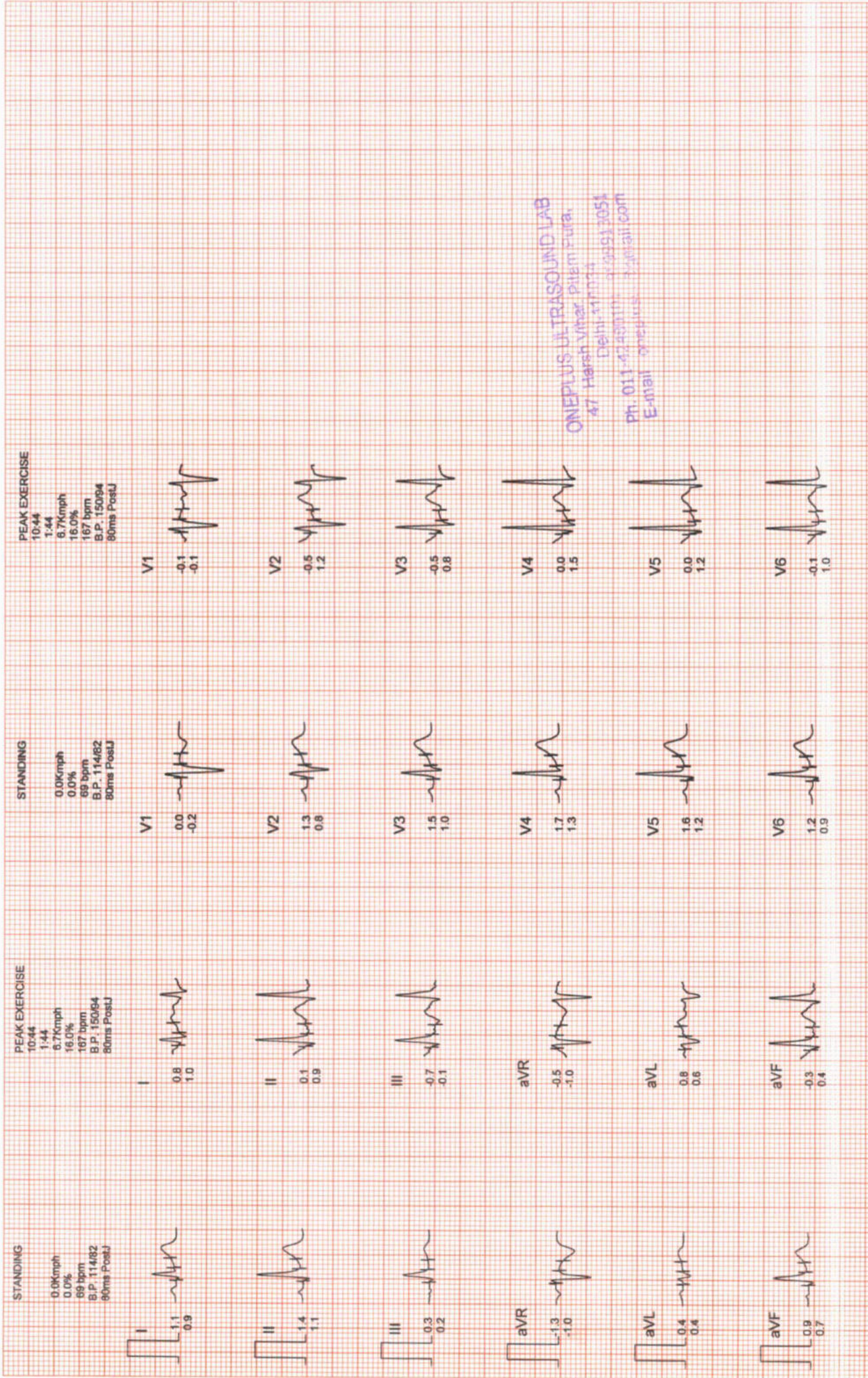
AGE/SEX : 33/M

I.D. : 984

Mr. DHARMBIR

RECORDED : 22-7-2023 11:15

COMPARISON REPORT



ONEPLUS ULTRASOUND LAB
47 Harsh Vihar Pitam Pura
Delhi-110034
Ph. 011-67480171, 6748933054
E-mail: onepplus@onepluslab.com



OnePLUS

Ultrasound Lab

Dr. Nitin Agarwal
Pathologist & Director
Ex. Sr. Res. MAMC
& Lok Nayak Hospital
Ex. Chief of Lab Dr. Lal Path Labs.

Dr. Pooja (Garg) Agarwal
Radiologist & Director
MAMC & Lok Nayak Hospital



| | | | |
|-------------|-------------------------|-------------------|----------------------|
| NAME | :Mr. DHARAMBIR | Barcode No | :10149729 |
| AGE/GENDER | :33 YRS/Male | SPECIMEN DATE | :22/Jul/2023 09:35AM |
| PATIENT ID | :118072 | SPECIMEN RECEIVED | :22/Jul/2023 09:53AM |
| REFERRED BY | :Dr. MEDIWHEEL | REPORT DATE | :22/Jul/2023 04:40PM |
| CENTRE NAME | :ONEPLUS ULTRASOUND LAB | LAB NO. | :012307220013 |

| Test Name | Result | Unit | Ref. Range |
|-----------|--------|------|------------|
|-----------|--------|------|------------|

HAEMATOLOGY

Medi Wheel Health checkup < 40 Male

| | | | |
|--|-----|---|--|
| Glycosylated Hemoglobin (HbA1c) HPLC | 5.1 | % | Non Diabetic adults <5.7 Prediabetic (at risk) 5.7-6.4 Diabetes >6.4 |
|--|-----|---|--|

| | | | |
|--|-----|--|--|
| Estimated average blood glucose (eag) CALCULATED | 100 | | |
|--|-----|--|--|

Reference range (mg/dl):

90 - 120:Excellent control, 121 - 150:Good Control, 151 - 180:Average Control, 181 - 210:Action Suggested

>211:Panic value

| | | | |
|---|---|--|--|
| BLOOD GROUP (ABO) Forward and Reverse grouping (Slide & Tube) | O | | |
|---|---|--|--|

| | | | |
|------------------|----------|--|--|
| Rh typing | POSITIVE | | |
|------------------|----------|--|--|

NOTE :

- * Apart from major A,B,H antigens which are used for ABO grouping and Rh typing, many minor blood group antigens exist. Agglutination may also vary according to titre of antigen and antibody.
- * So before transfusion, reconfirmation of blood group as well as cross-matching is needed.
- * Presence of maternal antibodies in newborns, may interfere with blood grouping.
- * Auto agglutination (due to cold antibody, falciparum malaria, sepsis, internal malignancy etc.) may also cause erroneous result.

CBC

| | | | |
|---|-------|-------|------------|
| Haemoglobin Non cyanide Hb analysis | 15.5 | g/dl | 13.0-17.0 |
| Total Leucocyte Count Electrical Impedance | 7100 | /cumm | 4000-10000 |
| Differential leucocyte count | | | |
| Neutrophils Electrical Impedance & Microscopic | 47.2 | % | 40-80 |
| Lymphocyte Electrical Impedance & Microscopic | 46.80 | % | 20-40 |
| Monocytes | 4.00 | % | 2-10 |

Checked By.

Dr. NITIN AGARWAL
DR. NITIN AGARWAL
MBBS, MD
MBBS, MD (PATHOLOGIST)
Regn. No. DMC 2436

47, Harsh Vihar, Pitampura, New Delhi-110034 | Ph.: 011-42480101, 9599913051

E-mail: oneplusul@gmail.com | Web.: www.oneplusul.in

Page 1 of 6



OnePLUS Ultrasound Lab

Dr. Nitin Agarwal
Pathologist & Director
Ex. Sr. Res. MAMC
& Lok Nayak Hospital
Ex. Chief of Lab Dr. Lal Path Labs.

Dr. Pooja (Garg) Agarwal
Radiologist & Director
MAMC & Lok Nayak Hospital



| | | | |
|-------------|--|-------------------|----------------------|
| NAME | QUALITY FIRST... ALWAYS! :Mr. DHARAMBIR | Barcode No | :10149729 |
| AGE/GENDER | :33 YRS/Male | SPECIMEN DATE | :22/Jul/2023 09:35AM |
| PATIENT ID | :118072 | SPECIMEN RECEIVED | :22/Jul/2023 09:53AM |
| REFERRED BY | :Dr. MEDIWHEEL | REPORT DATE | :22/Jul/2023 04:40PM |
| CENTRE NAME | :ONEPLUS ULTRASOUND LAB | LAB NO. | :012307220013 |

| Test Name | Result | Unit | Ref. Range |
|------------------------------------|--------|--------------|---------------|
| Electrical Impedance & Microscopic | | | |
| Eosinophils | 1.2 | % | 1-6 |
| Electrical Impedance & Microscopic | | | |
| Basophils | 0.8 | % | 0-2 |
| Electrical Impedance & Microscopic | | | |
| RBC Count | 4.90 | million/cumm | 4.5 - 5.5 |
| Electrical Impedance | | | |
| Hematocrit(PCV) | 49.4 | % | 40-50 |
| Flow Cytometry | | | |
| MCV | 100.4 | fl | 83-101 |
| Calculated | | | |
| MCH | 31.6 | pg | 27-32 |
| Calculated | | | |
| MCHC | 31.5 | g/dL | 31.5-34.5 |
| Calculated | | | |
| RDW-CV | 13.9 | % | 11.4-14.0 |
| Calculated | | | |
| Platelet count | 159000 | /cumm | 150000-410000 |
| Electrical Impedance | | | |

BIOCHEMISTRY

| | | | |
|----------------------------------|-------|-------|--------------|
| Blood sugar fasting | 98 | mg/dl | 70-100 mg/dl |
| GOD-POD | | | |
| Blood sugar pp | 154 | mg/dL | 70.0-140.0 |
| GOD-POD | | | |
| Bun (blood urea nitrogen) | 10.20 | mg/dl | 8.9-21.6 |
| CALCULATED | | | |
| Uric acid, serum | 4.2 | mg/dl | 3.5-7.2 |
| Uricase- PAP | | | |
| Creatinine, serum | 0.60 | mg/dl | 0.60-1.2 |
| Enzymatic | | | |

LFT(LIVER FUNCTION TEST)

| | | | |
|----------------------------|------|-------|-----------|
| Bilirubin Total | 0.98 | mg/dl | 0.1-1.2 |
| Modified tab | | | |
| Bilirubin Conjugated | 0.40 | mg/dl | 0-0.4 |
| Diazotized sulfanilic acid | | | |
| Bilirubin Unconjugated | 0.58 | mg/dl | up to 0.7 |
| Calculated | | | |

Checked By.

Dr. NITIN AGARWAL
DR. NITIN AGARWAL
MBBS, MD(PATHOLOGIST)

47, Harsh Vihar, Pitampura, New Delhi-110034 | Ph.: 011-42480101, 9599913051

E-mail: oneplusul@gmail.com | Web.: www.oneplusul.in

Page 2 of 6



OnePLUS

Ultrasound Lab

Dr. Nitin Agarwal
Pathologist & Director
Ex. Sr. Res. MAMC
& Lok Nayak Hospital
Ex. Chief of Lab Dr. Lal Path Labs.

Dr. Pooja (Garg) Agarwal
Radiologist & Director
MAMC & Lok Nayak Hospital



| | | | |
|-------------|--|-------------------|----------------------|
| NAME | QUALITY FIRST... ALWAYS! :Mr. DHARAMBIR | Barcode No | :10149729 |
| AGE/GENDER | :33 YRS/Male | SPECIMEN DATE | :22/Jul/2023 09:35AM |
| PATIENT ID | :118072 | SPECIMEN RECEIVED | :22/Jul/2023 09:53AM |
| REFERRED BY | :Dr. MEDIWHEEL | REPORT DATE | :22/Jul/2023 04:40PM |
| CENTRE NAME | :ONEPLUS ULTRASOUND LAB | LAB NO. | :012307220013 |

| Test Name | Result | Unit | Ref. Range |
|--------------------------------------|--------|-------|-------------|
| SGOT (AST) Tris buffer | 89 | U/L | 0-46 |
| SGPT (ALT) Tris buffer | 208 | U/L | 0-49 |
| Alkaline phosphatase Amp buffer | 104 | U/L | 40-129 |
| GAMMA GT Szasz Method | 26 | U/L | 10-45 |
| Total Protein Biuret | 7.6 | gm/dl | 6.60 - 8.70 |
| Albumin serum BCG | 4.4 | g/dL | 3.0-5.2 |
| Globulin Calculated | 3.20 | gm/dl | 1.8-3.4 |
| Albumin/Globulin Ratio Calculated | 1.38 | | 1.10 - 2.50 |

LIPID PROFILE

| | | | |
|---|------|-------|--|
| Cholesterol CHOD-PAP | 276 | mg/dl | 50-200 |
| Triglycerides GPO-PAP | 262 | mg/dL | 25-150 |
| HDL Cholesterol Selective Inhibition | 58 | mg/dL | 40 - 60 |
| LDL cholesterol Calculated | 166 | mg/dL | <130 |
| VLDL cholesterol Calculated | 52.4 | mg/dL | 5-40 |
| Cholesterol/HDL Ratio Calculated | 4.8 | | Low Risk 3.3-4.97 Average Risk 4.4-7.1 Moderate Risk 7.1-11.0 High Risk >11.0 |
| LDL/HDL Ratio Calculated | 2.9 | | 0 - 3.55 |

According to ATP III and NCEP guidelines

| Parameter | Normal | Desirable | Borderline | High |
|-----------|--------|-----------|------------|------|
|-----------|--------|-----------|------------|------|

Checked By.

Dr. NITIN AGARWAL
MBBS, MD
Regn. No. DMC-1-1436
DR. NITIN AGARWAL
MBBS, MD (PATHOLOGIST)

47, Harsh Vihar, Pitampura, New Delhi-110034 | Ph.: 011-42480101, 9599913051
E-mail: oneplusul@gmail.com | Web.: www.oneplusul.in

Page 3 of 6

Clinical correlation is essential for final diagnosis. • If test results are unsatisfactory please contact personally or on phone. • This report is for perusal of doctors only. • All disputes Subject to Delhi Jurisdiction only. • Not for medicolegal purposes. • All congenital anomalies in a foetus may not be diagnosed in routine obstetric ultrasound.



OnePLUS Ultrasound Lab

Dr. Nitin Agarwal
Pathologist & Director
Ex. Sr. Res. MAMC
& Lok Nayak Hospital
Ex. Chief of Lab Dr. Lal Path Labs.

Dr. Pooja (Garg) Agarwal
Radiologist & Director
MAMC & Lok Nayak Hospital



| | | | |
|-------------|--|-------------------|----------------------|
| NAME | QUALITY FIRST... ALWAYS! :Mr. DHARAMBIR | Barcode No | :10149729 |
| AGE/GENDER | :33 YRS/Male | SPECIMEN DATE | :22/Jul/2023 09:35AM |
| PATIENT ID | :118072 | SPECIMEN RECEIVED | :22/Jul/2023 09:53AM |
| REFERRED BY | :Dr. MEDIWHEEL | REPORT DATE | :22/Jul/2023 04:40PM |
| CENTRE NAME | :ONEPLUS ULTRASOUND LAB | LAB NO. | :012307220013 |

| Test Name | Result | Unit | Ref. Range |
|-------------------|--------------------------------------|--------------------|------------|
| Total cholesterol | <200 | 200-239 | 240 |
| Triglycerides | <150 | 150-199 200-499 | 500 |
| LDL | Optimal <100 Near Optimal 100-129 | 130-159 160-180 | 190 |
| HDL | <40 : LOW 60 : HIGH | | |

BUN/Creatinine ratio

| | | | |
|--|-------|-------|-------------|
| UREA UREASE-GLDH | 22.00 | mg/dl | 15-45 |
| Bun (blood urea nitrogen) CALCULATED | 10.28 | mg/dl | 8.9-21.6 |
| CREATININE ENZYMATIC | 0.60 | mg/dl | 0.30-1.10 |
| BUN/Creatinine ratio CALCULATED | 17.13 | | 10.0 - 20.0 |

ENDOCRINOLOGY

THYROID PROFILE(T3,T4,TSH)

| | | | |
|--|------|--------|------------|
| Triiodothyronine total [t3] ECLIA | 0.58 | ng/dl | 0.52-1.9 |
| Thyroxine total [t4] ECLIA | 6.22 | µg/dl | 4.4 - 10.8 |
| TSH (Thyroid Stimulating Hormone) Enzyme linked fluorescent assay | 4.27 | µIU/ml | 0.25-5.0 |

AGE WISE VARIATION IN TSH

| AGE | TSH(µIU/ml) | AGE | TSH(µIU/ml) |
|-----------|-------------|----------------------------|-------------|
| 1-4 weeks | 1.00 - 19.0 | 16-20 yrs | 0.25 - 5.0 |
| 1-12 mths | 1.70 - 9.1 | 21 - 80 yrs | 0.25 - 5.0 |
| 1-5 yrs | 0.80 - 8.2 | I st trimester | 0.25 - 5.0 |
| 6-10 yrs | 0.25 - 5.0 | II nd trimester | 0.50 - 5.0 |
| 11-15 yrs | 0.25 - 5.0 | II rd trimester | 0.4 - 6.0 |

Checked By.

Dr. NITIN AGARWAL
DR. NITIN AGARWAL
MBBS, MD(PATHOLOGIST)

47, Harsh Vihar, Pitampura, New Delhi-110034 | Ph.: 011-42480101, 9599913051
E-mail: oneplusul@gmail.com | Web.: www.oneplusul.in

Page 4 of 6



OnePLUS Ultrasound Lab

Dr. Nitin Agarwal
Pathologist & Director
Ex. Sr. Res. MAMC
& Lok Nayak Hospital
Ex. Chief of Lab Dr. Lal Path Labs.

Dr. Pooja (Garg) Agarwal
Radiologist & Director
MAMC & Lok Nayak Hospital



| | | | |
|-------------|-------------------------|-------------------|----------------------|
| NAME | :Mr. DHARAMBIR | Barcode No | :10149729 |
| AGE/GENDER | :33 YRS/Male | SPECIMEN DATE | :22/Jul/2023 09:35AM |
| PATIENT ID | :118072 | SPECIMEN RECEIVED | :22/Jul/2023 09:53AM |
| REFERRED BY | :Dr. MEDIWHEEL | REPORT DATE | :22/Jul/2023 04:40PM |
| CENTRE NAME | :ONEPLUS ULTRASOUND LAB | LAB NO. | :012307220013 |

| Test Name | Result | Unit | Ref. Range |
|-----------|--------|------|------------|
|-----------|--------|------|------------|

Reference ranges - Interpretation of Diagnostic tests - (Jacques Wallach)

1. Primary hypothyroidism is accompanied by depressed serum T3 and T4 values and elevated serum TSH level.
2. Primary hyperthyroidism is accompanied by elevated serum T3 and T4 levels along with depressed TSH values.
3. Slightly elevated T3 levels may be found in pregnancy and estrogen therapy, while depressed levels may be encountered in severe illness, renal failure and during therapy with drugs like propranolol and propyl thiouracil.
4. Although elevated TSH levels are nearly always indicative of primary hypothyroidism, and may be seen in secondary thyrotoxicosis

CLINICAL PATHOLOGY

URINE ROUTINE (Strip/microscopy)

Physical examination

| | | |
|--------------------------------|-------------|-------------|
| Quantity | 20 | ML |
| Colour | PALE YELLOW | |
| Transparency | CLEAR | CLEAR |
| Sp.gravity BROMOTHYMOL BLUE | 1.015 | 1.010-1.030 |
| pH Double Indicators Test | 6.00 | |
| Reaction | ACIDIC | ACIDIC |

Chemical examination

| | | |
|--|----------|----------|
| Urine protein Protein Ionization | NIL | NIL |
| Urine sugar Oxidation Reaction | NIL | NIL |
| Bilirubin, urine | NEGATIVE | NEGATIVE |
| Urobilinogen P-Aminobenzoic Acid and Phenazopyridine Reaction | NORMAL | NORMAL |
| Ketones Acetoacetate and Dichlorobenzene Reaction | NEGATIVE | NEGATIVE |

Microscopic examination

| | | | |
|--------------------------------|-----|------|-----|
| Pus cells. Microscopy | 1-2 | /HPF | 0-2 |
| Epithelial cells Microscopy | 0-1 | /HPF | NIL |
| R.B.C. | NIL | /HPF | NIL |

Checked By.

Dr. NITIN AGARWAL
DR. NITIN AGARWAL
MBBS, MD(PATHOLOGIST)
Regn. No. [Signature]

47, Harsh Vihar, Pitampura, New Delhi-110034 | Ph.: 011-42480101, 9599913051

E-mail: oneplusul@gmail.com | Web.: www.oneplusul.in

Page 5 of 6



OnePLUS Ultrasound Lab

Dr. Nitin Agarwal

Pathologist & Director
Ex. Sr. Res. MAMC
& Lok Nayak Hospital
Ex. Chief of Lab Dr. Lal Path Labs.

Dr. Pooja (Garg) Agarwal

Radiologist & Director
MAMC & Lok Nayak Hospital



| | | | |
|-------------|--|-------------------|----------------------|
| NAME | QUALITY FIRST... ALWAYS! :Mr. DHARAMBIR | Barcode No | :10149729 |
| AGE/GENDER | :33 YRS/Male | SPECIMEN DATE | :22/Jul/2023 09:35AM |
| PATIENT ID | :118072 | SPECIMEN RECEIVED | :22/Jul/2023 09:53AM |
| REFERRED BY | :Dr. MEDIWHEEL | REPORT DATE | :22/Jul/2023 04:40PM |
| CENTRE NAME | :ONEPLUS ULTRASOUND LAB | LAB NO. | :012307220013 |

| Test Name | Result | Unit | Ref. Range |
|------------|--------|------|------------|
| Microscopy | | | |
| Casts | NIL | /HPF | NIL |
| Microscopy | | | |
| Crystals | NIL | /HPF | NIL |
| Microscopy | | | |
| Bacteria | NIL | /HPF | NIL |
| Microscopy | | | |
| Others. | NIL | NIL | NIL |

*** End Of Report ***

Checked By.

Dr. NITIN AGARWAL
DR. NITIN AGARWAL
MBBS, MD (PATHOLOGIST)
Regn. No. DMC

47, Harsh Vihar, Pitampura, New Delhi-110034 | Ph.: 011-42480101, 9599913051

E-mail: oneplusul@gmail.com | Web.: www.oneplusul.in

Page 6 of 6

| | | | |
|---------|-----------------|------------|----------------|
| Name | : Mr. DHARAMBIR | Age/Sex | : 33 YRS/Male |
| Ref. By | : Dr. MEDIWHEEL | Lab No | : 012307220013 |
| Date | : 22-Jul-2023 | Patient ID | : LSHHI118072 |

ULTRASOUND EXAMINATION----WHOLE ABDOMEN

Liver is normal in size (13.4 cm) and normal in outline with **altered echopattern. Diffuse increase in echogenicity of liver parenchyma is noted, suggestive of fatty infiltration (grade I).** Intrahepatic biliary radicles are not dilated. No abscess or mass lesion seen. Hepatic veins, portal vein, IVC and aorta are normal. CBD is normal in caliber.

Gall bladder is well distended with anechoic lumen. Wall thickness is normal.

Both kidneys are normal in size, shape, position, outline and echopattern. Corticomedullary differentiation is maintained. No pelvicalyceal dilation or mass lesion is seen.

Spleen is normal in size and echotexture. No mass lesion seen.

Pancreas is normal in size, outline and echotexture.

Urinary bladder is normal in shape and position. No evidence of intravesical stone or mass seen.

Prostate is normal in size, shape and echopattern.

Prostate measures 3.3 x 2.9 x 2.6 cm. **Weight of prostate is 13.3 grams.**

No abnormal bowel wall thickening seen in right iliac fossa.

No free fluid seen anywhere in abdomen.

IMPRESSION:

- **Fatty infiltration of liver (grade I) with no hepatomegaly.**

DR. POOJA GARG
RADIOLOGIST

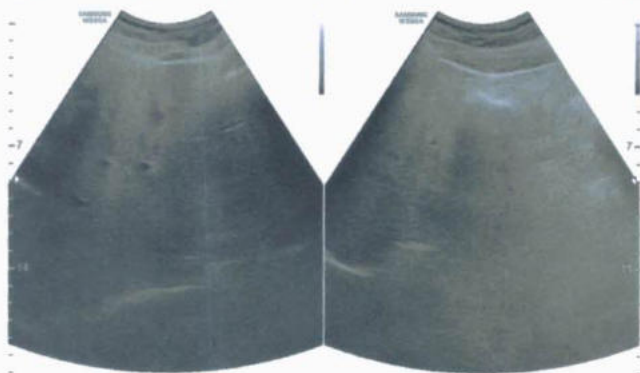
Dr. POOJA GARG
M.B.B.S., D.M.R.D
Reg No. DMC/R/03398
Radiologist

Type By : darshita

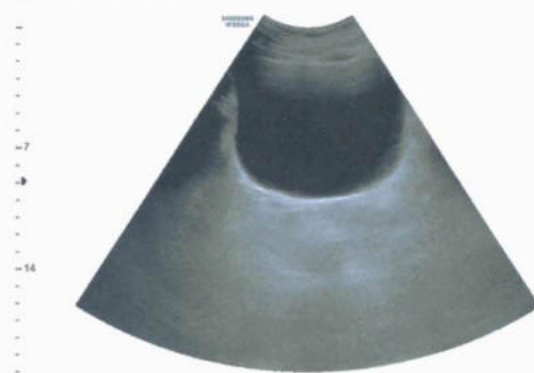
47, Harsh Vihar, Pitampura, Delhi-34 ☎ 011-4248 0101, 9599913051
✉ Email: oneplusul@gmail.com 🌐 www.oneplusul.in

• Clinical correlation is essential for final diagnosis. • If test results are unsatisfactory please contact personally or on phone.
• All disputes are subject to Delhi jurisdiction only. • Not for medico legal case. • All congenital anomalies in...

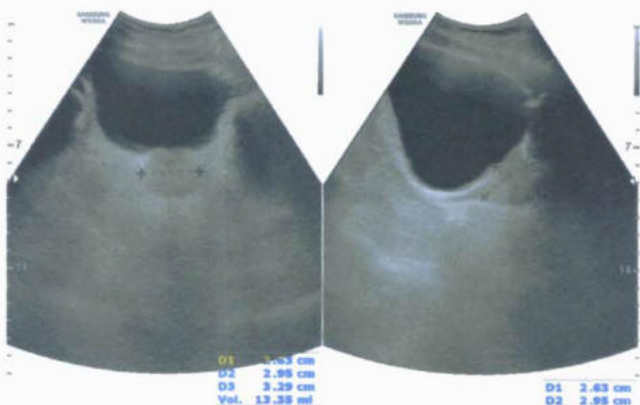
MR DHARAMBIR 33/M
OnePlus Ultrasound Lab MI 1.4 22-07-2023
CA1-7A / Abdomen / FR 21Hz Tls 0.1 12:13:00 PM
Q56 DR135-FAB P90 Frq Gen. 20 Dcm



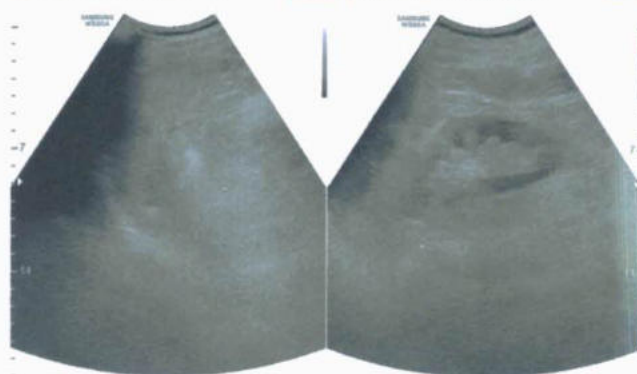MR DHARAMBIR 33/M
OnePlus Ultrasound Lab MI 1.4 22-07-2023
CA1-7A / Abdomen / FR 21Hz Tls 0.1 12:13:03 PM
Q56 DR135-FAB P90 Frq Gen. 20 Dcm



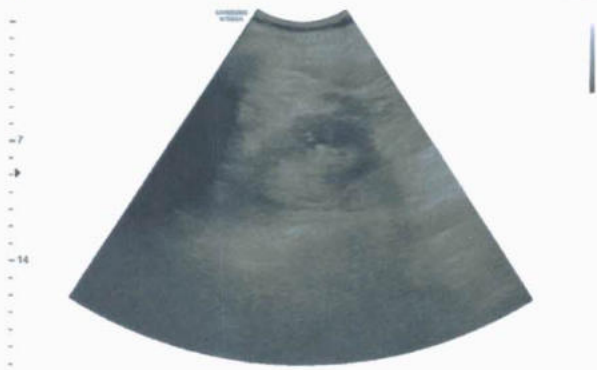MR DHARAMBIR 33/M
OnePlus Ultrasound Lab MI 1.4 22-07-2023
CA1-7A / Abdomen / FR 21Hz Tls 0.1 12:13:17 PM
Q56 DR135-FAB P90 Frq Gen. 20 Dcm



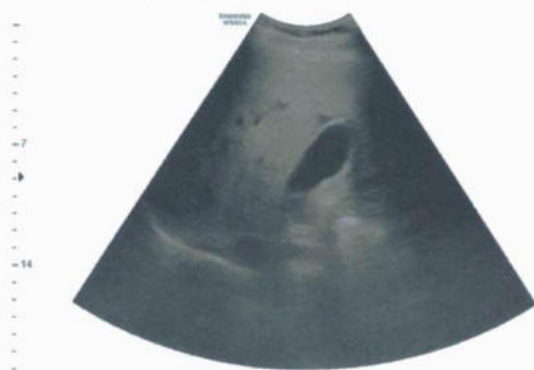MR DHARAMBIR 33/M
OnePlus Ultrasound Lab MI 1.4 22-07-2023
CA1-7A / Abdomen / FR 21Hz Tls 0.1 12:13:31 PM
Q61 DR135-FAB P90 Frq Gen. 20 Dcm



MR DHARAMBIR 33/M
OnePlus Ultrasound Lab MI 1.4 22-07-2023
CA1-7A / Abdomen / FR 21Hz Tls 0.1 12:13:48 PM
Q57 DR135-FAB P90 Frq Gen. 20 Dcm



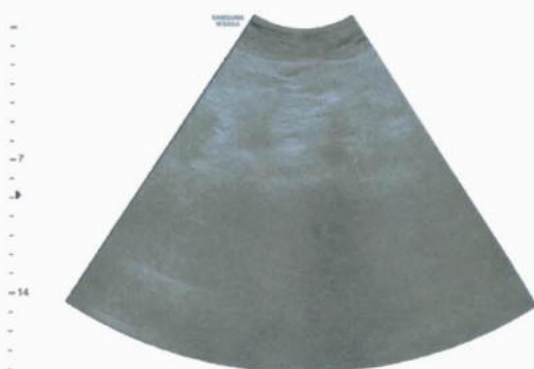MR DHARAMBIR 33/M
OnePlus Ultrasound Lab MI 1.4 22-07-2023
CA1-7A / Abdomen / FR 21Hz Tls 0.1 12:13:57 PM
Q57 DR135-FAB P90 Frq Gen. 20 Dcm





MR DHARAMBIR 33/M
OnePlus Ultrasound Lab MI 1.4 22-07-2023
CA1-7A / Abdomen / FR 21Hz Tls 0.1 12:14:13 PM
Q61 DR135-FAB P90 Frq Gen. 20 Dcm



MR DHARAMBIR 33/M
OnePlus Ultrasound Lab MI 1.4 22-07-2023
CA1-7A / Abdomen / FR 21Hz Tls 0.1 12:15:06 PM
Q62 DR135-FAB P90 Frq Gen. 18 Dcm



D1 13.42 cm





OnePLUS
Ultrasound Lab
— QUALITY FIRST... ALWAYS! —

Dr. Nitin Agarwal

Pathologist & Director
MBBS MD (Pathology)
Ex. Sr. Res. MAMC & Lok Nayak Hospital
Ex. Chief of Lab Dr. Lal Path labs.

Dr. Pooja (Garg) Agarwal

Radiologist & Director
MBBS (MAMC) DMRD (MAMC)
Imaging Expert In Fetal And Maternal Medicine,
University of Barcelona, Spain
Fetal Medicine Foundation (UK) Accreditation

Name : Mr. DHARAMBIR
Ref. By : Dr. MEDIWHEEL
Date : 22-Jul-2023

Age/Sex : 33 YRS/Male
Lab No : 012307220013
Patient ID : LSHHI118072

X-ray-Chest PA view

Bony cage and soft tissues are normal.
Cardiothoracic ratio is normal.
Mediastinum is normal.
Both hila are normal.
Both costophrenic angles are clear.
Both domes of diaphragm are normal.
Lung fields are clear. No parenchymal lesion seen.

IMPRESSION: Normal Study.


DR. POOJA GARG
M.B.B.S., D.M.D.
Reg No. DMC/R/03398
Radiologist

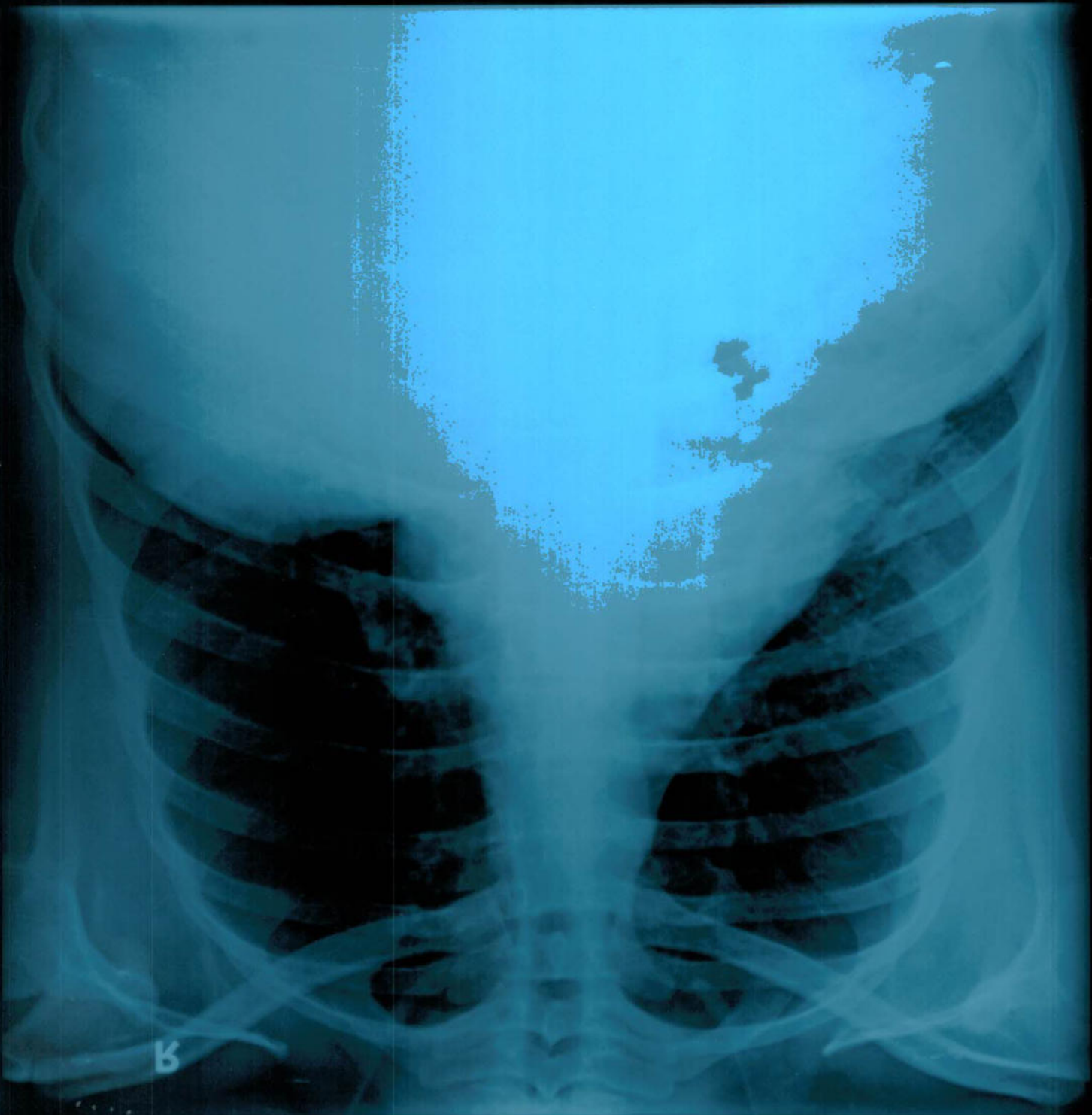
Type By: POOJA

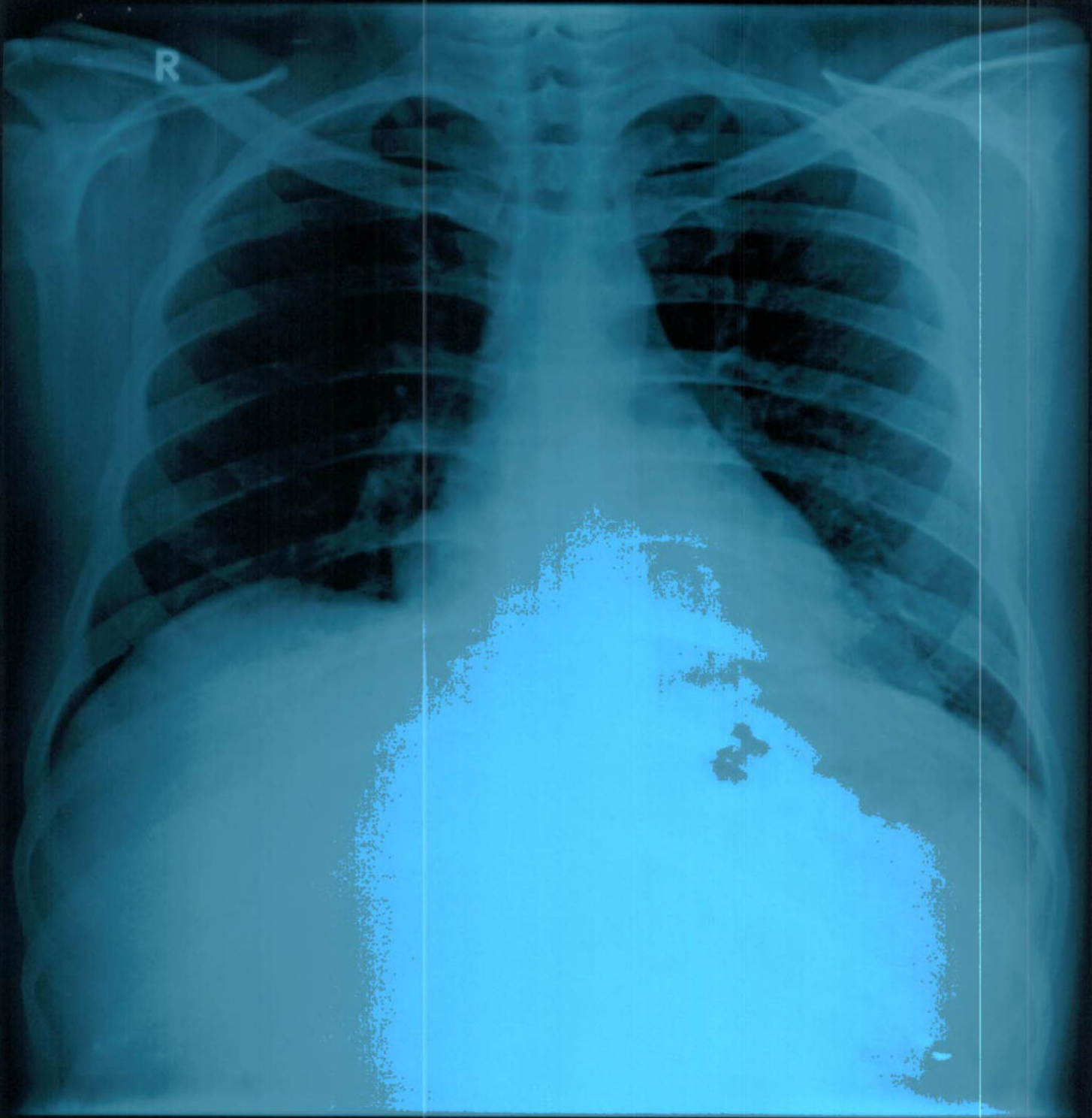
47, Harsh Vihar, Pitampura, Delhi-34 ☎ 011-4248 0101, 9599913051
Email: oneplusul@gmail.com www.oneplusul.in

Diagnosis. • If test results are unsatisfactory please contact personally or on phone. • This report is for perusal of doctors only.
• Not for medico legal case. • All congenital anomalies in a foetus may not be diagnosed in routine obstetric ultrasound.



ОИЕБГУС УГТРАСОДИО ГАР АТ-НАРГН АИНАР РИТАМЬУКА
МР ДНАРМВІР АСЕ 33-82 33-01-3030 М. СРЕСТРА ВІЕМ





MR DHARMBIR AGE 33 YRS 22-07-2023 M CHEST PA VIEW
ONEPLUS ULTRASOUND LAB. 47-HARSH VIHAR PITAMPURA