



 GPS Map Camera

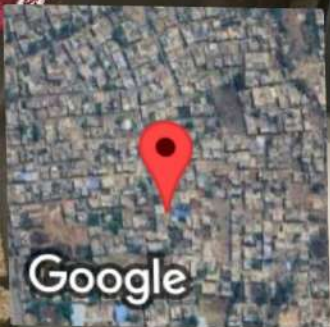रायपुर, छत्तीसगढ़, भारत

6J6W+C64, कृष्णा नगर, संतोषी नगर, रायपुर, मथुरेना, छत्तीसगढ़ 492001, भारत

Lat 21.211134°

Long 81.645617°

14/09/24 09:40 AM GMT +05:30





भारत सरकार

Government of India

विलियम एक्का

William Ekka

पिता : सिरील एक्का

Father : SIRIL EKKA

जन्म तिथि / DOB : 01/03/1962

पुरुष / Male



9425 6749 9389

आधार - आम आदमी का अधिकार



भारतीय विशिष्ट पहचान प्राधिकरण

Unique Identification Authority of India

पता:

S/O: सिरिल एक्का, टी-47/ए, सेक्टर
१ एक्स्टेंशन, अवंती विहार, वार्ड न-28,
तेलीबांधा, रविग्राम, रायपुर,
छत्तीसगढ़, 492006

Address:

S/O: Ciril Ekka, T-47/A, SECTOR
1 EXTENSION, AVANTI VIHAR,
ward NO-28, Telibandha,
Ravigram, Raipur, Chhattisgarh,
492006

9425 6749 9389



1947

1800 300 1947



help@uidai.gov.in

WWW

www.uidai.gov.in

A Unit of Diagnostic Care with Trust

श्री साई एडवांस इमेजिंग एंड डायग्नोस्टिक सेंटर

PVT.LTD.

हर जीवन  अमूल्य हैपुराना धमतरी रोड, सब्जी बाजार के सामने,
संतोषी नगर, रायपुर (छ.ग.) ☎ 0771-4023900

MRI | CT Scan | 4D Color USG | Digital X-Ray | Advance Pathology | 2D Echo / E.C.G. / TMT / E.E.G. / OPG / SPIRO

DATE- 14-Sep-24

PATIENT NAME MR. WILLIAM EKKA
AGE/SEX 62 YEAR / MALE
REF. BY BANK OF BARODA

SONOGRAPHY OF THE ABDOMEN

PROCEDURE DONE BY ULTRASOUND MACHINE Canon Apllo a450 (4D COLOR DOPPLER)

LIVER : The liver is normal in size, shape & contour with normal echotexture. No evidence of any Focal lesion or mass seen. The intrahepatic biliary ducts are normal. The CBD is normal in course, caliber & contour. Hepatic & portal vein appear normal in morphology.

GALL BLADDER : Appears normal distended. No obvious intraluminal calculus is seen.

PANCREAS : It is normal echogenicities and size, shape. Pancreatic duct is normal.

SPLEEN : Spleen is normal size, shape and position. No focal lesion seen.

KIDNEY : Right kidney measures 10.6 x 3.9 cm.
Left kidney measures 9.8 x 4.0 cm.
Both Kidneys are normal size, shape and position.
Renal parenchymal echogenicities are normal.
No evidence of any calculus or pelvicalyceal dilation.

URINARY BLADDER: UB is well distended with normal wall thickness. No evidence of mass /calculus.

PROSTATE : It is normal in size ~ 3.5 x 3.3 x 3.4 cm & vol 21.5 cc, shape & smooth outlines.

RETRO PERITONEUM : No evidence of lymphadenopathy / mass.

FREE FLUID : No free fluid seen in abdomen & peritoneal cavity.

IMPRESSION:

- NO SIGNIFICANT ABNORMALITY DETECTED

Needs clinical correlation & other investigations.


Dr. Hulesh Mandle, MD
Consultant Radiologist

Kindly Note:-

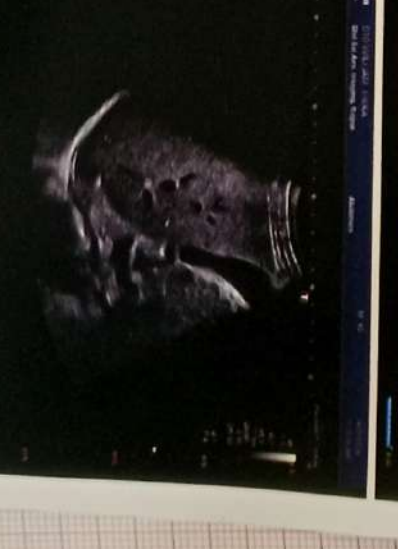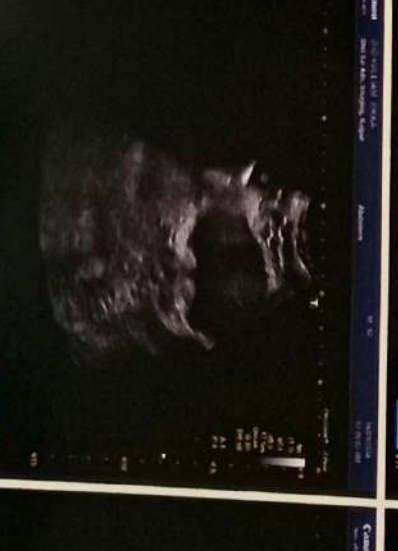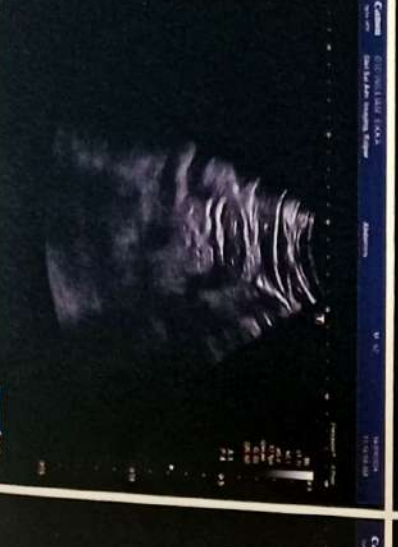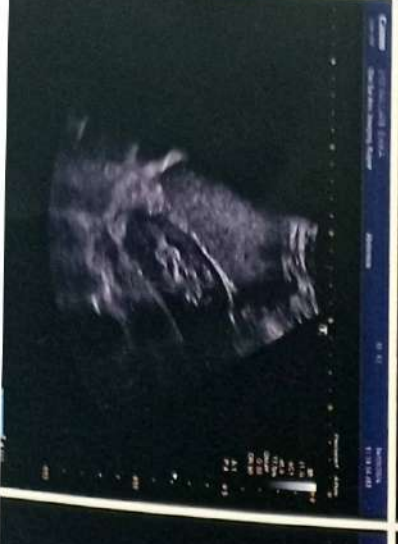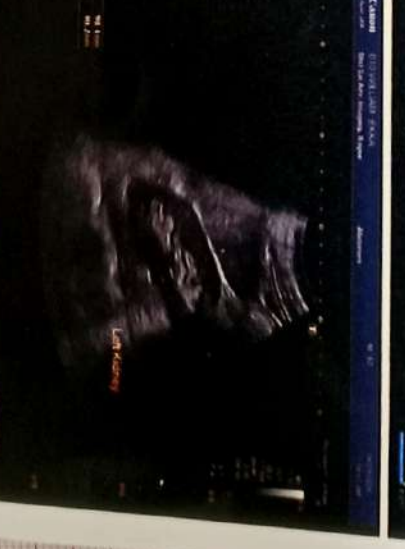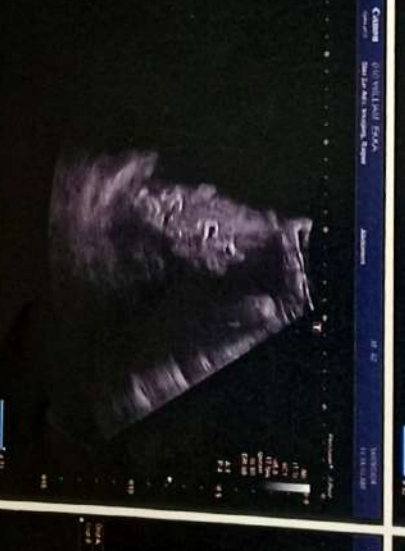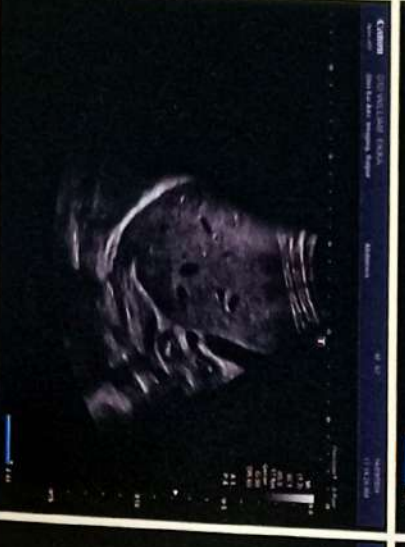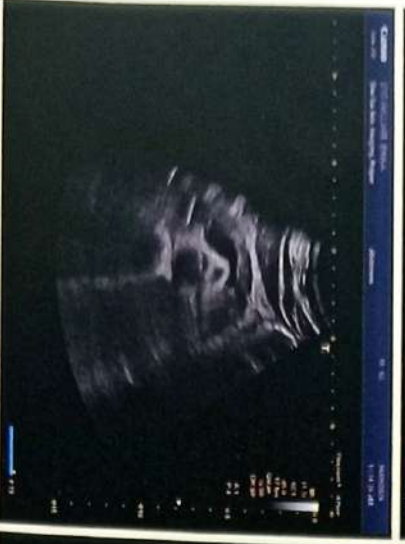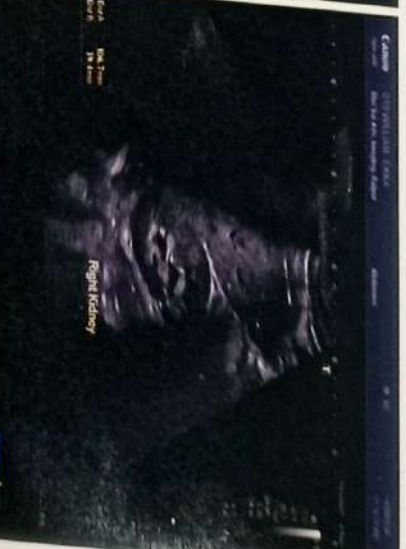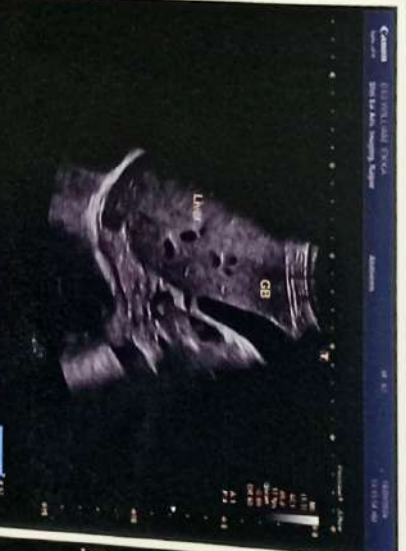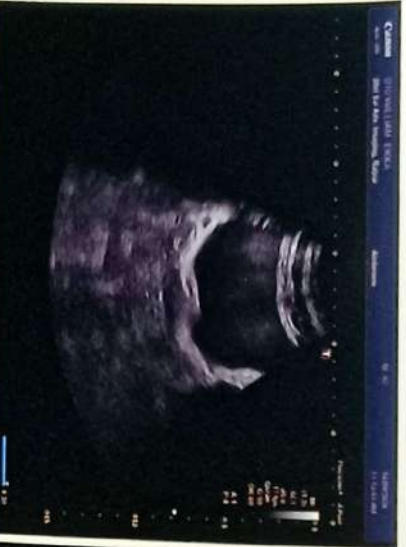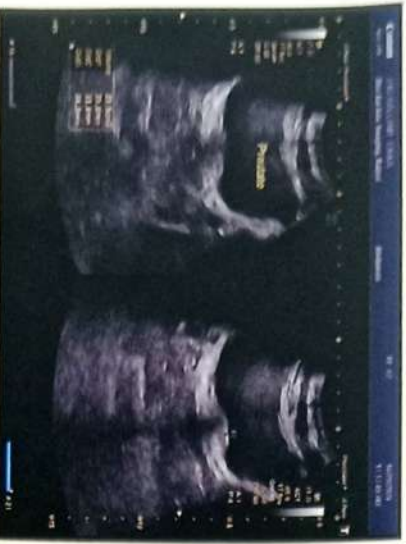- The report and films are not valid for medico – legal purpose.
- Please Intimate us if any typing mistakes and send the report for correction within 7 days.
- कृपया अगली बार जांच के लिए आने पर पुराना रिपोर्ट साथ में लावे ।

सही जाँच ही सही ईलाज का आधार है..

Email : shrisaiimaging@gmail.com, Website : www.shrisaidiagnostic.com

14 Sep 2024 Study : Abdomen
Name : WILLIAM EKA 062Y / M

SHRI SAI ADVANCE IMAGING & DAIGNOSTIC CENTER, SANTOSHI NAGAR



सभ्यता डेन्टल केयर SABHYATA DENTAL CARE



डॉ. घनश्याम राव सहारे
बी.डी.एस. (GDC Raipur)
(दंत रोग विशेषज्ञ)
मो. 6232195768
Regd. No. CGDC/12/G/1126

उपलब्ध सुविधाएँ :

दांतों की सफाई

दर्द रहित दांत निकालना

दांतों में मसाला भरना

पायरिया का ईलाज

दांतों के जड़ का ईलाज (R.C.T.)

दांतों के बीच गेप भरना

बच्चों के सड़े दांतों का ईलाज

बत्तीसी बनवाना

फिक्स दांत बनवाना

दांतों में कैप लगवाना

टेढ़े मेढ़े दांतों का ईलाज

मुंह के कैंसर का ईलाज

एक्स-रे सुविधा

आपात एवं दुर्घटना उपचार

Rx Williams Ikk a ,

Date 14/9/24

o/c - pt % sensitivity of food lodgement.

o/c -

PDH - RCT 35, 36, 45

PMH - NRH. • Habit - NRH.

o/c - Generalised Attrition.

(Rx)

Toothpaste Sensodyne.

Miw Sensodyne.





रामकथा

आँख, कान, नाक, गला एवं मल्टीस्पेशियलिटी हॉस्पिटल

24 घंटे आपातकालीन चिकित्सा सेवा उपलब्ध

MR. WILLIAM

Age sex - 62 y/m

no Routine
checkup
ENT

DATE
14/09/24

Both eardrums - clear Tympanic membrane - Normal

Quality - NAD

NOH clear Both.

Neck - clear

Clinically - NAD. ENT

S. G. G.

ENT
fw R + w
→ w ←
© ENT ©

Patient:

MR WILLIAM EKA

62 year / M

..... cm / kg

HR 57/min

Axis: P 61°

SINUS RHYTHM
T ABNORMALITY IN ANTERIOR LEADS

UNCONFIRMED REPORT

QRS 69°

T 48°

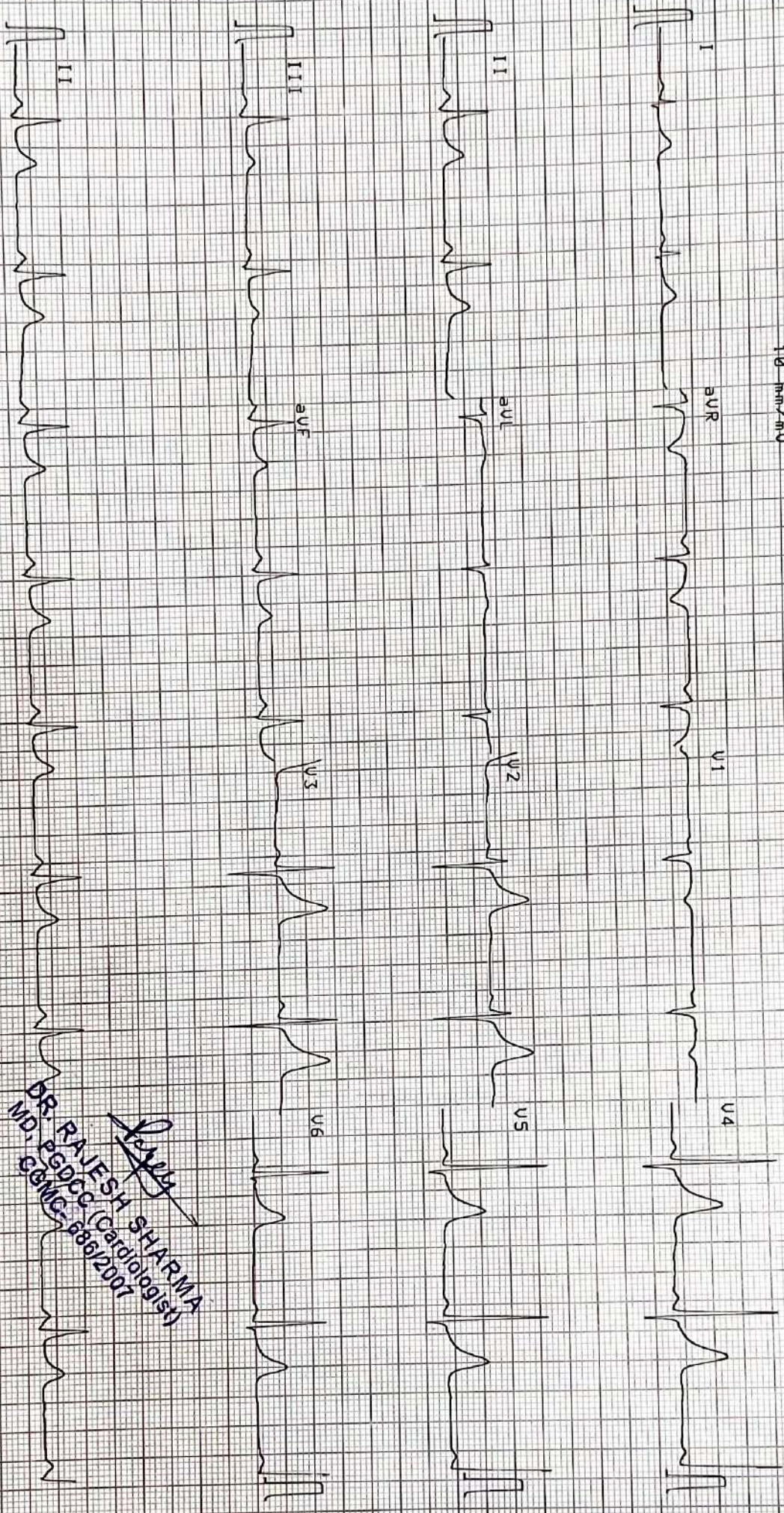
5.62

Intervals:

RR	1055 ms	P (II)	0.16 mV
P	124 ms	S (V1)	-0.48 mV
PR	142 ms	R (V5)	2.05 mV
QRS	88 ms	Sokol.	5.17 mV
QT	414 ms		
QTc	406 ms		

10 mm/mV

10 mm/mV



Rajesh
DR. RAJESH SHARMA
 MD, PGDCC (Cardiologist)
 GMC-886/2007

[Signature]
 14.9.14

25 mm/s
 0.05=35Hz F50 SF 585 Fr 15-SEP-24 22:06:07 RT-2PIUS 4.14 (C) SCHILLER AG AF-2PIUS 4.14 CM

DATE- 14-Sep-24

PATIENT NAME MR. WILLIAM EKKA
AGE/SEX 62 YEAR / MALE
REF. BY BANK OF BARODA

X-RAY CHEST PA VIEW

Observation & Impression

- Bilateral lung fields are clear.
- Both costophrenic angles are normal.
- Bilateral hila are normal.
- The cardiac shadow is normal.
- The bony thorax is normal.

IMPRESSION No significant abnormality is seen.

Needs clinical correlation & other investigations.


Dr. Hulesh Mandle, MD
Consultant Radiologist

Investigations have their limitation, solitary radiological / pathological and other investigations never confirm the final diagnosis of disease. They only help in diagnosing the disease in correlation to symptom and other related test please interpret accordingly.

Note-

1. The report & film are not valid for medico-legal purpose.
2. Please intimate us if any typing mistakes & send the report for correction within 7 days.



DATE-14-Sep-24

PATIENT NAME	MR. WILLIAM EKKA
AGE/SEX	62 YEAR / MALE
REF. BY	BANK OF BARODA

COLOUR DOPPLER ECHOCARDIOGRAPHY

PROCEDURES: M-MODE/2D/DOPPLER/COLOUR/CONTRAST.

MEASUREMENTS:

AO	~	3.2 CMS
LA	~	3.4 CMS.
LVDd	~	3.9 CMS.
LVDs	~	2.3 CMS.
IVSd	~	1.2 CMS.
LVPWd	~	1.2 CMS.

DOPPLER

E	~	0.53 M/SEC.
A	~	0.64 M/SEC.
AO	~	0.99 M/SEC.

- NORMAL LV AND RV SIZE AND FUNCTION.
- NORMAL PERICARDIUM. NO PERICARDIAL EFFUSION.
- NORMAL PA & AORTA.

OPINION:-

- ☞ MILD LVH.
- ☞ GRADE -I DIASTOLIC DISFUNCTION.
- ☞ NORMAL CHAMBER SIZE.
- ☞ NO RWMA.
- ☞ GOOD LV SYSTOLIC FUNCTION.
- ☞ EF 60%
- ☞ NO CLOT/MASS



DR. SAWAN AGRAWAL
(MBBS, MD, DNB Cardiology)

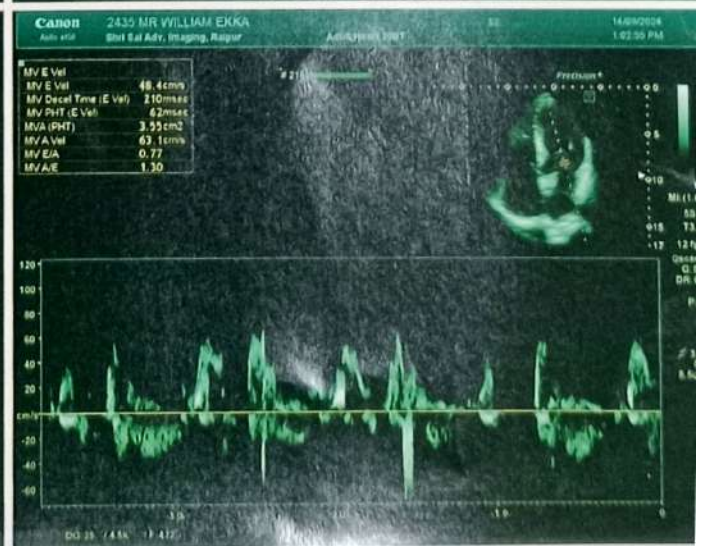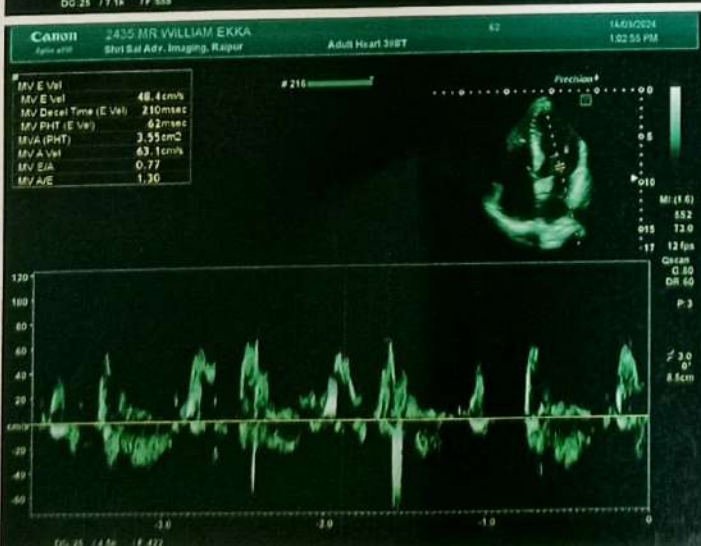
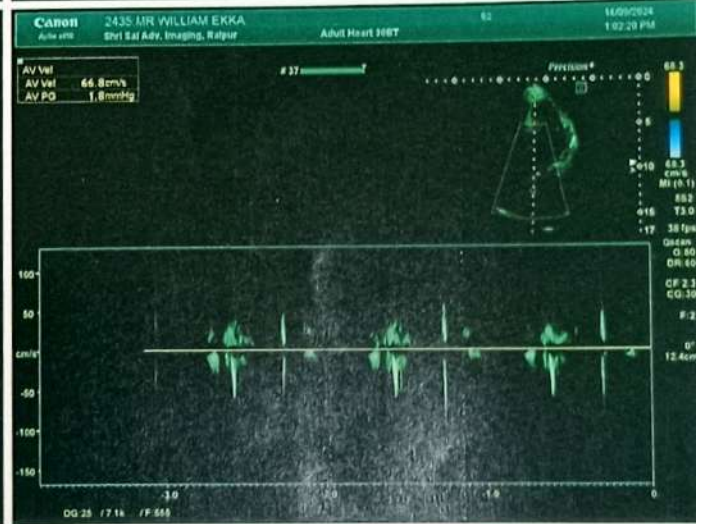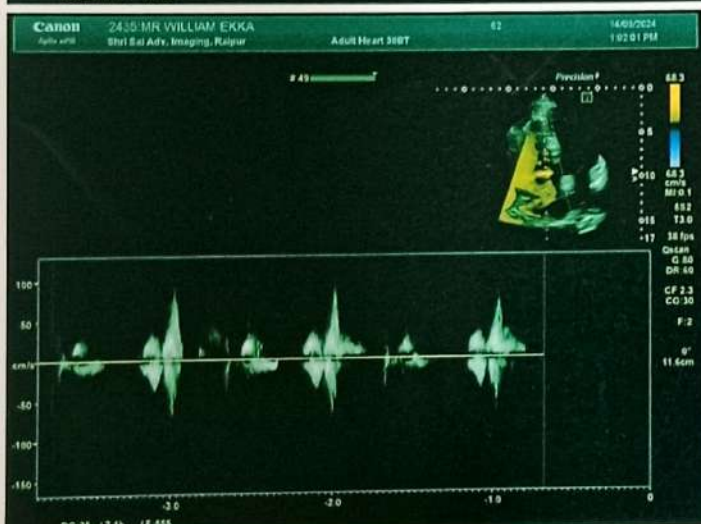
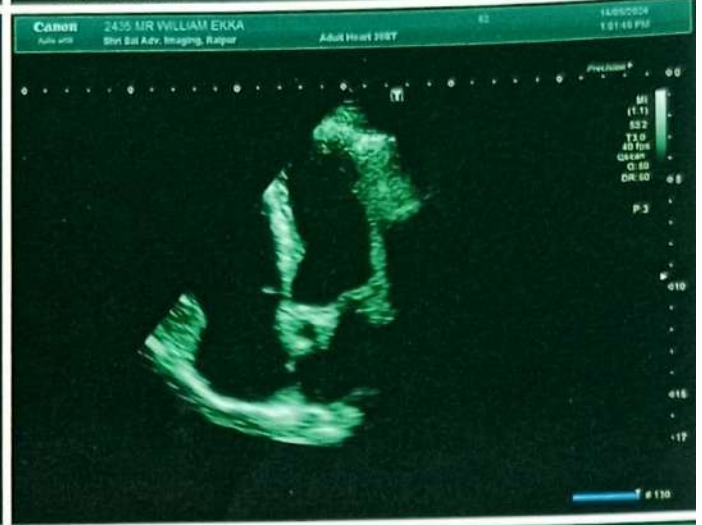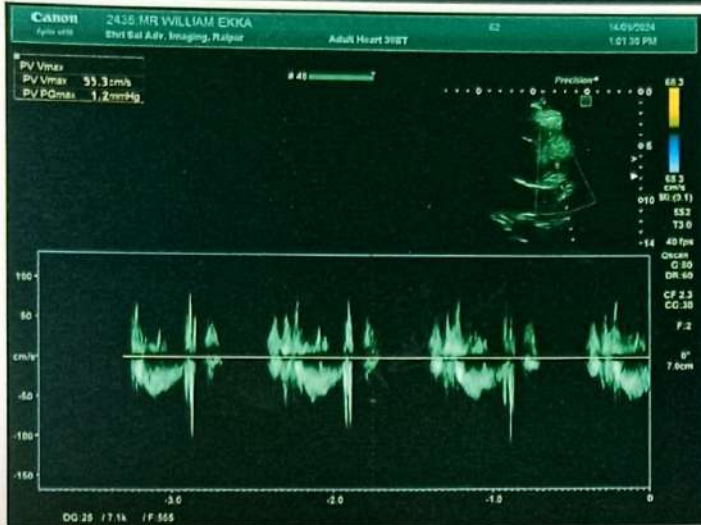
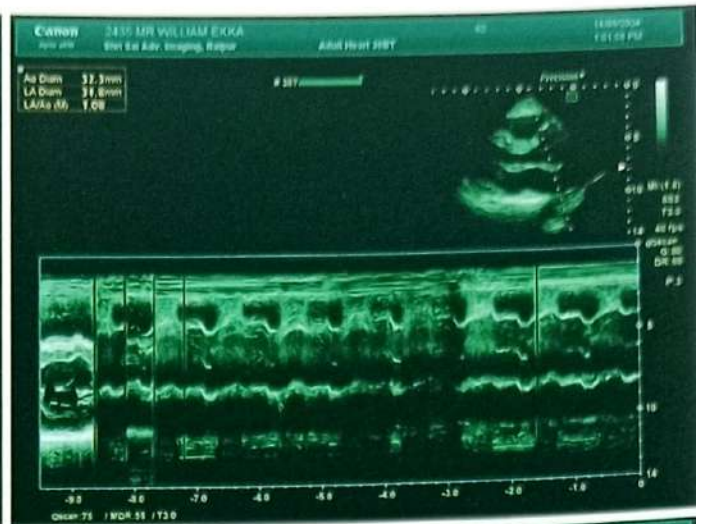
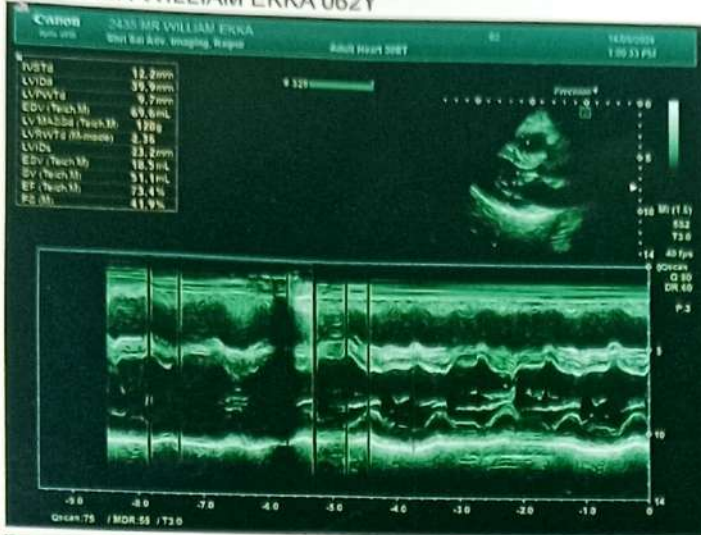
Investigations have their limitation, solitary radiological / pathological and other investigations never confirm the final diagnosis of disease. They only help in diagnosing the disease in correlation to symptom and other related test please refer accordingly.

Advance Imaging & Diagnostic Center
Shri Sai Imaging & Diagnostic Center
Radha Raipur (C.G.)
Address: Near G. Market, Krishna Nagar,
Raipur (C.G.)

सही जाँच ही सही ईलाज का आधार है...

SHRI SAI ADVANCE IMAGING & DAIGNOSTIC CENTER, SANTOSHI NAGA R

14 Sep 2024 Study : Abdomen
Name : MR WILLIAM EKKA 062Y



MRD No **DJE10819**

Patient : MR.VILLIAM EKKA / male / 62Yr(s)

Address: AVANTI VIHAR

Contact Number : 9406122518

Date : 14-09-2024 03:01 PM

Presenting Complaint: ROUTINE CHECK UP

Eye	Distance vision			Near vision	
	UCDVA	BCDVA	PH	UCNVA	BCNVA
Right	6/24				
Left	6/24P				

IOP:
DateTime: 14-09-2024 02:57 PM
NCT
10
10

Prescription
Spectacle Correction:

	Right Eye				Left Eye			
	SPH	CYL	AXIS	V/A	SPH	CYL	AXIS	V/A
D.V	+1.75			6/6	+1.75			6/6
N.V	+4.25			N6	+4.25			N6
Add	2.5				2.5			

Examination:

Eye Parts	Right Eye	Left Eye
ANTERIOR SEGMENT	NORMAL	NORMAL
POSTERIOR SEGMENT	NORMAL	NORMAL

Diagnosis:

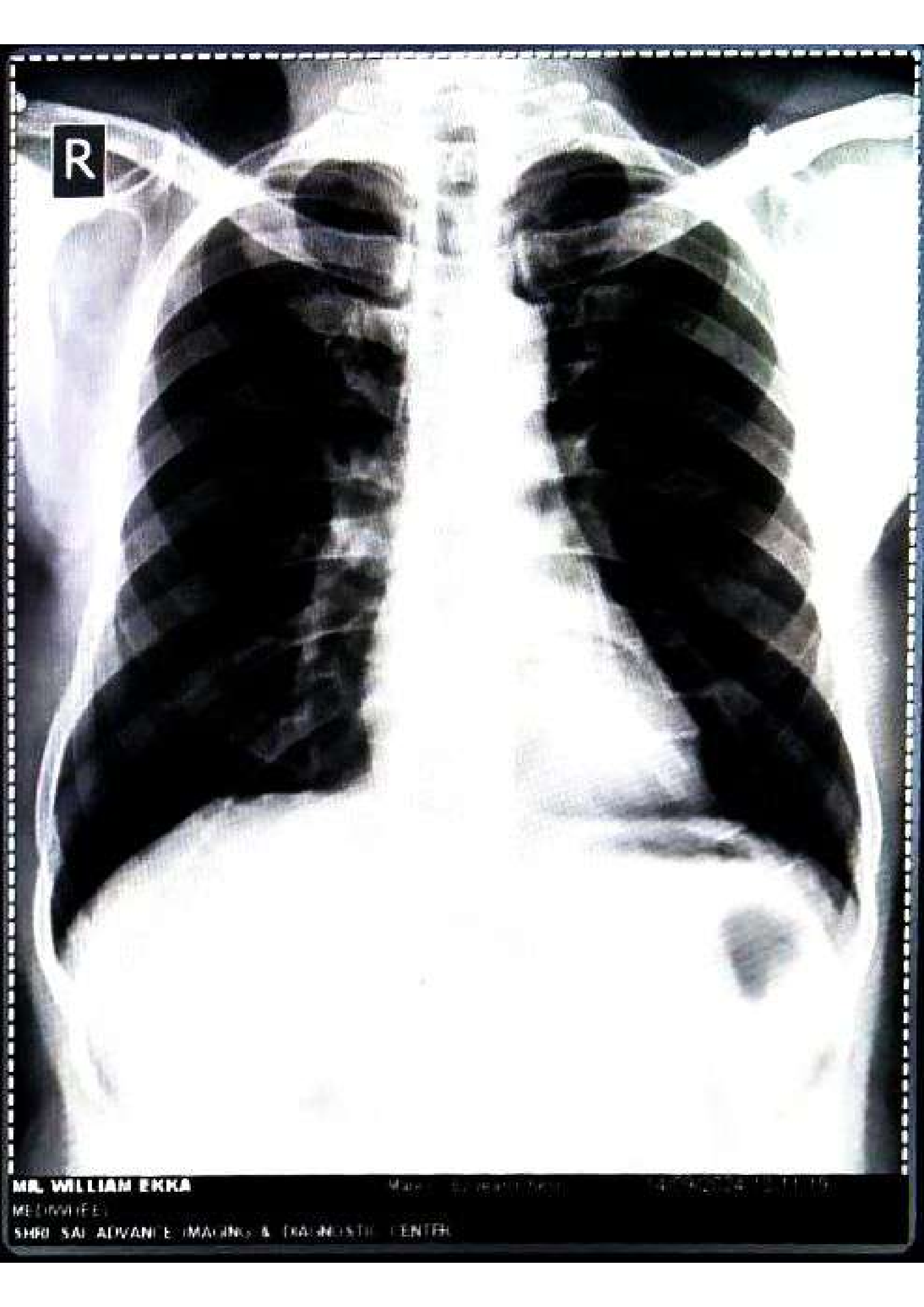
BothEyes-REFRACTIVE ERROR

Prescription:

- [LUBRISKY Eye Drops] (1)
Both Eyes- 4 TIMES A DAY (1drop---1drop---1-drop---1drop) , 7 Day(s)
- (CHLORAMPHENICOL & POLYMYXIN - B SULPHATE & DEXMET) [POLYSPORIN DEXA Eye Ointment] (1)
Both Eyes- Once in a day @ night , 7 Day(s)



DR DINESH (CGMC/862/2007)



R

MR. WILLIAM EKKA

MEDICAL OFFICER

SHRI SAI ADIVANI'S IMAGING & TRAUMATOLOGY CENTER

Male - 92 years old

14/06/2024 12:11:19