



PRE – EMPLOYMENT HEALTH CHECK UP REPORT

DATE - 12/11/2022

PATIENT NAME - Mrs. Lata Parmar AGE - 30y / F GENDER -

WEIGHT(KG) - 56.1 kg HEIGHT - 157 cm

PHYSICAL EXAMINATION

PULSE 70

BP - 100/60

BLOOD SUGAR(RANDOM)

FINDINGS

INVESTIGATIONS : Investigation reports are attached

FITNESS CERTIFICATE



SIGNATURE

(This is only professional opinion and not the diagnosis, Please correlate clinically)

Q Block South City 11, Sohna Road, Main Sector-47, Gurgaon, Haryana
Ph.: 0124-4900000 (100 Lines) Fax : 0124-2218733 E-mail : parkmedicenters@gmail.com

PARK GROUP OF HOSPITALS : West Delhi • South Delhi • Gurgaon • Karnal • Panipat • Hodal • Ambala • Behror

the **health** care providers

the **health** care providers





Park Hospital

GROUP SUPER SPECIALITY HOSPITAL



MRS. LATA

12/11/12

30-1/R

BCG
NUR

BP - 120/80

P - 80/min.

No fresh coughing.

By - Ravi Report

Dr. Anil Singh
MBBS, DNB
General Medicine
2000-01-12-2010



(This is only professional opinion and not the diagnosis, Please correlate clinically)

Q Block South City 11, Sohna Road, Main Sector-47, Gurgaon, Haryana

Ph.: 0124-4900000 (100 Lines) Fax : 0124-2218733 E-mail : parkmedicenters@gmail.com

PARK GROUP OF HOSPITALS : West Delhi • South Delhi • Gurgaon • Karnal • Panipat • Hodal • Ambala • Behror

the health care providers

the health care providers





Lata / 39y / F.

12/11/2022
12:20 PM

• Delayed menses - 3 cycles.
(10 days delay).

Vitals :

Chief Complaints :

LMP - 9/10/2022

PMH - 2-3 days (3m)
32-33 days.

H/O Present Illness :

OH - 3 RTND - LCB - 8y.
Past History: 4th 5th - MTP - Medical.
Mod / S / H - NAD

Past Mens H/O

2-3 days (N) flow.
23-24 days.

Investigation :

Drug Allergies : (if any)

Husband vasectomy done.

Treatment :

PS - Thick serous discharge @
Cervical erosion @ on
posterior lip. of Cx.
PV → ut AV, (N) size
B/Lhs free, NT

Adv

✓ TFT - BHC G
S. FSH - S. prolactin

• USG pelvis TVS
gynae.

• S. PRL

• pap smear ✓ Taken.

• FBS

Adv

Vag Tab Clingen forte - NS
PV 100mg - 6 night

• Top Doxycycline 100mg
7 days



Gurgaon

Plot No. 11, South City 11, Sohna Road, Main Sector-47, Gurgaon, Haryana Ph.: 0124-4900000 Fax : 0124-2218733
E-mail : parkmedicenters@gmail.com

• West Delhi • South Delhi • Faridabad • Panipat • Karnal



Vitals :

Chief Complaints :

routine dental checkup

H/O Present Illness :

o/e Caries in 6/6

Past History :

Investigation :

Drug Allergies : (if any)

Advs

Composite restorations in 36, 46

Treatment :



Gurgaon

Q Block South City 11, Sohna Road, Main Sector-47, Gurgaon, Haryana Ph.: 0124-49000000 Fax : 0124-2218733
E-mail : parkmedicenters@gmail.com

● West Delhi ● South Delhi ● Faridabad ● Panipat ● Karnal

the **health** care providers

the **health** care providers





12/11/22

S/B Dermatology

Vitals :

Chief Complaints :

pt. has no skin complaints
at present

H/O Present Illness :

Past History :

Adv.:

Investigation :

Drug Allergies : (if any)

R/v ses /
when complaints
present

Treatment :

[Signature]



Gurgaon

Q Block South City 11, Sohna Road, Main Sector-47, Gurgaon, Haryana Ph.: 0124-4900000 Fax : 0124-2218733
E-mail : parkmedicenters@gmail.com

● West Delhi ● South Delhi ● Faridabad ● Panipat ● Karnal

the **health** care providers

the **health** care providers





NAME	: MRS. LATA PARMAR	DATE	: 12 / 11 / 2022
Age Sex	: 30 Years / Female	Inpatient No	:
PERFORMED BY	: Dr. ELA MADAAN	BILL NO.	: 22990727

TRANS THORACIC ECHO CARDIOGRAPHY REPORT

MITRAL VALVE

Morphology AML: Normal / Thickening / Calcification / Flutter / Vegetation / Non significant Prolapse / SAM
PML: Normal / Thickening / Calcification / Prolapse / Paradoxical Motion / Fixed.
Subvalvular deformity: Present / Absent

Doppler Normal / Abnormal
Mitral Stenosis Present / Absent
Mitral Regurgitation; Absent / Normal / Mild / Trace / Moderate / Severe.

TRICUSPID VALVE

Morphology Normal / Atresia / Thickening / Calcification / Prolapse / Vegetation / Doming.
Doppler Normal / Abnormal
Tricuspid Stenosis: Present / Absent.
Tricuspid Regurgitation: Absent / Mild / Trace / Moderate

PULMONARY VALVE

Morphology Normal / Atresia / Thickening / Calcified / Doming / Vegetation.
Doppler Normal / Abnormal.
Pulmonary Stenosis: Present / Absent
Pulmonary regurgitation: Present / Absent

AORTIC VALVE

Morphology Normal / Thickened / Mildly / Calcified / Flutter / Vegetation / Restricted / Opening
No. of Cusps 1 / 2 / 3 / 4
Doppler Normal / Abnormal
Aortic Stenosis : Present / Absent
Aortic regurgitation : Present / Absent / Mild



(This is only professional opinion and not the diagnosis, Please correlate clinically)

Q Block South City 11, Sohna Road, Main Sector-47, Gurgaon, Haryana

Ph.: 0124-4900000 (100 Lines) Fax : 0124-2218733 E-mail : parkmedicenters@gmail.com

PARK GROUP OF HOSPITALS : West Delhi • South Delhi • Gurgaon • Karnal • Panipat • Hodal • Ambala • Behror

<u>Measurements</u>	<u>Normal Values</u>	<u>Measurements</u>	<u>Normal Value</u>
IVSD : 0.9cm	(0.6-1.1cm))	LA : 3.1cm	(1.9-4.0cm)
LVID : 4.3cm	(3.7-5.6cm)	LVOT : 1.3cm	
LVPW : 0.7cm	(0.6-1.1cm)	AORTA : 2.1cm	(2.0-3.7cm)
EF : 60%	(55% - 80%)	IVSmotion :	Normal / Flat / Paradoxical
Any Other			

CHAMBERS:-

- LV Normal / Enlarged / Clear / Thrombus /
Contraction Normal LV shows concentric LVH, no gradient across LVOT /Inetic / Intra capillary
Regional wall motion abnormality: Absent/ Present
- LA Normal /Enlarged / Clear /Thrombus / Myxoma; LAA: Clear / Thrombus
- RA Normal / Clear / Thrombus, Dilated.
- RV Normal / Mildly Dilated / Enlarged / Clear / Thrombus / Hypertrophied/

PERICARDIUM Normal / Thickening / Calcification / Effusion.

COMMENTS & SUMMARY:-

- All Cardiac Chamber Dimensions are within normal limits.
- Global LVEF 60%
- No RWMA
- NORMAL LV FUNCTION
- NO MR / NO AR
- TRACE TR
- GOOD RV FUNCTION
- IAS/IVS. No Flow seen across IAS/IVS.
- No Thrombus/Mass in any chamber.
- No Pericardial Effusion.

Please correlate clinically

Dr. ELA MADAN
MBBS, PGDCC
Fellowship in non Invasive
Cardiology



(This is only professional opinion and not the diagnosis, Please correlate clinically)

Q Block South City 11, Sohna Road, Main Sector-47, Gurgaon, Haryana
Ph.: 0124-4900000 (100 Lines) Fax : 0124-2218733 E-mail : parkmedicenters@gmail.com

PARK GROUP OF HOSPITALS : West Delhi • South Delhi • Gurgaon • Karnal • Panipat • Hodal • Ambala • Behror

the **health** care providers

the **health** care providers



DEPARTMENT OF RADIOLOGY

Patient Name	Mrs. LATA PARMAR	Billed Date	: 12/11/2022	9.55 AM
Reg No	665728	Reported Date	: 12/11/2022	
Age/Sex	30 Years / Female	Req. No.	: 22990727	
Type	OPD	Consultant Doctor	: Dr. RMO	

USG WHOLE ABDOMEN

The real time, B mode, gray scale sonography of the abdominal organs was performed.

LIVER : The liver is normal in size, 12.6cm shape and echotexture. No evidence of any focal lesion. IHBR is not dilated.

GALL BLADDER : The gall bladder is well distended . No evidence any calculus or mass seen.

GB wall thickness with in normal limits.No evidence of pericholecystic fluid is seen.

BILE DUCT :The common bile duct is normal in caliber. No evidence of calculus is noted in common bile duct.

SPLEEN :The spleen is normal in size 9.4cm and shape.Its echotexture is homogeneous.No evidence of focal lesion is noted.

PANCREAS :The pancreas is normal in size, shape, contours and echotexture.No evidence of solid or cystic mass lesion is noted.MPD is not dilated. No evidence of peripancreatic collection.

KIDNEYS : The bilateral kidneys are normal in size and echotexture. Cortico-medullary differentiation is maintained.There is no evidence of obvious calculus or hydronephrosis.

URINARY BLADDER :The urinary bladder is well distended.It shows uniformly thin walls and sharp mucosa.No evidence of calculus is seen. No evidence of mass or diverticulum is noted.

UTERUS: The uterus is anteverted. It measures 7.3x5.2x3.6 cms. in the longitudinal, anteroposterior and transverse dimensions respectivelyThe uterine margins is smooth and does not reveal any contour abnormalities.

The uterine myometrium shows homogeneous echotexture.

No evidence of leiomyoma is noted. No solid or cystic mass lesion is noted.

The endometrial echo is in the midline and measures 6.9mm.

The ovaries on the either side show normal echotexture.

Right ovary :2x1.6cm

Left ovary : 1.8x1.2cm.

No adnexal mass is seen.No cyst is seen in ovaries.

No evidence of ascites or interbowel free fluid is seen.

No evidence of obvious retroperitoneal or mesentric lymphadenopathy is seen.

IMPRESSION- NORMAL STUDY

Dr. ANSHU K. SHARMA
MBBS, MD, PDCC
correlated clinically.
CONSULTANT RADIOLOGIST

Dr. MANJEET SEHRAWAT
MBBS, MD, PDCC
CONSULTANT RADIOLOGIST



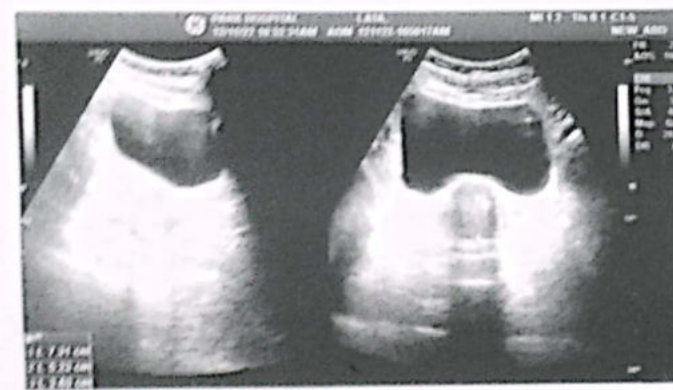
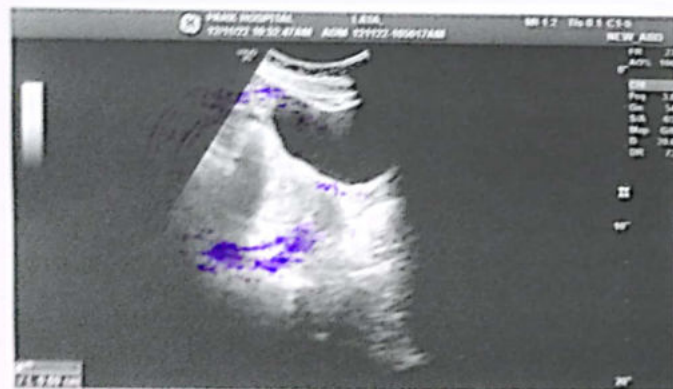
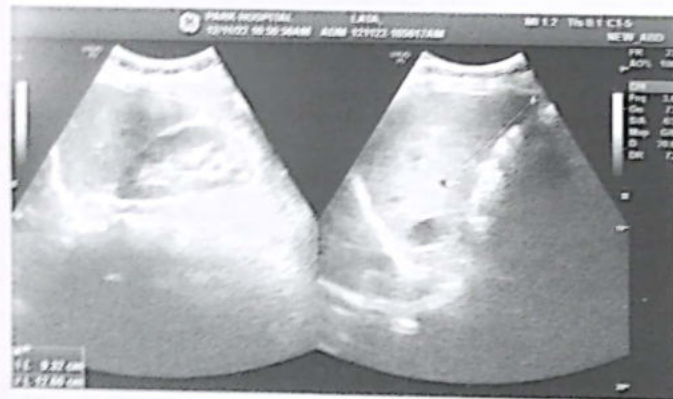
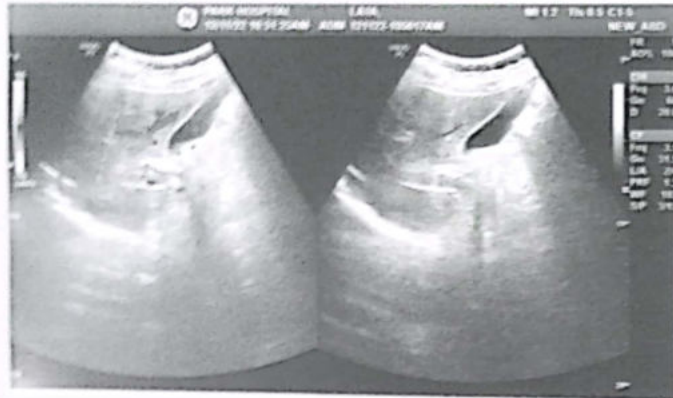
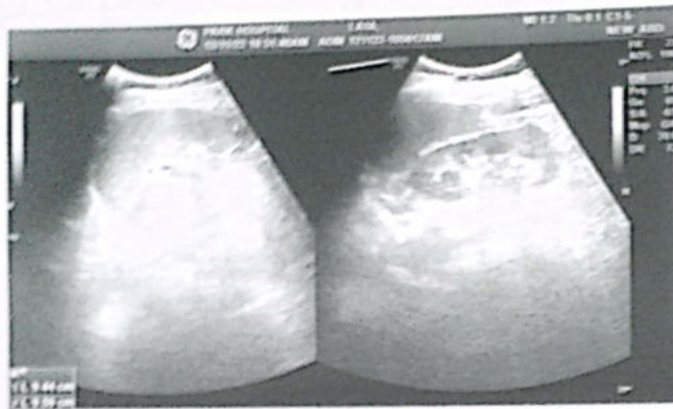
(Signature)

Dr. NEENA SIKKA
MBBS, DNB
CONSULTANT RADIOLOGIST

(This is only professional opinion and not the diagnosis, Please correlate clinically)

Q Block South City 11, Sohna Road, Main Sector-47, Gurgaon, Haryana

Ph.: 0124-4900000 (100 Lines) Fax : 0124-2218733 E-mail : parkmedicenters@gmail.com





Park Hospital

GROUP SUPER SPECIALITY HOSPITAL

DEPARTMENT OF RADIOLOGY



Patient Name	Mrs. LATA PARMAR	Billed Date	: 12/11/2022	9.55 AM
Reg No	665728	Reported Date	: 12/11/2022	
Age/Sex	30 Years / Female	Req. No.	: 22990727	
Type	OPD	Consultant Doctor	: Dr. RMO	

X-RAY CHEST AP/PA

X-RAY CHEST P.A. VIEW

Bilateral lungs appears normal.

No focal lung lesion seen.

No evidence of free fluid is seen.

Both hila are normal in size, have equal density and bear normal relationship.

The heart and trachea are central in position and no mediastinal abnormality is visible.

The cardiac size is normal for patient age and view.

The domes of the diaphragms are normal in position, and show smooth outline.

To be correlated clinically



Dr. ANSHU K. SHARMA
MBBS, MD
CONSULTANT RADIOLOGIST

Dr. MANJEET SEHRAWAT
MBBS, MD, PDCC
CONSULTANT RADIOLOGIST

Dr. NEENA SIKKA
MBBS, DNB
CONSULTANT RADIOLOGIST

(This is only professional opinion and not the diagnosis, Please correlate clinically)

Q Block South City 11, Sohna Road, Main Sector-47, Gurgaon, Haryana

Ph.: 0124-4900000 (100 Lines) Fax : 0124-2218733 E-mail : parkmedcenters@gmail.com

PARK GROUP OF HOSPITALS : West Delhi • South Delhi • Gurgaon • Karnal • Panipat • Hodal • Ambala • Behror

the health care providers

the health care providers



Scanned with OKEN Scanner



Park Hospital

GROUP SUPER SPECIALITY HOSPITAL

DEPARTMENT OF PATHOLOGY



NABL



NABH

Cert. No. MC - 4830 Cert No. H-2016-0369

Patient Name : Mrs. LATA PARMAR

MR No : 665728

Age/Sex : 30 Years / Female

Type : OPD

TPA/Corporate : Bank Of Baroda

Ref Doctor : Dr.RMO

Bill Date : 12/11/2022 9:55 AM

Sample Col Dt/Tm : 12/11/2022 10:53 am

Sample Rec Dt/Tm : 12/11/2022 10:53 am

Reporting Date : 12/11/2022 6:07.21 PM

Sample ID : 62878

Bill/Req. No. : 22990727

Test	Result	Bio. Ref. Interval	Units	Method
BLOOD SUGAR FASTING				
PLASMA GLUCOSE FASTING	83	60 - 100	mg/dl	GOD TRINDERS

***** END OF THE REPORT *****



Dr. PRADIP KUMAR
Consultant (Microbiology)

Dr. SONIA KUMARI
MD Pathology (Gold Medalist)

Dr. NISHA TIWARI
MBBS, MD (Microbiology)
USER NM ANSAR

(This is only professional opinion and not the diagnosis, Please correlate clinically)

Q Block South City 11, Sohna Road, Main Sector-47, Gurgaon, Haryana

Ph.: 0124-4900000 (100 Lines) Fax : 0124-2218733 E-mail : parkmedicenters@gmail.com

PARK GROUP OF HOSPITALS : West Delhi • South Delhi • Gurgaon • Karnal • Panipat • Hodal • Ambala • Behror

the **health** care providers

the **health** care providers





DEPARTMENT OF BIOCHEMISTRY

NABL

NABH

Cert No. MC - 4830 Cert No. H-2016-0369

Patient Name : Mrs. LATA PARMAR
 MR No : 665728
 Age/Sex : 30 Years / Female
 Type : OPD
 TPA/Corporate : Bank Of Baroda
 Ref Doctor : Dr.RMO

Bill Date : 12/11/2022 9.55 AM
 Sample Col Dt/Tm : 12/11/2022 10:53 am
 Sample Rec Dt/Tm : 12/11/2022 10:53 am
 Reporting Date : 12/11/2022 3.09.36 PM
 Sample ID : 62946
 Bill/Req. No. : 22990727

Test	Result	Bio. Ref. Interval	Units	Method
BLOOD SUGAR 2 HR. PP				
BLOOD SUGAR P.P.	130	80 - 150	mg/dl	

***** END OF THE REPORT *****

Dr.PRADIP KUMAR
 Consultant (Microbiology)

Dr.SONIA KUMARI
 MD Pathology (Gold Medalist)



Dr.NISHA TIWARI
 MBBS, MD (Microbiology)
 USER NM ARUN

(This is only professional opinion and not the diagnosis, Please correlate clinically)

Q Block South City 11, Sohna Road, Main Sector-47, Gurgaon, Haryana
 Ph.: 0124-4900000 (100 Lines) Fax : 0124-2218733 E-mail : parkmedicenters@gmail.com

PARK GROUP OF HOSPITALS : West Delhi • South Delhi • Gurgaon • Karnal • Panipat • Hodal • Ambala • Behror

the health care providers the health care providers



Park Hospital

GROUP SUPER SPECIALITY HOSPITAL

DEPARTMENT OF PATHOLOGY



Patient Name : Mrs. LATA PARMAR
 MR No : 665728
 Age/Sex : 30 Years / Female
 Type : OPD
 TPA/Corporate : Bank Of Baroda
 Ref Doctor : Dr.RMO

Bill Date : 12/11/2022 9:55 AM
 Sample Col Dt/Tm : 12/11/2022 10:53 am
 Sample Rec Dt/Tm : 12/11/2022 10:53 am
 Reporting Date : 12/11/2022 7.18.31 PM
 Sample ID : 62946
 Bill/Req. No. : 22990727

NABL Cert No. MC-4930
 NABH Cert No. H-2016-0369

Test	Result	Bio. Ref. Interval	Units	Method
URINE ROUTINE AND MICROSCOPY				
PHYSICAL CHARACTERISTICS				
QUANTITY	30ml	5 - 100	ml	
COLOUR	Pale Yellow	Pale Yellow		
TURBIDITY	Clear	clear		
SPECIFIC GRAVITY	1.010	1.000-1.030		urinometer
PH	Acidic	Acidic/Alkaline		PH PAPER
CHEMICAL EXAMINATION-1				
UROBILINOGEN	NIL	NIL		Ehrlich
URINE PROTEIN	NIL	NIL	mg/dl	Protein error indicator
GLUCOSE	NIL	NIL	mg/dL	GOD-POD/Benedicts
URINE KETONE	NIL	NIL		SOD.NITROPRUSSIDE
MICRO.EXAMINATION				
PUS CELL	5-6	0-5	cells/hpf	
RED BLOOD CELLS	Nil	0-2	cells/hpf	
EPITHELIAL CELLS	2-4	0-5	cells/hpf	
CASTS	NIL	NIL	/lpf	
CRYSTALS	NIL	NIL	/hpf	

***** END OF THE REPORT *****



Dr. PRADIP KUMAR
 Consultant (Microbiology)

Dr. SONIA KUMARI
 MD Pathology (Gold Medalist)

Dr. NISHA TIWARI
 MBBS, MD (Microbiology)
 USER NM ANSAR

(This is only professional opinion and not the diagnosis, Please correlate clinically)

Q Block South City 11, Sohna Road, Main Sector-47, Gurgaon, Haryana
 Ph.: 0124-4900000 (100 Lines) Fax : 0124-2218733 E-mail : parkmedicenters@gmail.com

PARK GROUP OF HOSPITALS : West Delhi • South Delhi • Gurgaon • Karnal • Panipat • Hodal • Ambala • Behror

the health care providers the health care providers



Park Hospital

GROUP SUPER SPECIALITY HOSPITAL

DEPARTMENT OF HAEMATOLOGY



Patient Name : Mrs. LATA PARMAR
 MR No : 665728
 Age/Sex : 30 Years / Female
 Type : OPD
 TPA/Corporate : Bank Of Baroda
 Ref Doctor : Dr.RMO

Bill Date : 12/11/2022 9.55 AM
 Sample Col Dt/Tm : 12/11/2022 10:53 am
 Sample Rec Dt/Tm : 12/11/2022 10:53 am
 Reporting Date : 12/11/2022 6.08.23 PM
 Sample ID : 62878
 Bill/Req. No. : 22990727

Test	Result	Bio. Ref. Interval	Units	Method
------	--------	--------------------	-------	--------

BLOOD GROUPING AND RH FACTOR

BLOOD GROUP	"O" RH POSITVE	MATRIX GEL ABO/Rho (D) FORWARD & REVERSE GROUPING
-------------	----------------	---

***** END OF THE REPORT *****



Dr.PRADIP KUMAR
 Consultant (Microbiology)

Dr.SONIA KUMARI
 MD Pathology (Gold Medalist)

Dr.NISHA TIWARI
 MBBS, MD (Microbiology)
 USER NM ANSAR

(This is only professional opinion and not the diagnosis, Please correlate clinically)

Q Block South City 11, Sohna Road, Main Sector-47, Gurgaon, Haryana
 Ph.: 0124-4900000 (100 Lines) Fax : 0124-2218733 E-mail : parkmedicenters@gmail.com

PARK GROUP OF HOSPITALS : West Delhi • South Delhi • Gurgaon • Karnal • Panipat • Hodal • Ambala • Behror

the **health** care providers the **health** care providers



Park Hospital

GROUP SUPER SPECIALITY HOSPITAL



NABL



NABH

DEPARTMENT OF PATHOLOGY

Patient Name : Mrs. LATA PARMAR

MR No : 665728

Age/Sex : 30 Years / Female

Type : OPD

TPA/Corporate : Bank Of Baroda

Ref Doctor : Dr.RMO

Bill Date : 12/11/2022 9:55 AM

Sample Col Dt/Tm : 12/11/2022 10:53 am

Sample Rec Dt/Tm : 12/11/2022 10:53 am

Reporting Date : 12/11/2022 6:08.13 PM

Sample ID : 62878

Bill/Req. No. : 22990727

Cert. No. MG-4830 Cert. No. H-2016-0369

Test	Result	Bio. Ref. Interval	Units	Method
CBC				
HAEMOGLOBIN	12.3	12 - 15	gm/dL	COLORIMETRY
TOTAL LEUCOCYTE COUNT	8300	4000 - 10000	/ μ L	ELECTRICAL IMPEDANCE
DIFFERENTIAL COUNT				
NEUTROPHILS	55	40.0 - 80.0	%	FLOW CYTOMETRY
LYMPHOCYTES	40	20.0 - 40.0	%	FLOW CYTOMETRY
MONOCYTES	03	2.0 - 10.0	%	FLOW CYTOMETRY
EOSINOPHILS	02	0.0 - 5.0	%	FLOW CYTOMETRY
BASOPHILS	00	0.0 - 2.0	%	FLOW CYTOMETRY
RED BLOOD CELL COUNT	4.0	3.5 - 5.5	millions/ μ L	ELECTRICAL IMPEDANCE
PACKED CELL VOLUME	36.8	35.0 - 50.0	%	ELECTRICAL IMPEDANCE
MEAN CORPUSCULAR VOLUME	91.5	83 - 101	fL	ELECTRICAL IMPEDANCE
MEAN CORPUSCULAR HAEMOGLOBIN	30.6	27 - 31	Picogrames	CALCULATED
MEAN CORPUSCULAR HB CONC	33.4	33 - 37	g/dl	CALCULATED
PLATELET COUNT	242	150 - 450	thou/ μ L	ELECTRICAL IMPEDANCE
RDW	13.1	11.6 - 14.5	%	CALCULATED
SPECIMEN TYPE	WHOLE BLOOD-EDTA			

***** END OF THE REPORT *****

Dr. PRADIP KUMAR
Consultant (Microbiology)

Dr. SONIA KUMARI
MD Pathology (Gold Medalist)



Dr. NISHA TIWARI
MBBS, MD (Microbiology)
USER NM ANSAR

Page 1 of 1

(This is only professional opinion and not the diagnosis, Please correlate clinically)

Q Block South City 11, Sohna Road, Main Sector-47, Gurgaon, Haryana
Ph.: 0124-4900000 (100 Lines) Fax : 0124-2218733 E-mail : parkmedicenters@gmail.com

PARK GROUP OF HOSPITALS : West Delhi • South Delhi • Gurgaon • Karnal • Panipat • Hodal • Ambala • Behror

the **health** care providers

the **health** care providers



Scanned with OKEN Scanner



Park Hospital

GROUP SUPER SPECIALITY HOSPITAL

DEPARTMENT OF HAEMATOLOGY



NABL

NABH

Cert. No. MC-4330 Cert. No. H-2016-0369

Patient Name : Mrs. LATA PARMAR

MR No : 665728

Age/Sex : 30 Years / Female

Type : OPD

TPA/Corporate : Bank Of Baroda

Ref Doctor : Dr.RMO

Bill Date : 12/11/2022 9.55 AM

Sample Col Dt/Tm : 12/11/2022 10:53 am

Sample Rec Dt/Tm : 12/11/2022 10:53 am

Reporting Date : 12/11/2022 6.08.37 PM

Sample ID : 62878

Bill/Req. No. : 22990727

Test	Result	Bio. Ref. Interval	Units	Method
ESR (WESTERGREN)				
E.S.R. - II HR.	33		mm II Hr.	Westergren

***** END OF THE REPORT *****



Dr. PRADIP KUMAR
Consultant (Microbiology)

Dr. SONIA KUMARI
MD Pathology (Gold Medalist)

Dr. NISHA TIWARI
MBBS, MD (Microbiology)
USER NM ANSAR

(This is only professional opinion and not the diagnosis, Please correlate clinically)

Q Block South City 11, Sohna Road, Main Sector-47, Gurgaon, Haryana

Ph.: 0124-4900000 (100 Lines) Fax : 0124-2218733 E-mail : parkmedicenters@gmail.com

PARK GROUP OF HOSPITALS : West Delhi • South Delhi • Gurgaon • Karnal • Panipat • Hodal • Ambala • Behror

the health care providers

the health care providers





NABL



NABH

DEPARTMENT OF MICROBIOLOGY

Cert No. MC-4830 Cert. No. H-2016-0369

Patient Name : Mrs. LATA PARMAR
 MR No : 665728
 Age/Sex : 30 Years / Female
 Type : OPD
 TPA/Corporate : Bank Of Baroda
 Ref Doctor : Dr.RMO

Bill Date : 12/11/2022 9:55 AM
 SampleCol Dt/Tm : 12/11/2022 10:53 am
 SamplecRec Dt/Tm : 12/11/2022 10:53 am
 Reporting Date : 14/11/2022 10.42.04 AM
 Sample ID : 62946
 Bill/Req. No. : 22990727

Test	Result	Bio. Ref. Interval	Units	Method
URINE C/S				

NAME OF SPECIMEN	URINE
ORGANISM IDENTIFIED	NO MICRO ORGANISM GROWN IN CULTURE AFTER 48 HRS OF INCUBATION AT 37 DEGREE C

***** END OF THE REPORT *****



Dr. PRADIP KUMAR
Consultant (Microbiology)

Dr. SONIA KUMARI
MD Pathology (Gold Medalist)

Dr. NISHA TIWARI
MBBS, MD (Microbiology)
USER NM AMIT

(This is only professional opinion and not the diagnosis, Please correlate clinically)

Q Block South City 11, Sohna Road, Main Sector-47, Gurgaon, Haryana

Ph.: 0124-4900000 (100 Lines) Fax : 0124-2218733 E-mail : parkmedicenters@gmail.com

PARK GROUP OF HOSPITALS : West Delhi • South Delhi • Gurgaon • Karnal • Panipat • Hodal • Ambala • Behror

the **health** care providers

the **health** care providers





Park Hospital

GROUP SUPER SPECIALITY HOSPITAL

DEPARTMENT OF IMMUNOLOGY



NABL



NABH

Patient Name : Mrs. LATA PARMAR
 MR No : 665728
 Age/Sex : 30 Years / Female
 Type : OPD
 TPA/Corporate : Bank Of Baroda
 Ref Doctor : Dr.RMO

Bill Date : 12/11/2022 9.55 AM
 Sample Col Dt/Tm : 12/11/2022 10:53 am
 Sample Rec Dt/Tm : 12/11/2022 10:53 am
 Reporting Date : 13/11/2022 1.31.47 PM
 Sample ID : 62946
 Bill/Req. No. : 22990727

Cert No. MC-4830 Cert No. H-2016-0169

Test	Result	Bio. Ref. Interval	Units	Method
THYROID PROFILIE				
TRI-IODOTHYRONINE (T3)	1.43	0.60 - 1.81	ng/ml	Chemiluminescence
THYROXINE (T4)	10.9	5.01 - 12.45	µg/dL	Chemiluminescence
THYROID STIMULATING HORMONE (TSH)	1.96	0.5-5.50	µIU/ml	
SPECIMEN TYPE	SERUM			

Method : chemiluminescent immunoassay

Note : Clinical Significance:

Thyroid function tests (TFTs) is a collective term for blood tests used to check the function of the thyroid. TFTs may be requested if a patient is thought to suffer from hyperthyroidism (overactive thyroid) or hypothyroidism (underactive thyroid), or to monitor the effectiveness of either thyroid-suppression or hormone replacement therapy. It is also requested routinely in conditions linked to thyroid disease, such as atrial fibrillation and anxiety disorder. A TFT panel typically includes thyroid hormones such as thyroid-stimulating hormone (TSH, thyrotropin) and thyroxine (T4), and triiodothyronine (T3) depending on local laboratory policy.

Note: Please correlate with clinical condition

***** END OF THE REPORT *****

Dr. PRADIP KUMAR
 Consultant (Microbiology)

Dr. SONIA KUMARI
 MD Pathology (Gold Medallist)



Dr. NISHA TIWARI
 MBBS, MD (Microbiology)
 USER NM DINESH

(This is only professional opinion and not the diagnosis, Please correlate clinically)

Q Block South City 11, Sohna Road, Main Sector-47, Gurgaon, Haryana
 Ph.: 0124-4900000 (100 Lines) Fax : 0124-2218733 E-mail : parkmedicenters@gmail.com

PARK GROUP OF HOSPITALS : West Delhi • South Delhi • Gurgaon • Karnal • Panipat • Hodal • Ambala • Behror

the health care providers the health care providers



Park Hospital

GROUP SUPER SPECIALITY HOSPITAL

DEPARTMENT OF PATHOLOGY



NABL



NABH

Cert. No. MC - 4830 Cert. No. H-2016-0363

Patient Name : Mrs. LATA PARMAR
 MR No : 665728
 Age/Sex : 30 Years / Female
 Type : OPD
 TPA/Corporate : Bank Of Baroda
 Ref Doctor : Dr.RMO

Bill Date : 12/11/2022 9:55 AM
 Sample Col Dt/Tm : 12/11/2022 10:53 am
 Sample Rec Dt/Tm : 12/11/2022 10:53 am
 Reporting Date : 12/11/2022 6.09.04 PM
 Sample ID : 62878
 Bill/Req. No. : 22990727

Test	Result	Bio. Ref. Interval	Units	Method
LFT (LIVER FUNCTION TEST)				
LFT				
TOTAL BILIRUBIN	0.7	0 - 1.2	mg/dL	DIAZO
DIRECT BILIRUBIN	0.3	0 - 0.4	mg/dL	DIAZO
INDIRECT BILIRUBIN	0.4	0.10 - 0.6	mg/dL	CALCULATED
SGOT (AST)	33	0 - 45	U/L	IFCC WITHOUT PYRIDOXAL PHOSHATE
SGPT (ALT)	55 H	0 - 45	U/L	IFCC WITHOUT PYRIDOXAL PHOSHATE
ALKALINE PHOSPHATASE	110	30 - 170	IU/L	MODIFIED IFCC
TOTAL PROTEINS	6.2 L	6.4 - 8.0	g/dL	BIURET
ALBUMIN	3.1 L	3.3 - 5.5	g/dL	BCG DYE
GLOBULIN	3.1	2.3 - 4.5	g/dL	CALCULATED
A/G RATIO	1.0 L	1.1 - 2.2		CALCULATED
SPECIMEN TYPE	SERUM			

***** END OF THE REPORT *****

Dr. PRADIP KUMAR
 Consultant (Microbiology)

Dr. SONIA KUMARI
 MD Pathology (Gold Medalist)

Dr. NISHA TIWARI
 MBBS, MD (Microbiology)
 USER NM ANSAR



(This is only professional opinion and not the diagnosis, Please correlate clinically)

Q Block South City 11, Sohna Road, Main Sector-47, Gurgaon, Haryana
 Ph.: 0124-4900000 (100 Lines) Fax : 0124-2218733 E-mail : parkmedicenters@gmail.com

PARK GROUP OF HOSPITALS : West Delhi • South Delhi • Gurgaon • Karnal • Panipat • Hodal • Ambala • Behror

the health care providers

the health care providers





Park Hospital

GROUP SUPER SPECIALITY HOSPITAL

DEPARTMENT OF PATHOLOGY



NABL

NABH

Cert. No. MC - 4830 Cert. No. H-2016-0369

Patient Name : Mrs. LATA PARMAR
 MR No : 665728
 Age/Sex : 30 Years / Female
 Type : OPD
 TPA/Corporate : Bank Of Baroda
 Ref Doctor : Dr.RMO

Bill Date : 12/11/2022 9.55 AM
 Sample Col Dt/Tm : 12/11/2022 10:53 am
 Sample Rec Dt/Tm : 12/11/2022 10:53 am
 Reporting Date : 12/11/2022 6.09.33 PM
 Sample ID : 62878
 Bill/Req. No. : 22990727

Test	Result	Bio. Ref. Interval	Units	Method
KFT (RENAL PROFILE)				
KFT				
SERUM UREA	25	10 - 45	mg/dL	UREASE-GLDH
SERUM CREATININE	0.6	0.4 - 1.4	mg/dL	MODIFIED JAFFES
SERUM URIC ACID	3.0	2.5 - 7.0	mg/dL	URICASE
SERUM SODIUM	150 H	136 - 145	meq/l	ISE
SERUM POTASSIUM	4.5	3.5 - 5.5	meq/l	ISE
SERUM CALCIUM	8.6	8.5 - 10.5	mg/dL	ARSENazo III
SERUM PHOSPHORUS	2.6	2.5 - 4.5	mg/dL	AMMONIUM MOLYBDATE
SPECIMEN TYPE	SERUM			

***** END OF THE REPORT *****

Dr. PRADIP KUMAR
 Consultant (Microbiology)

Dr. SONIA KUMARI
 MD Pathology (Gold Medalist)



Dr. NISHA TWARI
 MBBS, MD (Microbiology)
 USER NM ANSAR

(This is only professional opinion and not the diagnosis, Please correlate clinically)

Q Block South City 11, Sohna Road, Main Sector-47, Gurgaon, Haryana
 Ph.: 0124-4900000 (100 Lines) Fax : 0124-2218733 E-mail : parkmedicenters@gmail.com

PARK GROUP OF HOSPITALS : West Delhi • South Delhi • Gurgaon • Karnal • Panipat • Hodal • Ambala • Behror

the **health** care providers

the **health** care providers





Park Hospital

GROUP SUPER SPECIALITY HOSPITAL



DEPARTMENT OF BIOCHEMISTRY

Cert. No. MC-4830 Cert. No. H-2015-0369

Patient Name : Mrs. LATA PARMAR
 MR No : 665728
 Age/Sex : 30 Years / Female
 Type : OPD
 TPA/Corporate : Bank Of Baroda
 Ref Doctor : Dr.RMO

Bill Date : 12/11/2022 9:55 AM
 Sample Col Dt/Tm : 12/11/2022 10:53 am
 Sample Rec Dt/Tm : 12/11/2022 10:53 am
 Reporting Date : 12/11/2022 6.11.16 PM
 Sample ID : 62878
 Bill/Req. No. : 22990727

Test	Result	Bio. Ref. Interval	Units	Method
LIPID PROFILE				
LIPID PROFILE				
TOTAL CHOLESTEROL	155	0 - 250	mg/dL	CHOD -Trinder
SERUM TRIGLYCERIDES	59 L	60 - 165	mg/dl	GPO-TRINDER
HDL-CHOLESTEROL	54	30 - 70	mg/dl	DIRECT
VLDL CHOLESTEROL	11	6 - 32	mg/dL	calculated
LDL	90	50 - 135	mg/dl	calculated
LDL CHOLESTEROL/HDL RATIO	1.6	1.0 - 3.0	mg/dL	calculated
TOTAL CHOLESTEROL/HDL RATIO	2.8	2.0 - 5.0	mg/dl	calculated
SPECIMEN TYPE	SERUM			

***** END OF THE REPORT *****

Dr. PRADIP KUMAR
 Consultant (Microbiology)

Dr. SONIA KUMARI
 MD Pathology (Gold Medalist)



Dr. NISHA TIWARI
 MBBS, MD (Microbiology)
 USER NM ANSAR

(This is only professional opinion and not the diagnosis, Please correlate clinically)

Q Block South City 11, Sohna Road, Main Sector-47, Gurgaon, Haryana
 Ph.: 0124-4900000 (100 Lines) Fax : 0124-2218733 E-mail : parkmedicenters@gmail.com

PARK GROUP OF HOSPITALS : West Delhi • South Delhi • Gurgaon • Karnal • Panipat • Hodal • Ambala • Behror

the health care providers

the health care providers

25mm/s 0.5-25Hz

I 10mm/mV

aVR 10mm/mV

V1 10mm/mV

II

aVL

V2

SYNC

SYNC

SYNC

III

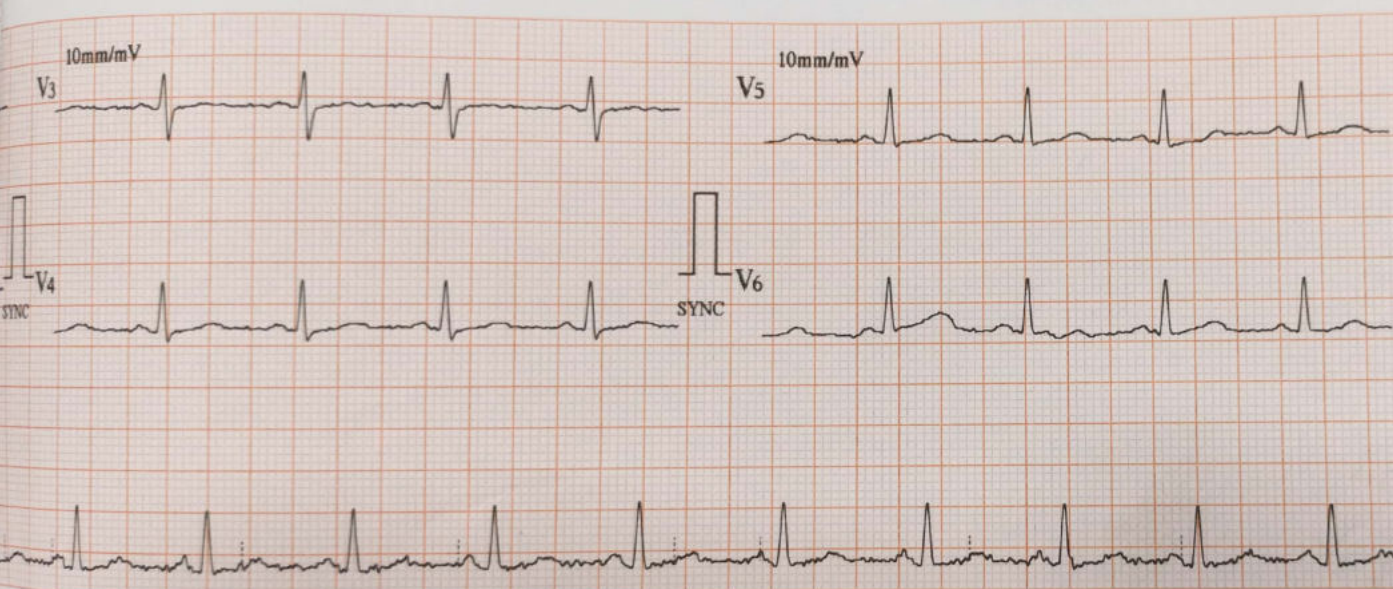
aVF

10mm/mV

II

ECG-1203 V2.000 (BIOS: V2.000/AMP: V1.001) 2016-01-01 00:06

12/11/22



ID : 0365

Name: *Lata Parmar*

Sex : *female*

Age : *30y/A*

HR : 91 bpm

R-R : 656 ms

P-R : 128 ms

QRS : 89 ms

QT/QTc : 354/437 ms

P/QRS/T : 74/71/37 °

RV5/SV1 : 0.700/0.350 mV

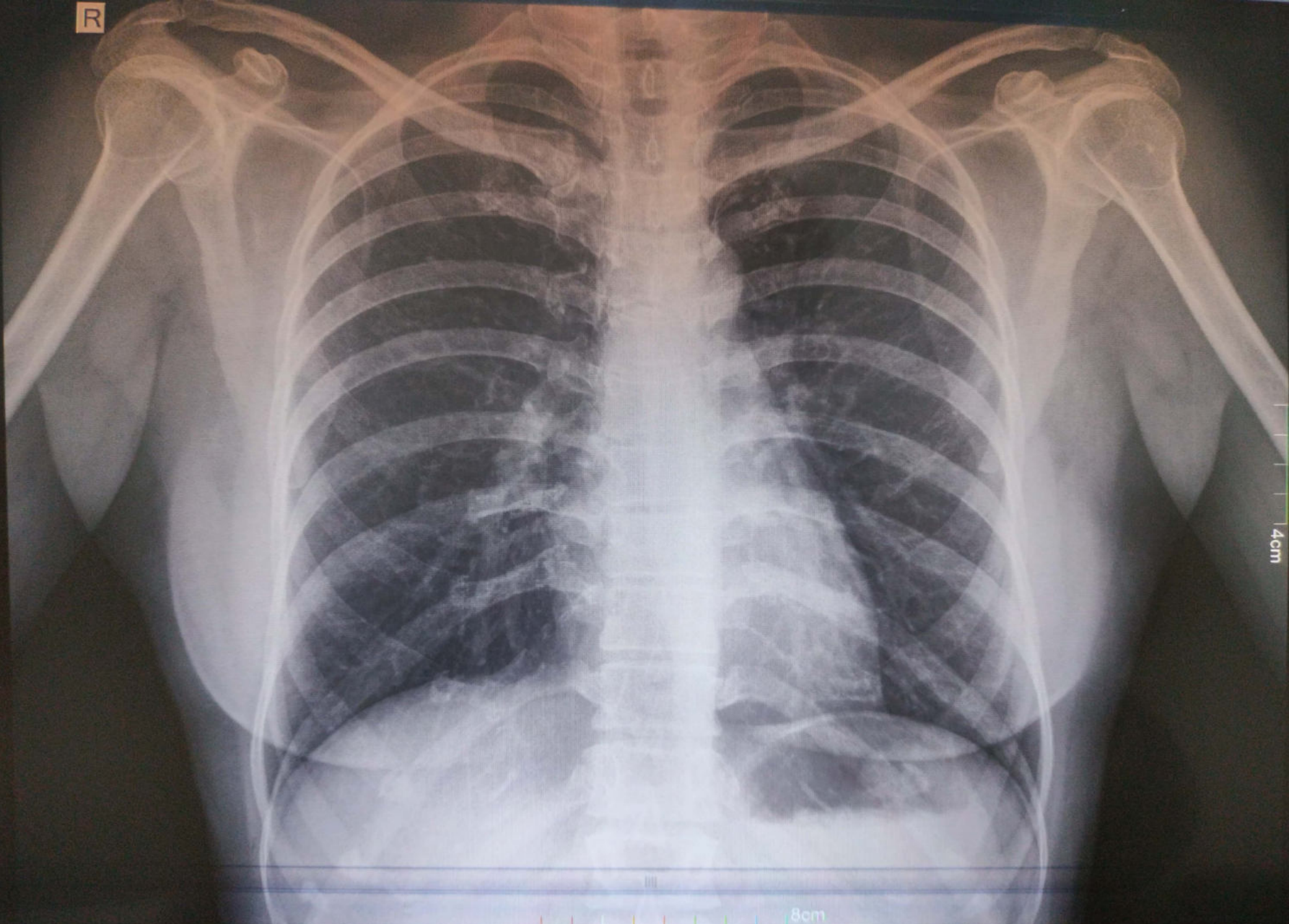
RV5+SV1 : 1.050 mV

_____ Sinus Rhythm

_____ T Abnormality (Flat T)

Unconfirmed report Verified by: _____

R



LATA PARMAR 30Y F
PARK HOSPITAL SOUTH CITY II GURGAON HARYANA

CHEST

12/11/2022 11:13:59
REQ-22990727