



# PARKLINE DIAGNOSTICS PVT. LTD.

L.G. 3, 4 & 5, Bhuvana Towers, S.D. Road, Secunderabad - 500 003.  
Tel : +91 40-2784 5852, 6649 1787, 7995421787, 7093445852, Fax : +91 40 2784 7864  
Email parklinediagnostics@gmail.com www.parklinediagnostics.com



NABL Accredited  
Certificate No.MC-2566


## MEDICAL EXAMINATION REPORT

Name	Mr. G. Venugopal		Date :	23/02/2022	
Company	Clo: mediwheel		Reg. No. :	1898848	
Contact No.	7988403185		Sex	<input checked="" type="checkbox"/> M	Age : <input type="checkbox"/> 43
Type	Pre-Emp		Emp. No.:	126980	
	Overseas		Height	176 cm	
	Annual	<input checked="" type="checkbox"/>	Weight	85 kgs	
Remarks	Clinical parameters and lab reports are within normal limits				
Fitness Status	Medically Fit / Unfit		Physician's Signature 		

Dr. D. RAJA RAO  
MBBS  
Reg. No. 6443

# COMPREHENSIVE MEDICAL EXAMINATION REPORT

NAME Mr. G. Venugopal.  
 AGE 43 yrs / male  
 MARITAL STATUS married CHILDREN : M  F   
 IDENTIFICATION (IF ANY) A mole on tip of the nose.



## PAST HISTORY

Any family H/o : High Blood Pressure, Heart Disease, Tuberculosis, Diabetes, Asthma, Cancer

Mother     Father

Any personal H/o Major illness like : Typhoid.....NIL.....Jaundice.....NIL.....Etc.

Any H/o STD.....NIL.....Skin infection.....NIL.....

H/o Blood Transfusion.....NIL.....Recent Vaccination.....Covid/SH/BCG 2 doses ✓

H/o Epilepsy.....NIL.....Giddiness.....NIL.....

H/o Surgery.....Dr. Symptomatology 1996.....Fracture in the past.....NIL.....

Any Personal H/O.

High Blood Pressure, Heart Disease Tuberculosis, Diabetes, Asthma, Cancer

Drug Abuse, Drug Allergy, Micturition, Bowels, Alcohol, Smoking, Sleep, MC, Wt. Loss/Wt. Gain

*Both weekly once.*

Present illness / Medication

## GENERAL EXAMINATION

Conjunctiva :  
 Skin :  
 Ears :  
 Nose :  
 Throat & Oral Cavity :

NAD

Bone, Joints :  
 Nutritional Status :  
 Lymph Nodes :  
 Edema Feet :  
 Varicose Veins :

(N)  
well nourished.  
NPD  
NIL  
NIL

**Distant Vision : Near Vision :**

Right Eye: 6/6

With glasses / Without glasses

left Eye : 6/6

with glasses / without glasses

Colour Vision : BF normal

**Right Ear**

Hearing :

Rinee's Test ;

Weber Test :

Discharge :

(N)  
+ve  
Central  
Absent

Right Eye: Ng

With glasses / Without glasses

left Eye : Ng

with glasses / without glasses

**Ophthalmologist's Signature**

**Left Ear**

(N)  
+ve  
Central  
Absent

**SYSTEMIC EXAMINATION**

Pulse : 80 bpm

B.P. : 130/90 mmHg

Lungs : A. Shape of Chest B/c symmetrical  
B. Breath Sounds B/c - clear ⊕  
C. Adventitious Sounds NO

Heart : A. Sounds S1 S2 ⊕  
B. Murmurs No murmurs

Abdomen : A. Liver NPD  
B. Spleen NPD  
C. Piles NIL  
D. Any Lump NIL

General : A. Hernia  
B. Hydrocele  
C. Varicocele  
NPD

Breast : Rt \_\_\_\_\_ Lt. \_\_\_\_\_

**Nervous System**

A. Higher Function :  
B. Cranial Nerves :  
C. Sensory System :  
D. Motor System :  
E. Jerks :

} (N)

DR. KATTA  
M.B.B.S., D.O., F.R.C.S.  
Regd: 8951 (AMC)



## CANDIDATE'S DECLARATION

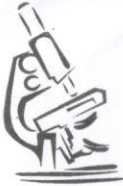I hereby solemnly declare that I am not suffering from Asthma, Hypertension, Diabetes, Occult Psychological disorders or any other ailment which can be suppressed without my voluntary declaration.

**Date :**

\_\_\_\_\_  
**Signature**

**Place :**

Note : General Physical Examination and Investigation included in the health check-up Have certain limitations and may not be able to detect all latent and asymptomatic diseases. Any new symptoms developing after the health check-up or persisting thereafter should be brought to the attention of the treating physician.



# PARKLINE DIAGNOSTICS PVT. LTD.

L.G. 3, 4 & 5, Bhuvana Towers, S.D. Road, Secunderabad - 500 003. Tel : +91 40-2784 5852, 6649 1787, 7995421787, 7093445852, Fax : +91 40 2784 7864 Email parklinediagnostics@gmail.com www.parklinediagnostics.com



NABL Accredited  
Certificate No. MC-2566

## ENT CONSULTATION

S.No. 1898848 Emp.No. 126980 Date 23/3/22  
Name Mr. G. Venugopal Age 43Yrs Sex  M/F

EARS : Right Left

EAC : (N) (N)

TM : (N) (N)

TFT : Rinne AC>BC AC>BC

Waber's ← → Central

NOSE : ABC same as examiner  
AR - septum - central mucosa (N) IT (N)

THROAT : AP (N) TP (N) PPh (N)

NECK : No central/tend neck swelling

IMPRESSION: ENT within (N) limits

Dr. D. Hari Krishna Reddy  
MS (ENT)  
Head & Neck Surgeon  
Reg. No: 88379

Dr. R. Prashanth Kumar  
M.D. GMS (ENT)  
Head & Neck Surgeon  
Reg. No: 88379



Phone: 27844043  
66339096

# SECUNDERABAD DENTAL HOSPITAL

## CENTRE FOR ADVANCED DENTAL CARE

24/3/22

### ORAL & MAXILLOFACIAL SURGEONS

**Dr. Kazim Himathi M.D.S.**

**Dr. Gautam Dendukuri**

FDSRCS (Eng), FFDRCS (Ire),  
FFDRCS (OMFS),(Ire)

### PROSTHODONTIST

**Dr. Chandrakanth Reddy M.D.S.**

### ENDODONTIST

**Dr. Ram Narayan Reddy M.D.S.**

### ORTHODONTIST

**Dr. Rajesh Reddy M.D.S., M.Orth RCS.**

**Dr. Sudeep Bhalerao M.D.S.**

### PERIODONTIST

**Dr. Veerendranath Reddy M.D.S.**

### PEDODONTIST

**Dr. Soumya M.D.S.**

**Dr. Mounika M.D.S.**

### DENTAL SURGEONS

**Dr. N. Jagadish Rao B.D.S.**

**Dr. Baisakhi Saha B.D.S.**

*Mr. G. Venugopal*

*c/o J. Patil's came for a general  
checkup*

*o/e :- 8dams +*

*Adv Scaling*







# PARKLINE DIAGNOSTICS PVT. LTD.

L.G 3, 4 & 5, Bhuvana Towers, Sarojini Devi Road, Secunderabad - 500 003.  
Tel. +91 40 2784 5852, 6649 1787, 77995421787, 7093445852, Fax : + 91 40 2784 7864  
Email : parklinediagnostics@gmail.com, www.parklinediagnostics.com



NABL Accredited  
Certificate No.: MC-2566

## TEST REPORT

Name : Mr . G VENUGOPAL [126980]  
Age / Gender : 43 Years / Male  
Ref.By : Medi Wheel  
Req. No : BIL1898848

TID : UMR0750386  
Registered on : 23-Mar-2022 08:47 AM  
Reported On : 23-Mar-2022 12:41 PM

### Ultrasound Abdomen and Pelvis

**LIVER** is normal shape, size ( 15.3 cms) and has uniform echopattern.  
No evidence of focal lesion or intrahepatic biliary ductal dilatation.  
Hepatic and portal vein radicals are normal.

**GALL BLADDER** shows normal shape and has clear contents.  
Gall bladder wall is of normal thickness.

CBD is of normal calibre.

**PANCREAS** has normal shape, size and uniform echopattern.  
No evidence of ductal dilatation or calcification.

**SPLEEN** shows normal shape, size and echopattern.

**KIDNEYS** move well with respiration and have normal shape, size and echopattern.  
Cortico- medullary differentiations are well made out.  
No evidence of calculus or hydronephrosis.  
Right kidney measures: 9.5 x 4.6 cms, Left kidney measures: 10.1 x 5.1 cms.

**URINARY BLADDER** shows normal shape and wall thickness.  
It has clear contents. No evidence of diverticula.

**PROSTATE** is normal in size and echotexture.

No evidence of free fluid in the abdomen


Subcutaneous lipoma measuring 22 x 11 mm is noted in right paraumbilical region.

#### **IMPRESSION:**

\* Subcutaneous lipoma in right paraumbilical region.

Suggested clinical correlation and follow up

The Test marked with\*are not accredited by NABL

  
Dr. Abid Yazden  
Consultant Radiologist

Lab Timings (Weekdays) : 7.00 am to 8.30 pm  
Sundays & Holidays : 7.00 am to 1.00 pm

Radiologists Timings (Weekdays) : 7.30 am to 1.30 pm  
& 5.30 pm to 7.45 pm  
Sundays & Holidays : 7.30 am to 9.30 am





# PARKLINE DIAGNOSTICS PVT. LTD.

L.G 3, 4 & 5, Bhuvana Towers, Sarojini Devi Road, Secunderabad - 500 003.  
Tel. +91 40 2784 5852, 6649 1787, 77995421787, 7093445852, Fax : + 91 40 2784 7864  
Email : parklinediagnostics@gmail.com, www.parklinediagnostics.com



NABL Accredited  
Certificate No.: MC-2566

## TEST REPORT

Name : Mr . G VENUGOPAL [126980]  
Age / Gender : 43 Years / Male  
Ref.By : Medi Wheel  
Req. No : BIL1898848

TID : UMR0750386  
Registered on : 23-Mar-2022 08:47 AM  
Reported On : 23-Mar-2022 11:49 AM

### X-RAY CHEST PA VIEW

Lung fields are clear.

Cardia is normal.

Hila are normal.

C P angles are free.

Bony cage is normal.

Soft tissues are normal.

**IMPRESSION : NORMAL CHEST X-RAY**



**Dr. PRAJAKTA SUKHADEVE**  
**DNB RADIOLOGY**  
**Reg. No. 88493**

The Test marked with\*are not accredited by NABL

Lab Timings (Weekdays) : 7.00 am to 8.30 pm  
Sundays & Holidays : 7.00 am to 1.00 pm

Radiologists Timings (Weekdays) : 7.30 am to 1.30 pm  
& 5.30 pm to 7.45 pm  
Sundays & Holidays : 7.30 am to 9.30 am



ID: 1898848  
G Venugopal  
Male 43Years

25-05-2022 09:44:29 AM

CARDIART

HR : 76 bpm  
P : 109 ms  
PR : 151 ms  
QRS : 75 ms  
QT/QTc : 373/419 ms  
P:QRS/T : 40/20/1 °  
RV5/SV1 : 0.967/0.677 mV

NSR  
WNL



**Dr. NAVEEN KUMAR .C**  
M.D., D.M.  
Consultant Cardiologist  
Reg. No. 52291

Diagnosis Information:  
Sinus Rhythm  
Slight ST Depression(V2)

Report Confirmed by:



**PATIENT SUMMARY REPORT**

**AKLINE DIAGNOSTICS PVT.LTD**

PHONE : 1898848  
NAME : MR G.VENUGOPAL  
AGE / SEX : 43 / MALE

HEIGHT (cm) : 176  
WEIGHT (kg) : 85  
PROTOCOL : BRUCE

REF: BY : MEDIWHEEL  
DONE BY : DR NAVEEN KUMAR C  
TECHNICIAN : G.M.SURESH

23-03-2022, 11:22:

CLINICAL HISTORY :

INDICATION :

EFFECT OF TEST : Routine Check Up.

RISK FACTOR : None.

ACTIVITY : Very Active.

PREVIOUS INVESTIGATION : ECG

REASON FOR TERMINATION : THR ACHIEVED

EXERCISE TOLERANCE : Good (> 10 METS).


EXERCISE INDUCED ARRHYTHMIAS : No.

HEMO RESPONSE : Normal.

PRONAL RESPONSE : Normal.

GENERAL IMPRESSION :

LABORATORY COMMENTS : *negative for inducible ischemia*



Confirmed By *ls*  
**DR. NAVEEN KUMAR C**  
M.D., D  
Consultant Cardiologist  
Reg. No. 52291