

# GULATI HOSPITAL

169, Sarojini Colony, Near Bus Stand,  
YAMUNA NAGAR - 135 001

## Dr. J.K. Gulati

M.D., D.N.B. (AIIMS, New Delhi)  
Consultant Physician & Heart Specialist

## Dr. Sarita Gulati

D.G.O., DCH (Gynaecologist)  
Ex. SMO, Civil Hospital, YNR.

### MEDICAL EXAMINATION

I have examined Mr. Rajan Sudan for today and his particulars are given below

No h/o Cough / Expectoration/ Breathlessness/ Pain Chest


No evidence of Anaemia/ Cyanosis/ Jaundice/ Edema

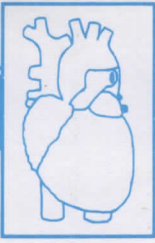
Pulse – 78/mt

BP – 120/80mmhg

Age – 35yrs

No Abnormality Detected

  
DR. J.K. GULATI  
MD, DNB  
GULATI HOSPITAL  
Near Bus Stand, Yamuna Nagar



HOS 260633  
RES 261633

# GULATI HOSPITAL

169, Sarojini Colony, Near Bus Stand,  
YAMUNA NAGAR - 135 001

**Dr. J.K. Gulati**

M.D., D.N.B. (AIIMS, New Delhi)  
Consultant Physician & Heart Specialist

**Dr. Sarita Gulati**

D.G.O., DCH (Gynaecologist)  
Ex. SMO, Civil Hospital, YNR.

## X - RAY Chest PA

Date:-07/03/2023

Name:-Mr.Rajan Sudan Age/Sex:-35Y/Male


Skin and soft tissue normal

Bony and skeleton normal

Trachea is central

Mediastinum is normal

Heart size and shape Normal

  
**DR. J.K. GULATI**  
MD, DNB  
GULATI HOSPITAL  
Near Bus Stand, Yamuna Nagar



K.V. CLINICAL COMPUTERISED LABORATORY

# GULATI HOSPITAL

Equipped with Latest Computerised Analyzer (CBA-300)


169, Sarojini Colony, Phase-I, YAMUNA NAGAR - 135 001

NAME. MR. RAJAN SUDAN AGE/SEX:-35/M DATE :-07.03.2023

## COMPLETE HAEMOGRAM

Normal Values

Hb	13.7 gm%	12 - 17 gm%
RBC COUNT	5.00m/cu mm	4 - 5.5 m / cu mm
WBC COUNT	5,000cu/ mm	4000-11000 /cu mm
PLATELET COUNT	1.78Lac/ cu mm	1.5 - 4 lac/ cu mm
DLC Polymorph	60	40-70%
Lymphocytes	30	20-45%
Monocytes	07	2-19%
Eosinophils	03	01-06%
Basophils	00	0.0-0.1%
MCH	34.25pg	28-35pg/cell
MCV	96.00fl	86-98 fl
MCHC	32.11gm%	32- 36 gm%
HAEMATOCRIT	50%	42- 52 %
ESR	05mm/hr	0.0-10mm/hr

  
DR. J.K. GULATI  
MD, DNB  
GULATI HOSPITAL  
Near Bus Stand, Yamuna Nagar

  
Lab Incharge



K.V. CLINICAL COMPUTERISED LABORATORY

# GULATI HOSPITAL

Equipped with Latest Computerised Analyzer (CBA-300)

169, Sarojini Colony, Phase-I, YAMUNA NAGAR - 135 001


NAME MR. RAJAN SUDAN

AGE:-35Y/M

DATE 07.03.2023

## BLOOD PROFILE

TEST	RESULT	NORMAL VALUE
B.SUGAR-F	85.0mg/dl	60-110mg/dl
B.SUGAR-PP	100.0mg/dl	70-140mg/dl
Blood group	'O'+VE	
S.CREATININE	1.0mg%	0.1 -1.5mg%
B.U N	18.0mg%	10-20mg%
S. Uric Acid	6.5mg%	3.0-7.0mg%
S. BILIRUBIN	0.7 mg%	0.2- 1.0mg%
DIRECT	0.1 mg%	0.0 -0.2 mg%
INDIRECT	0.6mg%	0.1 - 1.0 mg%
SGOT	38 IU/L	5-40 IU/L
SGPT	32 IU/L	5 -35 IU/L
GGTP	45 IU/L	M 11-49U/L F 7-32 U/L
HBA1C	4.8 %	< 6%
Alkaline Phosphatate	185.0 U/L	70-270 U/L
TOTAL PROTEINS	7.5gm/dl	5.5 - 8.0 gm/dl
ALBUMIN	4.2 gm/dl	3.5 -5.5 gm/dl
GLOBULIN	3.3 gm/dl	2.5 -3.5 gm/dl
A:G Ratio	1:27	1:0-1:7
TOTAL CHOLESTROL	181mg%	(130- 200 )
L D L	127mg%	< 150 )
H D L	38 mg%	(30 - 55 )
V L D L	16mg%	(5- 35 )
TRIGLYCERIDES	115mg%	( 65- 170 )
CHOLESTROL / HDL RATIO	4.7	

  
**DR. J.K. GULATI**  
MD, DNB  
GULATI HOSPITAL  
Near Bus Stand, Yamuna Nagar

  
Lab Incharge

IN CASE ANY MISPRINTING OR ABNORMAL RESULT FOR ANY MISTAKE PLEASE CONTACT TO US IMMEDIATELY  
THIS REPORT IS STRICTLY NOT VALID FOR MEDICO-LEGAL PURPOSE.

(Wishing for your speedy recovery)




K.V. CLINICAL COMPUTERISED LABORATORY


# GULATI HOSPITAL

Equipped with Latest Computerised Analyzer (CBA-300)

169, Sarojini Colony, Phase-I, YAMUNA NAGAR - 135 001

MR.RAJAN SUDAN	AGE 35 /MALE		DATE 07.03.2023
TEST NAME	RESULTS	UNITS	BIO.REF.INTERVAL
THYROID PROFILE,TOTAL,SERUM (CLIA)			
T3.TOTAL	0.95	ng/mL	0.60-1.81
T4.TOTAL	5.25	ug/dL	5.01-12.45
TSH	1.45	uIU/mL	0.35-5.50

  
**DR. J.K. GULATI**  
MD, DNB  
GULATI HOSPITAL  
Near Bus Stand, Yamuna Nagar

  
Lab Incharge



K.V. CLINICAL COMPUTERISED LABORATORY

# GULATI HOSPITAL

Equipped with Latest Computerised Analyzer (CBA-300)

169, Sarojini Colony, Phase-I, YAMUNA NAGAR - 135 001

Patient's Name Mr. Rajan Sudan

Age/Sex: 35Y/M

Advised By Dr. J.K. Gulati MD.

Date: 07-03-2023


INVESTIGATION	REPORT	NORMAL
---------------	--------	--------

## URINE EXAMINATION

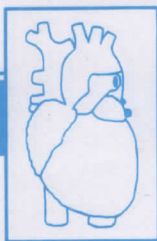
Reaction (PH)	Acidic	Acidic
Albumin	Nil	Nil
Sugar -F	Nil	Nil
Sugar-PP	Nil	Nil
Specific gravity	1018	1008-1025

## MICROSCOPI EXAM

Pus cell	Nil	/HPF
RBCs	Nil	/HPF
Epithelial Cell	Nil	/HPF
Crystals	Nil	/HPF
Casts	Nil	/HPF
Any other findings	Nil	/HPF

  
**DR. J.K. GULATI**  
MD, DNB  
GULATI HOSPITAL  
Near Bus Stand, Yamuna Nagar

  
Lab Incharge



# GULATI HOSPITAL

169, Sarojini Colony, Near Bus Stand,  
YAMUNA NAGAR - 135 001

**Dr. J.K. Gulati**

M.D., D.N.B. (AIIMS, New Delhi)  
Consultant Physician & Heart Specialist **ECHOCARDIOGRAPHY**

**Dr. Sarita Gulati**

D.G.O., DCH (Gynaecologist)  
Ex SMO, Civil Hospital, YNR.

**NAME MR RAJAN SUDAN      AGE& SEX 35 M      DATED 7.03.23**

## M-MODE PARAMETERS

		<b>Normal Values</b>
Left Ventricular ED Dimension	4.9 cm	(3.7-5.6cm)
Left Ventricular ES Dimension	3.5 cm	(2.2-4.0cm)
Right Ventricular ED Dimension	2.1 cm	(0.7-2.6cm)
Inter Ven. Septum thickness (D)	1.0 cm	(0.6-1.1cm)
LV Posterior Wall thickness (D)	0.9 cm	(0.6-1.1cm)
Aortic root diameter	3.0 cm	(2.0-3.7cm)
Left Atrial Diameter	3.2 cm	(1.9-4.0cm)

## INDICES OF LV SYSTOLIC FUNCTIONS (NORMAL VALUES)

Ejection Fraction	60 %	(54-76%)
Fractional Shortening	35 %	(25-46%)

## MITRAL VALVE

Thin, and it moves posteriorly during diastole. No subvalvular pathology, no anterior leaflet pathology no prolapsed or flutter or systolic anterior motion

## TRICUSPID VALVE

Valve is normal looking, no prolapse is seen

## AORTIC VALVE

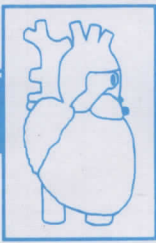
All three cusps seen, opens fully during systole with central closure

## PULMONARY VALVE

Thin opens well, Pulmonary Aartery not dilated

## LEFT VENTRICLE

No hypertrophy, Chamber slightly dilated No segmental wall motion abnormality



# GULATI HOSPITAL

169, Sarojini Colony, Near Bus Stand,  
YAMUNA NAGAR - 135 001

## Dr. J.K. Gulati

M.D., D.N.B. (AIIMS, New Delhi)

Consultant Physician & Heart Specialist

**PULSE & CONTINUOUS WAVE DOPPLER**

**No mitral regurgitation.**

**No aortic regurgitation.**

**No Tricuspid regurgitation .**

**No pulmonary regurgitation.**

**Predicted PA pressure (S)=25MM of Hg**

## Dr. Sarita Gulati

D.G.O., DCH (Gynaecologist)

Ex SMO. Civil Hospital, YNR.

## COLOUR FLOW IMAGING

**No Mitral regurgitation.**

**No aortic regurgitation.**

**No tricuspid regurgitation.**

**No pulmonary regurgitation.**

## COMMENTS

No LA, LAA, LV CLOT seen.

No vegetation on any valve

No intra cardiac mass.

Pericardial effusion.

IAS, IVS intact.

**IMPRESION:- Echocardiography Findings are suggestive of**

**Normal systolic and normal diastolic Functions**

**No Evidence of Hypertrophy**

**Dr J K Gulati MD, DNB (Medicine)**

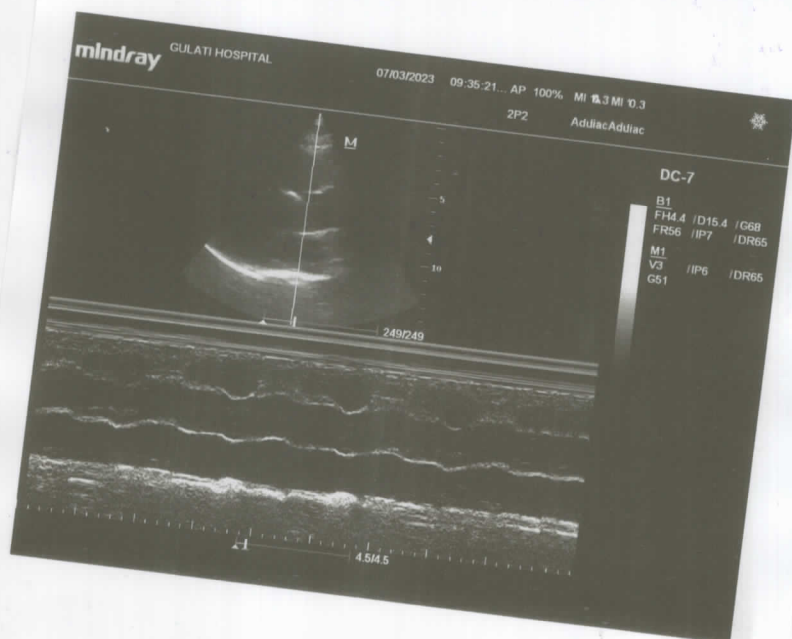
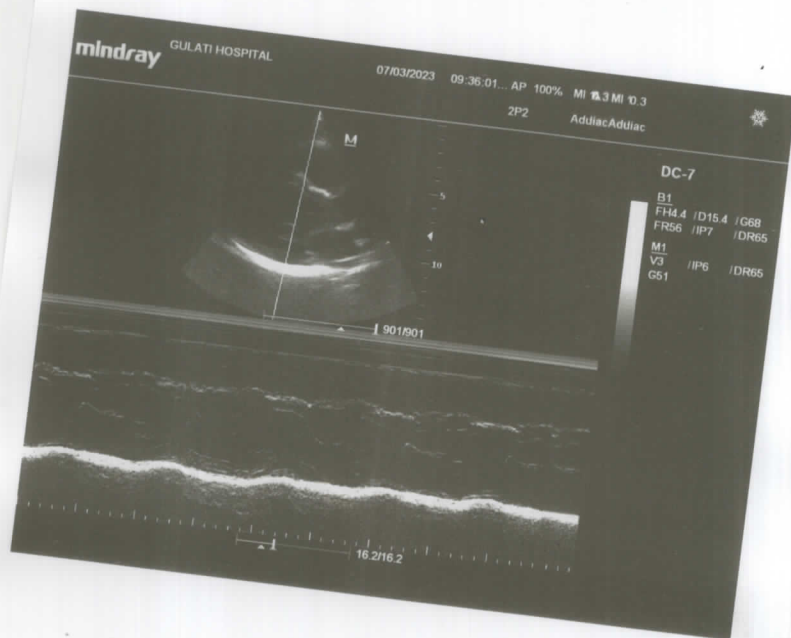
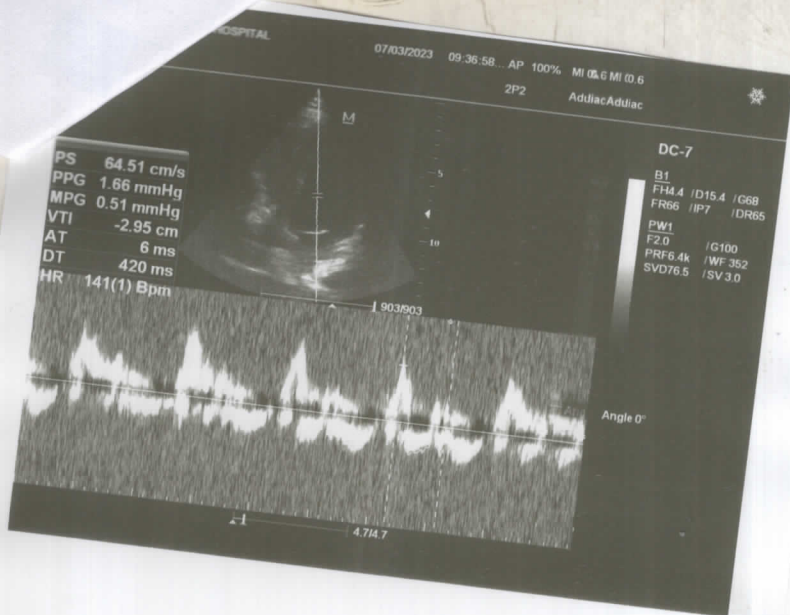
**DR. J.K. GULATI**

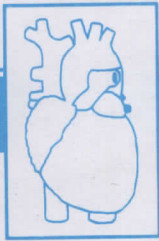
**MD, DNB**

**GULATI HOSPITAL**

**Near Bus Stand, Yamuna Nagar**







# GULATI HOSPITAL

169, Sarojini Colony, Near Bus Stand,  
YAMUNA NAGAR - 135 001

## Dr. J.K. Gulati

M.D., D.N.B. (AIIMS, New Delhi)  
Consultant Physician & Heart Specialist

## Dr. Sarita Gulati

D.G.O., DCH (Gynaecologist)  
Ex SMO, Civil Hospital, YNR.

### ULTRASONOGRAPHY (WHOLE ABDOMEN)

NAME MR RAJAN SUDAN AGE & SEX 35 M 7.03.23

#### LIVER

Liver size is 14.5 CMS and it shows bright echopattern with normal vasculature and intrahepatic biliary radical pattern.

No abscess or mass is seen.

#### GALL BLADDER

It shows normal echopattern with normal smooth wall. No evidence of hyperechoic shadow or acoustic shadow is seen in the region.

CBD measures within normal limits.

#### PANCREAS

Pancreas shows normal echo pattern.

#### KIDNEYS

Both kidney measure within normal limits with normal echogenic Pattern and well maintained corticomedullary distinction. No evidence of hydronephrotic change is seen. No calculus seen

#### SPLEEN

Its span is normal.No abnormal echoes detected from the splenic area.

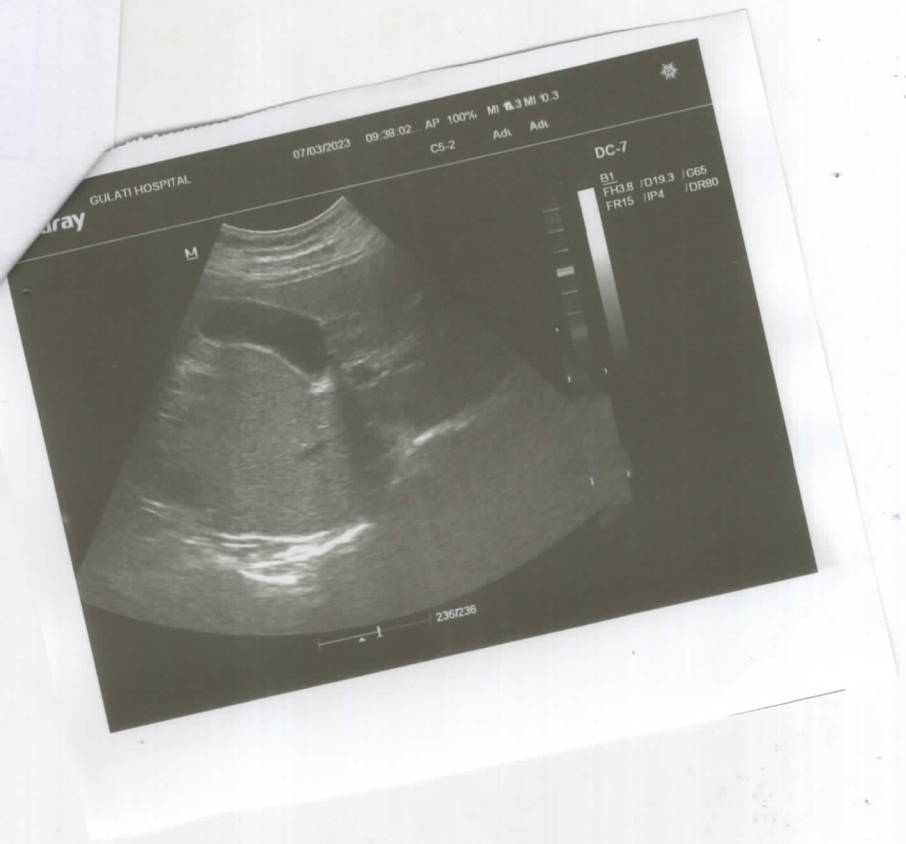#### URINARY BLADDER

Bladder is well distended and as normal smooth wall. No mass or calculus is seen

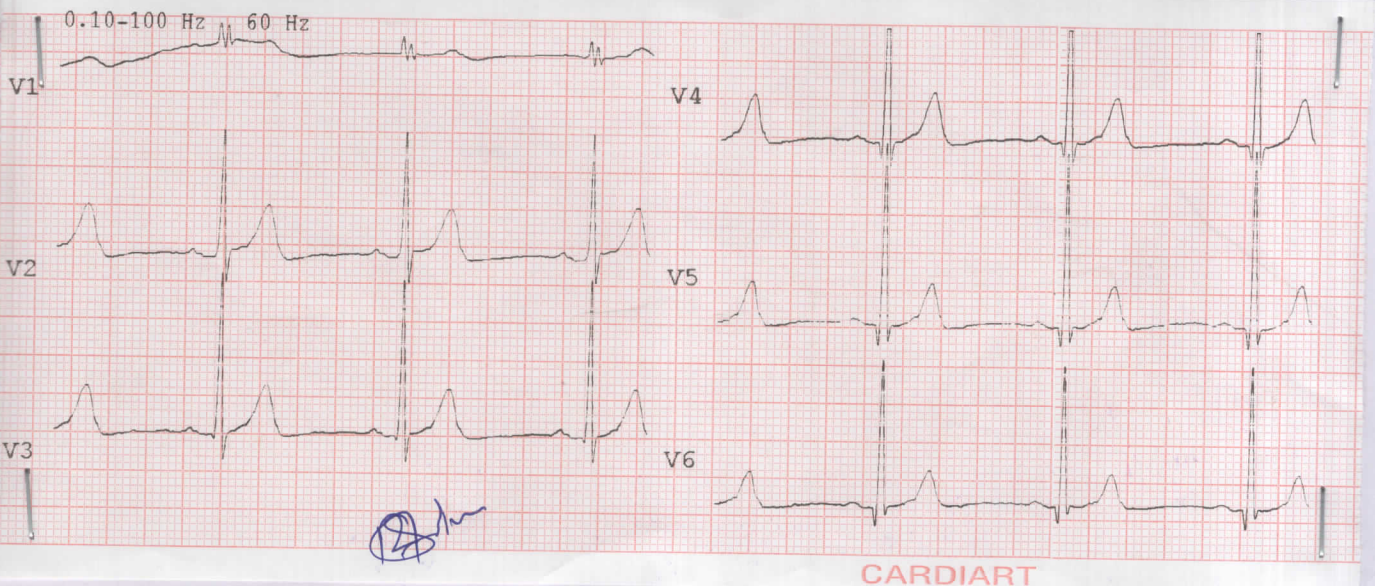
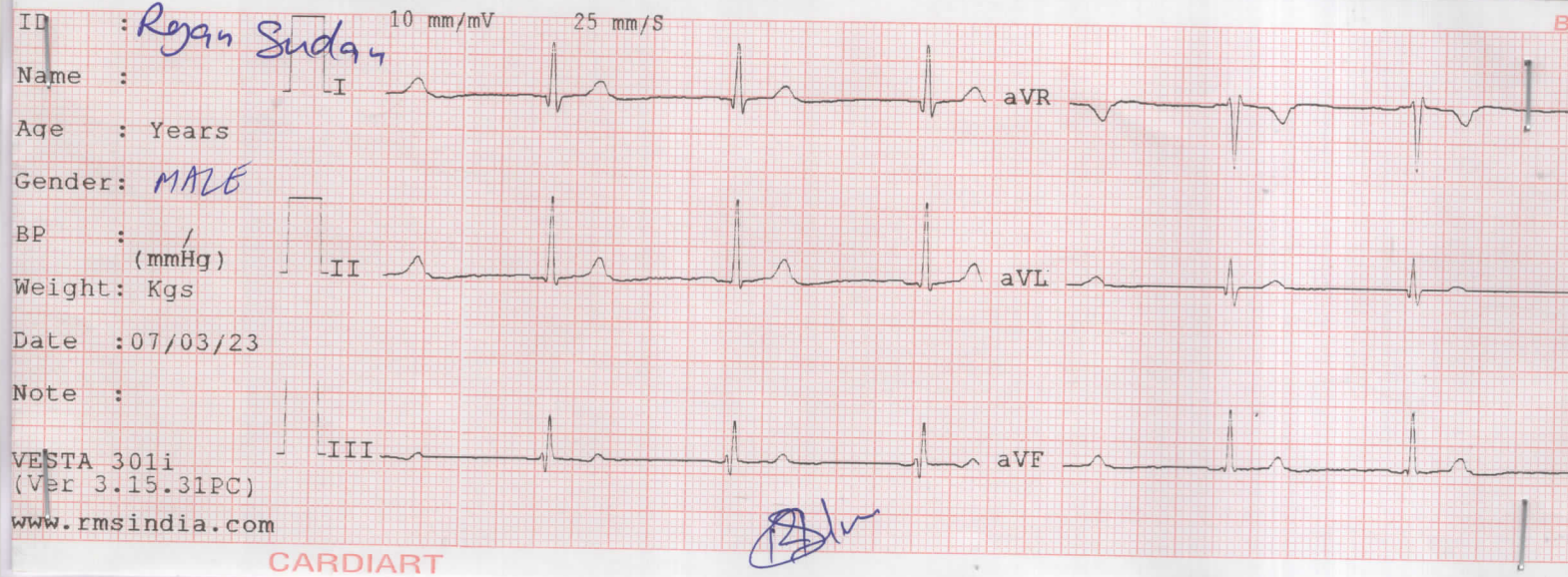
No free fluid seen in the peritoneal cavity.

**CONCLUSION :- FATTY LIVER**

*Arav*  
**DR. J.K. GULATI**  
MD, DNB  
GULATI HOSPITAL  
Near Bus Stand, Yamuna Nagar



RAJAN SUDAN



**ECG REPORT:-Within Normal Limits**

*J.K. Gulati*  
Signature  
**DR. J.K. GULATI**  
MD, DNB  
GULATI HOSPITAL  
Near Bus Stand, Yamuna Nagar

PA

L

