

Name : Mr. Y H RAVI Kumar

Age: 48 Y

UHID:CKOR.0000248306

Address : kml

Sex: M



Plan : ARCOFEMI MEDIWHEEL MALE AHC CREDIT PAN
INDIA OP AGREEMENT

OP Number:CKOROPV389780

Bill No :CKOR-OCR-79250

Date : 30.11.2023 08:25

Sno	Serive Type/ServiceName	Department
1	ARCOFEMI - MEDIWHEEL - FULL BODY ANNUAL PLUS ABOVE 50Y MALE - 2D ECHO - PAN INDIA - FY2324	
1	URINE GLUCOSE(FASTING)	
2	GAMMA GLUTAMYL TRANFERASE (GGT)	
3	PROSTATIC SPECIFIC ANTIGEN (PSA TOTAL)	
4	HbA1c, GLYCATED HEMOGLOBIN	
5	2 D ECHO <i>Room no - 10</i>	
6	LIVER FUNCTION TEST (LFT)	
7	X-RAY CHEST PA	
8	GLUCOSE, FASTING	
9	HEMOGRAM + PERIPHERAL SMEAR	
10	ENT CONSULTATION <i>Dr. Nigam</i>	
11	FITNESS BY GENERAL PHYSICIAN	
12	DIET CONSULTATION	
13	COMPLETE URINE EXAMINATION	
14	URINE GLUCOSE(POST PRANDIAL)	
15	PERIPHERAL SMEAR	
16	ECC <i>Am</i>	
17	BLOOD GROUP ABO AND RH FACTOR	
18	LIPID PROFILE	
19	BODY MASS INDEX (BMI)	
20	OPTHAL BY GENERAL PHYSICIAN	
21	RENAL PROFILE/RENAL FUNCTION TEST (RFT/KFT) <i>R. NO - 20 (2nd floor) ✓</i>	
22	ULTRASOUND - WHOLE ABDOMEN <i>R. NO - 17 (2nd floor)</i>	
23	THYROID PROFILE (TOTAL T3, TOTAL T4, TSH)	
24	DENTAL CONSULTATION <i>Room no - 15</i>	
25	GLUCOSE, POST PRANDIAL (PP), 2 HOURS (POST MEAL)	

25. physio
⑤ Dental

Height - 163cm
weight - 61kg
BP - 144/87 mmHg
Pulse - 71 bts/mts

NAME: MR. Y H RAVI KUMAR

AGE: 48Y

SEX: MALE

DATE: 30/11/2023

ECHOCARDIOGRAPHY REPORT

MEASUREMENT

AO -24(20 – 35)mm	LIVD d – 41(36-52)mm	IVS - 10 (06 - 11)mm
LA -27(19- 40)mm	LVID s - 27 (23- 39)mm	PWD – 11(06- 11)mm
EF - 60% (>50%)	RVID-22	

VALVES

Mitral Valve : Normal
Aortic Valve : Normal
Tricuspid Valve : Normal
Pulmonary Valve : Normal

CHAMBERS

Left Atrium : Normal
Right Atrium : Normal
Left Ventricle : Normal
Right Ventricle : Normal

SEPTAE

IVS : Intact
IAS : Intact

GREAT ARTERIES

Aorta : Normal
Pulmonary Artery : Normal

DOPPLER DATA

Mitral : E > A
Aortic : Normal
Tricuspid : Normal
Pulmonary : Normal

WALL MOTION ABNORMALITIES : No RWMA

Pericardium : Normal

FINAL DIAGNOSIS

**NORMAL CHAMBERS AND VALVES
NORMAL BIVENTRICULAR FUNCTION
NO RWMA AT REST, LV EF -60%**


**DR. MOHAN MURALI
CONSULTANT
CARDIOLOGIST**

DR VIJAYA LAKSHMI M
M.B.B.S, D.L.O, D.N.B(ENT)
Phone No.9972044580,080-25633823/24/23

30/11/23

HEALTH CHECK- ENT

NAME: *Y.H.RAVI Kumar* **P** **AGE:** *48/m*

EAR: **RE:** **LE:**

EXTERNAL EAR
MIDDLE EAR
INNER EAR (FN) *normal*

HEARING ASSESSMENT: **RE:** **LE:**

RHINNE
WEBER
ABC *normal*

NOSE **THROAT**
AIRWAY
SEPTUM
TURBINATES
OTHERS
NECK
NECK NODES
OTHER *normal*

ORAL CAVITY
OROPHARYNX
PHARYNX
LARYNX *normal*

AUDIOMETRY
IMPRESSION *normal*

Vijaya M
SIGNATURE:

Patient Name	: Mr. Y H RAVI Kumar	Age	: 48 Y M
UHID	: CKOR.0000248306	OP Visit No	: CKOROPV389780
Reported on	: 30-11-2023 11:30	Printed on	: 30-11-2023 13:55
Adm/Consult Doctor	:	Ref Doctor	: SELF

DEPARTMENT OF RADIOLOGY

X-RAY CHEST PA

Both lungs fields appear normal.

Both hila are normal.

Both costophrenic and cardiophrenic angles are normal.

The cardiac and mediastinal shadows appear normal.

Bones and soft tissues appear normal.

IMPRESSION : NORMAL STUDY.


DR VINOD JOSEPH DNB,DMRD
RADIOLOGIST

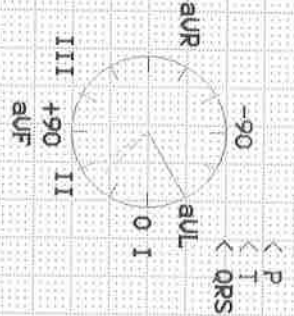
Printed on:30-11-2023 11:30

---End of the Report---

AGE: 48

Measurement Results:

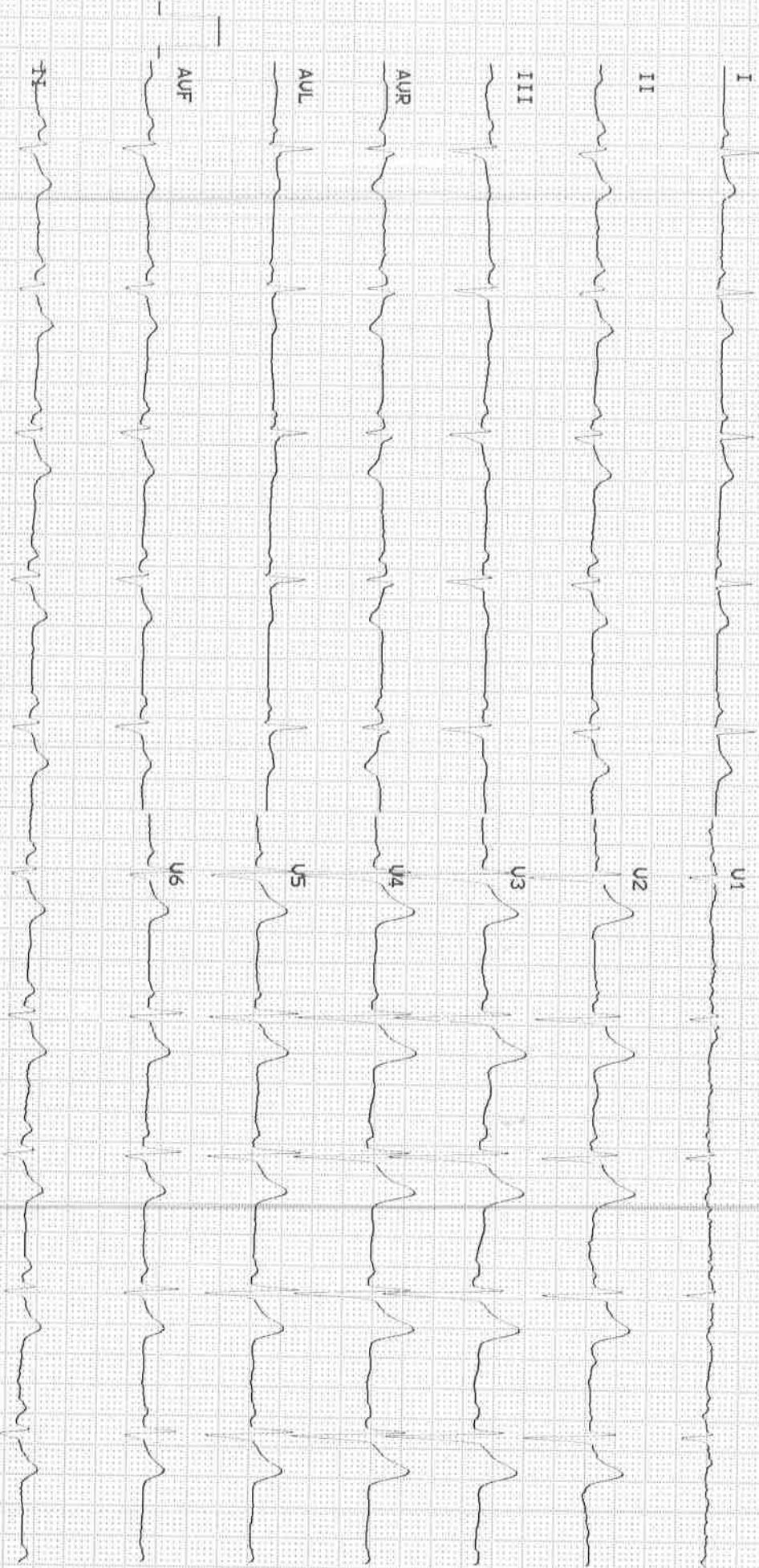
QRS	102 ms
QT/QTcB	406 / 417 ms
PR	172 ms
P	128 ms
RR/PP	948 / 950 ms
P/ORS/T	55 / -30 / 45 degrees
QTd/QTcBd	30 / 31 ms
Sokolow	1.1 mV
NK	8



Interpretation:

RSRy

Unconfirmed report.



Patient Name	: Mr. Y H RAVI Kumar	Age	: 48 Y/M
UHID	: CKOR.0000248306	OP Visit No	: CKOROPV389780
Reported By:	: Dr. MOHAN MURALI	Conducted Date	: 30-11-2023 15:25
Referred By	: SELF		

ECG REPORT

Observation :-

1. Normal Sinus Rhythm.
2. Heart rate is 63beats per minutes.
3. No pathological Q wave or S-T,T changes seen.
4. Normal P,Q,R,S,T waves and axis.
5. No evidence of chamber, hypertrophy or enlargement seen.

Impression:

NORMAL RESTING ECG.

Dr. MOHAN MURALI
CARDIOLOGIST

NOTE : KINDLY TAKE A PHOTOCOPY OF THE GRAPH
FOR FUTURE REFERENCE IF NEEDED.

----- END OF THE REPORT -----

Apollo Clinic

Consent Form

Patient Name: ① RAVIKUMAR-Y.H Age: ② SARITHA-K-S. 41 yrs
#8

UHID Number: Company Name: Bank of Baroda

I Mr/Mrs/Miss: ① RAVIKUMAR-Y.H
② SARITHA-K.S Employee of Bank of Baroda

(Company) want to inform you that I am not getting the Consultation

Test which is a part of health check package.

Reason If any: Coming on 09.12.2023

And I claim the above statement in my full consciousness.

Patient Signature:  Date: 30.11.2023



DR. MAHABALESHWAR.M
MBBS.(MYS), MD(AIIMS DELHI)FICS
D.O (JIPMER)
REG.NO:KMC:9748

DATE: 30.11.23
OP NO:

THE APOLLO MEDICAL CENTER KORAMANGALA

NAME: Ron Kumar,
AGE : 48
GENDER: M

OPHTHALMIC REPORT

RIGHT EYE

LEFT EYE

GENERAL APPEARANCE

VISION - DISTANCE

WITHOUT GLASS

WITH GLASS

GLASS POWER

6/6A / 6/6

NEAR

WITHOUT GLASS

WITH GLASS

GLASS POWER

MB MB

COLOUR

- mild primary colour. normal.

ANTERIOR SEGMENT:-

FUNDUS

I.O.P: DIGITAL

} AM

- Myopia

DOCTOR SIGNATURE

Patient Name : Mr Y H Ravi Kumar

Patient ID: 248306

Age : 48Year(s)

Sex : Male

Referring Doctor : H/C

Date : 30.11.2023

ULTRASOUND ABDOMEN AND PELVIS

FINDINGS:

Liver is normal in size and shows increased echotexture. No biliary dilatation. No focal lesion
CBD is not dilated. **Portal vein** is normal in size, course and calibre.

Gall bladder contracted

Pancreas to the extent visualized, appears normal in size, contour and echogenicity

Spleen is normal in size, shape, contour and echopattern. No evidence of mass or focal lesions.

Right Kidney is normal in size, position, shape and echopattern. Corticomedullary differentiation is maintained. No evidence of calculi or hydronephrosis.

Left Kidney is normal in size, position, shape and echopattern. Corticomedullary differentiation is maintained. No evidence of calculi or hydronephrosis.

Urinary Bladder is well distended. Wall thickness is normal. No evidence of calculi, mass or mural lesion.

Prostate: normal in size and echotexture. There is no ascites.

IMPRESSION: GRADE I FATTY LIVER

DR VINOD JOSEPH DNB,DMRD
RADIOLOGIST