



Shubham Imaging & ALC Diagnostic Center

ISO 9001:2015 Certified center

(A Unit of P.K. Arogyam Health & Wellness Center)

E-95, P.C. Colony, Near Sai Netryalaya Transformer, Kankarbagh, Patna - 20

alcdiagnostics@gmail.com

www.pkarogayamhealthcheckup.com

7050037694, 8271206196

OPINION MUST BE CORRELATES WITH CLINICALLY & OTHER INVESTIGATION FOR FINAL DIAGNOSIS. NOT FOR MEDICO LEGAL PURPOSE

PATIENT NAME : Mrs. ANAMIKA SINGH

PATIENT ID: 178

COL DATE : 25/02/2023 REPORTING DATE: 25/02/2023 AGE SEX : 28 YRS/F

REF.BY : DR. /MEDIWHEEL.

TEST NAME	RESULT	Unit	REF.RANGE
BLOOD SUGAR (F)	72.0 mg/dl		70 - 110 mg/dl
BLOOD SUGAR (PP)	98.0 mg/dl		70 - 140 mg/dl

LIPID PROFILE:-

TOTAL CHOLESTROL	151.4 mg/dl		130 -250 mg/dl
TRIGLYCERIDE	107.6 mg/dl		50 -160 mg/dl
HDL CHOLESTROL	43.0 mg/dl		30 - 60 mg/dl
LDL CHOLESTROL	86.9 mg/dl		80 -130 mg/dl
VLDL CHOLESTROL	21.5 mg/dl		15 - 40 mg/dl
T.CH./HDL RATIO	3.5:1		Upto 5:1
LDL./HDL RATIO	2.0:1		2 - 4:1

AK
25/02/23

Consultant Radiologist

ESTB BY:-

Dr. P. K. Tiwari
MD, M.Sc (Radio Imaging)
Ph.D (Alt Nuclear Medicine)
Consultant Imagonologist & Sonologist

Dr. S. Kumar
MD (Pat)
Consultant Pathologist

Dr. Abhishek Kumar
MBBS, MD
Consultant Neuropatho Physiologist

Dr. Kumari Suman
MBBS, DGO, MD
Consultant (TVS & HSG Specialist)

Dr. A. K. Singh
MBBS, PGDMCH
Consultant Radiologist & Sonologist

PRINTING MISTAKE SHOULD BE REPORTED BACK IMMEDIATELY/यहाँ जन्म से पहले भुण का लिंग जाँच नहीं होता है ।

Shubham Imaging & ALC Diagnostic Center

ISO 9001:2015 Certified center

(A Unit of P.K. Arogyam Health & Wellness Center)

E-95, P.C. Colony, Near Sai Netryalaya Transformer, Kankarbagh, Patna - 20

alcdiagnostics@gmail.com

www.pkarogyamhealthcheckup.com

7050037694, 8271206196

OPINION MUST BE CORRELATES WITH CLINICALLY & OTHER INVESTIGATION FOR FINAL DIAGNOSIS. NOT FOR MEDICO LEGAL PURPOSE

PATIENT NAME : Mrs. ANAMIKA KUMARI

PATIENT ID: 178

COL DATE : 25/02/2023 REPORTING DATE: 25/02/2023 AGE SEX : 28 YRS/F

REF.BY : DR./ MEDIWHEEL.

GLYCOSYLATED HEMOGLOBIN

TEST NAME	RESULT	Unit	REF.RANGE
HbA1c	3.8 %		Below 5.7 % : Normal 5.7 – 6.4 % : Prediabetic > = 6.5 % : Diabetic
AVERAGE PLASMA GLUCOSE	91.0 mg/dl		90 – 120 mg/dl : Good Control 121– 150 mg/dl : Fair Control 151- 180 mg/dl: Unsatisfactory Control >180 mg/dl : Poor Control



Consultant Radiologist

ESTB BY:-

Dr. P. K. Tiwari
MD, M.Sc (Radio Imaging)
Ph.D (Alt Nuclear Medicine)
Consultant Imaginationist & Sonologist

Dr. S. Kumar
MD (Pat)
Consultant Pathologist

Dr. Abhishek Kumar
MBBS, MD
Consultant Neuropathology & Physiologist

Dr. Kumari Suman
MBBS, DGO, MD
Consultant (TVS & HSG Specialist)

Dr. A. K. Singh
MBBS, PGDMCH
Consultant Radiologist & Sonologist

PRINTING MISTAKE SHOULD BE REPORTED BACK IMMEDIATELY/ यहाँ जन्म से पहले भ्रूण का लिंग जाँच नहीं होता है ।

Shubham Imaging & ALC Diagnostic Center

ISO 9001:2015 Certified center

(A Unit of P.K. Arogyam Health & Wellness Center)

E-95, P.C. Colony, Near Sai Netryalaya Transformer, Kankarbagh, Patna - 20

alcdiagnostics@gmail.com

www.pkarogayamhealthcheckup.com

7050037694, 8271206196

OPINION MUST BE CORRELATES WITH CLINICALLY & OTHER INVESTIGATION FOR FINAL DIAGNOSIS. NOT FOR MEDICO LEGAL PURPOSE

PATIENT NAME : Mrs .ANAMIKA KUMARI

PATIENT ID: 178

COL DATE : 25/02/2023 REPORTING DATE: 25/02/2023 AGE SEX:- 28 YRS/F

REF.BY : DR. /MEDIWHEEL.

ROUTINE EXAMINATION OF URINE

PHYSICAL EXAMINATION


Quantity	30 ml	Colour... .	Straw
Appearance...	Clear	Sediment ...	Nil
Specific gravity....	1.010		

CHEMICAL EXAMINATION

Reaction	6.0	Nitrite.....	Not done
Sugar	Nil	Bile Pigment	Not done
Albumin	Nil	Urobilinogen....	Not done
Excess of Phosphate....	Nil	Chile.....	Not done
Bile Salt	Not Done	Acetone...	Not done

MICROSCOPIC EXAMINATION

Erythrocytes....	Nil	Casts	Nil
Leucocytes	1-3 / HPE	Crystals....	Nil
Epith. Cell	A, Few	Others	Nil


Consultant Radiologist

ESTB BY:-

Dr. P. K. Tiwari
MD, M.Sc (Radio Imaging)
Ph.D (Alf Nuclear Medicine)
Consultant Imagonologist & Sonologist

Dr. S. Kumar
MD (Pat)
Consultant Pathologist

Dr. Abhishek Kumar
MBBS, MD
Consultant Neuropatho Physiologist

Dr. Kumari Suman
MBBS, DGO, MD
Consultant (TVS & HSG Specialist)

Dr. A. K. Singh
MBBS, PGDMCH
Consultant Radiologist & Sonologist

PRINTING MISTAKE SHOULD BE REPORTED BACK IMMEDIATELY/ यहाँ जन्म से पहले भुण का लिंग जाँच नहीं होता है ।

Shubham Imaging & ALC Diagnostic Center

ISO 9001:2015 Certified center

(A Unit of P.K. Arogyam Health & Wellness Center)

E-95, P.C. Colony, Near Sai Netryalaya Transformer, Kankarbagh, Patna - 20

alcdiagnostics@gmail.com

www.pkarogayamhealthcheckup.com

7050037694, 8271206196

OPINION MUST BE CORRELATES WITH CLINICALLY & OTHER INVESTIGATION FOR FINAL DIAGNOSIS. NOT FOR MEDICO LEGAL PURPOSE

PATIENT NAME : Mrs.ANAMIKA KUMARI PATIENT ID: 178
COL DATE : 25/02/2023 REPORTING DATE: 25/02/2023 AGE SEX : 28 YRS/F
REF.BY : DR. / MEDIWHEEL..


TEST NAME	RESULT	Unit	REF.RANGE
Total Triiodothyronin T3	1.84	ng/mL	0.80 -2.00 ng/mL
Total Thyroxin T4	10.31	µg/dL	5.10 -14.10 µg/dL
Serum TSH	1.59	µIU/mL	0.27 – 4.20 µIU/mL

THYROID DISORDER (>: Increase: < Decrease: n Normal

1. T3(n) T4(n) TSH(n) :EUTHYROID STATE:
2. T3(>) T4(>) TSH(<): HYPERTHYROIDISM:
3. T3(<)T4(<) TSH(>): HYPOTHYROIDISM:
4. T3(n)T4(n) TSH(>) : SUB-CLINICAL HYPO-THYROIDISM:
5. T3(n)T4(n) TSH(<): SUB-CLINICAL HYPER-THYROIDISM:
6. T3(>) T4(n) TSH(<): T3 THYROTOXICOSIS:

Total T3/T4 level is dependent on Level:

So determination of free T3/T4is a better MARKER of Thyroid Function.



Consultant Radiologist

ESTB BY:-

Dr. P. K. Tiwari
MD, M.Sc (Radio Imaging)
Ph.D (Alf Nuclear Medicine)
Consultant Imagonologist & Sonologist

Dr. S. Kumar
MD (Pat)
Consultant Pathologist

Dr. Abhishek Kumar
MBBS, MD
Consultant Neuropatho Physiologist

Dr. Kumari Suman
MBBS, DGO, MD
Consultant (TVS & HSG Specialist)

Dr. A. K. Singh
MBBS, PGDMCH
Consultant Radiologist & Sonologist

PRINTING MISTAKE SHOULD BE REPORTED BACK IMMEDIATELY/ यहाँ जन्म से पहले भुण का लिंग जाँच नहीं होता है ।

Shubham Imaging & ALC Diagnostic Center

ISO 9001:2015 Certified center

(A Unit of P.K. Arogyam Health & Wellness Center)

E-95, P.C. Colony, Near Sai Netryalaya Transformer, Kankarbagh, Patna - 20

alcdiagnostics@gmail.com

www.pkarogayamhealthcheckup.com

7050037694, 8271206196

OPINION MUST BE CORRELATES WITH CLINICALLY & OTHER INVESTIGATION FOR FINAL DIAGNOSIS. NOT FOR MEDICO LEGAL PURPOSE

PATIENT NAME : Mrs. ANAMIKA KUMARI

PATIENT ID: 178

COL DATE : 25/02/2023 REPORTING DATE: 25/02/2023 AGE SEX:- 28 YRS/F

REF.BY : DR./ MEDIWHEEL..

TEST NAME	RESULT	Unit	REF.RANGE
LFT:-			
SGPT	27.2 IU/L		5 - 48 IU/L
S G O T	24.3 IU/L		5 - 40 IU/L
ALKALINE PHOSPHATASE	87.6 IU/L		25 - 147 IU/L
TOTAL PROTIN	7.6 g/dl		6.0 - 8.7 g/dl
SERUM ALBUMIN	4.7 g/dl		3.5 - 5.4 g/dl
SERIUM GLUBLINE	2.9 g/dl		2.3 - 3.6 g/dl
AG RATIO	1.6 : 1		1.0 - 2.3 g/dl
BILIRUBIN			
TOTAL	0.57 mg/dl		0.1 - 1.1 mg/dl
IRECT	0.21 mg/dl		0.0 - 0.32 mg/dl
INDIRECT	0.38 mg/dl		0.0 - 0.78 mg/dl
GGTP (GGT)	23.4 iu/L		8 - 38 iu/L
KFT/RFT			
URIC ACID	3.9 mg/dl		3.2 - 7.0 mg/dl
SERUM CREATNINE	0.8 mg/dl		0.6 - 1.5 mg/dl
BLOOD URIA	29.2 mg/dl		5 - 45 mg/dl
BLOOD URIA NITROZEN(BUN).	13.6 mg/dl		5 - 24 mg/dl


25/02/23

Consultant Radiologist

ESTB BY:-

Dr. P. K. Tiwari
MD, M.Sc (Radio Imaging)
Ph.D (Altr Nuclear Medicine)
Consultant Imagianologist & Sonologist

Dr. S. Kumar
MD (Pat)
Consultant Pathologist

Dr. Abhishek Kumar
MBBS, MD
Consultant Neuropatho Physiologist

Dr. Kumari Suman
MBBS, DGO, MD
Consultant (TVS & HSG Specialist)

Dr. A. K. Singh
MBBS, PGDMCH
Consultant Radiologist & Sonologist

PRINTING MISTAKE SHOULD BE REPORTED BACK IMMEDIATELY/ यहाँ जन्म से पहले भुण का लिंग जाँच नहीं होता है ।

Shubham Imaging & ALC Diagnostic Center

ISO 9001:2015 Certified center

(A Unit of P.K. Arogyam Health & Wellness Center)

E-95, P.C. Colony, Near Sai Netryalaya Transformer, Kankarbagh, Patna - 20

alcdiagnostics@gmail.com

www.pkarogyamhealthcheckup.com

7050037694, 8271206196

OPINION MUST BE CORRELATES WITH CLINICALLY & OTHER INVESTIGATION FOR FINAL DIAGNOSIS. NOT FOR MEDICO LEGAL PURPOSE

PATIENT NAME : Mrs. ANAMIKA KUMARI

PATIENT ID: 178

COL DATE : 25/02/2023 REPORTING DATE: 25/02/2023 AGE SEX:- 28 YRS/F

REF.BY : DR. / MEDIWHEEL.

TEST NAME	RESULT	Unit	REF.RANGE
ESR	16 mm/hr		<20 mm/hr
CBC			
Total W.B.C. Count	6,800 /cumm		4,000-11,000 /cumm
R B C COUNT	4.01 Million/ CUmm		4 - 7 Million/ CUmm
Platelets count	1.92 Lakh/ cumm		1.5-5.0 Lakh/ cumm
Differential Count of W.B.C.			
Neutrophils	58 %		40-70%
Lymphocytes	35 %		25-40%
Eosinophils	06 %		01-05%
Mnonocytes	01 %		00-02%
Basophiles	00 %		00 -0%
HAEMOGLOBIN	11.8 gm/dl (80.8%)		14.6 gm/dl = 100%
PCV	34.7 %		35-47 %
MCV	86.0 fl		76-96 fl
MCH	30.2 pg		29-35 pg
MCHC	35.1 %		30-38 %

AK
25/02/23

ESTB BY:-

Dr. P. K. Tiwari
MD, M.Sc (Radio Imaging)
Ph.D (Ali Nuclear Medicine)
Consultant Imaginologist & Sonologist

Dr. S. Kumar
MD (Pat)
Consultant Pathologist

Dr. Abhishek Kumar
MBBS, MD
Consultant Neuropatho Physiologist

Dr. Kumari Suman
MBBS, DGO, MD
Consultant (TVS & HSG Specialist)

Dr. A. K. Singh
MBBS, PGDMCH
Consultant Radiologist & Sonologist

Consultant Radiologist

PRINTING MISTAKE SHOULD BE REPORTED BACK IMMEDIATELY/ यहाँ जन्म से पहले भुण का लिंग जाँच नहीं होता है ।

Shubham Imaging & ALC Diagnostic Center

ISO 9001:2015 Certified center

(A Unit of P.K. Arogyam Health & Wellness Center)

E-95, P.C. Colony, Near Sai Netryalaya Transformer, Kankarbagh, Patna - 20

alcdiagnostics@gmail.com

www.pkarogyamhealthcheckup.com

7050037694, 8271206196

OPINION MUST BE CORRELATES WITH CLINICALLY & OTHER INVESTIGATION FOR FINAL DIAGNOSIS. NOT FOR MEDICO LEGAL PURPOSE

PATIENT NAME : Mrs. ANAMIKA KUMARI

PATIENT ID: 178

COL DATE : 25/02/2023 REPORTING DATE: 25/02/2023 AGE SEX:- 28 YRS/F


REF.BY : DR. / MEDIWHEEL.

TEST NAME	RESULT	Unit	REF.RANGE
-----------	--------	------	-----------

BLOOD GROUP	:	'O'	
-------------	---	-----	--

Rh Typing	:	POSITIVE	
-----------	---	----------	--

Note: Do always cross – matching before blood transfusion



ESTB BY:-

Dr. P. K. Tiwari
MD, M.Sc (Radio Imaging)
Ph.D (All Nuclear Medicine)
Consultant Imagonologist & Sonologist

Dr. S. Kumar
MD (Pat)
Consultant Pathologist

Dr. Abhishek Kumar
MBBS, MD
Consultant Neuropatho Physiologist

Dr. Kumari Suman
MBBS, DGO, MD
Consultant (TVS & HSG Specialist)

Dr. A. K. Singh
MBBS, PGDMCH
Consultant Radiologist & Sonologist

Consultant Radiologist

PRINTING MISTAKE SHOULD BE REPORTED BACK IMMEDIATELY/ यहाँ जन्म से पहले भ्रूण का लिंग जाँच नहीं होता है ।

ID: 173
AGE: 28Y 0M 0D
Cms 45K9

CASE:
ANAMEKA KUMARI
FEMALE

25/02/2023 10:31:02
ALC ADVANCE IMAGING DIAGNOSTICS
E95 PC COLONY KANKARBAGH PATNA

DATE: 61 bpm SINUS RHYTHM WITH 1ST DEGREE A-V BLOCK
R-R: 970 ms LEAD(S) UNSUITABLE FOR ANALYSIS: VI
P-R: 312 ms
QRS: 86 ms
QT: 412 ms
QTc: 414 ms

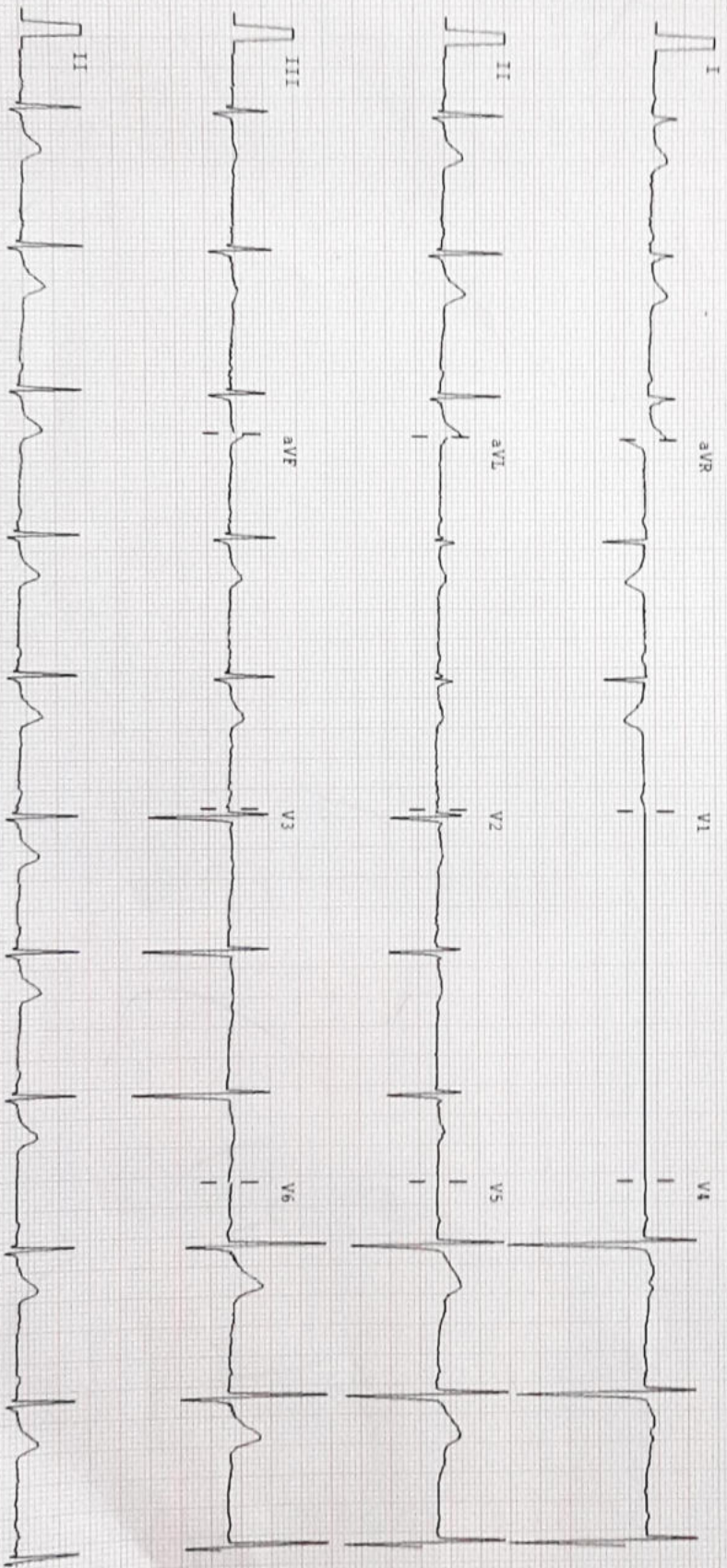
---AXIS---
P: 16°
QRS: 53°
T: 44°

ABNORMAL ECG

12 SL. REPORT FORMAT 3x4+1L SQ

REF: DR. MEDIWHEEL

Dr. DR. ABHISHEK KUMAR MD



25mm/sec 10mm/mV Notch: ON ECG: ON 0.05-35Hz ALLEGERS P15CRS 10121VER... 1.81 CLINICALLY CORRELATE THE FINDINGS.

Right

ANAMIKA KUMARI AGE 28 YEARS 178 DR BO B CHEST,FRN P->A 21-Feb-23
A.L.C. Advance Imaging Diagnostics Centre PATNA - 20



Shubham Imaging & ALC Diagnostic Center

ISO 9001:2015 Certified center

(A Unit of P.K. Arogyam Health & Wellness Center)

E-95, P.C. Colony, Near Sai Netryalaya Transformer, Kankarbagh, Patna - 20

alcdiagnostics@gmail.com

www.pkarogyamhealthcheckup.com

7050037694, 8271206196

OPINION MUST BE CORRELATES WITH CLINICALLY & OTHER INVESTIGATION FOR FINAL DIAGNOSIS. NOT FOR MEDICO LEGAL PURPOSE

Pt. Name :- ANAMIKA KUMARI
Ref. By :- DR .MEDIWHEEL

Date:- 25-Feb-23
Age / Sex – 28 Yrs. F.

Thanks for your kind referral

X-RAYCHEST (P.A.VIEW)

The lungs on the either side show equal translucency.

The peripheral pulmonary vasculature is normal.

No focal lung lesion is seen.

The pleural spaces are normal.

Both hila are normal in size, have equal density and bear normal relationship.

The heart and trachea are central in position and no mediastinal abnormality is visible.

The cardiac size is normal.

The domes of the diaphragms are normal in position, and show smooth outline.

IMPRESSION

- NO EVIDENCE OF PULMONARY OR CARDIAC PATHOLOGY IS NOTED.

25/2/23

ESTB BY:-

Dr. P. K. Tiwari
MD, M.Sc (Radio Imaging)
Ph.D (Ali Nuclear Medicine)
Consultant Imajonologist & Sonologist

Dr. S. Kumar
MD (Pat)
Consultant Pathologist

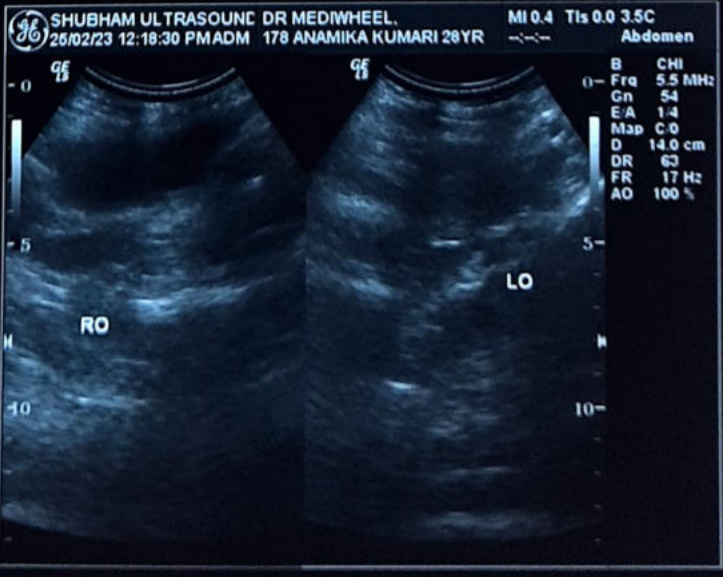
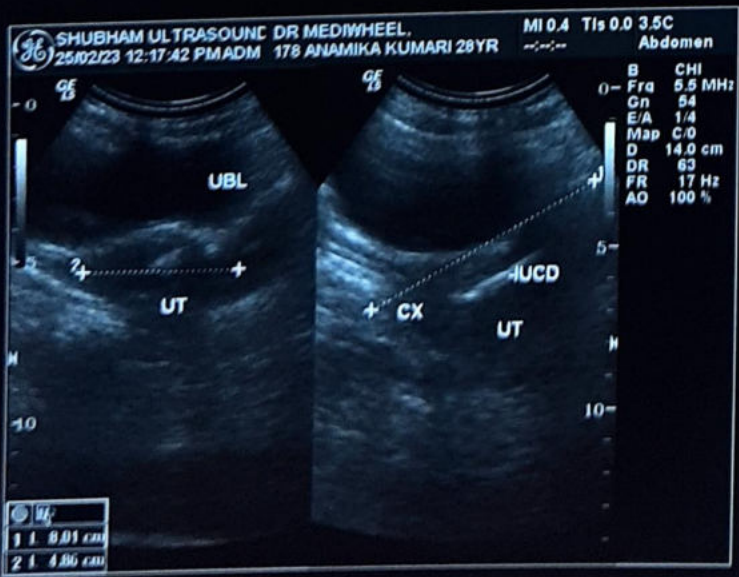
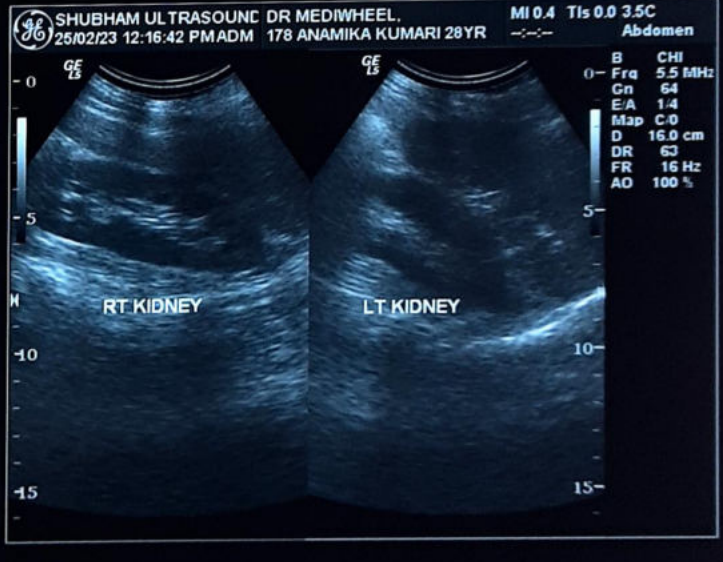
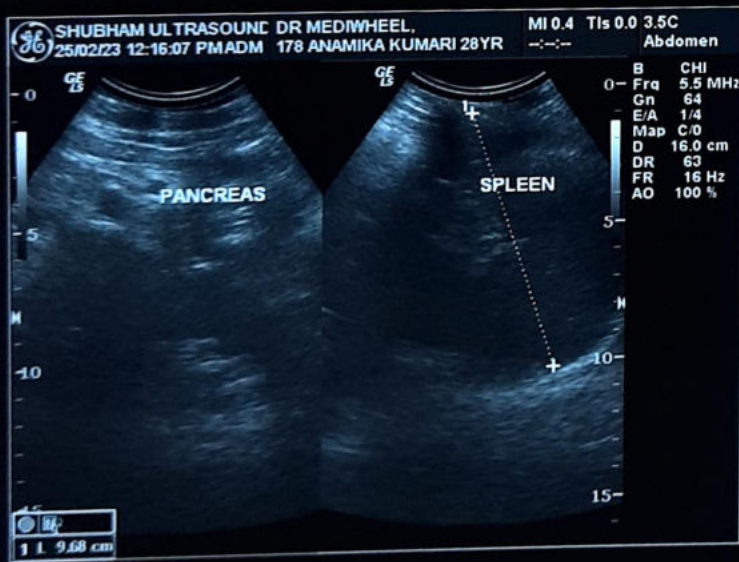
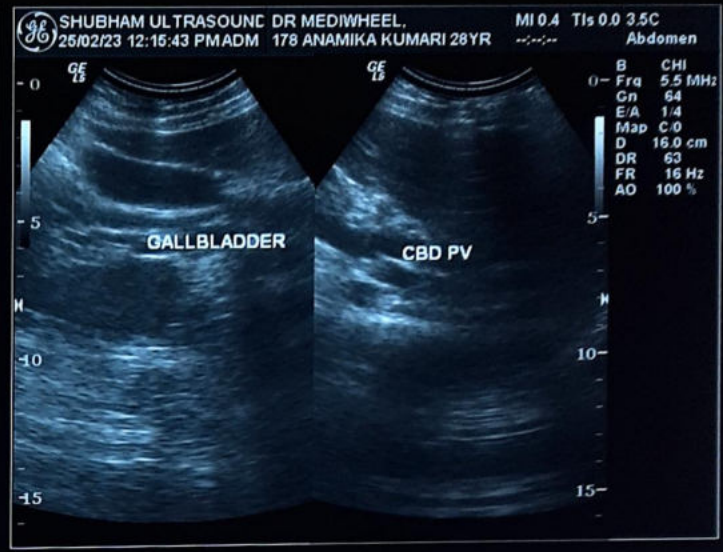
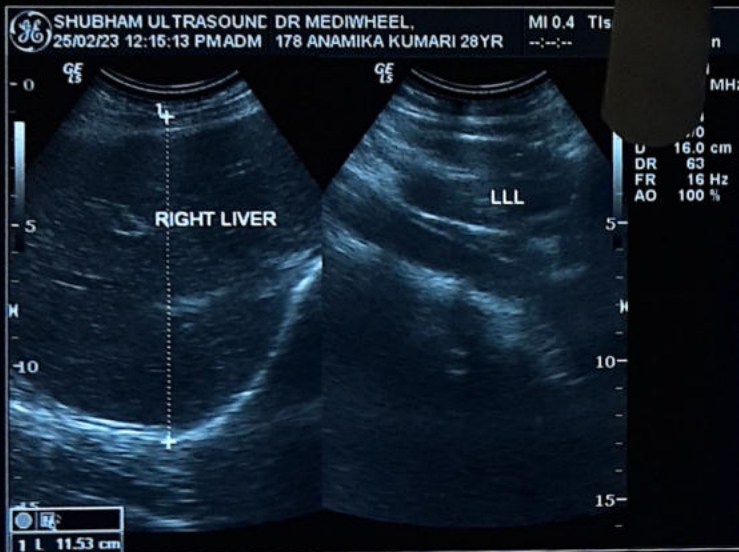
Dr. Abhishek Kumar
MBBS, MD
Consultant Neuropatho Physiologist

Dr. Kumari Suman
MBBS, DGO, MD
Consultant (TVS & HSG Specialist)

Dr. A. K. Singh
MBBS, PGDMCH
Consultant Radiologist & Sonologist

Consultant Radiologist

PRINTING MISTAKE SHOULD BE REPORTED BACK IMMEDIATELY/ यहाँ जन्म से पहले भ्रुण का लिंग जाँच नहीं होता है ।





Shubham Imaging & ALC Diagnostic Center

ISO 9001:2015 Certified center

(A Unit of P.K. Arogyam Health & Wellness Center)

E-95, P.C. Colony, Near Sai Netryalaya Transformer, Kankarbagh, Patna - 20

alcdiagnostics@gmail.com

www.pkarogyamhealthcheckup.com

7050037694, 8271206196

OPINION MUST BE CORRELATES WITH CLINICALLY & OTHER INVESTIGATION FOR FINAL DIAGNOSIS. NOT FOR MEDICO LEGAL PURPOSE

Pt. Name :- ANAMIKA KUMARI

Date:- 25-Feb-23

Ref. By :- DR. MEDIWHEEL

Age / Sex - 28 Yrs. F

REAL TIME U.S.G. OF WHOLE ABDOMEN

Thanks for your kind referral

(Report.)

- LIVER :- Measures 11.53 cm. Normal in shape, size and echo texture. I.H.B.R. are not dilated. Hepatic veins are normal. No SOL seen.
- G.BL. :- Lumen is echo free. Wall thickness appears normal.
- C.B.D. :- Measures 3.5 mm in diameter with echo free lumen. No calculi or mass seen.
- P.V. :- Measures 7.7 mm in diameter. Appears normal. No thrombus seen.
- PANCREAS :- Normal in shape, size and echo texture. No calcification mass seen.
- SPLEEN :- Measures 9.68 cm. Normal in shape, size and echo texture.
- KIDNEY :- Both kidney shows normal shape, size & echotexture. C.M.D.intact. P.C.S.is not dilated.
Right Kidney :- Measures 9.0 X 4.50 cm.
Left Kidney :- Measures 10.10 X 4.50 cm.
- URETER :- Not dilated. No apparent calculi seen.
- U.BLADDER:- Shows normal in outline with echo free lumen. No calculi or mass seen.
Pre void - 320 ml. Post void - is in significant
- UTERUS :- Normal in size measures 8.01 X 4.06 cm and Aneverted in Position Echogenicity of Myometrium is Normal
IUCD Seen In Uterine Cavity. No focal mass lesion seen cervix appear normal.
- ADNEXA :- Both ovary appears normal in size and shape.
- P.O.D :- No collection seen in P.O.D.
- R.I.F. :- Son graphically no appendicular mass or collection seen.
- OTHERS :- No Ascites No Lymph Adenopathy. No pleural Effusion seen on either side

IMPRESSION

- Normal Size Uterus With Intra uterine IUCD
- Adv:- Further work up other investigation
Otherwise son graphically normal scan. of rest organs

25/2/23

ESTD BY:-

Dr. P. K. Tiwari
MD, M.Sc (Radio Imaging)
Ph.D (Ab Nuclear Medicine)
Consultant Imaginologist & Sonologist

Dr. S. Kumar
MD (Pat)
Consultant Pathologist

Dr. Abhishek Kumar
MBBS, MD
Consultant Neuropathology Physiologist

Dr. Kumari Suman
MBBS, DGO, MD
Consultant (TVS & HSG Specialist)

Dr. A. K. Singh
MBBS, PGDMCH
Consultant Radiologist & Sonologist

Consultant Radiologist