



डॉ. सविता क्लिनिक

34, भूतल, मोहिनी अदिति आर्केड, शाहपुरा मस्जिद के पास
भरत नगर रोड, ई-7/194, अरेरा कॉलोनी, भोपाल - 462038

Mob. : 8989649694, 9516333619

Clinic Registration : CL/5392/Jun/2017

PNDT Registration : MPPCPNDT/BPL/2017/206



Name : Mrs. Nishat Shama Age 32 YRS. Female
R/B Health check-up No. 10/9/2022 Date 10/9/2022

WHOLE ABDOMES ULTRASOUND REPORT

Indication:

Liver appears normal in size and shape with normal outline. Normal/
~~increased~~ perenchymal echogenicity is noted. No E/O focal lesion/ IHBR
dilatation is seen. Hepatic veins and portal veins appear normal.

No E/O subdiaphragmatic Collection.

Gall Bladder is physiologically well distended. No. E/O echogenic foci in GB
lumen. GB wall is normal / ~~thickened~~. No E/O pericholecystic collection.
Common duct reveals normal course and caliber.

Pancreas appear normal in size, shape and echo texture with smooth
contour. No peripancreatic pathology seen. (Not seen ~~due to gases~~)

Spleen is normal in size and echo texture.

IVC and aorta appear to be normal.

No evidence of lymphadenopathy is noted.

No evidence of free fluid is noted.

Right Kidney is normal in size. size, shape and position. Corticomedullary
differentiation (CMD) is well maintained. Normal cortical thickness is
noted. No E/O hydronephrosis or calculus is noted.

PTO

Dr. P. Savita, MD

MBBS, MD (O&G) Reg. No. 9971

स्त्री रोग विशेषज्ञ

Dr. Jayant Yadav, MD

MBBS, MD (Radiologist) Reg. No. 4166

रेडियोलॉजिस्ट

Left kidney is normal in size, shape and position. CMD is well maintained. Normal cortical thickness is noted. No E/O hydronephrosis or calculus is noted.


Urinary Bladder is well distended (physiological). its contents are echo free. No E/O bladder wall thickening is noted. Post-void residue is insignificant. **Prostate** is normal in size. Shape and echo texture with smooth outline. No E/O focal lesion is noted.

Uterus is ante/ retro verted and normal in size, shape and echo texture with smooth outline. No E/O focal lesion is noted. Endometrial echo appear normal. Cervical and vaginal shadows appear normal.

Right Ovary appears enlarged / Normal in size, shape and echo texture.
Left Ovary appears enlarged / Normal in size, shape and echo texture.

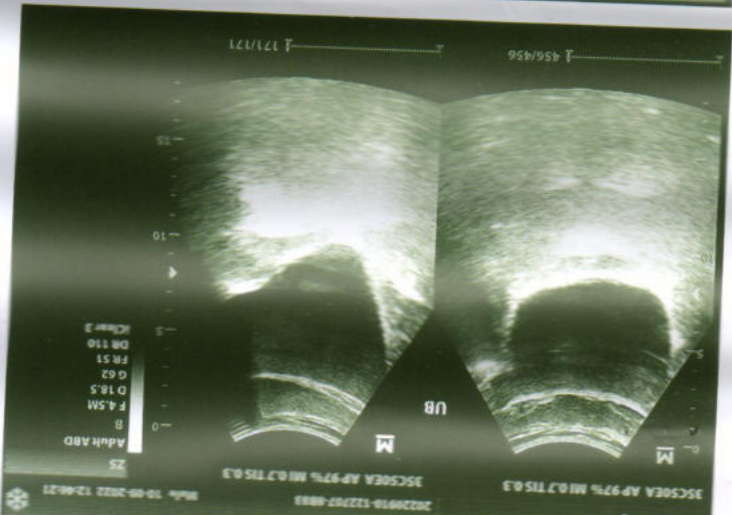
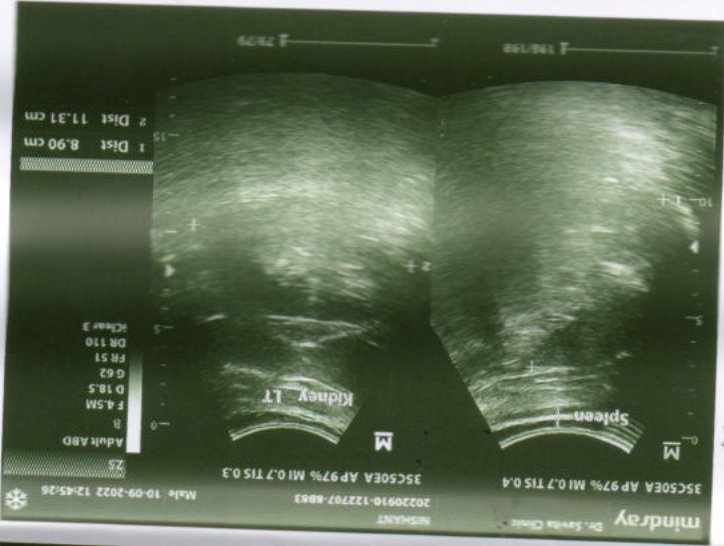
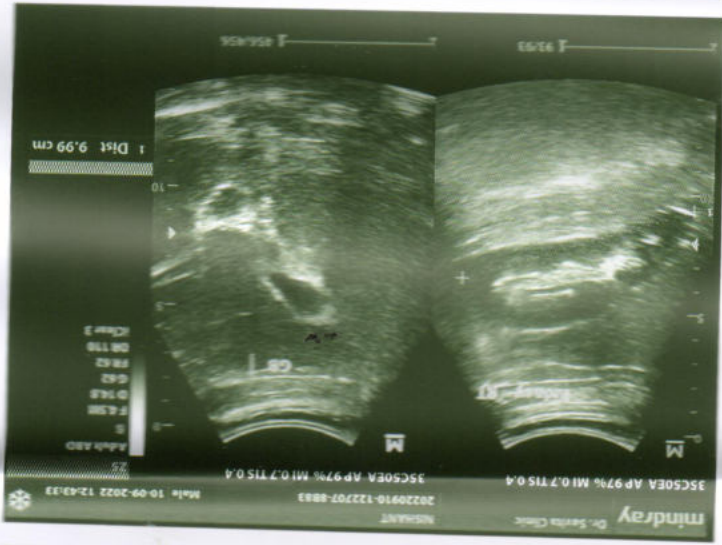
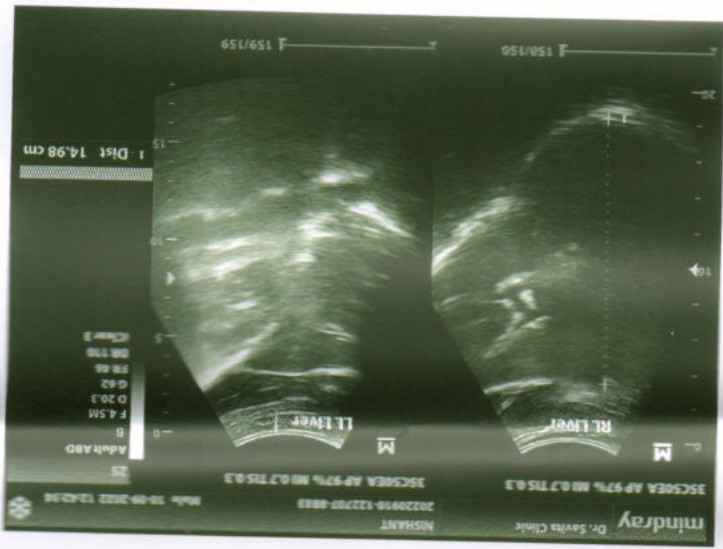
Impression : Normal study.

Advised clinical Correlation.



Dr. Jayant Yadav, MD
MBBS, MD (Radiologist) Reg. No. 4166
राज्योत्पीठ

Dr. P. Savita, MD
MBBS, MD (O&G) Reg. No. 9971
स्त्री रोग विशेषज्ञ



Dr. B. N. Agarwal
MBBS, DCP
DIPLOMA IN DIAGNOSTIC CENTRE
BHOPAL
DIPAK KUMAR

भारत सरकार
Government of India

निशांत शर्मा
Nishant Sharma

जन्म तिथि / DOB: 17/03/1990
पुरुष / Male

3300 5818 7830

मेरा आधार, मेरी पहचान



3300 5818 7830


Address: S/O: Dwarka Paul
Sharma, Village-Banhore,
Mahnan Pora, Kathua,
Mahampur, Jammu And
Kashmir, 184202

पता: अधिकार: दुवर्का पाल शर्मा
गांव-बन्होरे, महान पोरा, म्हाणपुर
कश्मीर, जम्मू आंड कश्मीर, 184202

www.uidai.gov.in

help @ uidai.gov.in

1947



IMPRESSION


-NO CARDIO PULMONARY PATHOLOGY
-CORRELATE WITH CLINICAL FINDINGS.

Tricia Central
Thoracic cage normal
Both Lungs Field Clear.
Both hilers normal
Cardiac border normal
Both cp angles clear
Both domes and diaphragm normal

REPORT

Pt Name :	Mr.Nishant Sharma
Age :	32/M
Ref.By :	BOB
Date :	10/09/2022
Skigram	X Ray Chest PA View
Radiologist	Dr. B.M.Agarwal MD (Radiology)





Dr. B.M. Agarwal
Pathologist

A. PHYSICAL EXAMINATION	
1. Colour	Pale Yellow
2. Appearance	Clear
3. Specific Gravity	Q.N.S.
B. CHEMICAL EXAMINATION	
1. Reaction	Acidic
2. Albumin	Nil
3. Sugar	Nil
4. Bile Salts	Absent
C. MICROSCOPIC EXAMINATION	
Pus Cells	2-3/HPF
R.B.C.	Nil
Epithelial Cell	occ
Cast	Nil
Crystals(Cal.Oxa)	Nil
Bacteria	Nil
Amorphous	Nil
T. Vaginitis	Nil

URINE ANALYSIS

Pt Name :- Mr. Nishant Sharma
Age :- 32/M
Date :- 10/09/2022

डिवाकर डायग्नोस्टिक सेंटर
E-7/636, पंजाब नेशनल बैंक के पास, फॉन रोड, अरुण कॉलोनी भीमपल (म.प्र.)
फोन: 0755-2465288, 0755-3520545 फॉ: 9826340190



डिवाकर डायग्नोस्टिक सेंटर



E-7/636, पंजाब नगर ल बँक के पास, मंग रोड, अरुण कॉलोनी भापाल (म.प्र.)

फोन: 0755-2465288, 0755-3520545 फा: 9826340190

Pt Name :- Mr. Nishant Sharma

Age :- 32/M

Date :- 10/09/2022

EXAMINATION OF BLOOD

TEST	RESULT	NORMAL VALUE
Haemoglobin	12.0gms%	Female 12-16gms%, Male 14-18gms%
Red Cell count	4.54	4.5-5.6 million /cumm
Platelet Count	1.79	1.5-5.6 Lac/cumm
Leucocytes per.cumm	5300/cumm	5000-11000/cumm
Neutrophils	47%	50-70%
Lymphocytes	46%	20-40%
Eosinophils	03%	0-7%
Monocytes	04%	2-8%
PCV	39.1	37-47
MCV	86.2	76-96
MCH	26.4	27-32
MCHC	30.6	31-35
ESR	09	Male 0-9, Female 0-20mm/FHR
Blood Group	"O" Positive	By slide method
Total Serum Cholesterol	187.0	100-250 mg%
Serum Triglyceride	155.0	Up to 150 mg%
Serum Cholesterol HDL	49.0	Up to 65 mg%
Serum Cholesterol LDL	107.0	Up to 125 mg%
LDL	31.0	Up to 30 mg%
S.Bilirubin(Total)	0.95	0.2-1.0mg/dl
Direct	0.50	0.0-0.25mg/dl
Indirect	0.45	
SGOT	31.0	5-35U/L
SGPT	34.5	8-40U/L
Alk Phosphatase	11.1	3-13 KA units
S. Protein(Total)	6.5	6.0-8.0mg%
Albumin	4.3	3.7-5.3mg%
Globulin	2.2	1.5 to 3.5 mg%
Blood Urea	19.0	Up to 40 mg%
S.Creatine	0.89	0.5-1.4mg/dl
S. Uric Acid	6.1	3.5-7.5mg%
GGTP	21.0	5-35 U/L/dl
Fasting Blood Sugar	98.2	Up to 110 mg%
PP Blood Sugar	116.0	Up to 125 mg%
Glycosylated Hemoglobin	5.2	Below - 6.0 % -Non Diabetic control 6-7 % -Excellent control Above- 8 % -Poor control
Thyrod Stimulating Hormone(TSH)	3.0	0.27-4.2

Pathologist

All test have technical limitation. Collaborative clinic pathological interpretation is mandatory. In case of disparity test may be repeated immediately. Typographical mistakes should be get correct instantly. This report is not valid for medico legal purpose

MBBS, DCP

Resident Pathologist




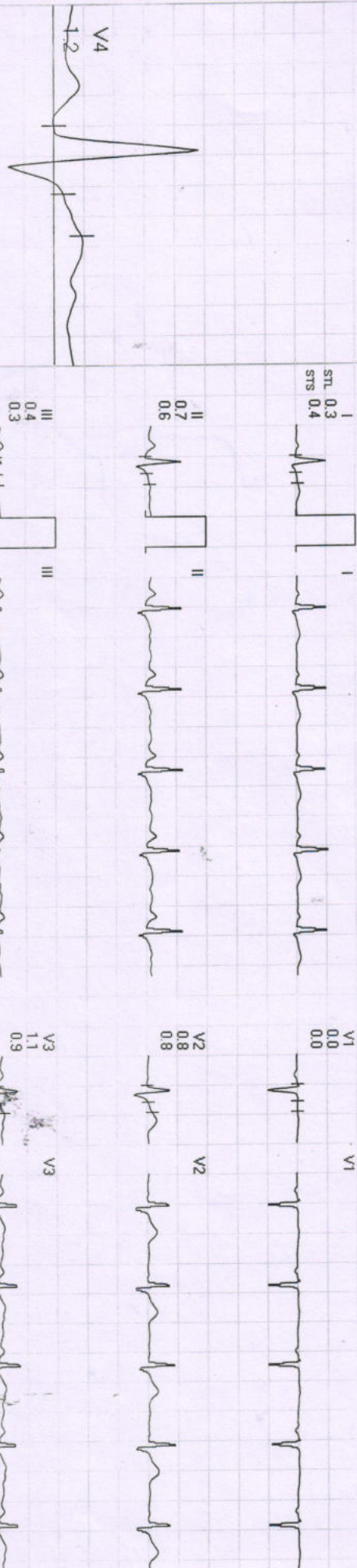
763 / NISHANT SHARMA / 32 Yrs / M

Date: 10-Sep-2022 11:16:22 AM METS: 1.0/ 94 bpm 50% of THR BP: 116/70 mmHg Raw ECG/ BLC On/ Notch On/ HF 0.05 Hz/LF 20 Hz

EXTime: 00:25 0.0 mph, 0.0%

25 mm/Sec. 1.0 Cm/mV

4X 80 ms Post J



REMARKS: II aVR aVF V2 V4 V6

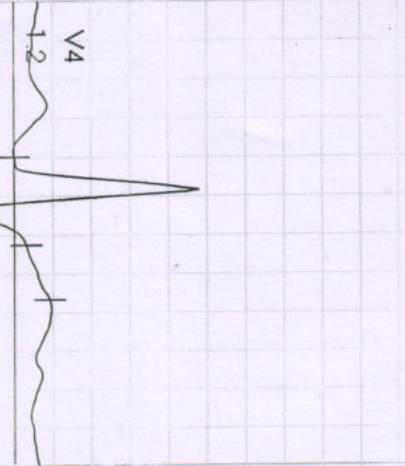
763 / NISHANT SHARMA / 32 Yrs / M

Date: 10-Sep-2022 11:16:22 AM METS: 1.0/94 bpm 50% of THR BP: 116/70 mmHg Raw ECG/ BLC On/ Notch On/ HF 0.05 Hz/LF 20 Hz

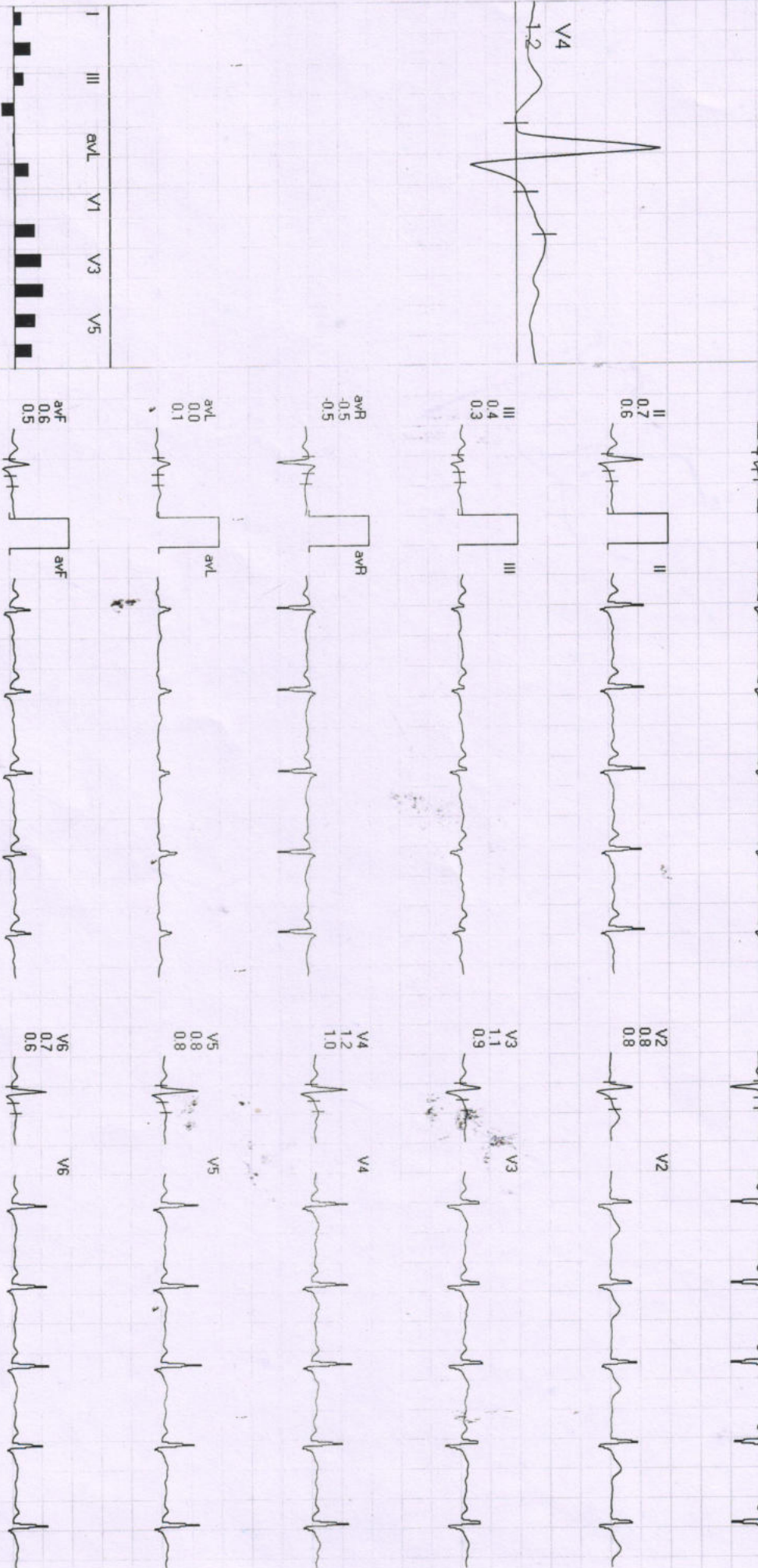
EXTime: 00:33 0.0 mph, 0.0%

4X 80 mS Post J

25 mm/Sec. 1.0 Cm/mV



STL 0.3
STS 0.4



REMARKS:
II aVR aVL V1 V3 V5


763 / NISHANT SHARMA / 32 Yrs / M

Date: 10-Sep-2022 11:16:22 AM METS: 1.0/ 95 bpm 50% of THR BP: 116/70 mmHg Raw ECG/ BLC On/ Notch On/ HF 0.05 Hz/LF 20 Hz

ExTime: 00:44 1.0 mph, 0.0%

4X 80 ms Post J

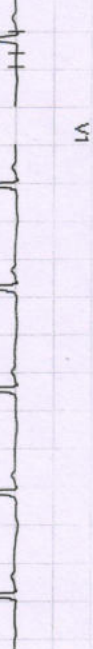25 mm/Sec 1.0 Cm/mV



I
STL 0.3
STS 0.4



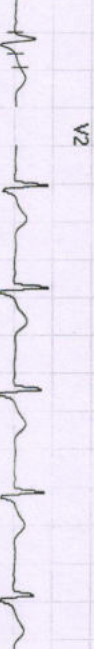V1
0.0
-0.1



II
0.7
0.7



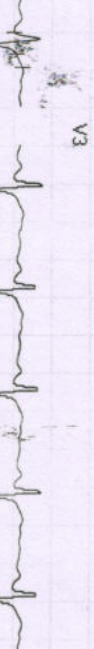V2
0.7
0.8



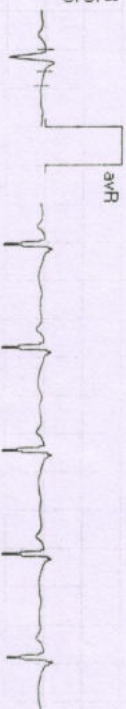III
0.4
0.3



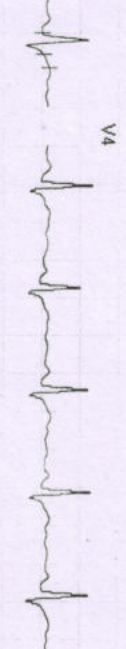V3
1.1
1.0



avR
-0.5
-0.5



V4
0.9
0.9



avL
0.0
0.0



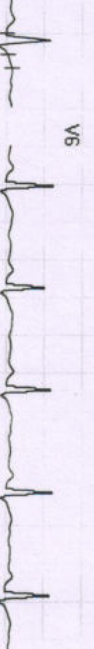V5
0.8
0.8



avF
0.6
0.5



V6
0.7
0.7



REMARKS:
II avR avF V2 V4 V6

4X

80 mS Post J

ExStt



ExTime: 00:00 0.8 mph 0.0%
25 mm/Sec. 1.0 Cm/mV

I STL 0.3
STS 0.4

II 0.7
0.7

III 0.4
0.3

avR -0.5
-0.5

avL -0.1
0.1

avF 0.5
0.5

V1 0.1
0.0

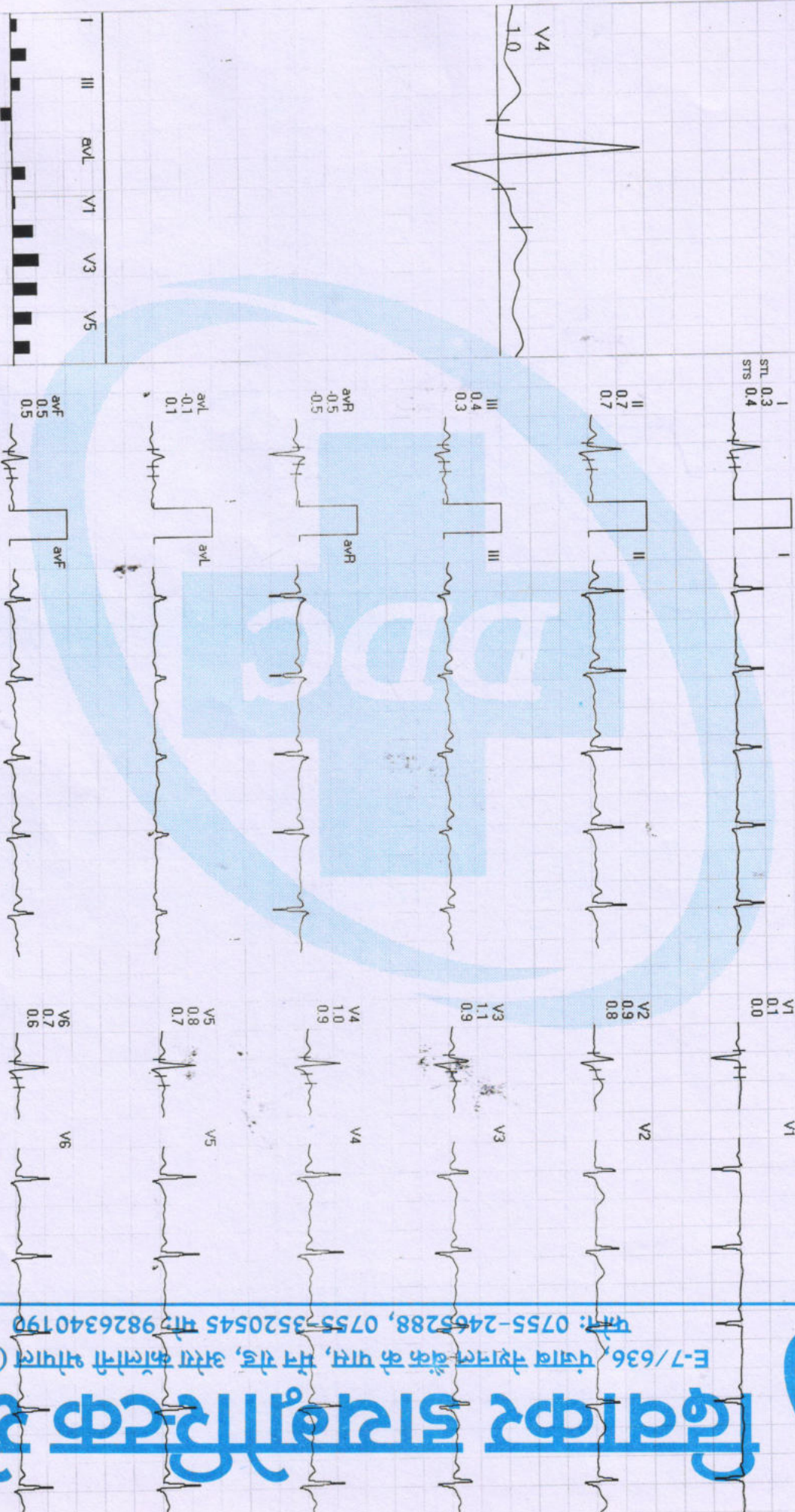

V2 0.9
0.8

V3 1.1
0.9

V4 1.0
0.9

V5 0.8
0.7

V6 0.7
0.6



REMARKS:

E-7/636, पंजाब रेजल बक के पास, मन रोड, अरुण कोलोनी थापाल (म.प्र.)
फोन: 0755-2465288, 0755-3520545 फा: 9826340190





Date: 10-Sep-2022 11:16:22 AM METS: 4.2/114 bpm 60% of THR BP: --- mmHg Raw ECG/ BLC On/ Notch On/ HF 0.05 Hz/LF 20 Hz

ExTime: 09:06 0.0 mph, 0.0%

25 mm/Sec. 1.0 Cm/mV

4X

80 ms Post J



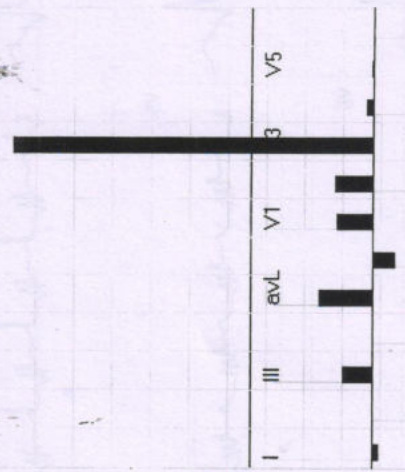
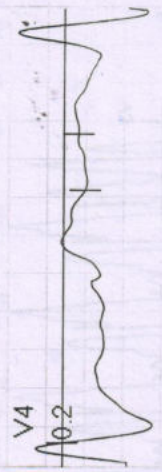
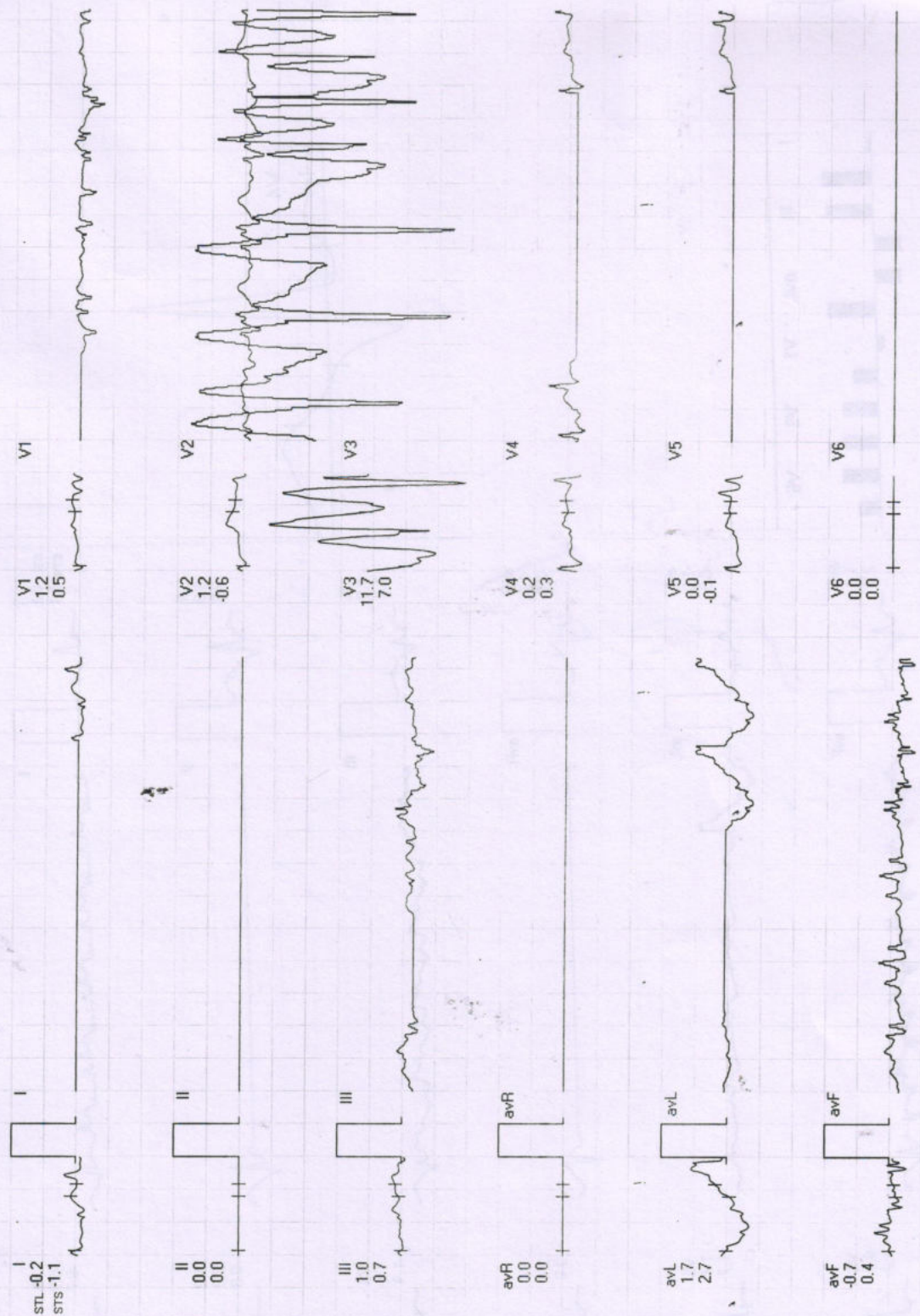
REMARKS:

Date: 10-Sep-2022 11:16:22 AM METS: 10.3/ 98 bpm 52% of THR BP: 146/90 mmHg Raw ECG/BLCOn/ Notch On/ HF 0.05 Hz/LF 20 Hz

4X

80 mS Post J

ExTime: 09:06 4.2 mph, 16.0%
25 mm/Sec. 1.0 Cm/mV



REMARKS: II avR avF V2 V4 V6



Date: 10-Sep-2022 11:16:22 AM

METS: 1.0/96 bpm 51% of THR BP: -/- mmHg Raw ECG/BLC On/Notch On/HF 0.05 Hz/LF 20 Hz

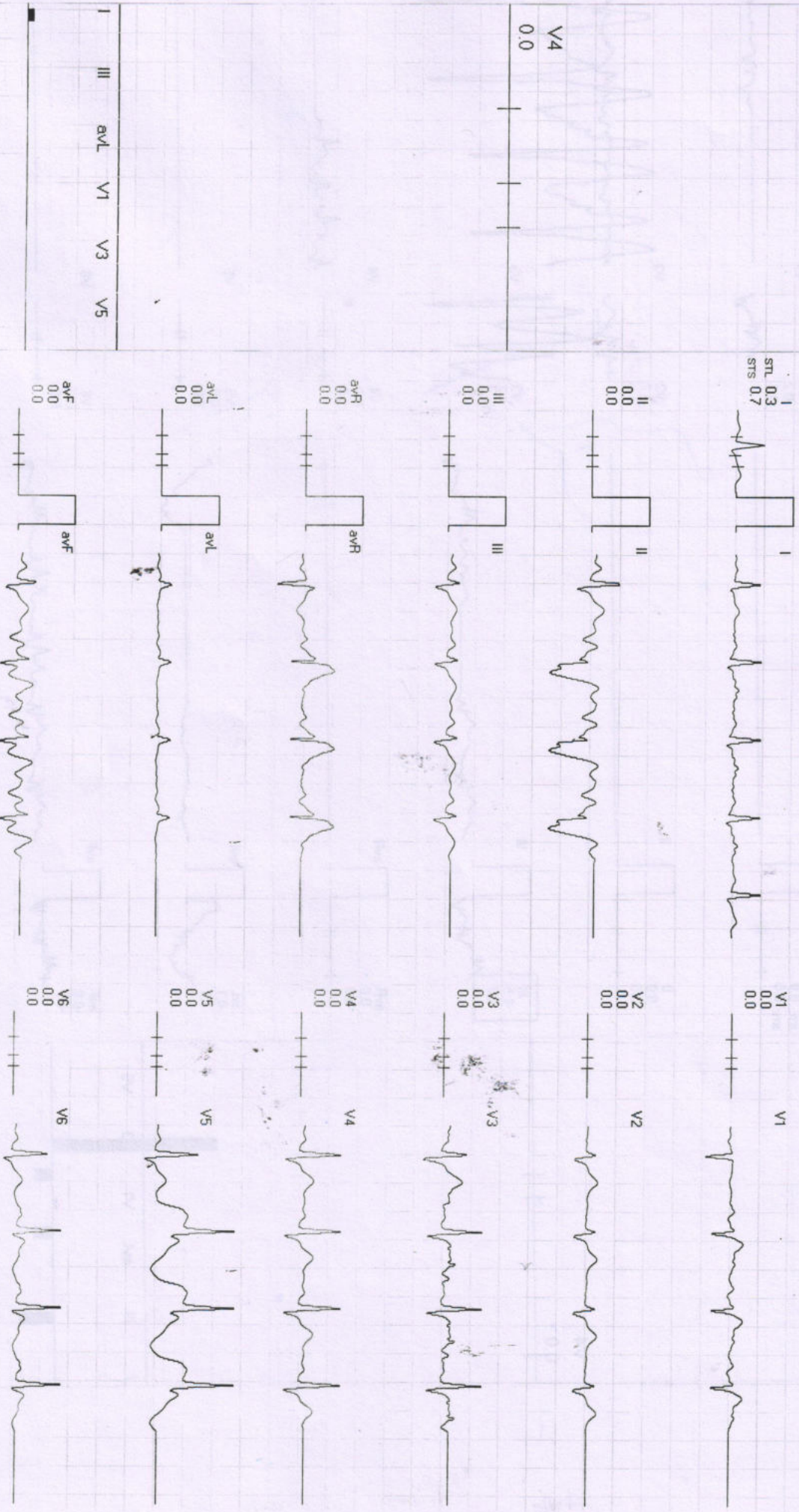
EXTime: 09:06 0.0 mph, 0.0%

4X

80 ms Post J

25 mm/Sec. 1.0 Cm/mV

STL 0.3
STS 0.7

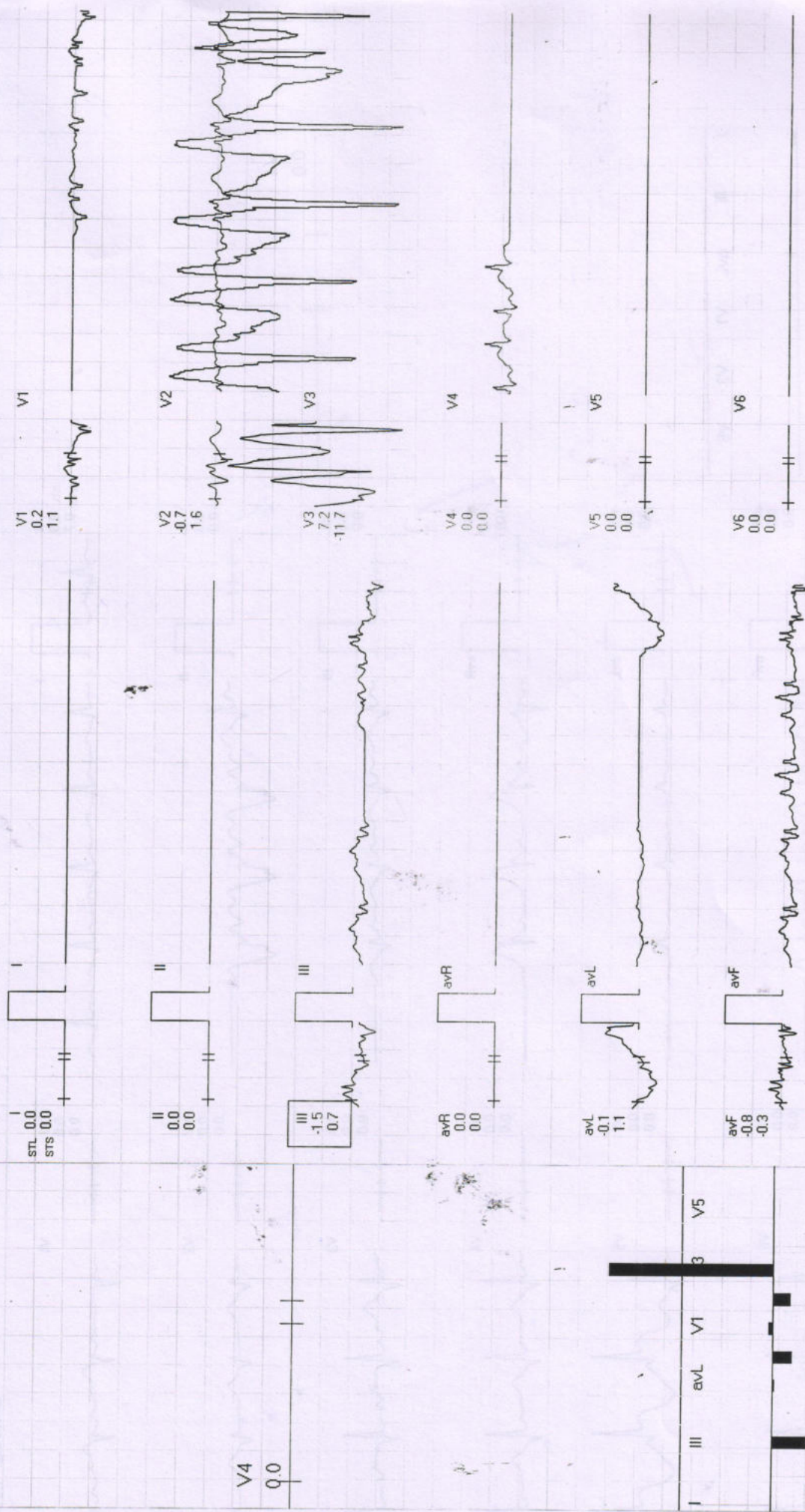


REMARKS:
II aVR aVF V2 V4 V6

Date: 10-Sep-2022 11:16:22 AM METS: 10.2/98 bpm 52% of THR BP: 146/90 mmHg Raw ECG/BLC On/ Notch On/ HF 0.05 Hz/LF 20 Hz

ExTime: 09:00 3.4 mph, 14.0%

4X 80 mS Post J



REMARKS: II avR avF V2 V4 V6

763 / NISHANT SHARMA / 32 Yrs / M / 0 Cms / 0 Kg Date: 10-Sep-2022 Refd By : BOB

(GEM213180307)(R)Allengers

Stage	Time	Duration	Belt Speed (mph)	Elevation	METS	Rate	% THR Achieved	BP	RPP	PVC	Comments
Supine	00:26	0:01	00.0	00.0	01.0	94	50 %	116/70	109	00	
Standing	00:34	0:01	00.0	00.0	01.0	94	50 %	116/70	109	00	
Warm Up	00:45	0:01	01.0	00.0	01.0	095	51 %	116/70	110	00	
ExStart	01:10	0:06	01.7	10.0	01.1	086	46 %	116/70	099	00	
BRUCE Stage 1	04:10	3:00	01.7	10.0	04.7	120	64 %	126/80	151	00	
BRUCE Stage 2	07:10	3:00	02.5	12.0	07.1	124	66 %	136/80	168	00	
BRUCE Stage 3	10:10	3:00	03.4	14.0	10.2	098	52 %	146/90	143	00	
PeakEx	10:16	0:07	00.0	00.0	10.3	098	52 %	146/90	143	00	
Recovery	11:15	1:00	00.0	00.0	04.3	114	61 %	146/90	166	00	
Recovery	12:15	2:00	00.0	00.0	01.0	096	51 %	140/86	134	00	
Recovery	12:57	2:41	00.0	00.0	01.0	100	53 %	140/86	140	00	

Findings :

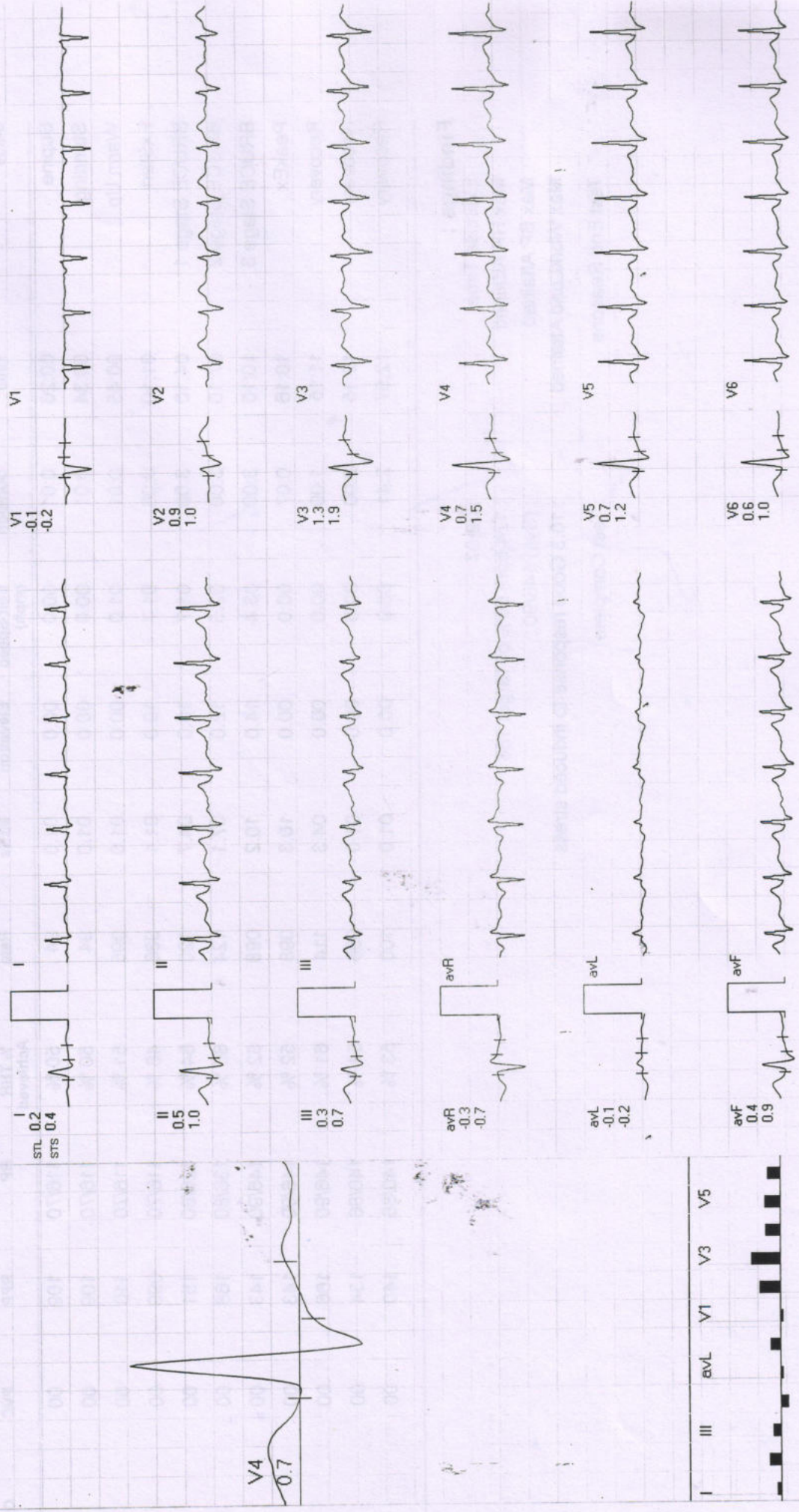
Exercise Time : 09:07
 Max HR Attained : 124 bpm 66% of Target 188
 Max BP Attained : (Sys) 146/90
 Max WorkLoad Attained : 10.3 Good response to induced stress
 Test End Reasons : Test Complete

Date: 10-Sep-2022 11:16:22 AM METS: 7.1/124 bpm 65% of THR BP: 136/80 mmHg Raw ECG/BLC On/ Natch On/ HF 0.05 Hz/LF 20 Hz

ExTime: 06:00 2.5 mph, 12.0%

4X

80 mS Post J



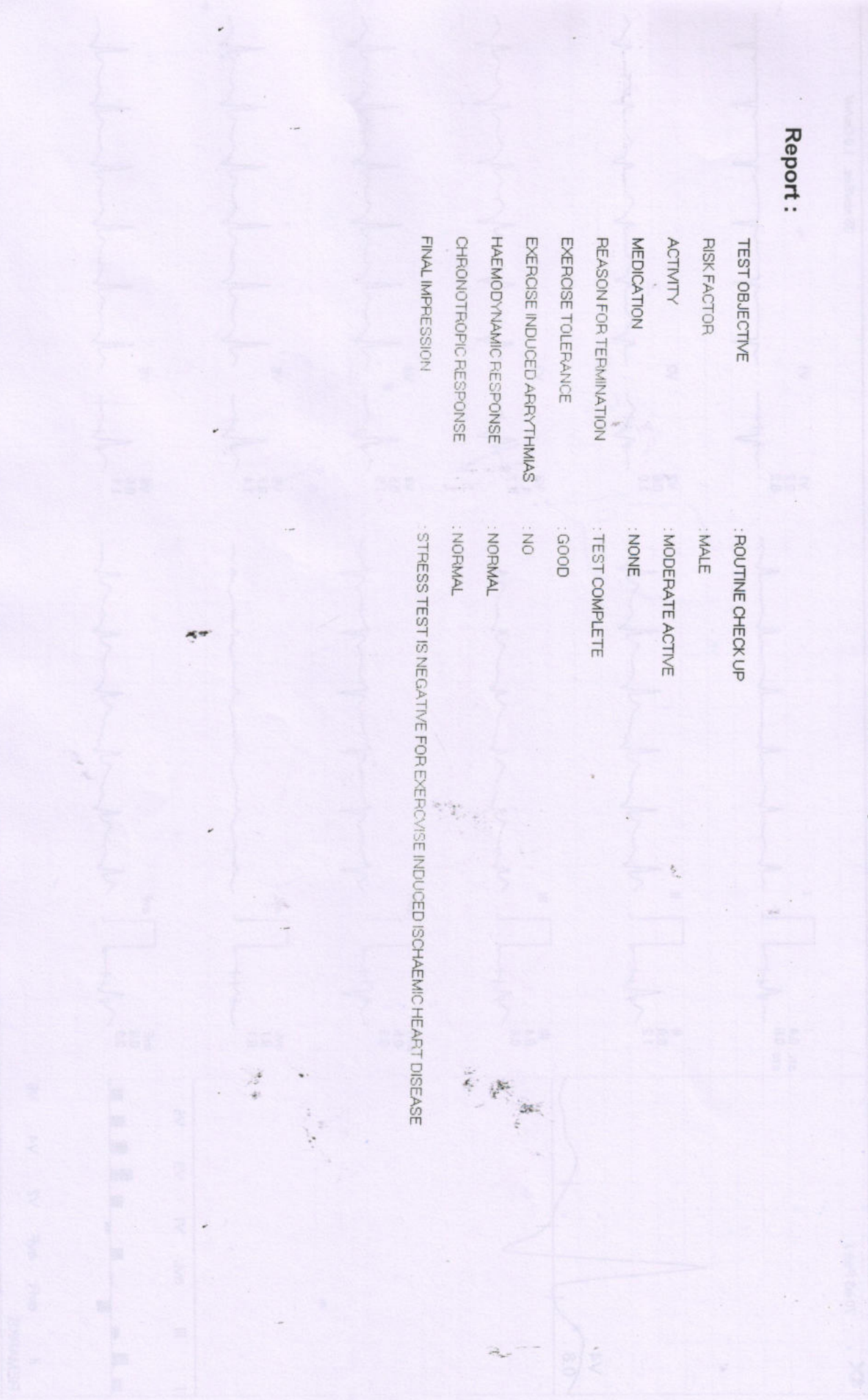
II aVR aVF V2 V4 V6

REMARKS:



Report :

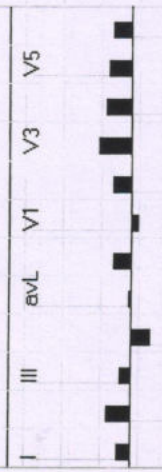
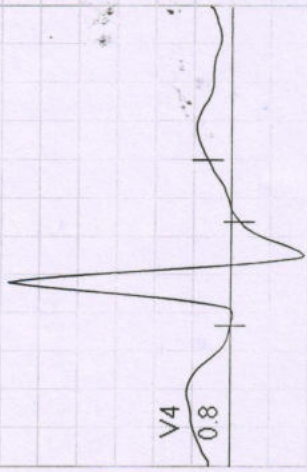
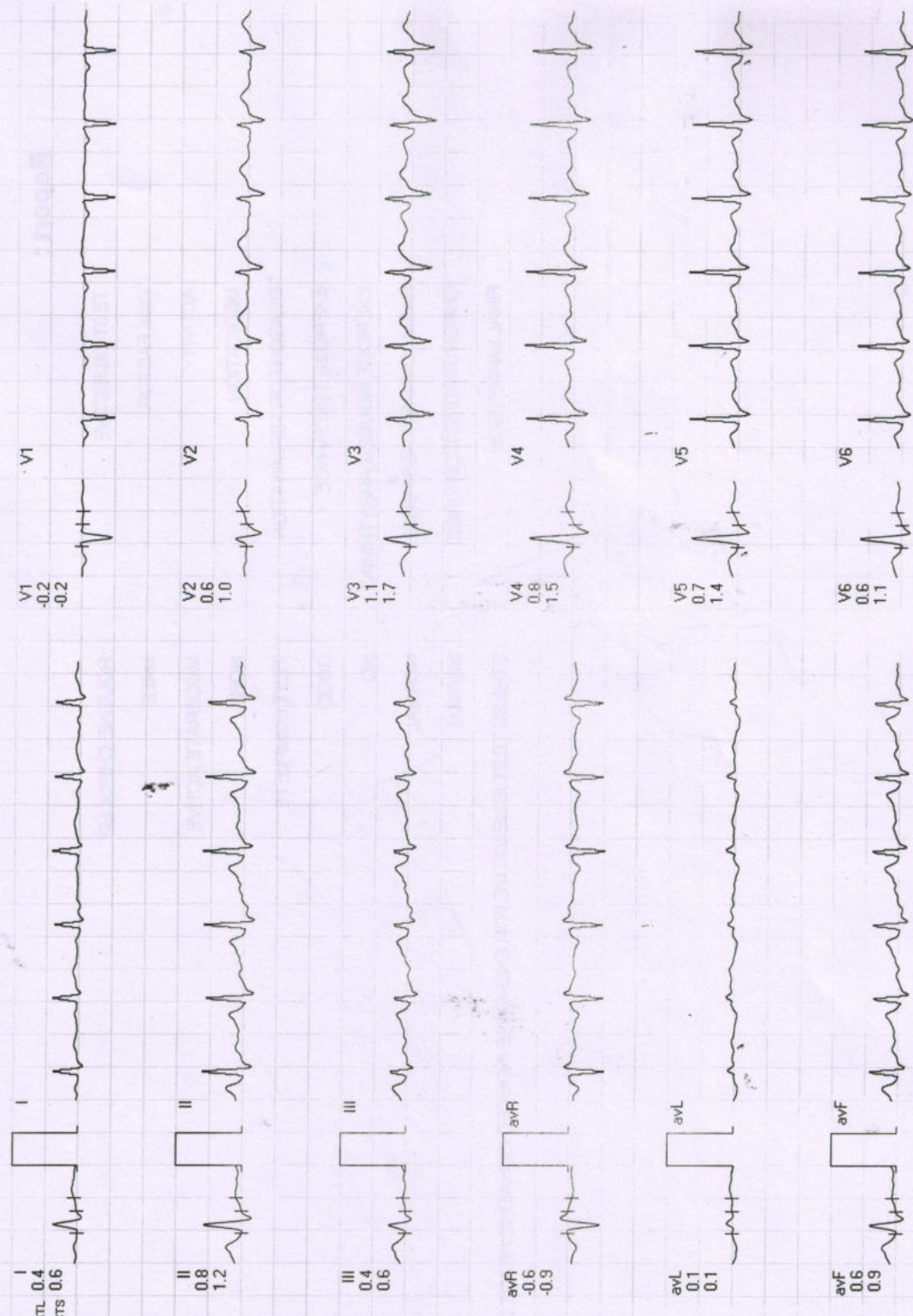
TEST OBJECTIVE	: ROUTINE CHECK UP
RISK FACTOR	: MALE
ACTIVITY	: MODERATE ACTIVE
MEDICATION	: NONE
REASON FOR TERMINATION	: TEST COMPLETE
EXERCISE TOLERANCE	: GOOD
EXERCISE INDUCED ARRHYTHMIAS	: NO
HAEMODYNAMIC RESPONSE	: NORMAL
CHRONOTROPIC RESPONSE	: NORMAL
FINAL IMPRESSION	: STRESS TEST IS NEGATIVE FOR EXERCISE INDUCED ISCHAEMIC HEART DISEASE



Date: 10-Sep-2022 11:16:22 AM METS: 4.7 / 120 bpm 63% of THR BP: 126/80 mmHg Raw ECG/BLC On/ Notch On/ HF 0.05 Hz/LF 20

ExTime: 03:00 1.7 mph, 10.0%

4X 70 mS Post J



REMARKS: II avR avF V2 V4 V6