



ভারতের নির্বাচন কমিশন
পরিচয় পত্র
ELECTION COMMISSION OF INDIA
IDENTITY CARD

ZTA2116911



নির্বাচকের নাম : মোমিতা মাইতি

Elector's Name : Moumita Maity

পিতার নাম : তপন মাইতি

Father's Name : Tapan Maity

লিঙ্গ/Scx : স্ত্রী/F

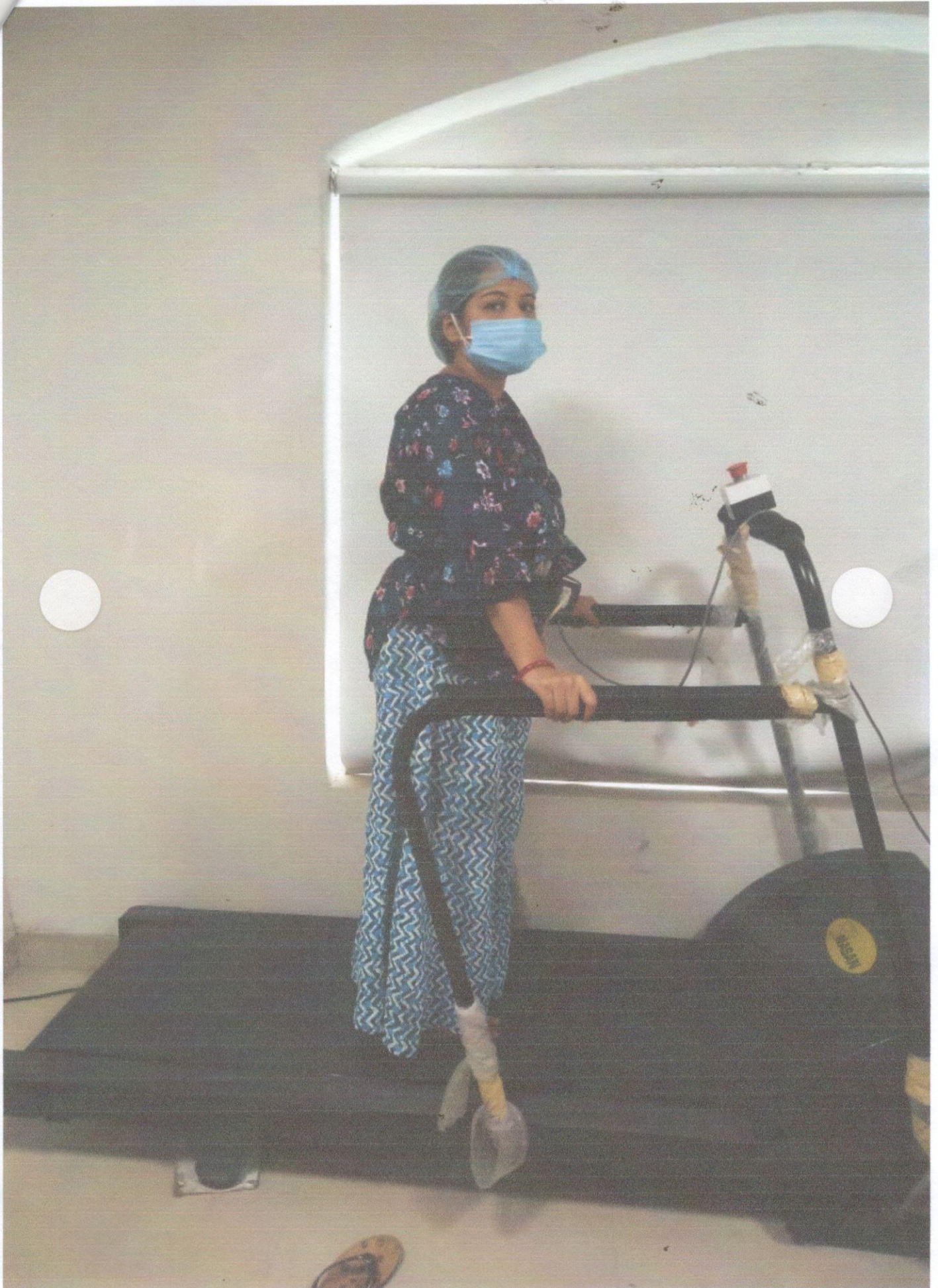জন্ম তারিখ
Date of Birth : 22/01/1993

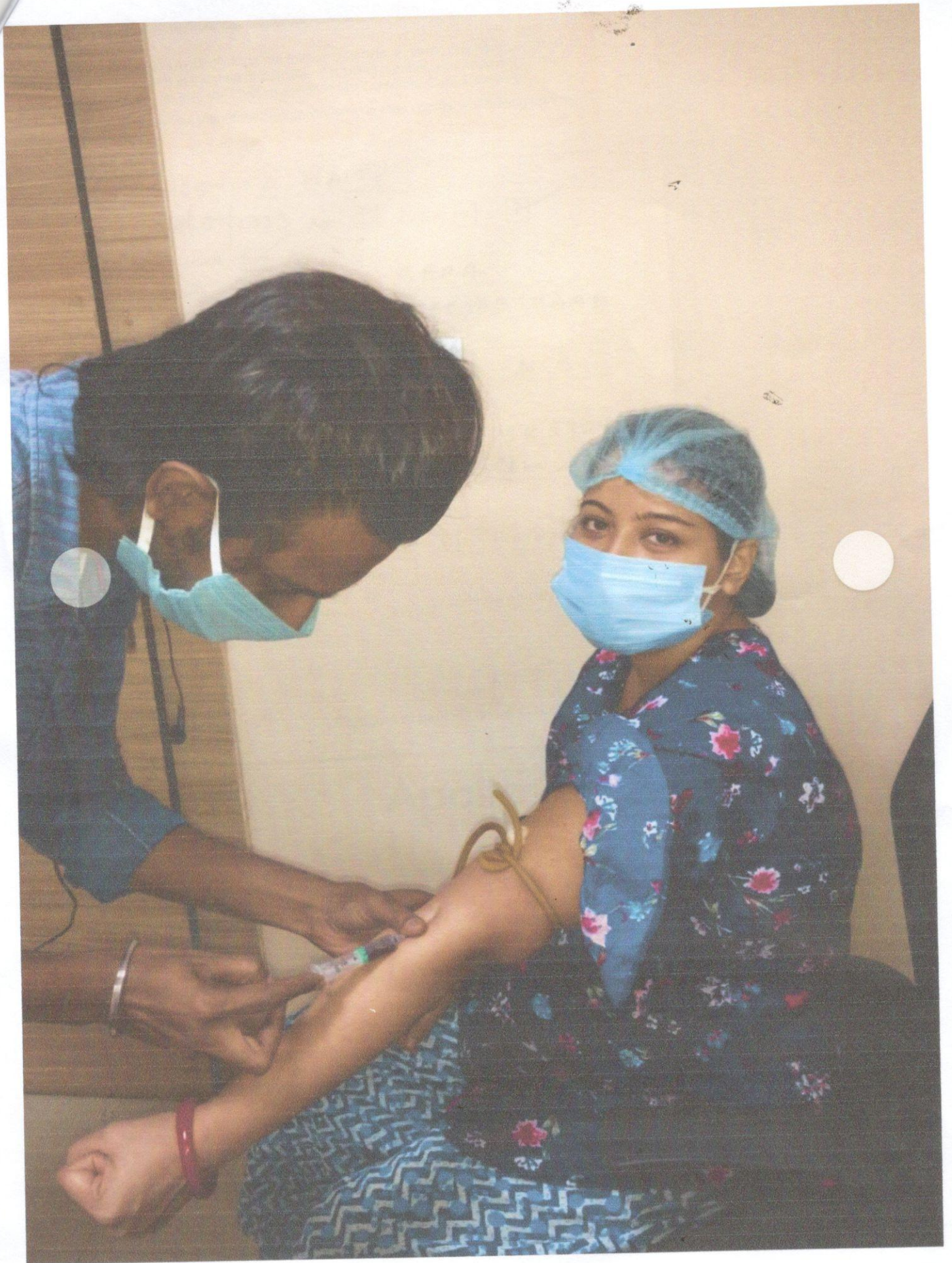
Moumita Maity
22/01/2021

28/06/2013
Municipal Health

ZTA2116911
दिनांक: 04/12/2013
8, DANESH SEKH LANE, HOWRAH
MUNICIPAL CORPORATION, SHIBPUR, HOWRAH-711109
Address:
CORPORATION, SHIBPUR, HOWRAH-711109
9
Facsimile Signature of the Electoral
Registration Officer for
173-Howrah Dakhin Constituency
Date: 04/12/2013
173-Howrah Dakhin Constituency
In case of change in address mention this Card No.
in the relevant Form for including your name in the
roll at the changed address and to obtain the card
with same number.
229/287







MR. NO- FSIN.0000000

SEX-FEMALE

NAME: -MRS. MOUMITA MAITY

EXAMINATION DATE- 26.06.2021

AGE- 28 YRS

REPORT DATE- 26.06.2021

REF DR. SELF

FINDINGS:

- Bilateral lung fields are clear.
- Tracheal shadow is in the midline.
- Bilateral CP angle are clear
- Both hilum appear normal .
- CTR appears normal .
- No definite bone fracture is noted.


DR. ARNAB MANDAL

MD, Physician, PGDUS (Delhi) CEBT-USG (WBUHS KOLKATA)
Fellow of Jefferson Ultrasound Radiology and Education Institute
Philadelphia Ex-Radiology Resident (S.E. Railway)
Regd.No:72022(WBMC)



033 2556 3333



033 2556 5555



+91 98521 66666



+91 74392 97827

NAME: MRS. MOUMITA MAITY	AGE: 28YRS	SEX: FEMALE
REF BY : SELF (CORPORATE)	MR NO: FSIN-0000	DATE: 26/06/2021

ULTRASOUND OF WHOLE ABDOMEN

LIVER: Liver is **Enlarged mild fatty changes seen**. The intrahepatic tubular structures are normal. No focal area of altered echogenicity is noted. The porta hepatis is normal. The common bile duct measures **0.44cm** in diameter. The portal vein measures **0.98cm** at porta.

GALL BLADDER: Gall bladder is normal. Wall is normal limits. No calculus or mass is seen within the gall bladder.

PANCREAS: It is normal in size, Shape, Outline and echotexture. Pancreatic duct is not dilated.

SPLEEN: It is normal in size **11.41cm**, Shape, Outline and echotexture. No parenchymal lesion is noted.

RIGHT KIDNEY: kidney are normal in position, size, shape, outline and echotexture. The cortico medullary differentiation is maintained. No calculus or hydronephrosis is seen.

RIGHT KIDNEY: measures – **9.21cm**.

LEFT KIDNEY: kidney are normal in position, size, shape, outline and echotexture. The cortico medullary differentiation is maintained. No calculus or hydronephrosis is seen.

LEFT KIDNEY: measures – **10.02cm**.

URINARY BLADDER: It is well distended with normal wall thickness. No calculus or mass is seen within the urinary bladder.

UTERUS: It is normal size, shape and echotexture. It is anteverted. No sol is seen in the myometrium. Uterine cavity is empty. Uterus measures. **(7.16cm X 3.60cm X 3.55cm)**. Endometrial thickness is **THICKENED** measures- **1.08cm**.

RIGHT OVARIES- They are normal in size, shape, outline and echotexture. measures- **(3.90cm X 1.88cm)**

LEFT OVARIES- They are normal in size, shape, outline and echotexture. measures- **(2.48cm X 1.56cm)**

POD- Free fluid present.

APOLLO CLINIC @ OM TOWER
Opp. of Rabindra Bharati University
Licensee : **Satyam Credit Pvt. Ltd.**

36C, B. T. Road, Kolkata - 700 002

E-mail : sinthimor@theapolloclinic.com
satyamcreditpvtltd@gmail.com



033 2556 3333



033 2556 5555



+91 98521 66666



+91 74392 97827

NAME:MRS.MOUMITA MAITY	AGE: 28YRS	SEX:FEMALE
REF BY : SELF(CORPORATE)	MR NO:FSIN-0000	DATE:26/06/2021

IMPRESSION:

- HEPATOMEGALY WITH MILD FATTY CHANGES.
- FREE FLUID IN POD.
- THICKENED ENDOMETRIUM.



DR.SUSMITA CHOWDHURY
MBBS,MD.
CONSULTANT SONOLOGIST

Patient Name/Mrs. MOUMITA MATTY 28/F

Resting ECG Report

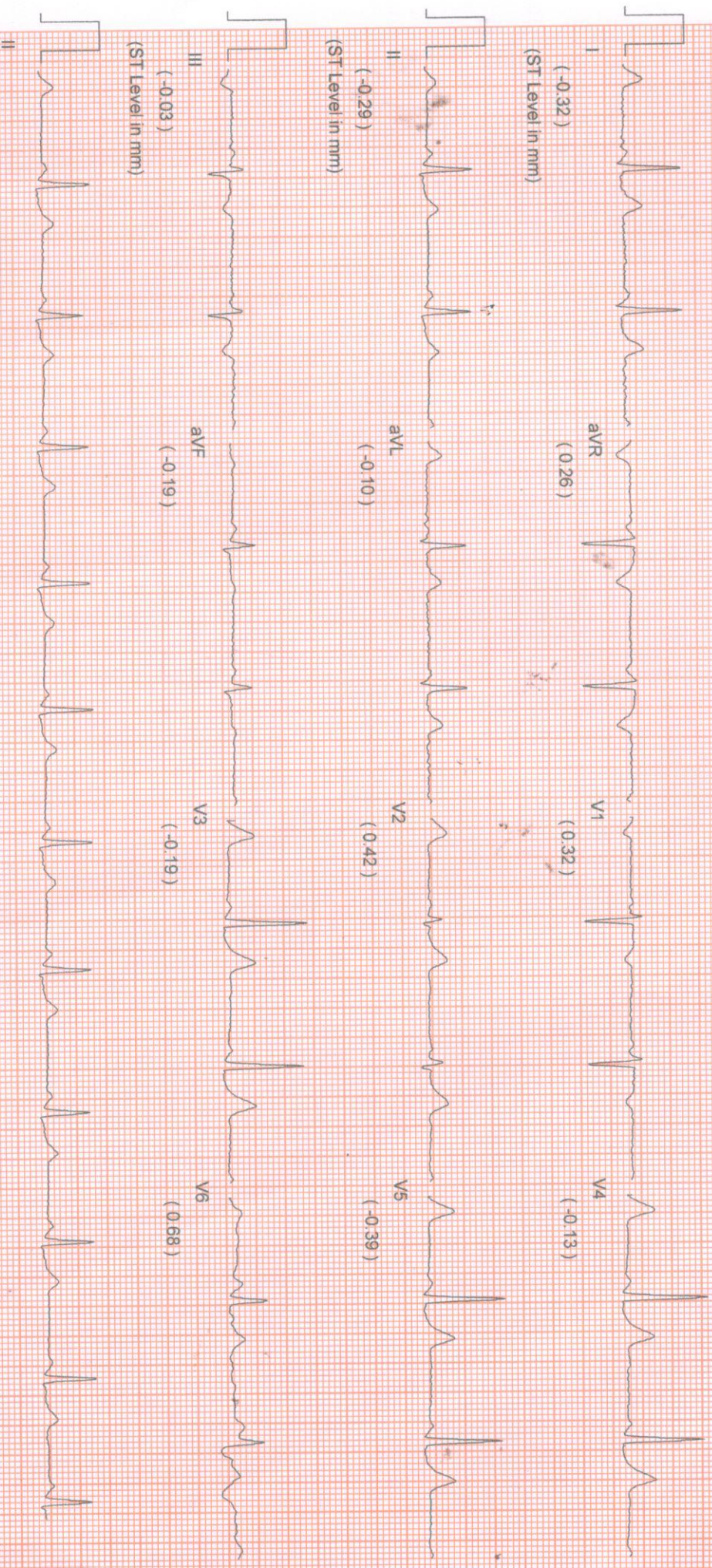
June 26, 2021
Time: 10:56:20

QT / QTc: 0.428 / 0.448 Sec
P-QRS-T Axis (26)-(24)-(11) deg

PR Interval: 0.14 sec
QRS Duration: 0.076 Sec

RR Interval: 0.91 sec

HR : 65 bpm
BP : 110 / 70 mmHg



Comments :-

Moumita Matty

NAME: MRS. MOUMITA MAITY	MR NO: FSIN-0000	DATE : 26.06.2021
AGE: 28YRS.	SEX: FEMALE	REF BY: SELF (CORPORATE)

ECG REPORT

HR : 65 b/min
 AXIS : NORMAL
 RHYTHM : SINUS
 PR INTERVAL : 0.14 sec
 QT INTERVAL : 0.448 sec
 QRS DURATION : 0.076 sec
 T-WAVE : NORMAL

IMPRESSION:

- RESTING ECG IS WITHIN NORMAL LIMITS.



Dr. SIDDHARTHA KUNDU
 MBBS (Cal), PGDCC, CCEBDM
 Clinical Cardiologist
 Ex Sr Resident, Cardiology Dept
 B.R Singh Hospital, Eastern Railways

APOLLO CLINIC @ OM TOWER
 Opp. of Rabindra Bharati University
 Licensee : Satyam Credit Pvt. Ltd.

36C, B.T. Road, Kolkata - 700 002
 E-mail : sinthimor@theapolloclinic.com
satyamcreditpvtltd@gmail.com

 **033 2556 3333**

 **033 2556 5555**

 **+91 98521 66666**

 **+91 74392 97827**