



DEPARTMENT OF RADIOLOGY

Patient Name	Mrs. GAGAN JANGIR	Billed Date	: 14/10/2023	10.02 AM
Reg No	28168	Reported Date	: 14/10/2023	
Age/Sex	35 Years 9 Months 14Days / Female	Req. No.	: 23058514	
Type	OPD	Consultant Doctor	: Dr. CONSULTANT	

X-RAY CHEST P.A. VIEW

X-RAY CHEST AP/PA

Bilateral lungs appears normal.

Both hila are normal in size, have equal density and bear normal relationship.

The heart and trachea are central in position and no mediastinal abnormality is visible.

The cardiac size is normal for patient age and view.

The domes of the diaphragms are normal in position, and show smooth outline.

To be correlated clinically

DR BINOD KR CHAUDHARY
MBBS, MD
CONSULTANT RADIOLOGIST

(This is only professional opinion and not the diagnosis, Please correlate clinically)

J-Block, Sector-10, Near Court, Faridabad - 121004, Haryana

Tel.: 0129-4200000 E-mail : parkfaridabad@gmail.com



DEPARTMENT OF PATHOLOGY

Patient Name : Mrs. GAGAN JANGIR
 MR No : 28168
 Age/Sex : 35 Years 9 Months 14 Days / Female
 Type : OPD
 TPA/Corporate : MEDIWHEEL

Bill Date : 14/10/2023
 Reporting Date : 14/10/2023
 Sample ID : 43623
 Bill/Req. No. : 23058514
 Ref Doctor : Dr. CONSULTANT

Test	Result	Bio. Ref. Interval	Units
CBC			
HAEMOGLOBIN	11.8 L	12 - 15	g/dL
PACKED CELL VOLUME	38.1	35.0 - 50.0	%
RED BLOOD CELL COUNT	4.08	3.5 - 5.5	millions/ μ L
MEAN CORPUSCULAR VOLUME	93.3	83 - 101	fL
MEAN CORPUSCULAR HAEMOGLOBIN	28.9	27 - 31	pg
MEAN CORPUSCULAR HB CONC	31.0 L	33 - 37	g/dL
RDW	12.9	11.6 - 14.5	%
TOTAL LEUCOCYTE COUNT	6100	4000-11000	μ L
DIFFERENTIAL COUNT			
NEUTROPHILS	65	40.0 - 80.0	%
LYMPHOCYTES	30	20 - 40	%
MONOCYTES	04	2.0 - 10.0	%
EOSINOPHILS	01	0.0 - 5.0	%
BASOPHILS	00	0.0 - 2.0	%
PLATELET COUNT	2.26	1.50 - 4.50	lac/cumm

***** END OF THE REPORT *****



Sample no.

Dr. VAISHALI YADAV Dr. REETU JADHAV Dr. PARDIP KUMAR S.C. GAUR
 CONS. PATHOLOGIST CONS. PATHOLOGIST MICROBIOLOGIST & ICO LAB INCHARGE USER NM DEEPCHAND

(This is only professional opinion and not the diagnosis, Please correlate clinically)

J-Block, Sector-10, Near Court, Faridabad - 121004, Haryana

Tel.: 0129-4200000 E-mail: parkfaridabad@gmail.com

PARK GROUP OF HOSPITALS : West Delhi • South Delhi • Gurgaon • Karnal • Panipat • Hodal • Ambala • Behror



DEPARTMENT OF PATHOLOGY

Patient Name : Mrs. GAGAN JANGIR
MR No : 28168
Age/Sex : 35 Years 9 Months 14 Days / Female
Type : OPD
TPA/Corporate : MEDIWHEEL

Bill Date : 14/10/2023
Reporting Date : 14/10/2023
Sample ID : 43623
Bill/Req. No. : 23058514
Ref Doctor : Dr. CONSULTANT

Test	Result	Bio. Ref. Interval	Units
------	--------	--------------------	-------

BLOOD GROUPING AND RH FACTOR

BLOOD GROUP	* B * RH POSITIVE		
-------------	-------------------	--	--

***** END OF THE REPORT *****



Sample no.

Dr. VAISHALI YADAV Dr. REETU JADHAV Dr. PARDIP KUMAR S.C. GAUR
CONS. PATHOLOGIST CONS. PATHOLOGIST MICROBIOLOGIST & ICO LAB INCHARGE USER NM DEEPCHAND

(This is only professional opinion and not the diagnosis, Please correlate clinically)

J-Block, Sector-10, Near Court, Faridabad - 121004, Haryana
Tel.: 0129-4200000 E-mail : parkfaridabad@gmail.com



DEPARTMENT OF PATHOLOGY

Patient Name : Mrs. GAGAN JANGIR
 MR No : 28168
 Age/Sex : 35 Years 9 Months 14 Days / Female
 Type : OPD
 TPA/Corporate : MEDIWHEEL

Bill Date : 14/10/2023
 Reporting Date : 14/10/2023
 Sample ID : 43623
 Bill/Req. No. : 23058514
 Ref Doctor : Dr. CONSULTANT

Test	Result	Bio. Ref. Interval	Units
BLOOD SUGAR FASTING			
PLASMA GLUCOSE FASTING	82.8	60 - 110	mg/dl

***** END OF THE REPORT *****



Sample no.

Dr. VAISHALI YADAV Dr. REETU JADHAV Dr. PARDIP KUMAR S.C. GAUR
 CONS. PATHOLOGIST CONS. PATHOLOGIST MICROBIOLOGIST & ICO LAB INCHARGE USER NM DEEPCHAND

(This is only professional opinion and not the diagnosis, Please correlate clinically)

J-Block, Sector-10, Near Court, Faridabad - 121004, Haryana
 Tel.: 0129-4200000 E-mail : parkfaridabad@gmail.com

PARK GROUP OF HOSPITALS : West Delhi • South Delhi • Gurgaon • Karnal • Panipat • Hodal • Ambala • Behror



DEPARTMENT OF PATHOLOGY

Patient Name : Mrs. GAGAN JANGIR
MR No : 28168
Age/Sex : 35 Years 9 Months 14 Days / Female
Type : OPD
TPA/Corporate : MEDIWHEEL
Bill Date : 14/10/2023
Reporting Date : 14/10/2023
Sample ID : 13623
Bill/Req. No. : 23058514
Ref Doctor : Dr CONSULTANT

Test	Result	Bio. Ref. Interval	Units
KFT (RENAL PROFILE)			
KFT			
SERUM UREA	23.5	10 - 45	mg/dL
SERUM CREATININE	0.8	0.4 - 1.4	mg/dL
SERUM URIC ACID	3.9	2.5 - 7.0	mg/dL
SERUM SODIUM	137.0	136 - 148	mmol/L
SERUM POTASSIUM	4.8	3.5 - 5.5	mmol/L
CHLORIDE	103.0	96 - 106	mmol/L

***** END OF THE REPORT *****



Sample no.

Dr. VAISHALI YADAV Dr. REETU JADHAV Dr. PARDIP KUMAR S.C. GAUR
 CONS. PATHOLOGIST CONS. PATHOLOGIST MICROBIOLOGIST & ICO LAB INCHARGE USER NAME DEEPCHAND

(This is only professional opinion and not the diagnosis, Please correlate clinically)

J-Block, Sector-10, Near Court, Faridabad - 121004, Haryana
 Tel.: 0129-4200000 E-mail: parkfaridabad@gmail.com

PARK GROUP OF HOSPITALS : West Delhi • South Delhi • Gurgaon • Karnal • Panipat • Hodal • Ambala • Behror



DEPARTMENT OF PATHOLOGY

Patient Name : Mrs. GAGAN JANGIR

MR No : 28168

Age/Sex : 35 Years 9 Months 14 Days / Female

Type : OPD

TPA/Corporate : MEDIWHEEL

Bill Date : 14/10/2023

Reporting Date : 14/10/2023

Sample ID : 43623

Bill/Req. No. : 23058514

Ref Doctor : Dr. CONSULTANT

Test	Result	Bio. Ref. Interval	Units
LFT (LIVER FUNCTION TEST)			
LFT			
TOTAL BILIRUBIN	0.5	0 - 1.2	mg/dL
DIRECT BILIRUBIN	0.2	0 - 0.4	mg/dL
INDIRECT BILIRUBIN	0.3	0.10 - 0.6	mg/dL
SGOT (AST)	21.0	0 - 45	U/L
SGPT (ALT)	19.3	0 - 45	U/L
ALKALINE PHOSPHATASE	113.0	30 - 170	IU/L
TOTAL PROTEIN	7.0	6.4 - 8.0	g/dL
ALBUMIN	4.2	3.3 - 5.5	g/dL
GLOBULIN	2.8	2.3 - 4.5	g/dL
A/G RATIO	1.5	1.1 - 2.2	

***** END OF THE REPORT *****



Sample no.

Dr. VAISHALI YADAV
CONS.PATHOLOGIST

Dr. REETU JABHAV
CONS.PATHOLOGIST

Dr. PARDIP KUMAR
MICROBIOLOGIST & ICO LAB INCHARGE

S.C.GAUR

USER NAME DEEPCHAND

(This is only professional opinion and not the diagnosis, Please correlate clinically)

J-Block, Sector-10, Near Court, Faridabad - 121004, Haryana

Tel.: 0129-4200000 E-mail : parkfaridabad@gmail.com

PARK GROUP OF HOSPITALS : West Delhi • South Delhi • Gurgaon • Karnal • Panipat • Hodal • Ambala • Behror



DEPARTMENT OF PATHOLOGY

Patient Name : Mrs. GAGAN JANGIR
 MR No : 28168
 Age/Sex : 35 Years 9 Months 14 Days / Female
 Type : OPD
 TPA/Corporate : MEDIWHEEL

Bill Date : 14/10/2023
 Reporting Date : 14/10/2023
 Sample ID : 43623
 Bill/Req. No. : 23058514
 Ref Doctor : Dr.CONSULTANT

Test	Result	Bio. Ref. Interval	Units
LIPID PROFILE			
TOTAL CHOLESTEROL	168.0	120.0 - 200.0	mg/dL
SERUM TRIGLYCERIDES	81.0	40.0 - 160.0	mg/dL
HDL-CHOLESTEROL	46.4	30 - 70	mg/dL
VLDL CHOLESTEROL	16.2	6 - 32	mg/dL
LDL	105.4	50 - 135	mg/dL
LDL CHOLESTEROL/HDL RATIO	2.27	1.0 - 3.0	mg/dL
TOTAL CHOLESTEROL/HDL RATIO	3.62	2.0 - 5.0	mg/dL

***** END OF THE REPORT *****



Sample no.

Dr. CO : Dr. VAISHALI YADAV
 CONS.PATHOLOGIST

Dr. REETU JADHAV
 CONS.PATHOLOGIST

Dr. PARDIP KUMAR
 MICROBIOLOGIST & ICO LAB INCHARGE

S.C.GAUR
 USER MM DEEPCHAND

(This is only professional opinion and not the diagnosis. Please correlate clinically)

J-Block, Sector-10, Near Court, Faridabad - 121004, Haryana
 Tel.: 0129-4200000 E-mail : parkfaridabad@gmail.com



DEPARTMENT OF PATHOLOGY

Patient Name : Mrs. GAGAN JANGIR
MR No : 28168
Age/Sex : 35 Years 9 Months 14 Days / Female
Type : OPD
TPA/Corporate : MEDIWHEEL


Bill Date : 14/10/2023
Reporting Date : 14/10/2023
Sample ID : 43623
Bill/Req. No. : 23058514
Ref Doctor : Dr. CONSULTANT

Test	Result	Bio. Ref. Interval	Units
URINE ROUTINE AND MICROSCOPY			
PHYSICAL CHARACTERSTICS			
QUANTITY	30.0 ML	5 - 100	ML
COLOUR	Pale Yellow		
TURBIDITY	CLEAR	clear	
SPECIFIC GRAVITY	1.005	1.003 - 1.030	
PH	7.0	Acidic	
CHEMICAL EXAMINATION-1			
URINE PROTEIN	NIL	NIL	
GLUCOSE	NIL	NIL	
MICRO.EXAMINATION			
PUS CELL	1 - 2/HPF		CELLS/HPF
RED BLOOD CELLS	NIL	0-2	CELLS/HPF
EPITHELIAL CELLS	1-2/HPF	0-5	CELLS/HPF
CASTS	NIL	NIL	CELLS/HPF
CRYSTALS	NIL	NIL	CELLS/HPF
OTHER	NIL		

***** END OF THE REPORT *****



Sample no.

Dr. VAISHALI YADAV Dr. REETU JADHAV Dr. PARDIP KUMAR S.C GAUR
CONS.PATHOLOGIST CONS.PATHOLOGIST MICROBIOLOGIST & ICO LAB INCHARGE USER NM 

(This is only professional opinion and not the diagnosis, Please correlate clinically)

J-Block, Sector-10, Near Court, Faridabad - 121004, Haryana
Tel.: 0129-4200000 E-mail : parkfaridabad@gmail.com



DEPARTMENT OF PATHOLOGY

Patient Name : Mrs. GAGAN JANGIR
 MR No : 28168
 Age/Sex : 35 Years 9 Months 14 Days / Female
 Type : OPD
 TPA/Corporate : MEDIWHEEL
 Bill Date : 14/10/2023
 Reporting Date : 15/10/2023
 Sample ID : 43623
 Bill/Req. No. : 23058514
 Ref Doctor : Dr. CONSULTANT

Test	Result	Bio. Ref. Interval	Units
------	--------	--------------------	-------

PAP SMEAR (FOR ONLY FEMALE)

PAP SMEAR	Conventional cervicovaginal smear
SPECIMEN TYPE	PAP
SPECIMEN ADEQUACY	Satisfactory for evaluation, with endocervical or transformation zone component.
MICROSCOPY	Smear show many superficial and intermediate squamous epithelial cells. Many endocervical cells and metaplastic cells seen. Along with this, there are sheets of polymorphonuclear cells are present. Many RBCs are also present in background. Normal bacterial flora seen. Reactive inflammatory changes seen. No candida and trichomonas seen. No atypical cells or granulomas noted.
IMPRESSION :-	Negative for intraepithelial lesion or malignancy (NILM), reactive inflammatory changes associated with inflammation. (NOTE:- Report as per the 2014 Bethesda system for report cervical cytology)

***** END OF THE REPORT *****



Sample no.

Dr. VAISHALI YADAV Dr. REETU JADHAV Dr. PARDIP KUMAR S.C. GAUR
 CONS. PATHOLOGIST CONS. PATHOLOGIST MICROBIOLOGIST & ICO LAB INCHARGE USER NM **SAMAY**

(This is only professional opinion and not the diagnosis, Please correlate clinically)

J-Block, Sector-10, Near Court, Faridabad - 121004, Haryana

Tel.: 0129-4200000 E-mail : parkfaridabad@gmail.com

PARK GROUP OF HOSPITALS : West Delhi • South Delhi • Gurgaon • Karnal • Panipat • Hodal • Ambala • Behror



DEPARTMENT OF PATHOLOGY

Patient Name : Mrs. GAGAN JANGIR
MR No : 28168
Age/Sex : 35 Years 9 Months 14 Days / Female
Type : OPD
TPA/Corporate : MEDIWHEEL

Bill Date : 14/10/2023
Reporting Date : 16/10/2023
Sample ID : 43623
Bill/Req. No. : 23058514
Ref Doctor : Dr. CONSULTANT

Test	Result	Bio. Ref. Interval	Units
THYROID PROFILE			
TRI-IODOTHYRONINE (T3)	1.12	0.60 - 1.81	ng/ml
THYROXINE (T4)	11.1	5.01 - 12.45	µg/dL
THYROID STIMULATING HORMONE	2.69	0.5-5.50	µIU/ml

***** END OF THE REPORT *****



Sample no.

Dr. VAISHALI YADAV Dr. REETU JADHAV Dr. PARDIP KUMAR S.C. GAUR
CONS. PATHOLOGIST CONS. PATHOLOGIST MICROBIOLOGIST & ICO LAB INCHARGE USER NM SUNIL

(This is only professional opinion and not the diagnosis, Please correlate clinically)

J-Block, Sector-10, Near Court, Faridabad - 121004, Haryana

Tel.: 0129-4200000 E-mail : parkfaridabad@gmail.com

Gagan

DEPARTMENT OF RADIOLOGY

Patient Name	Mrs. GAGAN JANGIR	Billed Date	: 14/10/2023	10.02 AM
Reg No	28168	Reported Date	: 14/10/2023	
Age/Sex	35 Years 9 Months 14Days / Female	Req. No.	: 23058514	
Type	OPD	Consultant Doctor	: Dr. CONSULTANT	

USG WHOLE ABDOMEN

LIVER : The liver is normal in size, shape and echotexture. No evidence of any focal lesion. IIR is not dilated.

GALL BLADDER : The gall bladder is well distended. No evidence any calculus or mass seen. GB wall thickness with in normal limits. No evidence of pericholecystic fluid is seen. The common bile duct is normal.

SPLEEN :The spleen is normal in size and shape. Its echotexture is homogeneous. No evidence of focal lesion is noted.

PANCREAS :The pancreas is normal in size, shape, contours and echotexture.

BILATERAL KIDNEYS : The bilateral kidneys are normal in size and echotexture. Cortico-medullary differentiation is maintained. There is no evidence of obvious calculus or hydronephrosis seen.

URINARY BLADDER :The urinary bladder is well distended. Wall thickness within normal limits. No evidence of calculus is seen. No evidence of mass or diverticulum is noted.


UTERUS: The uterus is normal in size, shape and echopattern. Endometrium echo is normal in thickness (5.3mm). **A Nabothian cyst of 5.6mm is seen in cervix.**

BILATERAL OVARIES are normal in size and echotexture. No adnexal mass lesion seen.

No free fluid is seen in peritoneal cavity.

No evidence of obvious retroperitoneal or mesenteric lymphadenopathy is seen.

IMPRESSION: USG WHOLE ABDOMEN REVEALS A Nabothian cyst in cervix.


DR BINOD KR CHAUDHARY
MBBS, MD
CONSULTANT RADIOLOGIST

(This is only professional opinion and not the diagnosis, Please correlate clinically)

J-Block, Sector-10, Near Court, Faridabad - 121004, Haryana

Tel.: 0129-4200000 E-mail : parkfaridabad@gmail.com


PARK GROUP OF HOSPITALS : West Delhi • South Delhi • Gurgaon • Karnal • Panipat • Hodal • Ambala • Behror



OPD PRESCRIPTION

MR.NO	: 28168	Date&Time	: 14/10/2023 10.15 AM
Name	: Mrs. GAGAN JANGIR	Sex	: Female
Doctor Name	: Dr. HARSH VARDHAN SINGH	Age	: 35Years 9Months 14Days
Speciality	: ENT	Mobile No	: 9555931153
Address	: H NO 814 , BLOCK E , NEAR SHARMA CHOWK , S.G. Panel NAGAR NIT FARIDABAD, Faridabad City, Faridabad, Haryana		: MEDIWHEEL FOC

14/10/23



Adv: →

- C (Amplified)
- C (SIT w.c.g) precaution explained.
- C Tab. MONMIR-U - at bed time ~ 15day
- C Tab SUPRADYN - daily ~ 15day
- C D w/ antifungal - Shampoo - alternate day - 15day
- C ~~antibiotic~~ CT - PAB / Mee /
- C ~~antibiotic~~ Reunion in camp

J-Block, Sector-10, Near Court, Faridabad - 121004, Haryana Tel.: 0129-4200000 E-mail : parkfaridabad@gmail.com

PARK GROUP OF HOSPITALS : West Delhi • South Delhi • Gurugram • Karnal • Panipat • Hodal • Ambala • Behror

the **health** care providers the **health** care providers

PANEL HOSPITAL : DELHI GOVT, CGHS, ECHS, MTNL, DJB, DTC NDPL MCO, NAFED, HUDCO, TRADE FAIR AUTHORITY OF INDIA, DDA, NDMC, PAWAN HANS HELICOPTER, IFFCO, METRO BHIL, MOTHER DAIRY, GAIL, VSNL, TCIL, IGL, TISCO, NPCC, NBCC, NTC, PEC, IREDA, IRCON, SCI, DU, SPG, MES, ESI, CERC, CCRT, UGC, DERC, IGNOU, JNU, DTL, CPCB, FCI, NPC, ICAR, IARI, BSNL, BSES, DELHI POLICE, ALL MAJOR TPA'S (MEDICLAIM CASHLESS HOSPITALISATION) ETC.



OPD PRESCRIPTION

MR.NO	: 28168	Date&Time	: 14/10/2023 10.13 AM
Name	: Mrs. GAGAN JANGIR	Sex	: Female
Doctor Name	: Dr. POOJA BAINS	Age	: 35Years 9Months 14Days
Speciality	: DERMATOLOGIST	Mobile No	: 9555931153
Address	: H NO 814 , BLOCK E , NEAR SHARMA CHOWK , S.G. Panel NAGAR NIT FARIDABAD, Faridabad City, Faridabad, Haryana		: MEDIWHEEL FOC

Neck & face of
Cherry angioma

do Egar cream YA HS as adv.
(Every other night)

Epilys cream YA

Photoban 50 sunscreen YA
8 am / 12 pm

Tab Stekvt. ① OD.

✓ 3 weeks

Pooja
14/10/23

J-Block, Sector-10, Near Court, Faridabad - 121004, Haryana Tel.: 0129-4200000 E-mail : parkfaridabad@gmail.com

PARK GROUP OF HOSPITALS : West Delhi • South Delhi • Gurugram • Karnal • Panipat • Hodal • Ambala • Behror

the **health** care providers

the **health** care providers

PANEL HOSPITAL : DELHI GOVT, CGHS, ECHS, MTNL, DJB, DTC NDPL MCD, NAFED, HUDCO, TRADE FAIR AUTHORITY OF INDIA, DDA, NDMC, PAWAN HANS HELICOPTER, IFFCO, METRO BH&L, MOTHER DAIRY, GAIL, VSNL, TCIL, IGL, TISCO, NPCC, NBCC, NTC, PEC, IREDA, IRCON, SCI, DU, SPG, MES, ESI, CERC, CCRT, UGC, DERC, IGNOU, JNU, DTL, CPCB, FCI, NPC, ICAR, IARI, BSNL, BSES, DELHI POLICE, ALL MAJOR TPA'S (MEDICLAIM CASHLESS HOSPITALISATION) ETC.



DEPARTMENT OF PATHOLOGY

Patient Name : Mrs. GAGAN JANGIR
 MR No : 28168
 Age/Sex : 35 Years 9 Months 14 Days / Female
 Type : OPD
 TPA/Corporate : MEDIWHEEL

Bill Date : 14/10/2023
 Reporting Date : 16/10/2023
 Sample ID : 43623
 Bill/Req. No. : 23058514
 Ref Doctor : Dr. CONSULTANT

Test	Result	Bio. Ref. Interval	Units
------	--------	--------------------	-------

HB A1C GLYCOSYLATED HAEMOGLOBIN

HBA1C	5.6		%
-------	-----	--	---

Note : Non-Diabetics 4.0 - 6.0 %

In Diabetics

Good Control 6.1 - 6.8 %

Fair Control 6.9 - 7.6 %

Poor Control > 7.6 %

***** END OF THE REPORT *****

OUT SOURCE
PARK HOSPITAL
GSN



Sample no.

Dr. VAISHALI YADAV Dr. REETU JADHAV Dr. PARDIP KUMAR S.C. GAUR
 CONS.PATHOLOGIST CONS.PATHOLOGIST MICROBIOLOGIST & ICO LAB INCHARGE USER NM SUNIL

(This is only professional opinion and not the diagnosis, Please correlate clinically)

J-Block, Sector-10, Near Court, Faridabad - 121004, Haryana

Tel.: 0129-4200000 E-mail : parkfaridabad@gmail.com

PARK GROUP OF HOSPITALS : West Delhi • South Delhi • Gurgaon • Karnal • Panipat • Hodal • Ambala • Behror



ECHO REPORT

Name of the patient: MRS. Gagan Jangir Age: 35 Sex: Male Female

UHID No: 28168 IPD No: 23058514 Date: 19/10/2022

Refer By Doctor: Dr. R. Arora

LVEF% 60%

2D ECHO

> Mitral Value Normal Pulmonary Value N Pulm

> Artery N

> Aortic avive N Tricuspid valve N

2D RWMA

> NO RWMA (Regional wall motion abnormality) at rest

COLD DOPPLER

> NO Significant Vavular stenosis / Regurgiation

COMMENTS AND SUMMARY

> All cardiac chambers of N size and shape NO dilatation or hypertrophy.

> NO RWMA (Regional wall motion abnormality) at rest

> NO Cloth / Vegetation/ pericardial effusion

> LV 60% Systolic function

> NO Significant Vavular stenosis / Regurgiation

Final Impression

> EF at Rest 60%

COMMENTS

3 DECHO & Color Doppler study was

Consultant Cardiology

Doctor Name : Dr.
Date :

Dr. Rakesh Kumar Arora
MBBS, MD (Cardiology)
R... ..
C... ..
Hospital, Faridkot

Signature :
Time :

2200000 0.5-2500
Echocardiography

1000000

1000000

I

aVR

aVR

II

aVL

aVL


III

aVF

aVF

1000000

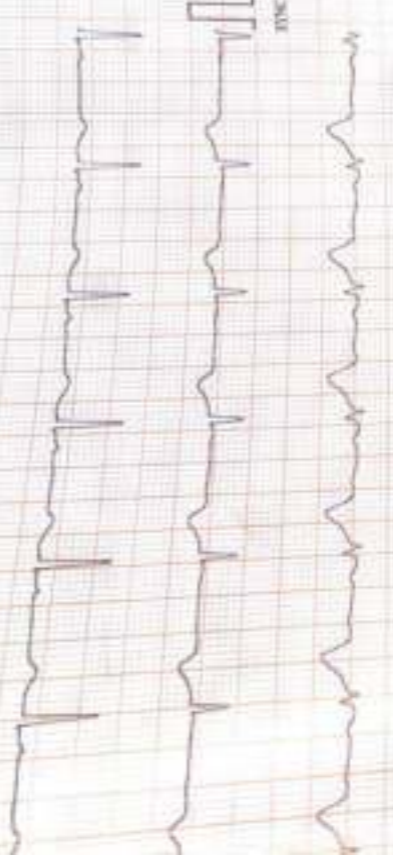
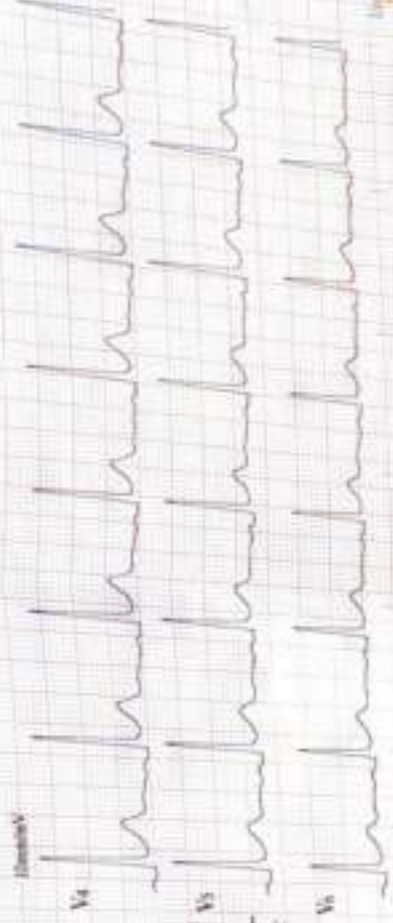1000000



IB 17.1
E-R 118
P-R 110
QRS 77
UT:06 / JUL / 198
PR:05 / 48-48.00
HR:50 / 1-470-0-4400
V5-VT / 2-010

ID 2015
Name: Gagan
Sex / Age /

— Sinus Rhythm
— Borderline Normal ECG



Interpreted report finalized by
Prof.