





Patient Name : Mr.ASHISH KUMAR KESHRI	Collected : 09/Nov/2024 09:26AM
Age/Gender : 41 Y 10 M 28 D/M	Received : 09/Nov/2024 11:55AM
UHID/MR No : SKOR.0000128862	Reported : 09/Nov/2024 02:16PM
Visit ID : CKOROPV431219	Status : Final Report
Ref Doctor : Self	Sponsor Name : ARCOFEMI HEALTHCARE LIMITED
Emp/Auth/TPA ID : 22E37365	


**DEPARTMENT OF HAEMATOLOGY**

**ARCOFEMI - MEDIWHEEL - FULL BODY ANNUAL PLUS ABOVE 50Y MALE - 2D ECHO - PAN INDIA - FY2324**

Test Name	Result	Unit	Bio. Ref. Interval	Method
<b>BLOOD GROUP ABO AND RH FACTOR , WHOLE BLOOD EDTA</b>				
BLOOD GROUP TYPE	B			Microplate Hemagglutination
Rh TYPE	Positive			Microplate Hemagglutination



Dr. Vidya Aniket Gore  
M.B.B.S,M.D(Pathology)  
Consultant Pathologist



Dr Priya Murthy  
M.B.B.S,M.D(Pathology)  
Consultant Pathologist





























---

Patient Name	: Mr. ASHISH KUMAR KESHRI	Age	: 41Yrs 10Mths 29Days
UHID	: SKOR.0000128862	OP Visit No.	: CKOROPV431219
Printed On	: 09-11-2024 05:14 AM	Advised/Pres Doctor	: --
Department	: Radiology	Qualification	: --
Referred By	: Self	Registration No.	: --
Employeer Id	: 22E37365		

---

## DEPARTMENT OF RADIOLOGY

---

### ULTRASOUND ABDOMEN AND PELVIS

#### FINDINGS:

**Liver** is enlarged in size (17 cms) and shows increased echotexture. No biliary dilatation. No focal lesion

**CBD** is not dilated.

**Portal vein** is normal in size, course and calibre.

**Gall bladder** is normal without evidence of calculi, wall thickening or pericholecystic fluid.

**Pancreas** obscured

**Spleen** is normal in size, shape, contour and echopattern. No evidence of mass or focal lesions.

Right Kidney is normal in size, position, shape and echopattern. Corticomedullary differentiation is maintained. No evidence of calculi or hydronephrosis.

---



---

Left Kidney is normal in size, position, shape and echopattern. Corticomedullary differentiation is maintained. No evidence of calculi or hydronephrosis.

**Retroperitoneum** – Obscured by bowel gas. No significant lymphadenopathy.

**Urinary Bladder** well distended. wall thickness is normal. No evidence of calculi, mass or mural lesion. Pre void -125 ml post void- nil.

Prostate: is enlarged in size with normal echotexture.

There is no ascites.

IMPRESSION:

**GRADE I FATTY HEPATOMEGALY**

**GRADE I PROSTATOMEGALY, NO RESIDUAL URINE**

---End Of The Report---




Dr.VINOD P JOSEPH  
MBBS, DNB, DMRD

---

---

25487  
Radiology



---

Patient Name	: Mr. ASHISH KUMAR KESHRI	Age	: 41Yrs 11Mths 1Days
UHID	: SKOR.0000128862	OP Visit No.	: CKOROPV431219
Printed On	: 12-11-2024 07:14 AM	Advised/Pres Doctor	: --
Department	: Cardiology	Qualification	: --
Referred By	: Self	Registration No.	: --
Employer Id	: 22E37365		

---

**DEPARTMENT OF CARDIOLOGY**

---

ECHO

---End Of The Report---



Dr.MOHAN MURALI  
MBBS, DNB General Medicine, DrNB Cardiology  
ANP20130001911KTK  
Cardiology

Patient Name	: Mr. ASHISH KUMAR KESHRI	Age	: 41Yrs 10Mths 29Days
UHID	: SKOR.0000128862	OP Visit No.	: CKOROPV431219
Printed On	: 09-11-2024 06:28 AM	Advised/Pres Doctor	: --
Department	: Cardiology	Qualification	: --
Referred By	: Self	Registration No.	: --
Employer Id	: 22E37365		

## DEPARTMENT OF CARDIOLOGY

### Observation :-

1. Normal Sinus Rhythm.
2. Heart rate is 71 beats per minutes.
3. No pathological Q wave or ST-T changes seen.
4. Normal P,Q,R,S,T waves and axis.
5. No evidence of chamber, hypertrophy or enlargement seen.

### Impression:

NORMAL RESTING ECG.

NOTE:KINDLY TAKE A PHOTOCOPY OF THE GRAPH FOR FUTURE REFERENCE IF NEEDED

---End Of The Report---



Dr.MOHAN MURALI  
MBBS, DNB General Medicine, DrNB Cardiology  
ANP20130001911KTK  
Cardiology





## Apollo Clinic

### Consent Form

Patient Name: ASHISH KUMAR KESHRI Age: 41

UHID Number: ..... Company Name: .....

I Mr/Mrs/Miss: ..... Employee of Bank of Baroda

(Company) want to inform you that I am ~~not~~ getting the consultation

Test which is a part of health check package.

Reason If any: I will be coming on Friday

And I claim the above statement in my full consciousness

Patient Signature: Ashish Keshri Date: 09/11/2024

# OPHTHAL REPORT

NAME: Mr. Arjun Kumar  
AGE: 41... GENDER: MALE/FEMALE

OD: 1

## RIGHT EYE

	SPH	CYL	AXIS	VA
DV	5.00			6/12P
NV				.

	SPH	CYL	AXIS	VA
DV	4			6/6P
NV				

*Refer Ophthal*

REMARK:

DATE: .....

OPTOMETRIST

BRING THIS PRESCRIPTION IN YOUR NEXT VISIT



**Patient Name** : Mr Ashish Kumar K

**Age** : 41 Year(s)

**Referring Doctor** : H/C

**Patient ID**:128862

**Sex**: Male

**Date**:09.11.2024

**ULTRASOUND ABDOMEN AND PELVIS**

**FINDINGS:**

**Liver** is enlarged in size(17 cms) and shows increased echotexture. No biliary dilatation. No focal lesion

**CBD** is not dilated.

**Portal vein** is normal in size, course and calibre.

**Gall bladder** is normal without evidence of calculi, wall thickening or pericholecystic fluid.

**Pancreas** obscured

**Spleen** is normal in size, shape, contour and echopattern. No evidence of mass or focal lesions.

**Right Kidney** is normal in size, position, shape and echopattern. Corticomedullary differentiation is maintained. No evidence of calculi or hydronephrosis.

**Left Kidney** is normal in size, position, shape and echopattern. Corticomedullary differentiation is maintained. No evidence of calculi or hydronephrosis.

**Retroperitoneum** – Obscured by bowel gas. No significant lymphadenopathy.

**Urinary Bladder** well distended. wall thickness is normal. No evidence of calculi, mass or mural lesion. Pre void -125 ml post void- nil.

**Prostate**: is enlarged in size with normal echotexture.

There is no ascites.

**IMPRESSION:**

**GRADE I FATTY HEPATOMEGALY**

**GRADE I PROSTATOMEGALY, NO RESIDUAL URINE**

**DR VINOD JOSEPH DNB,DMRD**  
**RADIOLOGIST**





*Dr. Vijayalakshmi*

MBBS, MS (ENT)  
KMC REG NO: 119251

**HEALTH CHECK - ENT**

*09/11/24*

**NAME:** *Ashok Kumar Kenger*

**AGE:** *41/M*

**EAR:**

**RE:**

**LE:**

EXTERNAL EAR

MIDDLE EAR

INNER EAR (FN)

*Normal*

**HEARING ASSESSMENT:**

**RE:**

**LE:**

RHINNE

WEBER

ABC

*R > L  
N/A  
N/A*

**NOSE**

**THROAT**

AIRWAY

ORAL CAVITY

SEPTUM

*Mucopus (R+)*

OROPHARYNX

TURBINATES

PHARYNX

*Normal*

OTHERS

LARYNX

**NECK**

NECK NODES

OTHER

*Normal*

**AUDIOMETRY**

**IMPRESSION**

*Acute*

*X-ray PNS*

*[Signature]*

**SIGNATURE**

**NAME: Mr. ASHISH KUMAR KESHRI**

**AGE: 41Y**

**SEX: MALE**

**DATE: 09/11/2024**

## ECHOCARDIOGRAPHY REPORT

### MEASUREMENT

AO – 25(20 – 35)mm	LIVD d – 40(36-52)mm	IVS – 11(06 – 11)mm
LA – 28(19- 40)mm	LVID s 28(23- 39)mm	PWD – 11(06- 11)mm
EF – 60(>50%)	RVID-20	

### VALVES

Mitral Valve : NORMAL  
Aortic Valve : NORMAL  
Tricuspid Valve : Normal,  
Pulmonary Valve : Normal,

### CHAMBERS

Left Atrium : Normal  
Right Atrium : Normal  
Left Ventricle : Normal  
Right Ventricle : Normal

### SEPTAE

IVS : Intact  
IAS : Intact

**GREAT ARTERIES**

Aorta : Normal  
Pulmonary Artery : Normal

**DOPPLER DATA**

Mitral : E > A , 0.8 / 0.6  
Aortic : Normal , 1.0 m/s  
Tricuspid : Normal , 0.4 / 0.6  
Pulmonary : Normal, 1.10

WALL MOTION ABNORMALITIES : No RWMA

Pericardium : Normal

**FINAL DIAGNOSIS**

**NORMAL CHAMBERS AND DIMENSION  
NO RWMA AT REST, NORMAL LV EF - 60%  
NORMAL DIASTOLIC FUNCTION  
NO OBVIOUS CLOTS/ EFFUSION/ VEGETATION**

  
**DR. MOHAN MURALI  
DNB(MED), DNB(CARDIOLOGY)  
CONSULTANT CARDIOLOGIST**



**Apollo Medical  
Centre**

Expertise. Closer to you.

Patient Name	: Mr. ASHISH KUMAR KESHRI	Age	: 41Yrs 10Mths 28Days
UHID	: SKOR.0000128862	OP Visit No.	: CKOROPV431219
Printed On	: 09-11-2024 12:39 PM	Advised/Pres Doctor	: --
Department	: Radiology	Qualification	: --
Referred By	: Self	Registration No.	: --
Employer Id	: 22E37365		

## DEPARTMENT OF RADIOLOGY

### X RAY CHEST PA

Both lungs fields appear normal.

Both hilae are normal.

Both costophrenic and cardiophrenic angles are normal.

The cardiac and mediastinal shadows appear normal.

Bones and soft tissues appear normal.

**IMPRESSION : NORMAL STUDY.**

---End Of The Report---

*P.J. Vinod*

Dr.VINOD P JOSEPH  
MBBS, DNB, DMRD  
25487  
Radiology

Apollo Health and Lifestyle Limited

(CIN - U85110TG2000PLC046089) Regd. Office: #7-1-617/A, 615 & 616, Imperial Towers, 7th Floor | Ameerpet, Hyderabad, Telangana - 500 038 | Email ID: enquiry@apollohl.com

APOLLO CLINICS NETWORK KARNATAKA

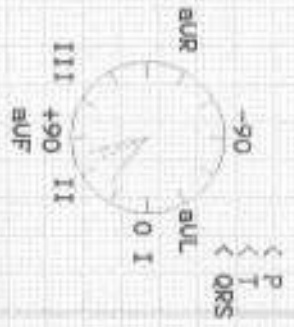**Bangalore** (Basavanagudi | Bellandur | Electronics City | HSR Layout | Indira Nagar | JP Nagar | Kundalahalli | Koramangala | Sarjapur Road) **Mysore** (Kallidas Road)

Online appointments: www.apolloclinic.com

TO BOOK AN APPOINTMENT

**1860 500 7788**

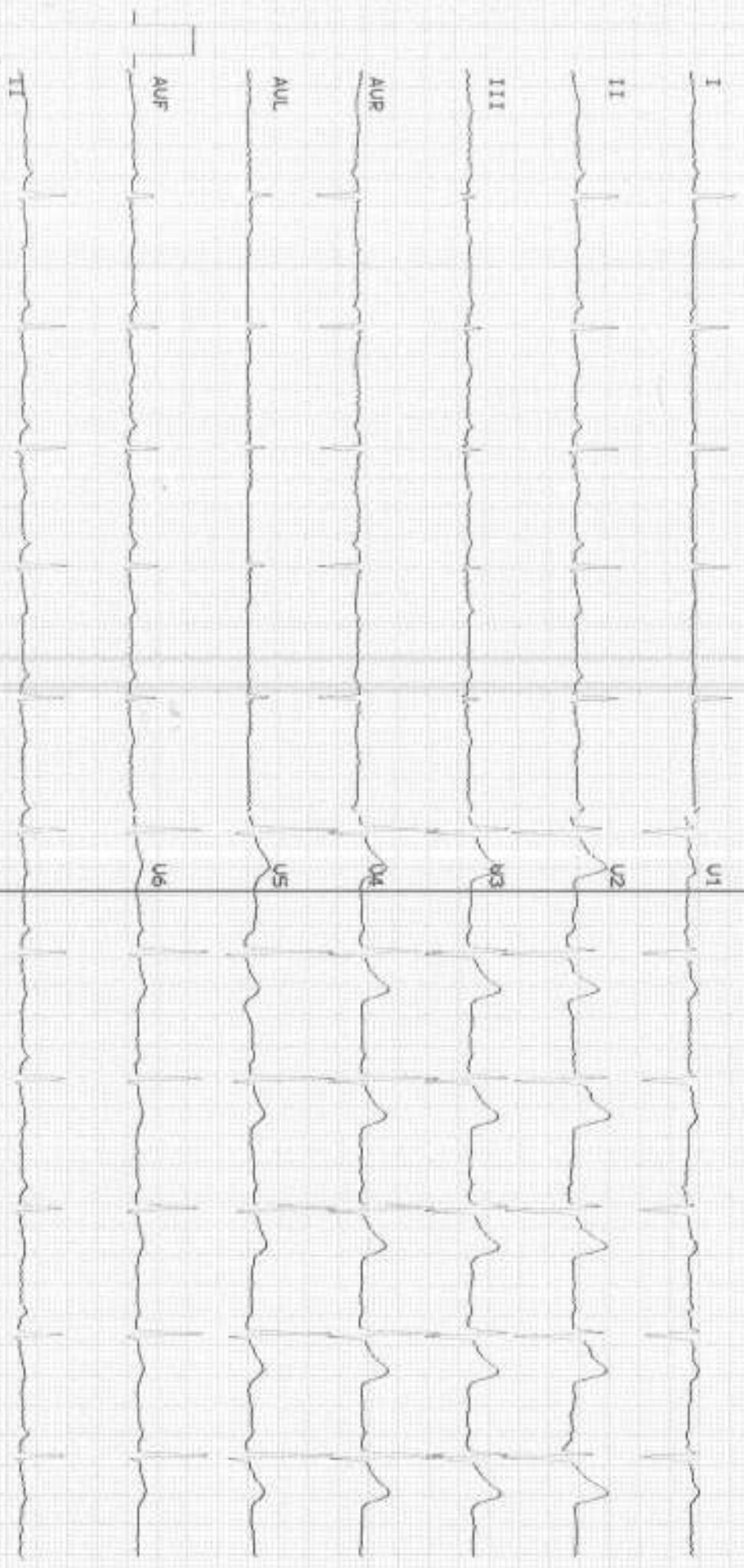
AGE: 41  
 Measurement Results:  
 QRS : 36 ms  
 QT/QTcB : 394 / 428 ms  
 PR : 160 ms  
 P : 94 ms  
 PE/PP : 846 / 845 ms  
 P/QRS/T : 65 / 40 / 75 degrees  
 QTd/QTcBd : 62 / 67 ms  
 Sokolow : 2.1 mV  
 NK : 9



Interpretation:

Unconfirmed report.

*Handwritten signature*





Patient Name	: Mr. ASHISH KUMAR KESHRI	Age	: 41Yrs 10M 14D 2005
UHID	: SKOR.0000128862	OP Visit No.	: CKOROPV431219
Printed On	: 09-11-2024 11:58 AM	Advised/Pres Doctor	: --
Department	: Cardiology	Qualification	: --
Referred By	: Self	Registration No.	: --
Employer Id	: 22E37365		

### DEPARTMENT OF CARDIOLOGY

#### Observation :-

1. Normal Sinus Rhythm.
2. Heart rate is 71 beats per minutes.
3. No pathological Q wave or ST-T changes seen.
4. Normal P,Q,R,S,T waves and axis.
5. No evidence of chamber, hypertrophy or enlargement seen.

#### Impression:

NORMAL RESTING ECG.

NOTE:KINDLY TAKE A PHOTOCOPY OF THE GRAPH FOR FUTURE REFERENCE IF NEEDED

---End Of The Report---

Dr.MOHAN MURALI  
MBBS, DNB General Medicine, DrNB Cardiology  
ANP20130001911KTK  
Cardiology

#### Apollo Health and Lifestyle Limited

(CIN - U85110TG2000PLC046089) Regd. Office: #7-1-617/A, 615 & 616, Imperial Towers, 7th Floor | Ammerpet, Hyderabad, Telangana - 500 098 | Email ID: enquiry@apollohl.com

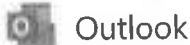#### APOLLO CLINICS NETWORK KARNATAKA

Bangalore (Basavanagudi) | Bellandur | Electronics City | HSR Layout | Indira Nagar | JP Nagar | Kundalahalli | Keramangala | Sarjapur Road | Mysore (Kaldasa Road)

Online appointments: [www.apolloclinic.com](http://www.apolloclinic.com)

TO BOOK AN APPOINTMENT

1860 500 7788



Health Check up Booking Confirmed Request(22E37365),Package Code-PKG10000367,  
Beneficiary Code-322506

From Mediwheel <wellness@mediwheel.in>

Date Tue 05-11-2024 16:26

To ASHISH KUMAR KESHRI <ASHISH.KESHRI2@bankofbaroda.com>

Cc customercare@mediwheel.in <customercare@mediwheel.in>

गवधान: यह मेल बैंक डोमेन के बाहर से आया है. अगर आप प्रेषक को नहीं जानते तो मेल में दी गयी ति  
:AUTION: THIS MAIL IS ORIGINATED FROM OUTSIDE OF THE BANK'S DOMAIN. DO

011-41195959

Dear **MR. KESHRI ASHISH KUMAR,**

We are pleased to confirm your health checkup booking request with the following details.

**Hospital Package Name** : Mediwheel Full Body Annual Plus Above 50 Male  
**Name of Diagnostic/Hospital** : Apollo Medical Centre - Koramangala  
**Address of Diagnostic/Hospital-** Apollo Medical centre, Plot 51, 5th Block, Opp. Jyothi Nivas College, Koramangala - 5600095  
**City** : Bangalore  
**State** : Karnataka  
**Pincode** : 560095  
**Appointment Date** : 09-11-2024  
**Confirmation Status** : Booking Confirmed  
**Preferred Time** : 08:00 AM - 08:30 AM  
**Booking Status** : Booking Confirmed

**Member Information**

Booked Member Name	Age	Gender
MR. KESHRI ASHISH KUMAR	41 year	Male

**Note - Please note to not pay any amount at the center.**

**Instructions to undergo Health Check:**

- Please ensure you are on complete fasting for 10-To-12-Hours prior to check.
- During fasting time do not take any kind of medication, alcohol, cigarettes, tobacco or any other liquids (except Water) in the morning.
- Bring urine sample in a container if possible (containers are available at the Health Check centre).

- Please bring all your medical prescriptions and previous health medical records with you.
- Kindly inform the health check reception in case if you have a history of diabetes and cardiac problems.

**For Women:**

- Pregnant Women or those suspecting are advised not to undergo any X-Ray test.
- It is advisable not to undergo any Health Check during menstrual cycle.

Request you to reach half an hour before the scheduled time.

In case of further assistance, Please reach out to Team Mediwheel.

---

Thanks,  
Mediwheel Team  
Please Download Mediwheel App

You have received this mail because your e-mail ID is registered with **Arcofemi Healthcare Limited** This is a system-generated e-mail please don't reply to this message.

Please visit to our Terms & Conditions for more informaion. [Click here to unsubscribe.](#)

@ 2024 - 25, Arcofemi Healthcare Pvt Limited.(Mediwheel)





अशीष कुमार केशरी

Ashish Kumar Keshri

जन्म तिथि/ DOB: 12/12/1982

पुरुष / MALE

4155 8194 5629

मेरा आधार, मेरी पहचान