
  
**भारतीय विशिष्ट पहचान प्राधिकरण**  
 UNIQUE IDENTIFICATION AUTHORITY OF INDIA

**पता:**  
 D/O जगदीश जैन, 'A',  
 बंदरिया के बालाजी के  
 सामने, श्रुव सडकी मील,  
 गंगपुर सिटी, गंगपुर, सवाई  
 राजपुर,  
 राजस्थान - 322201

**Address:**  
 D/O Jagdish Jain, 'A', bandariya  
 ke balaaji ke samne, shubh la xmi  
 meel, gangapur city, Gangapur,  
 Sawai Madhopur,  
 Rajasthan - 322201

**5452 9679 4734**  
**MERA AADHAAR, MERI PEHACHAN**



संतोष जैन

  
**Dr. NITIN AGARWAL**  
 MBBS, MD  
 Regn. No. DMC-R-1436

**ONEPLUS ULTRASOUND LAB**  
 47, Harsh Vihar, Pitam Pura  
 Delhi-110034  
 Ph. 011-42480101, 9599933051  
 E-mail: oneplusul@gmail.com


**भारत सरकार**  
 GOVERNMENT OF INDIA

**संतोष जैन**  
 Santosh Jain  
 जन्म तिथि/ DOB: 16/05/1998  
 महिला / FEMALE


  



**5452 9679 4734**  
**मेरा आधार, मेरी पहचान**

1911



1911





संतोष जैन

DR. NITIN AGARWAL  
MBBS, MD  
Regn. No. DMC-R-1436

ONEPLUS ULTRASOUND LAB  
47, Harsh Vihar, Pitam Pura,  
Delhi-110034  
Ph. 011-42480101, 9599913051  
E-mail: oneplusul@gmail.com





**OnePLUS**  
Ultrasound Lab  
— QUALITY FIRST... ALWAYS! —

**Dr. Nitin Agarwal**

Pathologist & Director  
Ex. Sr. Res. MAMC  
& Lok Nayak Hospital  
Ex. Chief of Lab Dr. Lal Path Labs.

**Dr. Pooja (Garg) Agarwal**

Radiologist & Director  
MAMC & Lok Nayak Hospital

This is to state that, I am not willing to give my sample in stool test, as I am uncomfortable in giving it. Moreover I don't feel any requirement of going through this test.

Name - Santosh Jain

Age - 24

संतोष जैन

**DR. NITIN AGARWAL**  
MBBS, MD  
Regn. No. DMC-R-1436

47, Harsh Vihar, Pitampura, New Delhi-110034 | Ph.: 011-42480101, 9599913051

E-mail: [oneplusul@gmail.com](mailto:oneplusul@gmail.com) | Web.: [www.oneplusul.in](http://www.oneplusul.in)

Clinical correlation is essential for final diagnosis. • If test results are unsatisfactory please contact personally or on phone. • This report is for perusal of doctors only. • All disputes Subject to Delhi Jurisdiction only. • Not for medicolegal purposes. • All congenital anomalies in a foetus may not be diagnosed in routine obstetric ultrasound.

# ONEPLUS ULTRASOUND LAB

47, HARSH VIHAR, PITAMPURA, DELHI- 110034

Ms. SANTOSH JAIN  
Age : 24/F  
Ref. by : MEDIWHEEL  
Indication1 :  
Indication2 :  
Indication3 :  
COMMENTS : Sinus Tachycardia.

ID : 2039  
H/Wt : 152/51  
Recorded : 8-11-2022 12:47  
Medication1 :  
Medication2 :  
Medication3 :

BPM : 119  
BP : 120/74  
P Axis : 88 deg  
QRS Axis : 66 deg  
T Axis : 23 deg

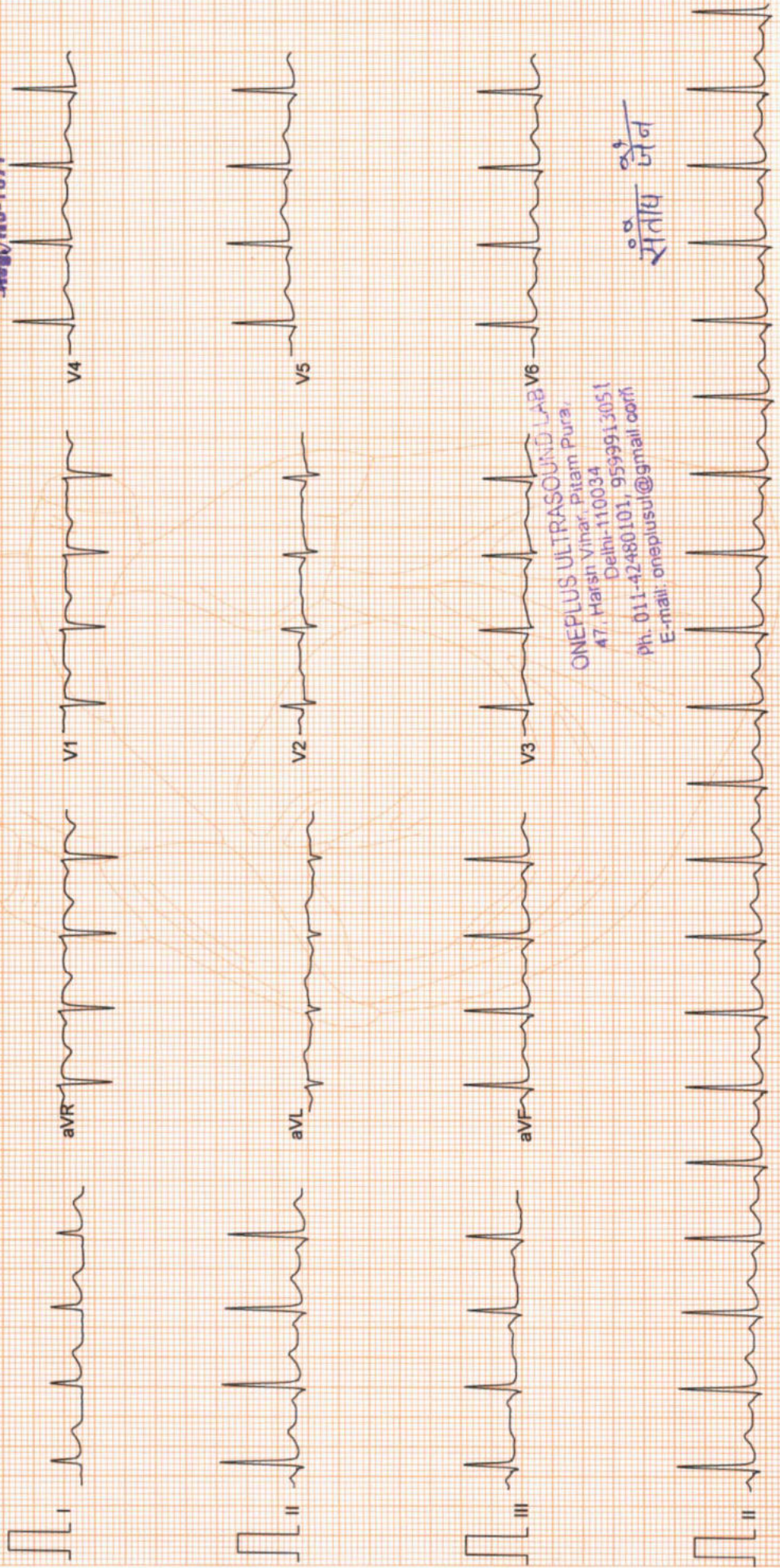
P duration : 80 msec  
PR duration : 110 msec  
QRS duration : 100 msec  
QT interval : 283 msec  
QTc interval : 366 msec

Raw E.C.G. (Seq)

Unconfirmed Report Reviewed By:

**Dr. P.K. GUPTA**  
**MBBS, MD**  
**Reg. No-1071**

Cardiologist



ONEPLUS ULTRASOUND LAB V6  
47, Harsh Vihar, Pitam Pura,  
Delhi-110034  
Ph. 011-42480101, 9599913051  
E-mail: oneplusul@gmail.com

संतोष जैन

# ONEPLUS ULTRASOUND LAB

47, HARSH VIHAR PITAMPURA DELHI 110034

Ms. SANTOSH JAIN  
Age : 24/F  
Ref by : MEDIWHEEL  
Indication 1 :  
Indication 2 :  
Indication 3 :

ID : 996  
Ht/Wt : 152/51  
Recorded : 8-11-2022 12:58

TREADMILL TEST SUMMARY REPORT  
Protocol: BRUCE  
History:  
Medication 1 :  
Medication 2 :  
Medication 3 :

PHASE	PHASE TIME	STAGE TIME	SPEED (Km./Hr.)	GRADE (%)	H.R. (BPM)	B.P (mmHg)	RPP X100	II	ST LEVEL (mm) V2	V5	METS
STANDING SUPINE					116 114	120/74 120/74	139 136	0.0 0.0	0.0 -0.1	0.2 0.1	
STAGE 1	2:59	2:59	2.70	10.00	167	132/78	220	-0.4	-0.1	0.1	4.80
STAGE 2	5:59	2:59	4.00	12.00	190	144/80	273	-0.3	0.5	0.1	7.10
STAGE 3	6:29	0:29	5.40	14.00	196	160/84	313	-0.4	0.5	0.1	7.57
PEAK EXER	6:30	0:30			197	160/84	315	-0.5	0.6	0.1	7.59
RECOVERY	2:59	2:59	0.00	0.00	135	126/76	170	-0.5	0.1	-0.2	

## RESULTS

Exercise Duration : 6:30 Minutes  
Max Heart Rate : 197 bpm 100 % of target heart rate 196 bpm  
Max Blood Pressure : 160/84 mmHg  
Max Work Load : 7.59 METS  
Reason of Termination :

## IMPRESSIONS

Negative for ischemic change

ONEPLUS ULTRASOUND LAB  
47, Harsh Vihar, Pitam Pura  
Delhi-110034  
Ph. 011-42480101, 9599913051  
E-mail: oneplusul@gmail.com

**Dr. P.K. GUPTA**  
MBBS, MD  
Cardiologist  
Reg. No. 1071

संतोष जैन

# ONEPLUS ULTRASOUND LAB

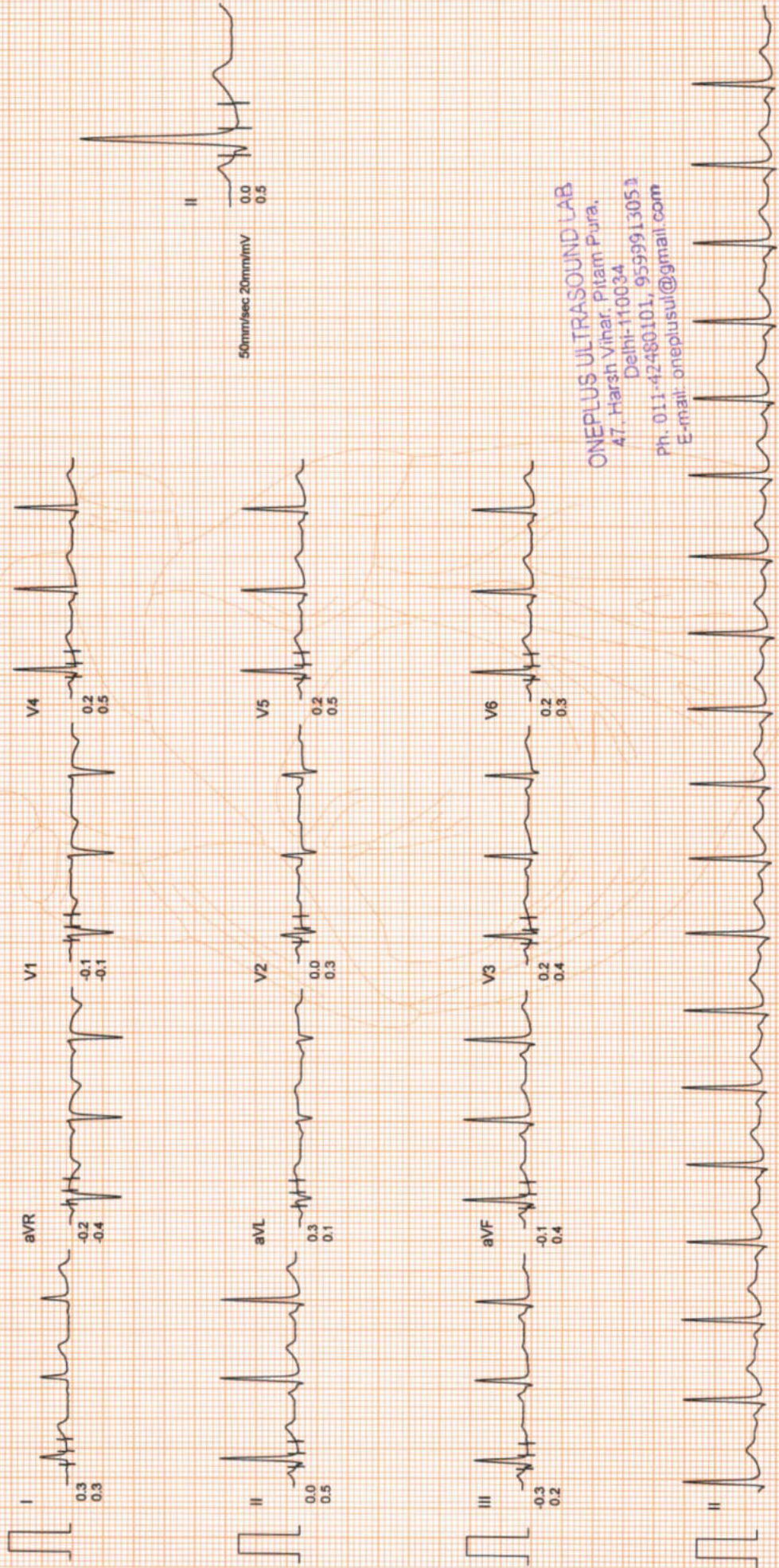
Ms. SANTOSH JAIN  
I.D. : 996

AGE/SEX : 24/F  
RECORDED : 8-11-2022 12:58  
RATE : 116 BPM  
B.P. : 120/74 mmHg

ST @ 10mm/mV  
80ms PostJ

STANDING  
PRETEST

LINKED MEDIAN



ONEPLUS ULTRASOUND LAB  
A7, Harsh Vihar, Pitam Pura,  
Delhi-110034  
Ph: 011-42480101, 9599913053  
E-mail: oneplusul@gmail.com



# ONEPLUS ULTRASOUND LAB

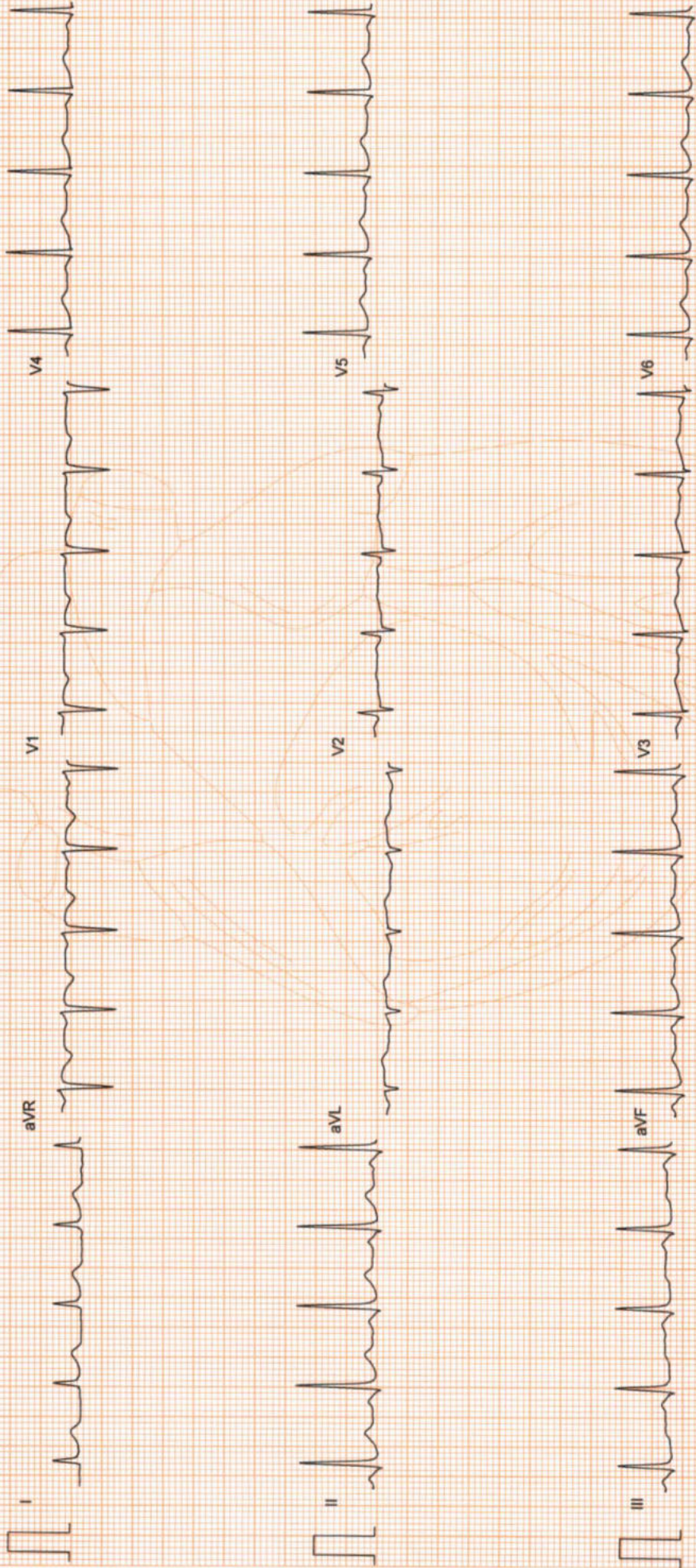
Ms. SANTOSH JAIN  
I.D. : 996

AGE/SEX : 24/F  
RECORDED : 8-11-2022 12:58  
RATE : 114 BPM  
B.P. : 120/74 mmHg

SUPINE  
PRETEST

ST @ 10mm/mV  
80ms PostJ

RAW E.C.G.



ONEPLUS ULTRASOUND LAB  
47, Harsh Vihar, Pitam Pura,  
Delhi-110034  
ph. 011-42480101, 9599913051  
E-mail: oneplusul@gmail.com

# ONEPLUS ULTRASOUND LAB

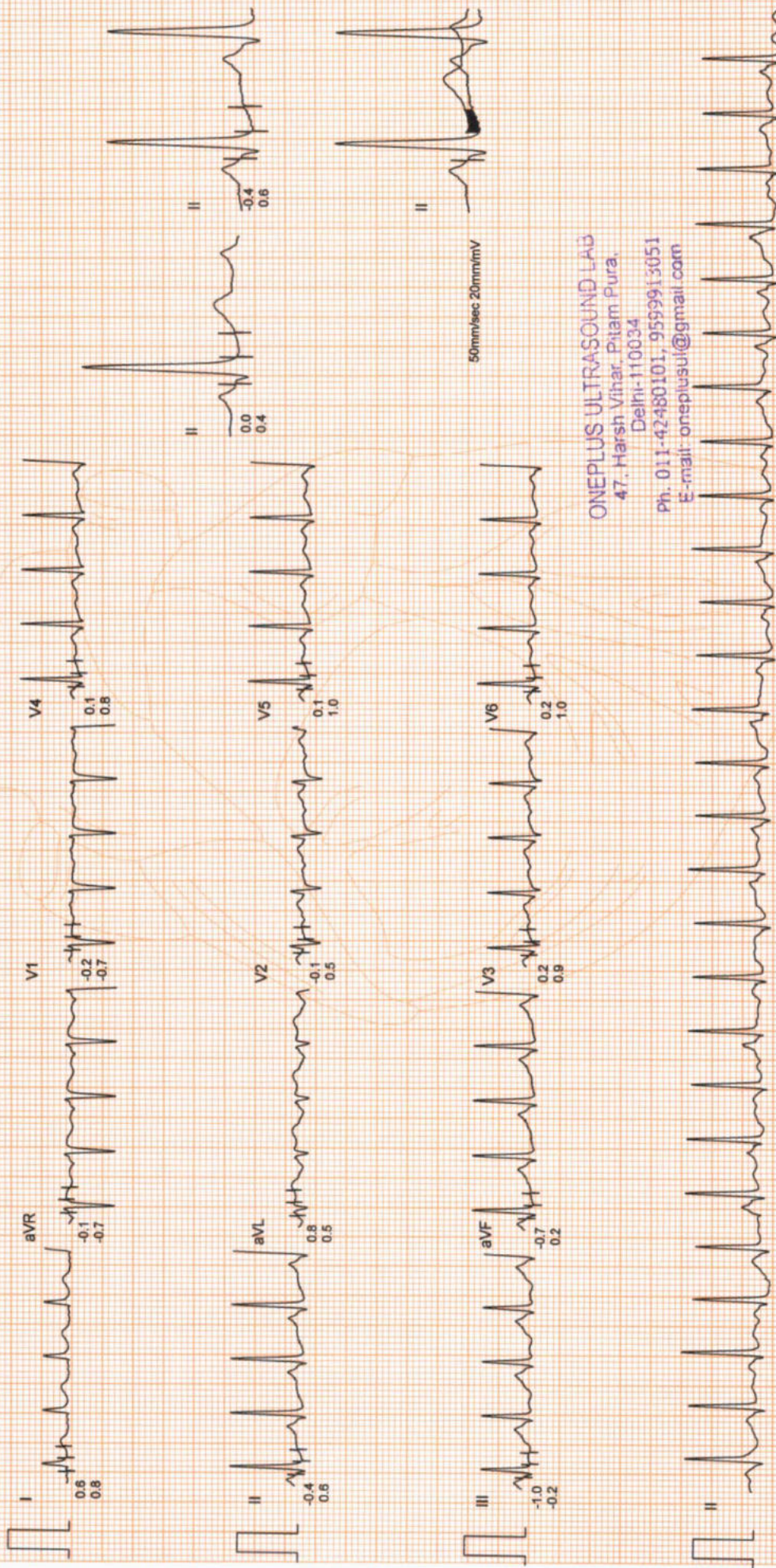
Ms. SANTOSH JAIN  
I.D. : 996

AGE/SEX : 24/F  
RECORDED : 8-11-2022 12:58

BRUCE  
EXERCISE 1  
PHASE TIME : 2:59  
STAGE TIME : 2:59

ST @ 10mm/mV  
80ms PostJ  
SPEED : 2.7 Km./Hr.  
GRADE : 10.0 %

LINKED MEDIAN



ONEPLUS ULTRASOUND LAB  
47, Harsh Vihar, Pitam Pura,  
Delhi-110034  
Ph: 011-42480101, 9599913051  
E-mail: oneplusul@gmail.com

# ONEPLUS ULTRASOUND LAB

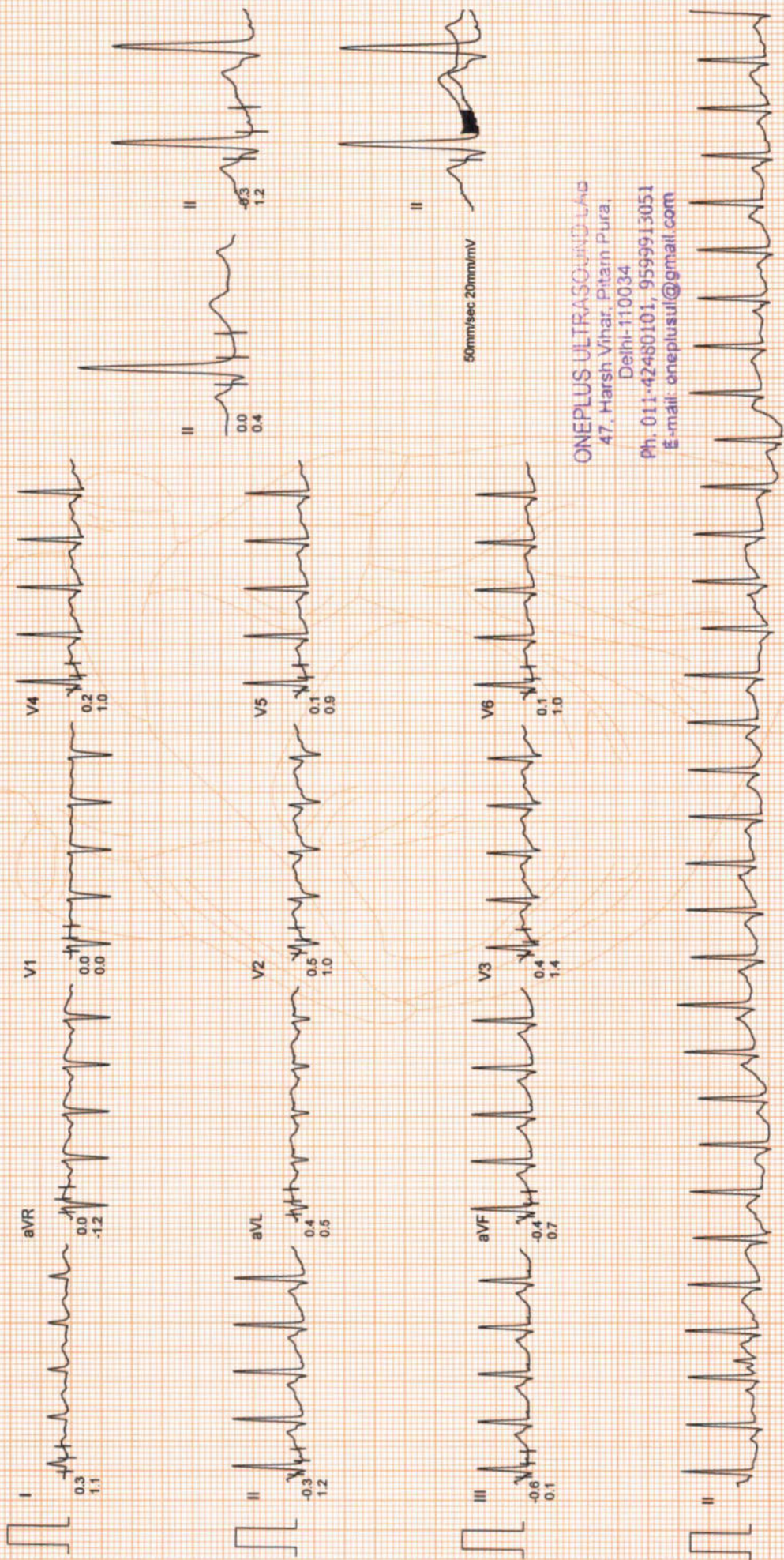
Ms. SANTOSH JAIN  
I.D. : 996

AGE/SEX : 24/F  
RECORDED : 8-11-2022 12:58

BRUCE  
EXERCISE 2  
PHASE TIME : 5:59  
STAGE TIME : 2:59

ST @ 10mm/mV  
80ms PostJ  
SPEED : 4.0 Km./Hr.  
GRADE : 12.0 %

LINKED MEDIAN



ONEPLUS ULTRASOUND LAB  
47, Harsh Vihar, Pitam Pura,  
Delhi-110034  
Ph. 011-42480101, 9599913051  
E-mail: oneplusul@gmail.com

# ONEPLUS ULTRASOUND LAB

Ms. SANTOSH JAIN

I.D. : 996

AGE/SEX : 24/F

RECORDED : 8-11-2022 12:58

RATE : 196 BPM

B.P. : 160/84 mmHg

BRUCE

EXERCISE 3

PHASE TIME : 6:29

STAGE TIME : 0:29

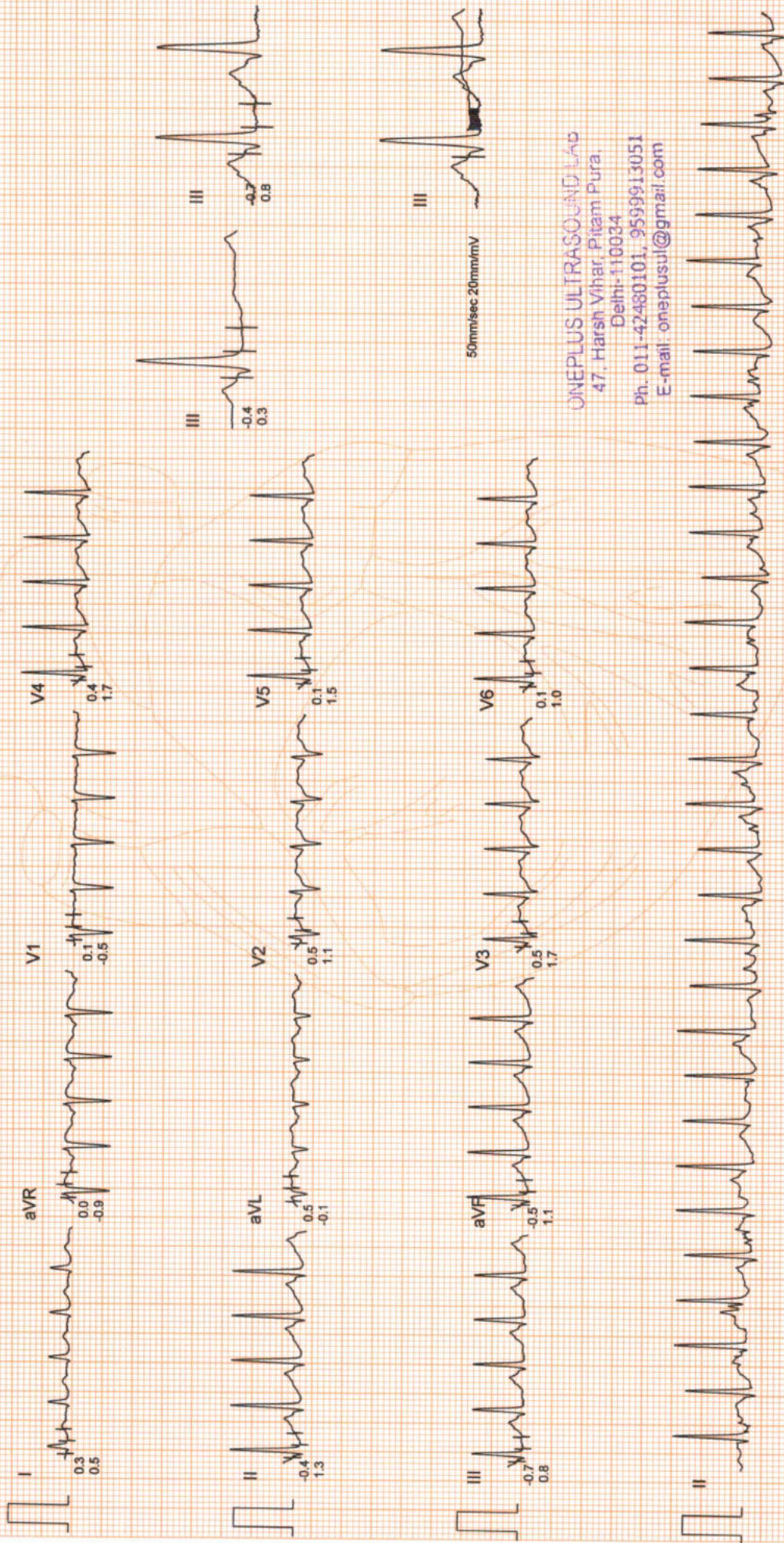
ST @ 10mm/mV

80ms Post. J

SPEED : 5.4 Km./Hr.

GRADE : 14.0 %

LINKED MEDIAN



ONEPLUS ULTRASOUND LAB  
47, Harsh Vihar, Pitam Pura,  
Delhi-110034  
Ph. 011-42480101, 9599913051  
E-mail: oneplusul@gmail.com

# ONEPLUS ULTRASOUND LAB

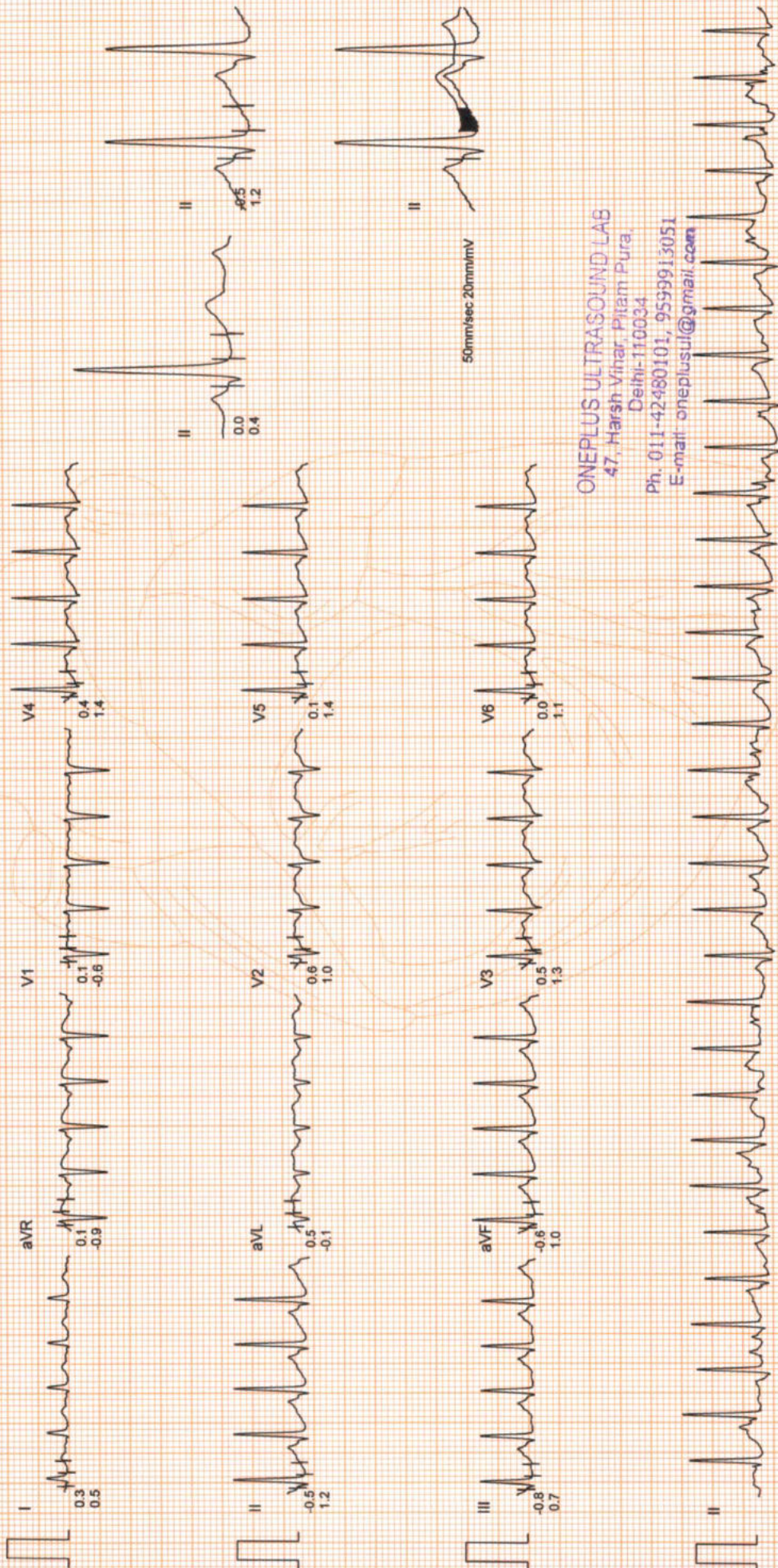
Ms. SANTOSH JAIN  
I.D. : 996

AGE/SEX : 24/F  
RECORDED : 8-11-2022 12:58

BRUCE  
PEAK EXER  
PHASE TIME : 6:30  
STAGE TIME : 0:30

ST @ 10mm/mV  
80ms PostJ  
SPEED : 5.4 Km./Hr.  
GRADE : 14.0 %

LINKED MEDIAN



ONEPLUS ULTRASOUND LAB  
47, Harsh Vihar, Pitam Pura,  
Delhi-110034  
Ph. 011-42480101, 9599913051  
E-mail: [oneplusul@gmail.com](mailto:oneplusul@gmail.com)

# ONEPLUS ULTRASOUND LAB

Ms. SANTOSH JAIN  
I.D. : 996

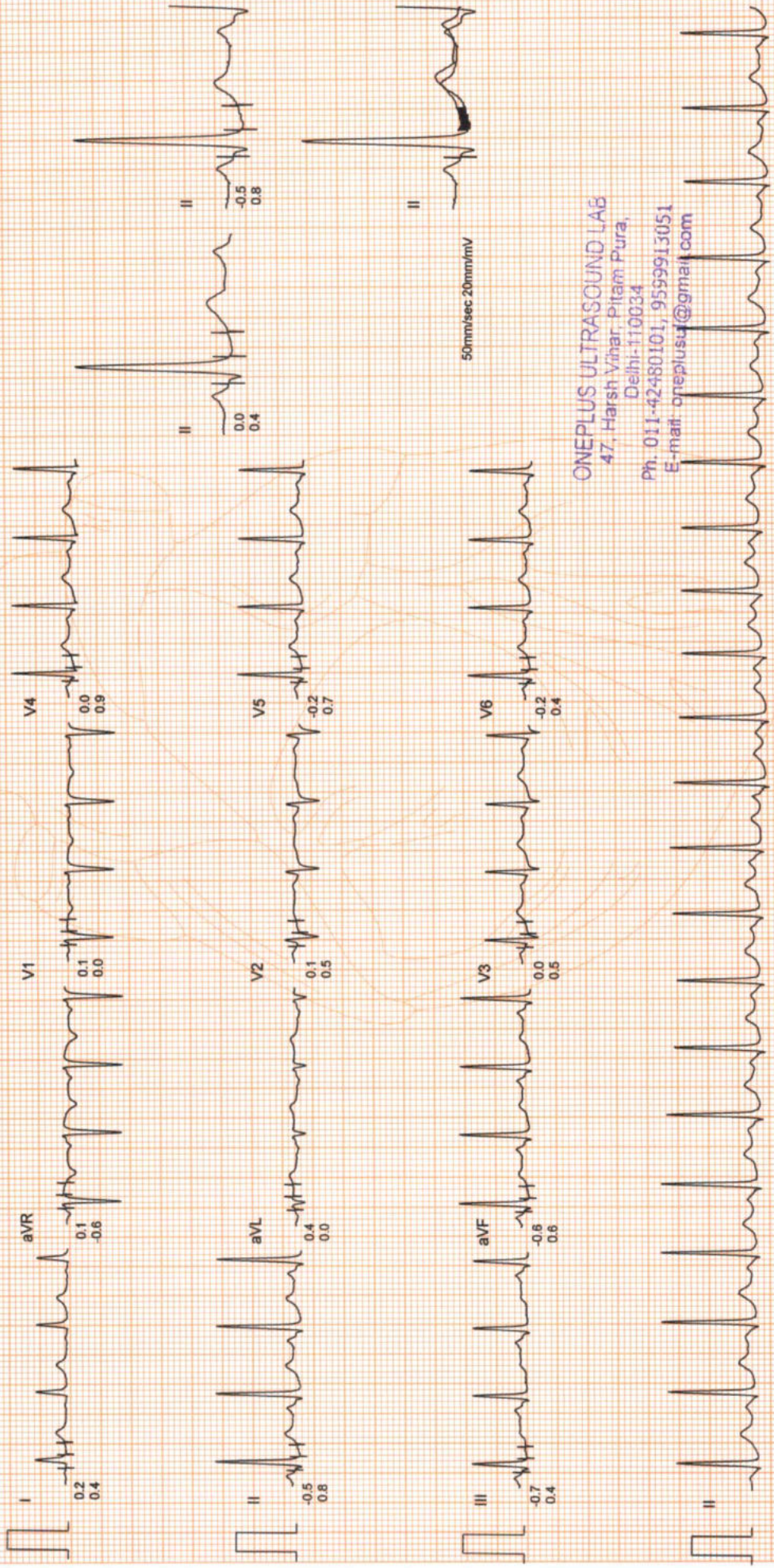
AGE/SEX : 24/F  
RECORDED : 8-11-2022 12:58

RATE : 135 BPM  
B.P. : 126/76 mmHg

BRUCE  
RECOVERY  
PHASE TIME : 2:59

ST @ 10mm/mV  
80ms PostJ  
SPEED : 0.0 Km./Hr.  
GRADE : 0.0 %

LINKED MEDIAN



ONEPLUS ULTRASOUND LAB  
47, Harsh Vihar, Pitam Pura,  
Delhi-110034  
Ph. 011-42480101, 9599913051  
E-mail: [oneplusul@gmail.com](mailto:oneplusul@gmail.com)

# ONEPLUS ULTRASOUND LAB

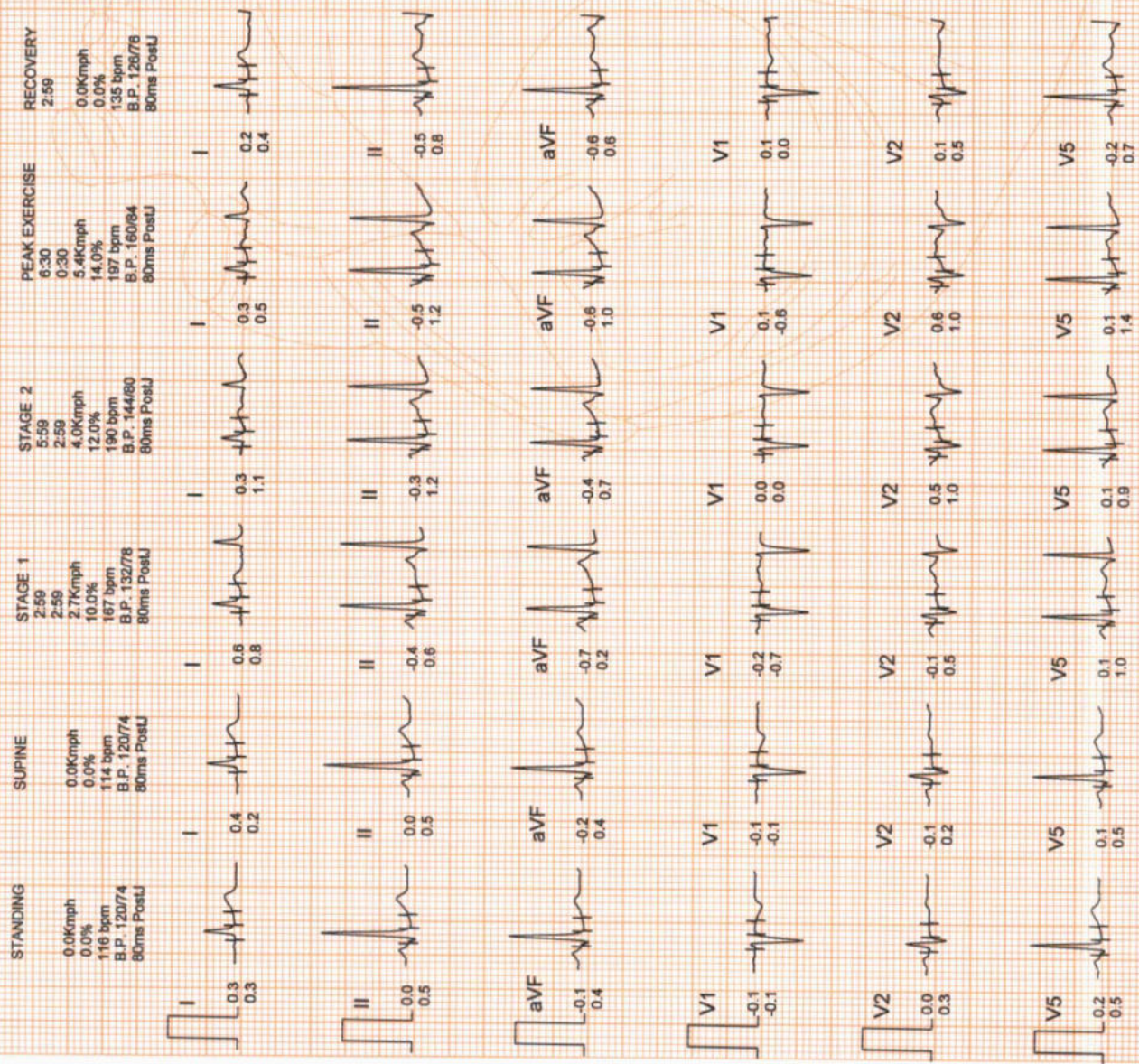
I.D. : 996

Ms. SANTOSH JAIN

AGE/SEX : 24/F

RECORDED : 8-11-2022 12:58

AVG E.C.G.



ONEPLUS ULTRASOUND LAB  
 47, Harsh Vihar, Pitam Pura,  
 Delhi-110034  
 Ph. 011-42480101, 9599913051  
 E-mail: oneplusul@gmail.com

# ONEPLUS ULTRASOUND LAB

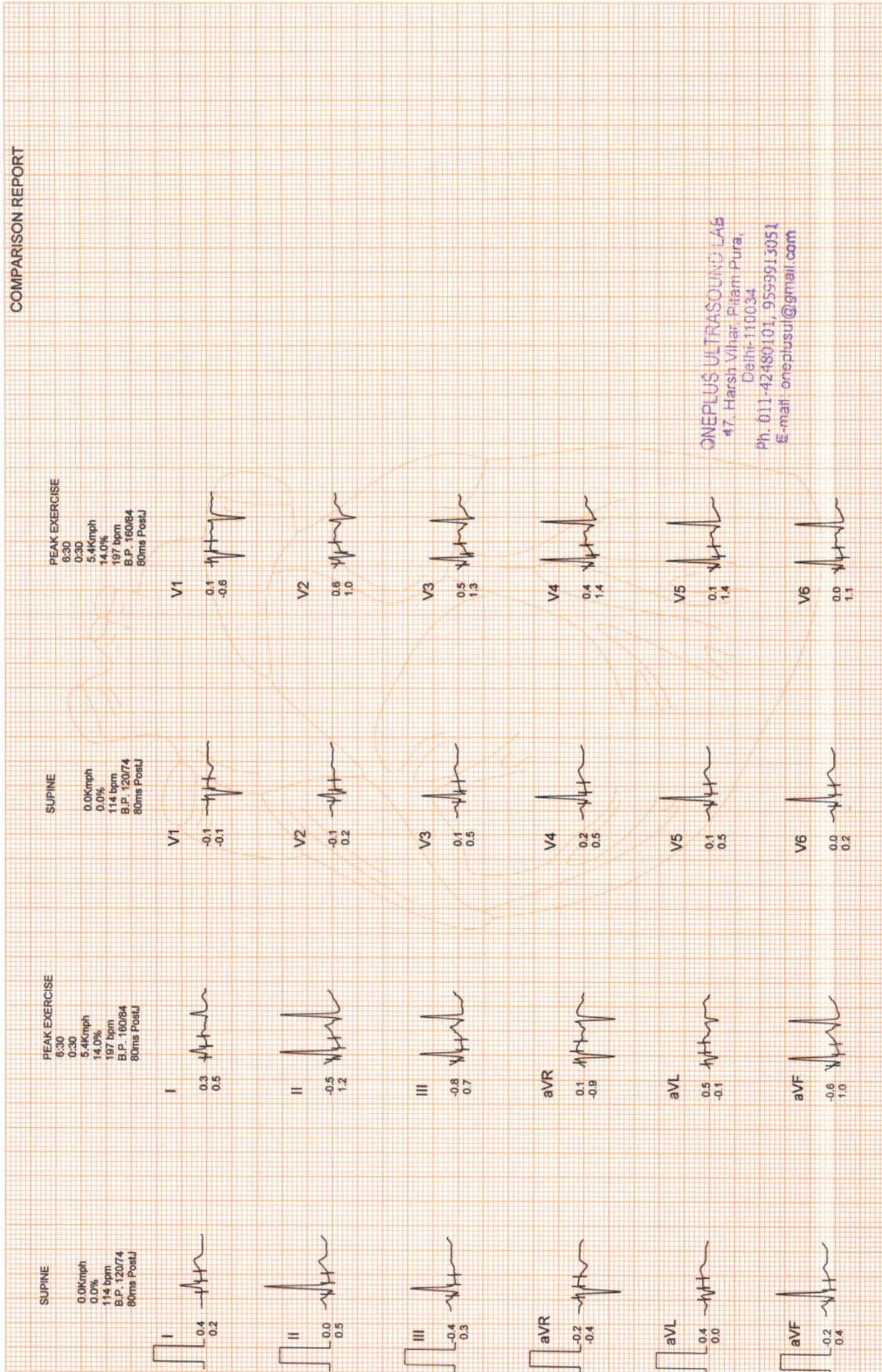
AGE/SEX : 24/F

I.D. : 996

Ms. SANTOSH JAIN

RECORDED : 8-11-2022 12:58

## COMPARISON REPORT



ONEPLUS ULTRASOUND LAB  
 #7, Harsh Vihar, Pitam Pura,  
 Delhi-110034  
 Ph. 011-42480101, 9599913051  
 E-mail: oneplusul@gmail.com





**OnePLUS**  
Ultrasound Lab  
— QUALITY FIRST... ALWAYS! —

**Dr. Nitin Agarwal**  
Pathologist & Director  
Ex. Sr. Res. MAMC  
& Lok Nayak Hospital  
Ex. Chief of Lab Dr. Lal Path Labs.

**Dr. Pooja (Garg) Agarwal**  
Radiologist & Director  
MAMC & Lok Nayak Hospital

<b>Name</b>	: Mrs. SANTOSH JAIN	<b>Age/Sex</b>	: 24 YRS/Female
<b>Ref. By</b>	: Dr. MEDIWHEEL	<b>Lab No</b>	: 012211080025
<b>Date</b>	: 08-Nov-2022	<b>Patient ID</b>	: LSHHI104400

### ULTRASOUND EXAMINATION----WHOLE ABDOMEN

**Liver** is normal in size and outline with normal echopattern. No abscess or mass lesion seen. Hepatic veins, portal vein, IVC and aorta are normal. Intrahepatic biliary radicles are not dilated. CBD is normal in caliber.

**Gall bladder** is well distended with anechoic lumen. Wall thickness is normal.

**Both kidneys** are normal in size, shape, position, outline and echopattern. Corticomedullary differentiation is maintained. No pelvicalyceal dilation or mass lesion is seen. **A calculus (5.1 mm) is seen at mid pole calyx of left kidney.**

**Spleen** is normal in size and echotexture. No mass lesion seen.

**Pancreas** is normal in size, outline and echotexture.

**Urinary bladder** is normal in shape and position. No evidence of intravesical stone or mass seen.

**Uterus** is normal in size (measures 8.0 x 3.1 cm), shape, position and echopattern. No mass seen.

**Uterine cavity** is empty. **Endometrial thickness** is 7.5 mm.

**Both ovaries** appear normal in size, shape and echopattern. No tubo-ovarian mass seen.

**There is e/o well defined anechoic cystic lesion sized 2.4 x 1.6 cm in right adnexa, adjoining the right ovary with no internal septations /solid component/internal vascularity ? simple right paraovarian cyst ?? exophytic ovarian cyst.**

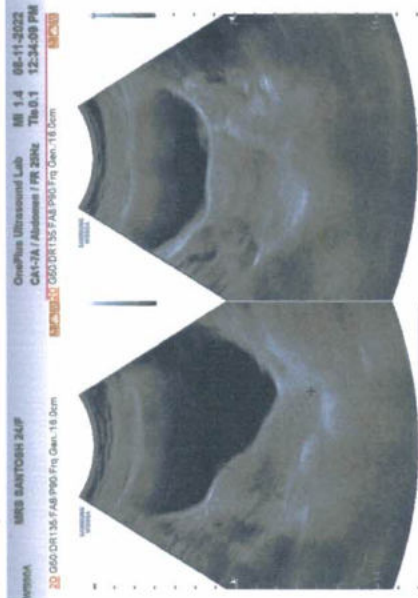
No abnormal bowel wall thickening seen in right iliac fossa.  
No free fluid seen anywhere in abdomen.

**Please correlate clinically**

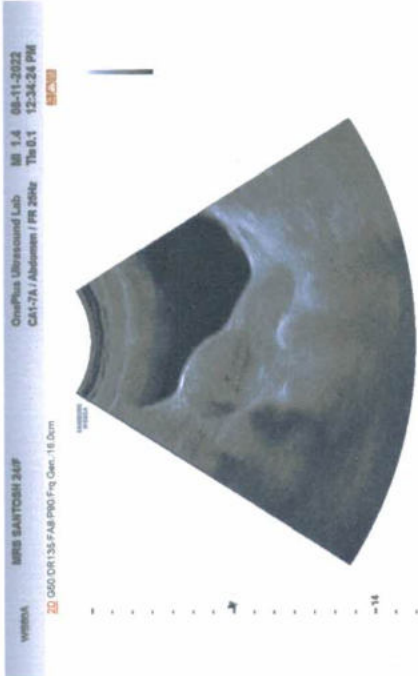**Dr. POOJA GARG**  
M.B.B.S., D.M.R.D.  
Reg No. DMC/R/03398  
Radiologist  
**DR. POOJA GARG**  
RADIOLOGIST  
REG. NO. DMC/R/03398

Type By : darshita

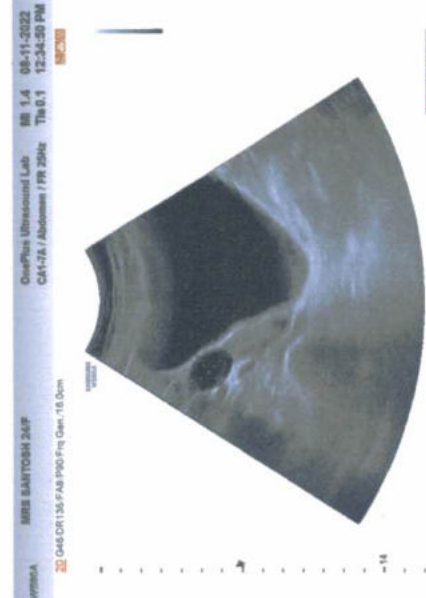
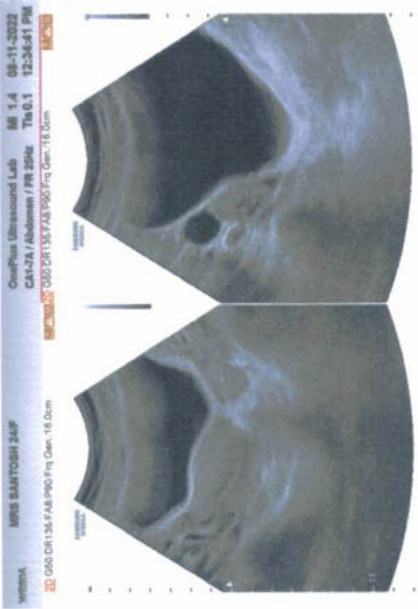
47, Harsh Vihar, Pitampura, New Delhi-110034 | Ph.: 011-42480101, 9599913051  
E-mail: [oneplusul@gmail.com](mailto:oneplusul@gmail.com) | Web.: [www.oneplusul.in](http://www.oneplusul.in)



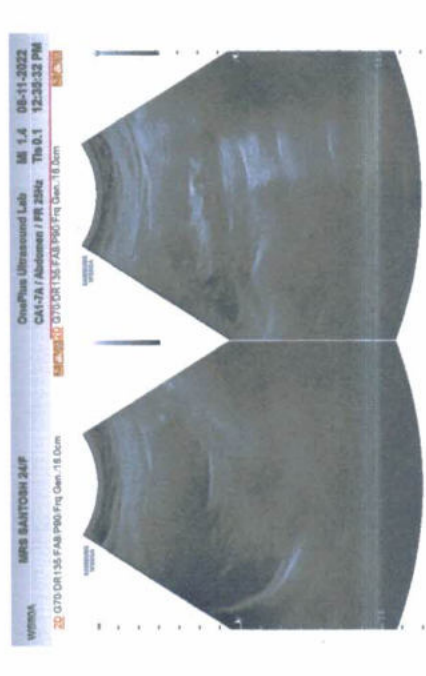
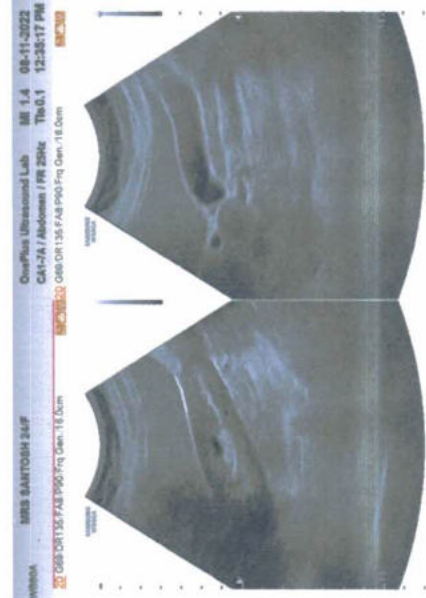
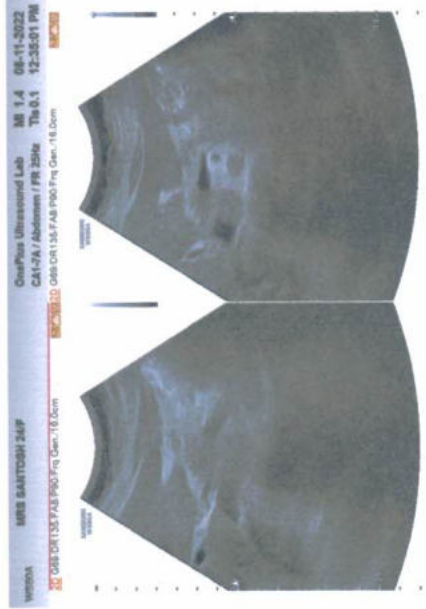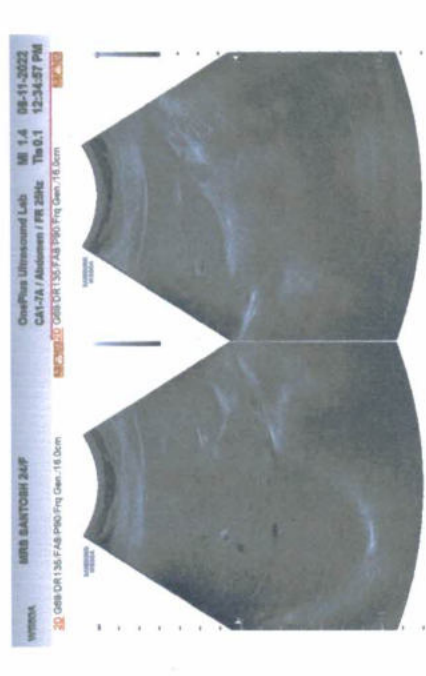
D1 8.63 cm  
D2 9.11 cm



D1 0.78 cm



D1 3.40 cm  
D2 1.64 cm




D1 0.51 cm

Division of Biological Sciences

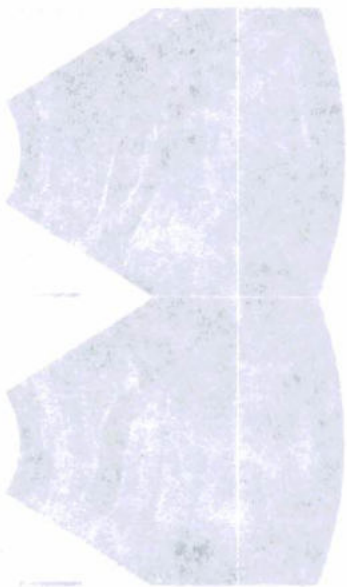PROJECT: 81-20  
APPROVED FOR: [illegible]  
APPROVED BY: [illegible]



PROJECT: 81-20  
APPROVED FOR: [illegible]  
APPROVED BY: [illegible]



PROJECT: 81-20  
APPROVED FOR: [illegible]  
APPROVED BY: [illegible]




PROJECT: 81-20  
APPROVED FOR: [illegible]  
APPROVED BY: [illegible]



PROJECT: 81-20  
APPROVED FOR: [illegible]  
APPROVED BY: [illegible]



PROJECT: 81-20  
APPROVED FOR: [illegible]  
APPROVED BY: [illegible]




PROJECT: 81-20  
APPROVED FOR: [illegible]  
APPROVED BY: [illegible]



PROJECT: 81-20  
APPROVED FOR: [illegible]  
APPROVED BY: [illegible]



PROJECT: 81-20  
APPROVED FOR: [illegible]  
APPROVED BY: [illegible]





# OnePLUS Ultrasound Lab

— QUALITY FIRST... ALWAYS! —

**Dr. Nitin Agarwal**  
Pathologist & Director  
Ex. Sr. Res. MAMC  
& Lok Nayak Hospital  
Ex. Chief of Lab Dr. Lal Path Labs.

**Dr. Pooja (Garg) Agarwal**  
Radiologist & Director  
MAMC & Lok Nayak Hospital



NAME	:Mrs. SANTOSH JAIN	Barcode No	:10131158
AGE/GENDER	:24 YRS/Female	SPECIMEN DATE	:08/Nov/2022 11:03AM
PATIENT ID	:104400	SPECIMEN RECEIVED	:08/Nov/2022 12:51PM
REFERRED BY	:Dr. MEDIWHEEL	REPORT DATE	:08/Nov/2022 03:23PM
CENTRE NAME	:ONEPLUS ULTRASOUND LAB	LAB NO.	:012211080025

Test Name	Result	Unit	Ref. Range
-----------	--------	------	------------

## HAEMATOLOGY

### Health checkup 2 Female

<b>Glycosylated Hemoglobin (HbA1c)</b>	5.1	%	Non Diabetic adults <5.7 Prediabetic (at risk) 5.7-6.4 Diabetes >6.4
--	-----	---	--

<b>Estimated average blood glucose (eag)</b>	100
--	-----

Reference range (mg/dl):

90 - 120:Excellent control, 121 - 150:Good Control, 151 - 180:Average Control, 181 - 210:Action Suggested

>211:Panic value

<b>BLOOD GROUP (ABO)</b>	B
<b>Rh typing</b>	POSITIVE

### NOTE :

- \* Apart from major A,B,H antigens which are used for ABO grouping and Rh typing, many minor blood group antigens exist. Agglutination may also vary according to titre of antigen and antibody.
- \* So before transfusion, reconfirmation of blood group as well as cross-matching is needed.
- \* Presence of maternal antibodies in newborns, may interfere with blood grouping.
- \* Auto agglutination (due to cold antibody, falciparum malaria, sepsis, internal malignancy etc.) may also cause erroneous result.

### CBC

Haemoglobin	9.7	g/dl	11.5-15.0
Total Leucocyte Count	7400	/cumm	4000-10000
<b>Differential leucocyte count</b>			
Neutrophils	74.9	%	40-80
Lymphocyte	19.70	%	20-40
Monocytes	3.40	%	2-10
Eosinophils	01	%	1-6
Basophils	01	%	0-2
RBC Count	4.40	million/cumm	3.8-4.8

Checked By.

Dr. NITIN AGARWAL  
M B B S , MD (Path)  
DMC/R/01436

47, Harsh Vihar, Pitampura, New Delhi-110034 | Ph.: 011-42480101, 9599913051

E-mail: onepusul@gmail.com | Web.: www.oneplusul.in

Page 1 of 5



# OnePLUS Ultrasound Lab

— QUALITY FIRST... ALWAYS! —

**Dr. Nitin Agarwal**  
Pathologist & Director  
Ex. Sr. Res. MAMC  
& Lok Nayak Hospital  
Ex. Chief of Lab Dr. Lal Path Labs.

**Dr. Pooja (Garg) Agarwal**  
Radiologist & Director  
MAMC & Lok Nayak Hospital



NAME	:Mrs. SANTOSH JAIN	Barcode No	:10131158
AGE/GENDER	:24 YRS/Female	SPECIMEN DATE	:08/Nov/2022 11:03AM
PATIENT ID	:104400	SPECIMEN RECEIVED	:08/Nov/2022 12:51PM
REFERRED BY	:Dr. MEDIWHEEL	REPORT DATE	:08/Nov/2022 03:23PM
CENTRE NAME	:ONEPLUS ULTRASOUND LAB	LAB NO.	:012211080025

Test Name	Result	Unit	Ref. Range
PCV(Hematocrit)	33.4	%	36-46
MCV	75.9	fL	83-101
MCH	22.1	Pg	27-32
MCHC	29.2	G/dL	32-35
Platelet count	267000	/cumm	150000-450000
RDW-CV	16.8	%	11.4-14.0
ESR(WESTEGRENs METHOD)	16	mm/1hr	<20

### BIOCHEMISTRY

<u>Blood sugar fasting</u>	88	mg/dL	70-110
<u>Blood sugar pp</u>	114	mg/dL	70.0-140.0
<u>Bun (blood urea nitrogen )</u>	13.60	mg/dl	7-18.7
<u>Uric acid, serum</u>	4.9	mg/dl	2.6-6.0
<u>Creatinine, serum</u>	0.5	mg/dl	0.50-1.0


### LFT(LIVER FUNCTION TEST)

Bilirubin Total	0.54	mg/dl	0.1-1.2
Bilirubin Conjugated	0.23	mg/dl	0-0.4
Bilirubin Unconjugated	0.31	mg/dl	up to 0.7
SGOT (AST)	26	U/L	0-46
SGPT (ALT)	23	U/L	0-49
Alkaline phosphatase	96	U/L	35-104
Gamma glutamyl transpeptidase	27	U/L	5.0-32.0
Total Protein	7.2	gm/dl	6.60 - 8.70
Albumin serum	4.6	g/dL	3.0-5.2
Globulin	2.60	gm/dl	1.8-3.4
Albumin/Globulin Ratio	1.77		1.10 - 2.50

### LIPID PROFILE

Cholesterol	233	mg/dl	50-200
Triglycerides	66	mg/dL	25-150

Checked By.

  
Dr. NITIN AGARWAL  
M B B S , MD (MBBS, MD (PATHOLOGIST))  
DMC/R/01436

47, Harsh Vihar, Pitampura, New Delhi-110034 | Ph.: 011-42480101, 9599913051

E-mail: [oneplusul@gmail.com](mailto:oneplusul@gmail.com) | Web.: [www.oneplusul.in](http://www.oneplusul.in)

Page 2 of 5



# OnePLUS Ultrasound Lab

— QUALITY FIRST... ALWAYS! —

**Dr. Nitin Agarwal**  
Pathologist & Director  
Ex. Sr. Res. MAMC  
& Lok Nayak Hospital  
Ex. Chief of Lab Dr. Lal Path Labs.

**Dr. Pooja (Garg) Agarwal**  
Radiologist & Director  
MAMC & Lok Nayak Hospital



NAME	:Mrs. SANTOSH JAIN	Barcode No	:10131158
AGE/GENDER	:24 YRS/Female	SPECIMEN DATE	:08/Nov/2022 11:03AM
PATIENT ID	:104400	SPECIMEN RECEIVED	:08/Nov/2022 12:51PM
REFERRED BY	:Dr. MEDIWHEEL	REPORT DATE	:08/Nov/2022 03:23PM
CENTRE NAME	:ONEPLUS ULTRASOUND LAB	LAB NO.	:012211080025

Test Name	Result	Unit	Ref. Range
HDL Cholesterol	46	mg/dL	40 - 60
LDL cholesterol	174	mg/dL	< 130
VLDL cholesterol	13.2	mg/dL	5-40
Cholesterol/HDL Ratio	5.1		Low Risk 3.3-4.97 Average Risk 4.4-7.1 Moderate Risk 7.1-11.0 High Risk >11.0
LDL/HDL Ratio	3.8		0 - 3.55

According to ATP III and NCEP guidelines

Parameter	Normal	Desirable	Borderline	High
Total cholesterol	<200		200-239	240
Triglycerides	<150	150-199	200-499	500
LDL	Optimal <100 Near Optimal 100-129	130-159	160-180	190
HDL	<40 : LOW 60 : HIGH			

## ENDOCRINOLOGY

### THYROID PROFILE(T3,T4,TSH)

Triiodothyronine total [t3]	0.69	ng/dl	0.52-1.9
Thyroxine total [t4]	6.50	µg/dl	4.8-11.6
TSH (Thyroid Stimulating Hormone)	5.50	µIU/ml	0.25-5.0

### AGE WISE VARIATION IN TSH

AGE	TSH(µIU/ml)	AGE	TSH(µIU/ml)
1-4 weeks	1.00 - 19.0	16-20 yrs	0.25 - 5.0
1-12 mths	1.70 - 9.1	21 - 80 yrs	0.25 - 5.0
1-5 yrs	0.80 - 8.2	1 <sup>st</sup> trimester	0.25 - 5.0

Checked By.

Dr. NITIN AGARWAL  
MBBS, MD (PATHOLOGIST)  
DMC/R/01436

47, Harsh Vihar, Pitampura, New Delhi-110034 | Ph.: 011-42480101, 9599913051

E-mail: oneplusul@gmail.com | Web.: www.oneplusul.in

Page 3 of 5



# OnePLUS

## Ultrasound Lab

QUALITY FIRST... ALWAYS!

**Dr. Nitin Agarwal**  
Pathologist & Director  
Ex. Sr. Res. MAMC  
& Lok Nayak Hospital  
Ex. Chief of Lab Dr. Lal Path Labs.

**Dr. Pooja (Garg) Agarwal**  
Radiologist & Director  
MAMC & Lok Nayak Hospital



NAME	:Mrs. SANTOSH JAIN	Barcode No	:10131158
AGE/GENDER	:24 YRS/Female	SPECIMEN DATE	:08/Nov/2022 11:03AM
PATIENT ID	:104400	SPECIMEN RECEIVED	:08/Nov/2022 12:51PM
REFERRED BY	:Dr. MEDIWHEEL	REPORT DATE	:08/Nov/2022 03:23PM
CENTRE NAME	:ONEPLUS ULTRASOUND LAB	LAB NO.	:012211080025

Test Name	Result	Unit	Ref. Range
6-10 yrs	0.25 - 5.0	II <sup>nd</sup> trimester	0.50 - 5.0
11-15 yrs	0.25 - 5.0	II <sup>rd</sup> trimester	0.4 - 6.0

### Reference ranges - Interpretation of Diagnostic tests - (Jacques Wallach)

1. Primary hypothyroidism is accompanied by depressed serum T3 and T4 values and elevated serum TSH level.
2. Primary hyperthyroidism is accompanied by elevated serum T3 and T4 levels along with depressed TSH values.
3. Slightly elevated T3 levels may be found in pregnancy and estrogen therapy, while depressed levels may be encountered in severe illness, renal failure and during therapy with drugs like propranolol and propyl thiouracil.
4. Although elevated TSH levels are nearly always indicative of primary hypothyroidism, and may be seen in secondary thyrotoxicosis

## CLINICAL PATHOLOGY

### URINE ROUTINE

#### Physical examination

Quantity	30	ML
Colour	PALE YELLOW	
Transparency	CLEAR	CLEAR
Sp.gravity	1.020	1.010-1.030
pH	6.00	
Reaction	ACIDIC	ACIDIC


#### Chemical examination

Urine protein	NIL	NIL
Urine sugar	NIL	NIL
Bilirubin, urine	NEGATIVE	NEGATIVE
Urobilinogen	NORMAL	NORMAL
Ketones	NEGATIVE	NEGATIVE

#### Microscopic examination

<b>Pus cells.</b>	2-3	/HPF	1-2
Epithelial cells	3-4	/HPF	0-5
R.B.C.	NIL	/HPF	NIL
Casts	NIL	/HPF	NIL

Checked By.

  
Dr. NITIN AGARWAL  
MBBS, MD (Path),  
DMC/R/01436

47, Harsh Vihar, Pitampura, New Delhi-110034 | Ph.: 011-42480101, 9599913051

E-mail: [oneplusul@gmail.com](mailto:oneplusul@gmail.com) | Web.: [www.oneplusul.in](http://www.oneplusul.in)

Page 4 of 5



# OnePLUS Ultrasound Lab

QUALITY FIRST... ALWAYS!

**Dr. Nitin Agarwal**

Pathologist & Director  
Ex. Sr. Res. MAMC  
& Lok Nayak Hospital  
Ex. Chief of Lab Dr. Lal Path Labs.

**Dr. Pooja (Garg) Agarwal**

Radiologist & Director  
MAMC & Lok Nayak Hospital



NAME	:Mrs. SANTOSH JAIN	Barcode No	:10131158
AGE/GENDER	:24 YRS/Female	SPECIMEN DATE	:08/Nov/2022 11:03AM
PATIENT ID	:104400	SPECIMEN RECEIVED	:08/Nov/2022 12:51PM
REFERRED BY	:Dr. MEDIWHEEL	REPORT DATE	:08/Nov/2022 03:23PM
CENTRE NAME	:ONEPLUS ULTRASOUND LAB	LAB NO.	:012211080025

Test Name	Result	Unit	Ref. Range
Crystals	NIL	/HPF	NIL
Bacteria	NIL	/HPF	NIL
Others.	NIL		NIL

\*\*\* End Of Report \*\*\*

Checked By.

Dr NITIN AGARWAL  
MBBS, MD (Path)  
DMC/R/01436  
DR. NITIN AGARWAL  
MBBS, MD (PATHOLOGIST)

47, Harsh Vihar, Pitampura, New Delhi-110034 | Ph.: 011-42480101, 9599913051

E-mail: [oneplusul@gmail.com](mailto:oneplusul@gmail.com) | Web.: [www.oneplusul.in](http://www.oneplusul.in)

Page 5 of 5





**OnePLUS**  
Ultrasound Lab

— QUALITY FIRST... ALWAYS! —

**Dr. Nitin Agarwal**

Pathologist & Director  
Ex. Sr. Res. MAMC  
& Lok Nayak Hospital  
Ex. Chief of Lab Dr. Lal Path Labs.

**Dr. Pooja (Garg) Agarwal**

Radiologist & Director  
MAMC & Lok Nayak Hospital

Name	: Mrs. SANTOSH JAIN	Age/Sex	: 24 YRS/Female
Ref. By	: Dr. MEDIWHEEL	Lab No	: 012211080025
Date	: 08-Nov-2022	Patient ID	: LSHHI104400

### X-ray-Chest PA view

Bony cage and soft tissues are normal.

Cardiothoracic ratio is normal.

Mediastinum is normal.


Both hila are normal.

Both costophrenic angles are clear.

Both domes of diaphragm are normal.

Lung fields are clear. No parenchymal lesion seen.

**IMPRESSION: Normal Study.**

  
**DR. POOJA GARG**  
RADIOLOGIST  
REG NO. DMC/R/03398  
M.B.B.S., D.M.R.D.  
Reg No. DMC/R/03398  
Radiologist

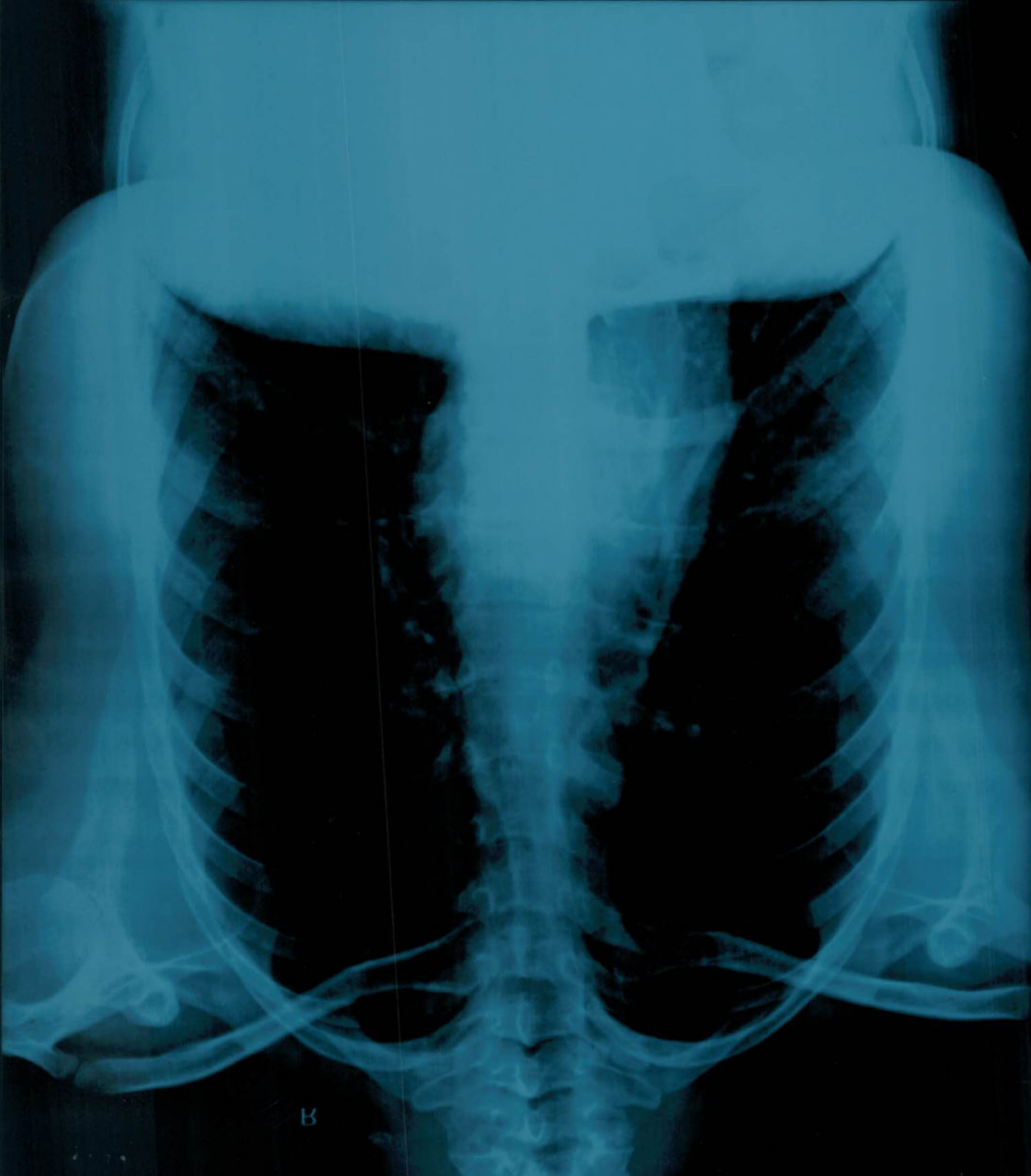Type By : darshita

47, Harsh Vihar, Pitampura, New Delhi-110034 | Ph.: 011-42480101, 9599913051

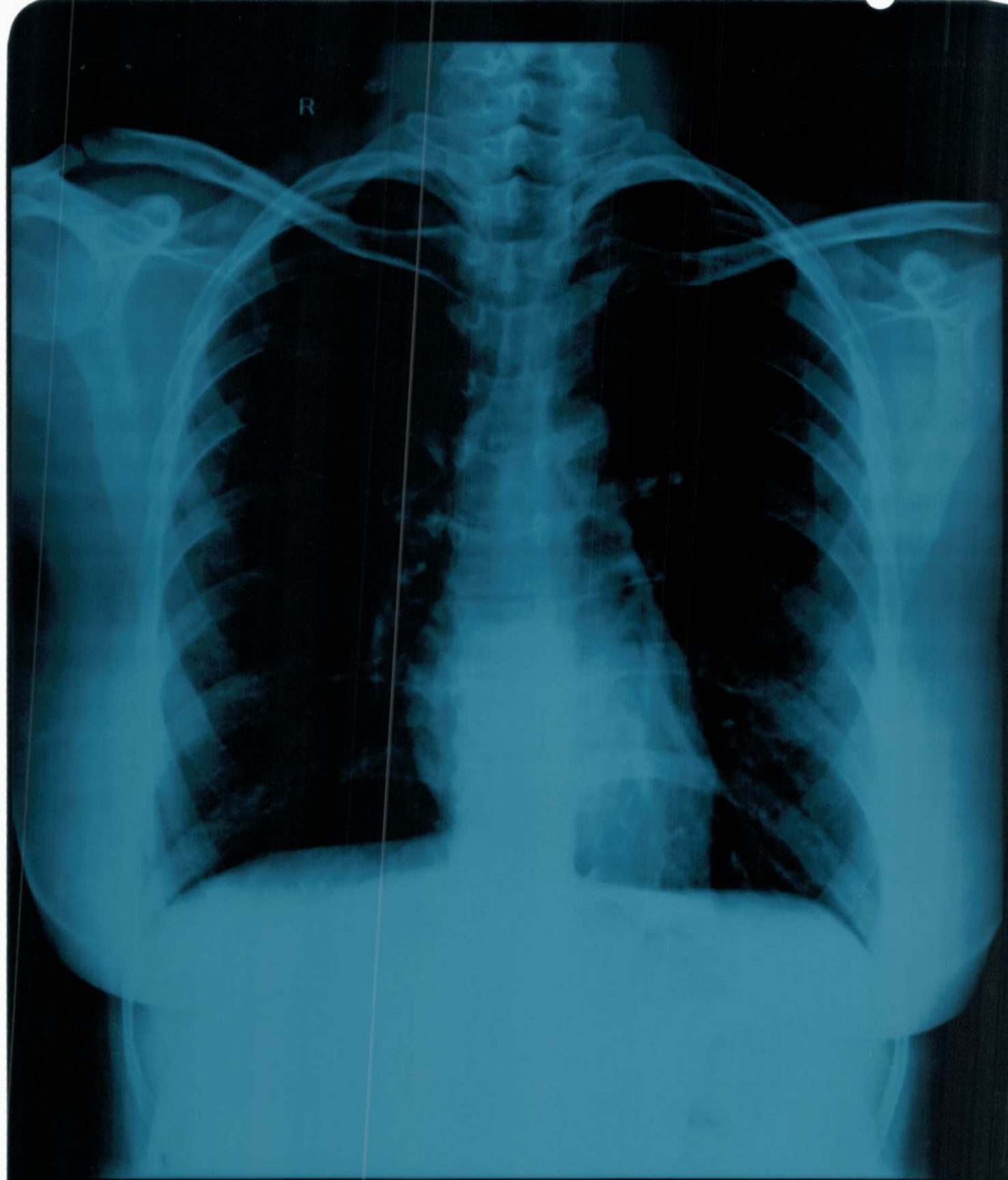
E-mail: oneplusul@gmail.com | Web.: www.oneplusul.in

Clinical correlation is essential for final diagnosis. • If test results are unsatisfactory please contact personally or on phone. • This report is for perusal of doctors only.  
• All disputes Subject to Delhi Jurisdiction only. • Not for medicolegal purposes. • All congenital anomalies in a foetus may not be diagnosed in routine obstetric ultrasound.

VIEW PA CHEST F 35017180 YRS 42 MIAL HOTOAS 2MS  
RUBA MBPUBITANV HAPSH-47 GAV. QUIDSOTRANU OIEBGS



B



R

MRS SANTOSH JAIN 24 YRS 08/11/2022 F CHEST PA VIEW  
ONEPLUS ULTRASOUND LAB,47-HARSH VIHAR,PITAMPURA