

MR. MAHENDRA SINGH LAHIYA
UNION BANK

46 YEARS / MALE

10-02-2024

Height: 171 Cms

Weight: 73 Kg

BP: - 128/86 mmhg

Pulse: - 72/- Regular

BMI: - 25 kg/m²

EYE: - Lost vision on from both eyes after acid attack in 1999

The Medical Examiner should record the findings under one of the following categories:-

FIT

UNFIT on account of

Dr. D. S. Chhabra
DR. D. S. CHHABRA
MBBS. MD.



MR. MAHENDRA SINGH LAHIYA

46 Years /M

UNION BANK

10-02-2024

HEAMOGRAM

Test Name	Results	Normal Range
Haemoglobin (HB)	16.1	13 - 18 gm%
R.B.C. Count	5.22	4.5 - 5.5 milli./cu.mm
PCV	47.6	40 - 50 %
MCV	91.19	80 - 95 fl
MCH	30.84	27 - 32 pg
MCHC	33.82	31.5 - 34.5 %
TOTAL WBC COUNT	5,200	4,000 to 11,000 /cu.mm
DIFFERENTIAL WBC COUNT	.	
Neutrophils	57	40 - 75 %
Lymphocytes	38	20 - 40 %
Monocytes	03	02 - 08 %
Eosinophils	02	01 - 05 %
Basophils	00	00 - 01 %
PLATELET COUNT	2.33	1.5 - 4 Lacs/cu.mm.
E.S.R	14	M- 0-10 at the end of 1 hr. F- 0-20 at the end of 1 hr

Dr. POOJA PRAPANNA

DR. POOJA PRAPANNA

M.D.

MR. MAHENDRA SINGH LAHIYA

46 Years /M

UNION BANK

10-02-2024

LIPID PROFILE

Test Name	Results	Normal Range
TOTAL LIPIDS	657	400 - 700 mg/dl
CHOLESTROL	180.0	<200 mg/dl- Desirable 200 - 239 mg/dl - Borderline High >240 Mg/dl High
HDL CHOLESTROL	49.0	35- 60 mg/dl
TRIGLYCERIDE	247.0	<150 mg/dl Normal 150 - 199 mg/dl Borderline High 200 - 499 mg/dl High
LDL CHOLESTROL	81.6	<100 mg/dl Optimal 100- 129 mg/dl Borderline high 160 - 189 mg/dl High
VLDL CHOLESTROL	49.4	<40 mg/dl
RISK RATIO	3.67	3 - 6

Dr. POOJA PRAPANNA

DR. POOJA PRAPANNA

M.D.

MR. MAHENDRA SINGH LAHIYA

46 Years /M

UNION BANK

10-02-2024

BIOCHEMISTRY

Test Name	Results	Normal Range
SERUM BILIRUBIN	:-	
TOTAL BILIRUBIN	0.82	0 - 1 mg/dl
DIRECT BILIRUBIN	0.17	<0.25 mg/dl
INDIRECT BILIRUBIN	0.65	< 1.0 mg/dl
S.G.O.T	30.0	0 - 45 IU/L
S.G.P.T	33.0	0 - 45 IU/L
ALKALINE PHOSPHATE	110.0	Adult - 42 - 128 IU/L Child - 150 - 630 IU/L
TOTAL PROTEIN	7.10	6.0 to 8.0 g/dl
ALBUMIN	3.29	3.2 to 5.0 g/dl
GLOBULIN	3.81	1.9 to 3.5
A:G RATIO	0.86	1.2 TO 2.3
GAMA GT	32.0	5 - 43 Iu/l

Dr. POOJA PRAPANNA
MD
DR. POOJA PRAPANNA
M.D.

MR. MAHENDRA SINGH LAHIYA

46 Years /M

UNION BANK

10-02-2024

Test Name	Results	Normal Range
-----------	---------	--------------

HAEMATOLOGY PROFILE

BLOOD GROUP

:-

"ABO " GROUP

"O"

Rh (D) Factor

Positive

(Cross matching & recheck of Blood Group is mandatory before any transfusion)

HBA1C

5.40

Normal 4-6 %

Good Control 6-7 %

Fair Control 7-8 %

Unsatisfactory

Control 8-10 %

Poor Control Above 10 %

SEROLOGY PROFILE

HBsAg

Non Reactive

* Test done by screening methods.
Requires confirmation at referral centre.

Dr. POOJA PRAPANNA
MD
DR. POOJA PRAPANNA
M.D.

MR. MAHENDRA SINGH LAHIYA

46 Years /M

UNION BANK

10-02-2024

Test Name	Results	Normal Range
<u>BIOCHEMISTRY</u>		
FASTING BLOOD SUGAR	71.0	70 - 110 mg/dl
P.P. BLOOD SUGAR	85.0	upto 140 mg/dl
BUN	11.0	5 - 21 Mg/dl
CREATININE	1.39	0.6 - 1.4 mg\dl
URIC ACID	6.35	3.5 - 7 mg\dl
CALCIUM	9.78	8.5 - 10.5 mg\dl

Dr. POOJA PRAPANNA
MP
DR. POOJA PRAPANNA
M.D.

MR. MAHENDRA SINGH LAHIYA
UNION BANK46 Years /M
10-02-2024**URINE EXAMINATION**

Test Name	Results	Normal Range
PHYSICAL EXAMINATION		
Quantity	30 ml	
Colour	Pale Yellow	
Appearance	Clear	
Deposits	Absent	
Specific Gravity	1.015	
Reaction	Acidic	
CHEMICAL EXAMINATION		
Albumin	Nil	
Sugar	Nil	
Ketones	Absent	
Bile Pigments	Negative	
Bile Salt	Negative	
Hematuria	Negative	
MICROSCOPIC EXAMINATION		
Pus Cells	1- 2 /hpf	
Red Blood Cells	Nil/hpf	
Epithelial Cell	1 - 2 /hpf	
Crystals	Nil	
Casts	Absent	

DR. POOJA PRAPANNA
MP
DR. POOJA PRAPANNA
M.D.

4D SONOGRAPHY • COLOR DOPPLER • ECHO • PATHOLOGY • DIGITAL X-RAY & OPG • TMT • ECG • HOLTER

MR. MAHENDRA SINGH LAHIYA

46 Yrs./M.

UNION BANK

10th Feb, 2024

X-RAY CHEST PA VIEW

Bony cage is normal.

Trachea is central. C.P. angles are clear.

Cardiac contour and cardiothoracic ratio are normal.

Lung fields are clear.



DR.D.S.CHHABRA.
M.D.

MR. MAHENDRA SINGH LAHIYA

46 Yrs/M.

UNION BANK

10th Feb, 2024

ABDOMINAL SONOGRAPHY

Liver is of normal size, shape, has smooth margins & regular contours and the parenchyma is mildly hyperechoic in echostructure, **early fatty changes**. No focal lesion.

Gall bladder is of normal size, shape, has thin walls & the contents are clear fluid. No evidence of any calculus. Biliary tree is undilated.

Pancreas is normal, no focal / diffuse pathology. Spleen is normal. The portal and splenic veins are normal in calibre.

Both Kidneys are normal in size [measure about 10.5 cms. in length], shape and echostructure. No evidence of any calculus in both. The collecting system and ureter on both side are undilated.

Urinary bladder is normal in size, shape & has thin walls.

Prostate is of normal size (around 16 gms.) & is normal in echostructure.

There is no ascitis. No obvious abdominal lymphadenopathy. No sub / supra diaphragmatic pathology on either side.

IMPRESSION:

Early fatty changes in liver.



DR.D.S.CHHABRA.
M.D.



LABORATORY REPORT



Name : Mr. MAHENDRA SINGH LAHIYA	Sex/Age : Male / 46 Years	Case ID : 40201602362
Ref. By :	Dis. At :	Pt. ID :
Bill. Loc. : UNIQUE DIAGNOSTIC CENTRE INDORE		Pt. Loc. :
Reg Date and Time : 10-Feb-2024 11:25	Sample Type : Serum	Mobile No. :
Sample Date and Time : 10-Feb-2024 11:25	Sample Coll. By : non	Ref Id1 :
Report Date and Time : 10-Feb-2024 13:00	Acc. Remarks : -	Ref Id2 :

TEST	RESULTS	UNIT	BIOLOGICAL REF RANGE	REMARKS
------	---------	------	----------------------	---------

BIOCHEMICAL INVESTIGATIONS

Electrolytes

Sodium <small>I_{SE}</small>	141.0	mEq/L	136 - 145	
Potassium <small>I_{SE}</small>	5.31	mEq/L	3.2 - 5.5	
Chloride <small>I_{SE}</small>	100.9	mEq/L	98 - 107	

Note: (LL-VeryLow, L-Low, H-High, HH-VeryHigh, A-Abnormal)

Dr Astha Dawani
Consultant Pathologist.

Dr. A Mishra
M.D. Microbiology

Dr. Soma Yadav
M.D. (Pathology)

Printed On : 10-Feb-2024 13:17

Page 1 of 5

Neuberg Diagnostics Private Limited

Laboratory : 3/3, South Tukoganj, Gokuldas Hospital Road, Near Madhumilan
Chouraha, Indore - 452001 Madhya Pradesh | 0731-4964961 / 62, 9713963333

neuberg.indore@supratechlabs.com

Regd. Office : Plot No. 7, Industrial Estate, Rajiv Gandhi Salai, Perungudi,
Chennai - 600096, Tamil Nadu, India. | CIN - U85300TN2017PTC114099

www.neubergsupratech.com



LABORATORY REPORT



Name : Mr. MAHENDRA SINGH LAHIYA	Sex/Age : Male / 46 Years	Case ID : 40201602362
Ref. By :	Dis. At :	Pt. ID :
Bill. Loc. : UNIQUE DIAGNOSTIC CENTRE INDORE		Pt. Loc. :
Reg Date and Time : 10-Feb-2024 11:25	Sample Type : Serum	Mobile No. :
Sample Date and Time : 10-Feb-2024 11:25	Sample Coll. By : non	Ref Id1 :
Report Date and Time : 10-Feb-2024 13:06	Acc. Remarks : -	Ref Id2 :

TEST	RESULTS	UNIT	BIOLOGICAL REF RANGE	REMARKS
Thyroid Function Test				
Triiodothyronine (T3) <small>CMA</small>	94.26	ng/dL	58 - 159	
Thyroxine (T4) <small>CMA</small>	8.29	µg/dL	4.6 - 10.5	
TSH <small>CMA</small>	0.97	µIU/mL	0.4 - 4.2	

INTERPRETATIONS

- Circulating TSH measurement has been used for screening for euthyroidism, screening and diagnosis for hyperthyroidism & hypothyroidism. Suppressed TSH (<0.01 µIU/mL) suggests a diagnosis of hyperthyroidism and elevated concentration (>7 µIU/mL) suggest hypothyroidism. TSH levels may be affected by acute illness and several medications including dopamine and glucocorticoids. Decreased (low or undetectable) in Graves disease. Increased in TSH secreting pituitary adenoma (secondary hyperthyroidism), PPTH and in hypothalamic disease thyrotropin (tertiary hyperthyroidism). Elevated in hypothyroidism (along with decreased T4) except for pituitary & hypothalamic disease.
- Mild to modest elevations in patient with normal T3 & T4 levels indicates impaired thyroid hormone reserves & incipient hypothyroidism (subclinical hypothyroidism).
- Mild to modest decrease with normal T3 & T4 indicates subclinical hyperthyroidism.
- Degree of TSH suppression does not reflect the severity of hyperthyroidism, therefore, measurement of free thyroid hormone levels is required in patient with a suppressed TSH level.

CAUTIONS

Sick, hospitalized patients may have falsely low or transiently elevated thyroid stimulating hormone. Some patients who have been exposed to animal antigens, either in the environment or as part of treatment or imaging procedure, may have circulating antianimal antibodies present. These antibodies may interfere with the assay reagents to produce unreliable results.

TSH ref range in pregnancy

	Reference range (microIU/ml)
First trimester	0.24 - 2.00
Second trimester	0.43-2.2
Third trimester	0.8-2.5

Note: (LL-VeryLow, L-Low, H-High, HH-VeryHigh, A-Abnormal)



Dr. Chetana Bora

MD Pathology

Page 2 of 5

Dr. A Mishra

M.D. Microbiology

Dr. Soma Yadav

M.D. (Pathology)

Printed On : 10-Feb-2024 13:17



LABORATORY REPORT

Name : Mr. MAHENDRA SINGH LAHIYA	Sex/Age : Male / 46 Years	Case ID : 40201602362
Ref. By :	Dis. At :	PL ID :
Bill. Loc. : UNIQUE DIAGNOSTIC CENTRE INDORE	Reg Date and Time : 10-Feb-2024 11:25	PL Loc :
Sample Date and Time : 10-Feb-2024 11:25	Sample Type : Serum	Mobile No. :
Report Date and Time : 10-Feb-2024 13:06	Sample Coll. By : non	Ref Id1 :
Acc. Remarks : -		Ref Id2 :

Interpretation Note:

Ultra sensitive thyroid-stimulating hormone (TSH) is a highly effective screening assay for thyroid disorders. In patients with an intact pituitary-thyroid axis, s-TSH provides a physiologic indicator of the functional level of thyroid hormone activity. Increased s-TSH indicates inadequate thyroid hormone, and suppressed s-TSH indicates excess thyroid hormone. Transient s-TSH abnormalities may be found in seriously ill, hospitalized patients, so this is not the ideal setting to assess thyroid function. However, even in these patients, s-TSH works better than total thyroxine (an alternative screening test) when the s-TSH result is abnormal, appropriate follow-up tests T4 & free T3 levels should be performed. If TSH is between 5.0 to 10.0 & free T4 & free T3 level are normal then it is considered as subclinical hypothyroidism which should be followed up after 4 weeks & if TSH is > 10 & free T4 & free T3 level are normal then it is considered as overt hypothyroidism.

Serum triiodothyronine (T3) levels often are depressed in sick and hospitalized patients, caused in part by the biochemical shift to the production of reverse T3. Therefore, T3 generally is not a reliable predictor of hypothyroidism. However, in a small subset of hyperthyroid patients, hyperthyroidism may be caused by overproduction of T3 (T3 toxicosis). To help diagnose and monitor this subgroup, T3 is measured on all specimens with suppressed s-TSH and normal FT4 concentrations.

Normal ranges of TSH & thyroid hormones vary according trimester in pregnancy:

TSH ref range in Pregnancy	Reference range (microIU/ml)
First trimester	0.24 - 2.00
Second trimester	0.43-2.2
Third trimester	0.8-2.5

	T3	T4	TSH
Normal Thyroid function	N	N	N
Primary Hyperthyroidism	↑	↑	↓
Secondary Hyperthyroidism	↑	↑	↑
Grave's Thyroiditis	↑	↑	↑
T3 Thyrotoxicosis	↑	N	N/↓
Primary Hypothyroidism	↓	↓	↑
Secondary Hypothyroidism	↓	↓	↓
Subclinical Hypothyroidism	N	N	↑
Patient on treatment	N	N/↑	↓

Note: (LL-Very Low, L-Low, H-High, HH-Very High, A-Abnormal)

Dr. Chetana Bora
MD Pathology

Dr. A Mishra
M.D. Microbiology

Dr. Soma Yadav
M.D. (Pathology)

Printed On : 10-Feb-2024 13:17



LABORATORY REPORT



Name : Mr. MAHENDRA SINGH LAHIYA	Sex/Age : Male / 46 Years	Case ID : 40201602362
Ref. By :	Dis. At :	Pt. ID :
Bill. Loc. : UNIQUE DIAGNOSTIC CENTRE INDORE		Pt. Loc. :
Reg Date and Time : 10-Feb-2024 11:25	Sample Type : Serum	Mobile No. :
Sample Date and Time : 10-Feb-2024 11:25	Sample Coll. By : non	Ref Id1 :
Report Date and Time : 10-Feb-2024 13:06	Acc. Remarks : -	Ref Id2 :

TEST	RESULTS	UNIT	BIOLOGICAL REF RANGE	REMARKS
Prostate Specific Antigen (PSA)				

Prostate Specific Antigen **0.821** ng/mL 0.00 - 4.00

	0 - 0.5 *(ng/mL)	>0.5 - 2.5 (ng/mL)	>2.5 - 5.0 (ng/mL)	>5.0 - 10 (ng/mL)	>10 (ng/mL)
Healthy Males	87.2	12.8	0.0	0.0	0.0
BPH	51.9	42.9	4.2	0.5	0.5
Stage A Prostate Cancer	38.5	42.3	11.5	3.8	3.8
Stage B Prostate Cancer	23.9	68.7	7.5	0.0	0.0

*% of population

Use

The total PSA test and digital rectal exam (DRE) are used together to help determine the need for a prostate biopsy. The goal of screening is to minimize unnecessary biopsies and to detect clinically significant prostate cancer while it is still confined to the prostate.

Clinical Significance of elevated levels of PSA are associated with prostate cancer, but they may also be seen with prostatitis and benign prostatic hyperplasia (BPH). Mild to moderately increased concentrations of PSA may be seen in those of African American heritage, and levels tend to increase in all men as they age.

Prostate biopsy is required for the diagnosis of cancer.

FREE PSA:TOTAL PSA

Males:

When Total PSA concentration is in the range of 4.0-10.0 ng/mL:

Free PSA/total PSA ratio	Probability of cancer		
	50-59 years	60-69 years	> or =70 years
< or =0.10	49%	58%	65%
0.11-0.18	27%	34%	41%
0.19-0.25	18%	24%	30%
>0.25	9%	12%	16%

----- End Of Report -----

Note:(LL-VeryLow,L-Low,H-High,HH-VeryHigh ,A-Abnormal)

Dr. Chetana Bora

MD Pathology

Page 4 of 5

Dr. A Mishra

M.D. Microbiology

Dr. Soma Yadav

M.D. (Pathology)

Printed On : 10-Feb-2024 13:17

Neuberg Diagnostics Private Limited

Laboratory : 3/3, South Tukoganj, Gokuldas Hospital Road, Near Madhumilan Chouraha, Indore - 452001 Madhya Pradesh ☎ 0731-4964961 / 62, 9713963333

neuberg.indore@supratechlabs.com

Regd. Office : Plot No. 7, Industrial Estate, Rajiv Gandhi Salai, Perungudi, Chennai - 600096, Tamil Nadu, India. | CIN - U85300TN2017PTC114099

www.neubergsupratech.com



LABORATORY REPORT



Name : Mr. MAHENDRA SINGH LAHIYA	Sex/Age : Male / 46 Years	Case ID : 40201602362
Ref. By :	Dis. At :	Pt. ID :
Bill. Loc. : UNIQUE DIAGNOSTIC CENTRE INDORE		Pt. Loc. :
Reg Date and Time : 10-Feb-2024 11:25	Sample Type : Serum	Mobile No. :
Sample Date and Time : 10-Feb-2024 11:25	Sample Coll. By : non	Ref Id1 :
Report Date and Time : 10-Feb-2024 13:06	Acc. Remarks : -	Ref Id2 :

For test performed on specimens received or collected from non-NSRL locations, it is presumed that the specimen belongs to the patient named or identified as labeled on the container/test request and such verification has been carried out at the point generation of the said specimen by the sender. NSRL will be responsible Only for the analytical part of test carried out. All other responsibility will be of referring Laboratory.

Note: (LL-VeryLow, L-Low, H-High, HH-VeryHigh A-Abnormal)

Dr. Chetana Bora

MD Pathology

Page 5 of 5

Dr. A Mishra

M.D. Microbiology

Dr. Soma Yadav

M.D. (Pathology)

Printed On : 10-Feb-2024 13:17

Neuberg Diagnostics Private Limited

Laboratory : 3/3, South Tukoganj, Gokuldas Hospital Road, Near Madhumilan Chouraha, Indore - 452001 Madhya Pradesh | 0731-4964961 / 62, 9713963333

neuberg.indore@supratechlabs.com

Regd. Office : Plot No. 7, Industrial Estate, Rajiv Gandhi Salai, Perungudi, Chennai - 600096, Tamil Nadu, India. | CIN - U85300TN2017PTC114099

www.neubergsupratech.com




Name: [REDACTED]
 [REDACTED]

Name: [REDACTED]
 MAHENDRA SINGH LAHRYA
 Date of Birth (DOB): 24/10/1977
 Gender: MALE

4803 4792 9056
 VID : 9130 0508 0020 1798
 मेरा आधार, मेरी पहचान



Dr. P. S. Chhabra
 483-4792-9056
 483-4792-9056




Name: [REDACTED]
 [REDACTED]

Address:
 S/O Prataap, Sarakari School K Raza, 541-
 Bhagirathpura, Indore, Indore,
 Madhya Pradesh - 452003

4803 4792 9056
 VID : 9130 0508 0020 1798
www.uidai.gov.in

M. S. LAHRYA

DR. PRIYANK JAIN

M.D.,D.M.

CONSULTANT CARDIOLOGIST

UNIQUE DIAGNOSTIC CENTRE

45-B, Jaora Compound,
Opp. M.Y.Hospital, M.Y.H. Road,
INDORE - 452 001. (M. P.).
Phone : 2704118. 4082228

ECHOCARDIOGRAPHY REPORT

NAME : **MR. MAHENDRA SINGH LAHIYA** **Age** : **46 Yrs./ M**
REFERRED BY : **UNION BANK** **Date** : **10th Feb, 2024**

ECHOCARDIOGRAPHIC OPINION

INTERPRETATION :-

- ** No RWMA.
- ** Good biventricular function. LVEF : 60 %.
- ** Normal cardiac valves, healthy pericardium.
- ** Grade I diastolic dysfunction.

Dr. PRIYANK JAIN
: **MBBS, M.D., D.M.**
Reg. No. 19547

DR. PRIYANK JAIN. M.D.,D.M.



TWO DIMENSIONAL ECHOCARDIOGRAPHY

M Mode examination revealed normal movement of both mitral leaflets during diastole.

No SAM or mitral valve prolapse is seen.

Mitral valve opening is normal. No evidence of mitral valve prolapse is seen.

Tricuspid valve is normal, pulmonary valve is normal, aortic root is normal in size, dimensions of left atrium and left ventricle are normal.

Aortic cusps are not thickened and enclosure line is central.

Aortic valve has three cusps and its opening is not restricted.

2 - D imaging in PLAX, SAX and apical views revealed a normal sized left ventricle.

Movement of septum, anterior, posterior, inferior and lateral walls is normal. Global LVEF is 60 %.

Right atrium and right ventricle are normal in size.

Tricuspid valve leaflets move normally.

Pulmonary valve is normal.

Interatrial and interventricular septa are intact.

No intracardiac mass or thrombus is seen.

No pericardial pathology is observed.



MEASUREMENTS :

[C] DIMENSIONS	OBSERVED VALUES	Normal Values (For Adults)
1. Aortic Root diameter	: 3.3 cms.	2.0-3.7 cm < 2.2 cm / M ²
2. Aortic Valve Opening	: 1.6 cms.	1.5-2.6 cm
3. Right Ventricular Dimension	: --	
4. Left Atrial Dimension	: 3.2 cms.	1.9-4.0 cm < 2.2 cm / M ²
5. Left Ventricular ED Dimension	: 4.4 cms.	3.7-5.6 cm < 3.2 cm / M ²
6. Left Ventricular ES Dimension	: 2.9 cms.	2.2-4.0 cm
7. Inter Ventricular ED Septal thickness	: 1.0 cms.	0.6-1.2 cm
8. Left Ventricular ED PW thickness	: 1.5 cms.	0.5-1.0 cm
9. IVS / LVPW	: 01	< 1.3

[E] INDICES OF LEFT VENTRICULAR FUNCTION

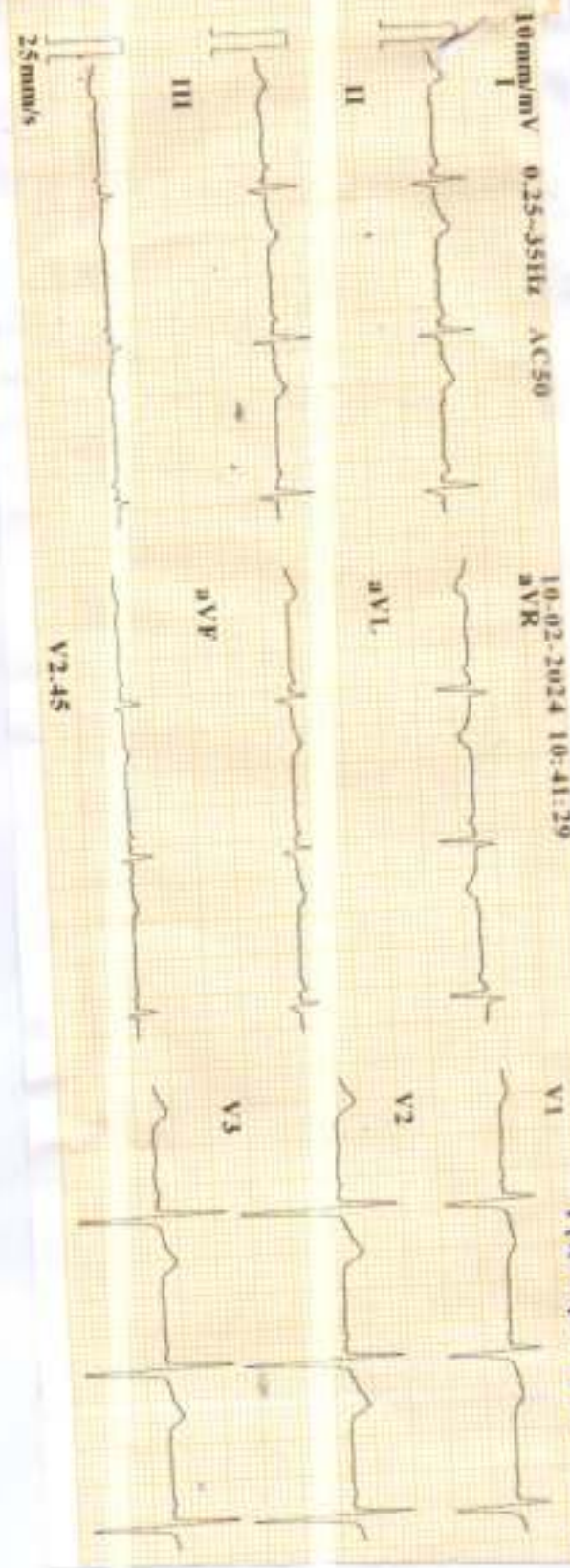
1. Mitral E - Septal Separation	: 0.5	< 0.9- cm
2. Left Ventricular Ejection Fraction	: 60 %	60 - 80 %



DOPPLER

Peak Flow Velocity (M/Sec.)		Peak Gradient (mmHg.)	Regurgitation
MV	Normal	--	Normal
TV	Normal	--	Normal
AV	Normal	--	Normal
PV	Normal	--	Normal

PASP : Normal



HR: Mahendra Singh

10mm/mV	0.25-35Hz	AC50	10-02-2024	10:41:29
			aVR	V1
			aVL	V2
			aVF	V3
			V2,45	
V4	V5	V6		

ID : 240210-1041 Minnesota Code:

Name : 46 yr
 Age : Male
 Sex :
 BP : mmHg
 Height : cm
 Weight : kg

HR : 73 bpm
 P Dur : 90 ms
 PR Int : 125 ms
 QRS Dur : 92 ms
 QT/QTc Int : 367/406 ms
 P/QRS/T axis : 22/60/15 °
 RV5/SV1 amp : 0.308/0.844 mV
 RV4/SV1 amp : 1.132 mV
 RV6/SV2 amp : 0.701/1.386 mV

Diagnosis Information:
 800: Sinus Rhythm
 Normal ECG

Report Confirmed by:

M O L K H V A

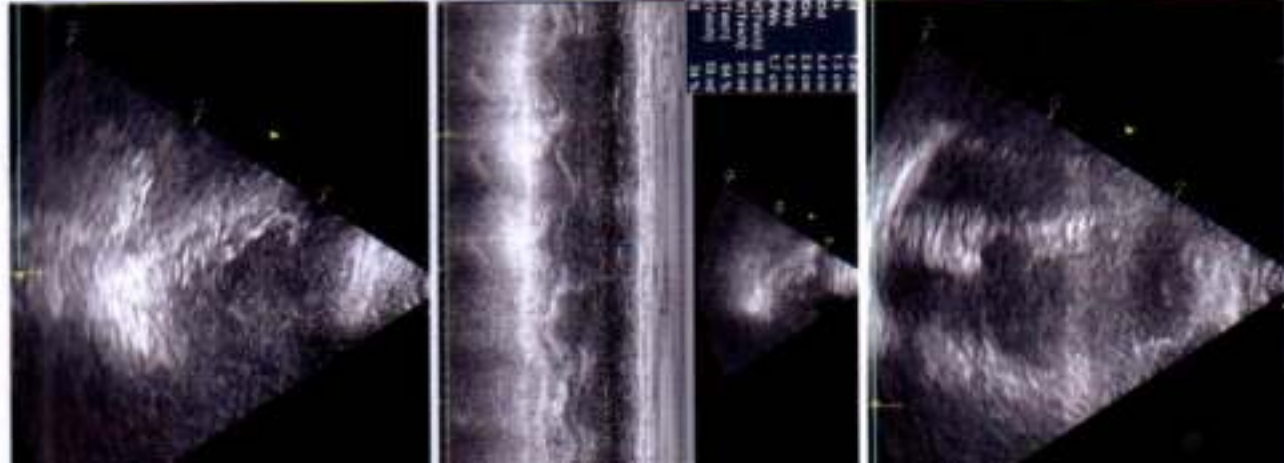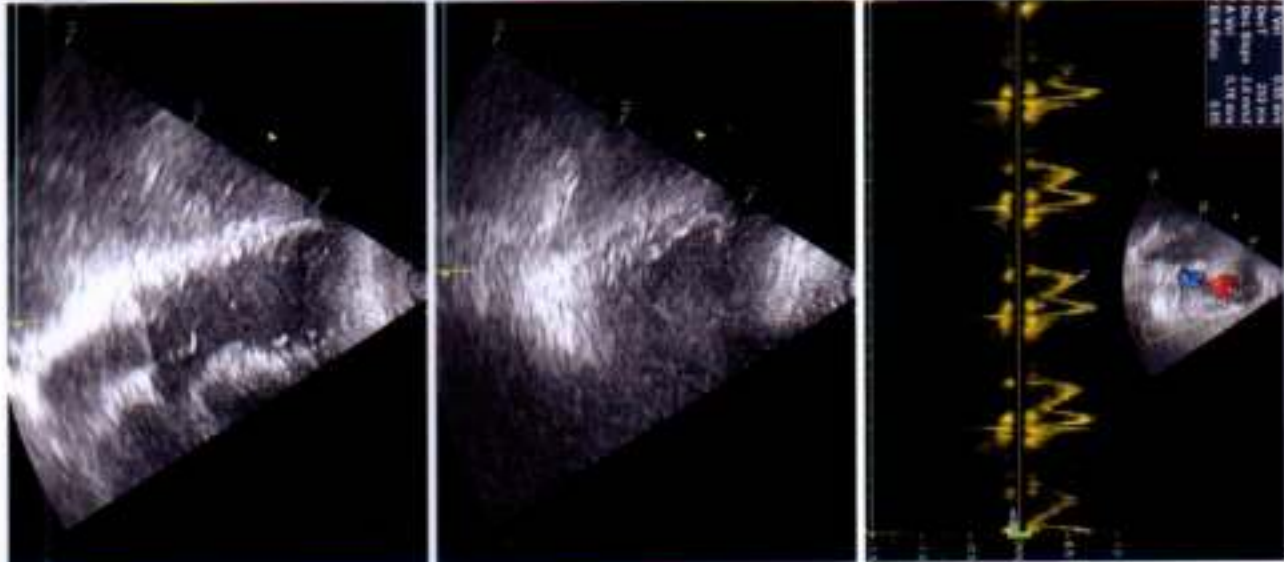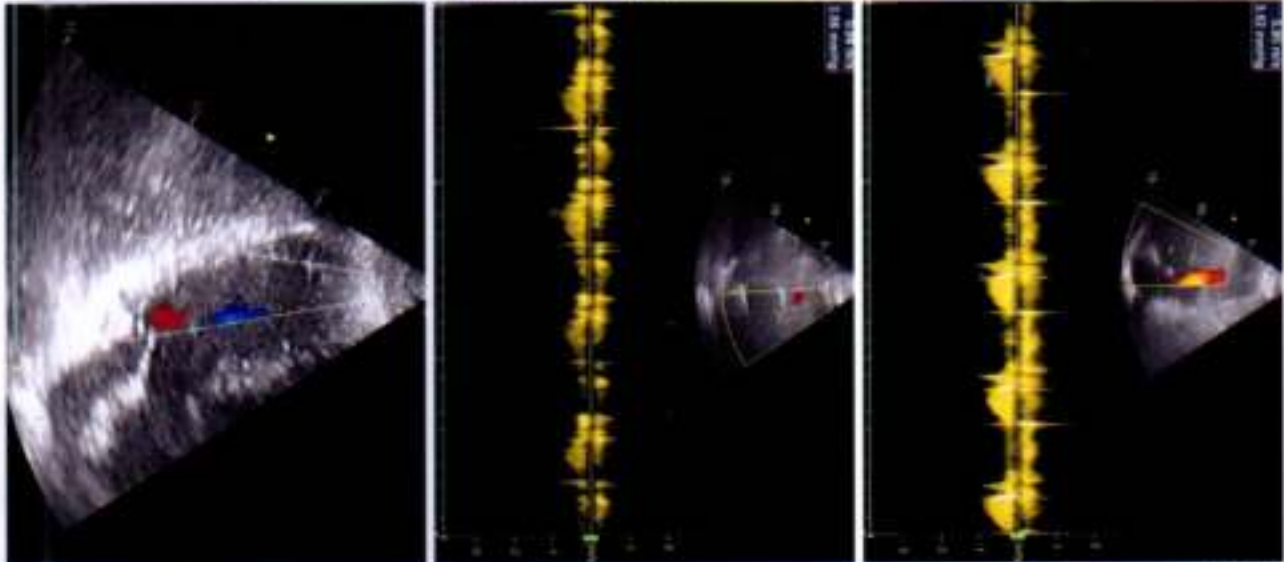
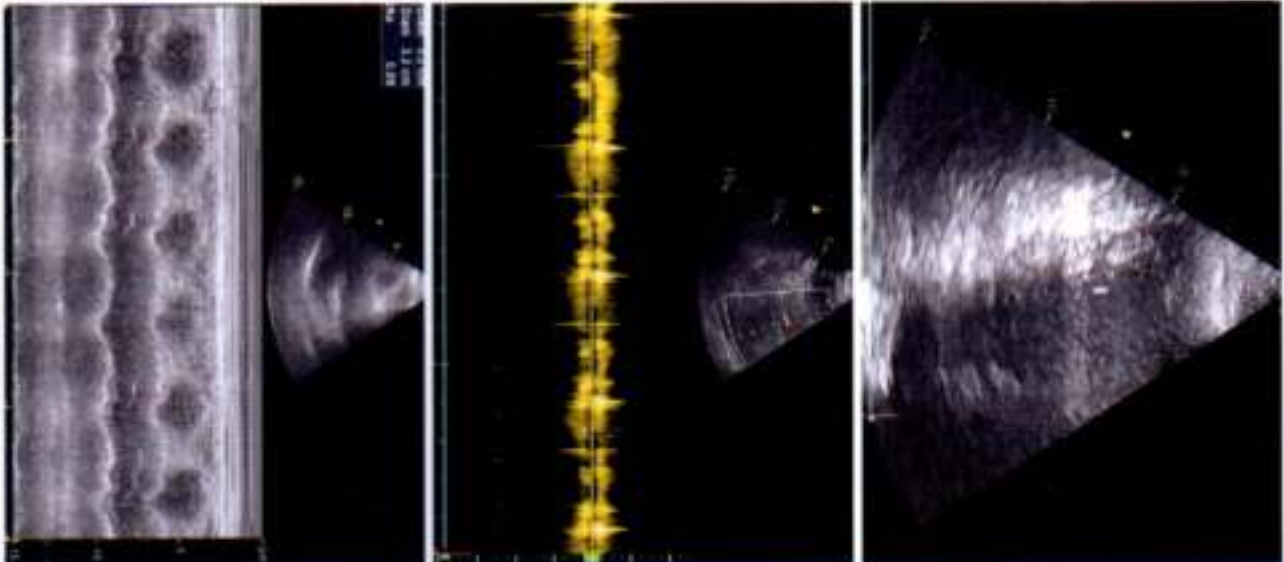
Dr. Mahendra Chourasiya
 M.D., D.M. (Cardio)



10 Feb 2024
Name : MR. MAHENDRA SINGH LAHIYA

UNIQUE DIAGNOSTIC CENTRE INDORE

Ref by : UNIO
Done by : DR. PRIYANK JAIN



117

