

**MEDICOVER****HOSPITALS**

NAVI MUMBAI

Name : Mrs. SHALAKA MHATRE
Bill No. : MCB54241101934Age /Sex : 32 Yrs (Female)
UMR No. : 542411000620**LABORATORY REPORT : BIOCHEMISTRY**

Parameters	Result	Reference Range	Units
BUN(BLOOD UREA NITROGEN)			
(Bill Date : 09-Nov-2024 11:27 AM Result ID : RMI241106760)			
BUN (Blood Urea Nitrogen.) <i>Calculated</i>	8	7 - 21.0	mg/dL
HBA1C (GLYCOSYLATED HAEMOGLOBIN)			
(Bill Date : 09-Nov-2024 11:27 AM Result ID : RMI241106761)			
HBA1C <i>HPLC</i>	5.2	" Normal : < 5.7% Pre diabetic : 5.7 % - 6.5 % Diabetic : > 6.5 %	
LIPID PROFILE			
(Bill Date : 09-Nov-2024 11:27 AM Result ID : RMI241106762)			
TOTAL CHOLESTEROL <i>Enzymatic colorimetric</i>	137	Desirable : < 200 mg/dL Borderline High : 200 - 239 mg/dL High risk : > 240 mg/dL	mg/dL
HDL CHOLESTEROL <i>Homogenous enzymatic colorimetric</i>	45	Low : < 40 mg/dL High : > 60 mg/dL	mg/dL
LDL CHOLESTEROL <i>Direct-Enzymatic colorimetric</i>	75	Very High : - > 190 mg/dL Optimal : - < 100 mg/dL Near Optimal : 100 - 129 mg/dL High : 160 - 189 mg/dL Borderline High:130-159 mg/dl	mg/dL
VLDL <i>Calculation</i>	15	2 - 30 mg/dL	mg/dL
SERUM TRYGLYCERIDES <i>Enzymatic colorimetric</i>	76	< 150 mg/dL Borderline High : 150 - 199 mg/dL High : 200 - 499 mg/dL	mg/dL
CHO/HDL RATIO <i>Calculation</i>	3.04	Normal : - < 3.5 High Risk : - > 5.0	
LDL/HDL RATIO	1.67		
FBS (FASTING BLOOD GLUCOSE WITH URINE GLUCOSE)			
(Bill Date : 09-Nov-2024 11:27 AM Result ID : RMI241106763)			
FASTING BLOOD GLUCOSE <i>Hexokinase</i>	85	Normal Range : 70 - 99 Impaired Glucose tolerance : 100 -125 Diabetes Mellitus : >=126	mg/dL





MEDICOVER

HOSPITALS

NAVI MUMBAI

Name : Mrs. SHALAKA MHATRE
Bill No. : MCB54241101934

Age /Sex : 52 Yrs FEMALE
UMR No. : 542411000620

FASTING URINE GLUCOSE NIL

SERUM CREATININE

(Bill Date : 09-Nov-2024 11:27 AM Result ID : RMI241106764)

CREATININE 0.72 0.6 - 1.2 mg/dL
..sifa

BUN / CREATININE RATIO

(Bill Date : 09-Nov-2024 11:27 AM Result ID : RMI241106765)

BUN / CREATININE RATIO 11.11 10-20
CALCULATED

LFT(LIVER FUNCTION TEST)

(Bill Date : 09-Nov-2024 11:27 AM Result ID : RMI241106766)

TOTAL BILIRUBIN 0.8 <1.2 mg/dL
DIAZO

DIRECT BILIRUBIN 0.3 * <=0.20 mg/dL
DIAZO

INDIRECT BILIRUBIN 0.5 <=1.0 mg/dL
Calculated

SGPT (ALT) 9 <=33 U/L
UV without PSP

SGOT (AST) 13 <= 32 U/L
UV without PSP

ALKALINE PHOSPHATASE (ALP) 61 35 - 105 U/L
PNPP, AMP Buffer - IFCC Ref.

TOTAL PROTEINS 7.4 6.0 - 8.0 g/dL
Buret method

SERUM ALBUMIN 4.9 3.5 - 5.2 g/dL
Bromocresol Green (BCG)

GLOBULINS 2.5 2.5 - 3.5 g/dL
Calculated

A/G RATIO 1.96 1.2 - 2.5
Calculation

GAMMA GLUTAMYL TRANSFERASE(GGT) 11 6-42 U/L
Gamma-glutamyl-carboxy-nitroanilide-IFCC





MEDICOVER

HOSPITALS

NAVI MUMBAI

Name : Mrs. SHALAKA MHATRE
Bill No. : MCB54241101934

Age /Sex : 52Y Yrs FEMALE
UMR No. : 542411000620

SERUM URIC ACID

(Bill Date : 09-Nov-2024 11:27 AM Result ID : RMI241106767)

SERUM URIC ACID <small>w/case</small>	2.9	2.4-5.7	mg/dL
--	-----	---------	-------

T3,T4 AND TSH

(Bill Date : 09-Nov-2024 11:27 AM Result ID : RMI241106771)

T3 <small>ECLM</small>	132.3	70 - 204	ng/dL
---------------------------	-------	----------	-------

T4 <small>ECLM</small>	7.80	5.1 - 14.1	ug/dL
---------------------------	------	------------	-------


TSH(THYROID STIMULATING HORMONE) <small>ECLIA</small>	2.23	0.270 - 4.20	uIU/mL
---	------	--------------	--------

PLBS (POST LUNCH BLOOD SUGAR WITH URINE SUGAR)

(Bill Date : 09-Nov-2024 11:27 AM Result ID : RMI241106975)

PLBS (POST LUNCH BLOOD GLUCOSE)	91		
------------------------------------	----	--	--

URINE SUGAR	NIL		
-------------	-----	--	--


DR. MEHROTRA VISHAL
MD Pathology





MEDICOVER

HOSPITALS

NAVI MUMBAI

Name : Mrs. SHALAKA MHATRE
Bill No. : MCB54241101934

Age /Sex : 32Y Y(s) FEMALE
UMR No. : 542411000620

LABORATORY REPORT : BLOOD BANK

Parameters	Result	Reference Range	Units
BLOOD GROUPING AND RH			
(Bill Date : 09-Nov-2024 11:27 AM Result ID : RMI241106769)			
BLOOD GROUP <i>Automated microcolumn gel method</i>	A		
RH TYPE	POSITIVE		

INTERPRETATION

1. If Rh is Du positive it is best considered as Rh negative as recipient and Rh positive as donor. Proper Cross matching is recommended before transfusion.
2. In case of forward and reverse grouping discrepancy, clinical correlation and repeat sample analysis is recommended.
3. For Infants below 6 months only forward grouping is performed.
4. A sub-grouping is recommended after the age of 6 months.


DR. MEHROTRA VISHAL
MD Pathology



**MEDICOVER**

NAVI MUMBAI

Name : Mrs. SHALAKA MHATRE
 Bill No. : MCB54241101934

Age /Sex : 52 Yrs FEMALE
 UMR No. : 542411000620

LABORATORY REPORT : CLINICAL PATHOLOGY

Parameters	Result	Reference Range	Units
CUE(COMPLETE URINE EXAMINATION)			
(Bill Date : 09-Nov-2024 11:27 AM Result ID : RMI241105772)			
<u>PHYSICAL EXAMINATION</u>			
VOLUME	30 ML		ml
COLOUR	Pale yellow	PALE YELLOW	
APPEARANCE	CLEAR	CLEAR	
<u>CHEMICAL EXAMINATION</u>			
DEPOSIT	ABSENT	ANSENT	
SPECIFIC GRAVITY <i>Bromthymol blue</i>	1.020	1.000 - 1.030	
PH <i>Bromthymol blue</i>	6.0	5.0 - 8.0	
PROTEIN <i>Tetra-bromophenol blue/Horser coagulation test</i>	NIL	NIL (<15 mg/dL)	
GLUCOSE <i>Glucose oxidase Peroxidase/Banadict[®] test</i>	NIL	NIL (<25 mg/dL)	
UROBILINOGEN <i>Diazotium salt</i>	NIL	NIL	
KETONE <i>Sodium nitroprusside/Reimer's test</i>	NIL	NIL (<5 mg/dL)	
BLOOD <i>Dipstick/Alcoacopy</i>	NIL	NEGATIVE	
BILIRUBIN <i>Dipstick/Fouchet's test</i>	NIL	NEGATIVE	
BILE SALT <i>Hay's sulphur powder</i>	NIL	NEGATIVE	
BILE PIGMENT <i>Fouchet test</i>	NIL	NEGATIVE	





MEDICOVER

Name	: Mrs. SHALAKA MHATRE	Age /Sex	: 32 Yrs / FEMALE
Bill No.	: MCB54241101934	UMR No.	: 542411000620

NAVI MUMBAI

NITRITE <i>Sulfanilic acid</i>	NIL	NEGATIVE	
LEUCOCYTE ESTERASE MICROSCOPIC EXAMINATION	NIL	NEGATIVE	
PUS CELLS	0-1	0 - 5 /hpf	
EPITHELIAL CELLS	1-2	0 - 5	hpf
RBC	NIL	0 - 5 /hpf	
CAST <i>Microscopy examination</i>	NIL	NIL	
CRYSTALS	NIL	NIL	
BACTERIA <i>Microscopic examination</i>	NIL		
YEAST <i>Microscopic examination</i>	NIL		
AMORPHOUS DEPOSITS <i>Microscopic examination</i>	NIL		
MUCUS THREAD <i>Microscopic examination</i>	NIL		

NOTE

Microscopic examination of urine is carried out on centrifuged urinary sediment.

Dr Neeta Shrivastava
MBBS, MD, DNB (Microbiology)





MEDICOVER

HOSPITALS

NAVI MUMBAI

Name	: Mrs. SHALAKA MHATRE	Age /Sex	: 33 Y (s) FEMALE
Bill No.	: MCB54241101934	UMR No.	: 542411000620

LABORATORY REPORT : HAEMATOLOGY

Parameters	Result	Reference Range	Units
CBP(COMPLETE BLOOD PICTURE)			
(Bill Date : 09-Nov-2024 11:27 AM Result ID : RMI241106768)			
R B C COUNT <i>Electrical impedance</i>	4.66	3.8-4.8	10 ¹² /L
HEMOGLOBIN <i>Photometric</i>	13.1	12.0 - 15.0	gms/dL
PCV/HCT <i>Calculated</i>	41.9	36 - 46	%
MCV <i>Calculated</i>	89.9	83 - 101	fL
MCH <i>Calculated</i>	28.0	27 - 32	pg
MCHC <i>Calculated</i>	31.2 *	31.5 - 34.5	g/dL
RDW(cv)	15.0 *	11.6 - 14.0 %	%
TLC (TOTAL LEUCOCYTE COUNT) <i>Impedance</i>	6.26	4.0 - 10.0	10 ³ /μl
DIFFERENTIAL COUNT			
NEUTROPHILS <i>DHSS/Microscopy</i>	60	40 - 80 %	
LYMPHOCYTES <i>DHSS/Microscopy</i>	33	20 - 40 %	
MONOCYTES <i>DHSS/Microscopy</i>	05	02 - 10 %	
EOSINOPHILS <i>DHSS/Microscopy</i>	02	00 - 06 %	
BASOPHILS <i>DHSS/Microscopy</i>	00	00 - 01 %	
PLATELET COUNT <i>Electrical impedance</i>	221	150 - 400	10 ³ /μL





MEDICOVER

Name : Mrs. SHALAKA MHATRE
Bill No. : MCB54241101934

Age /Sex : 62Y Y (S) F
UMR No. : 542411000620

HOSPITALS

NAVI MUMBAI

ESR

(Bill Date : 09-Nov-2024 11:27 AM Result ID : RMI241106770)

ESR 04 0 - 20 mm/1st hour
MODIFIED WESTERGRÉN'S METHOD


DR. MEHROTRA VISHAL
MD Pathology





Patient ID:	542411000620	Patient Name:	SHALAKA MHATRE
Age:	32YRS	Sex:	F
Accession Number:		Modality:	US
Referring Physician:	DMO	Study:	USG ABDOMEN PELVIS
Study Date:	09-Nov-2024		

ULTRASOUND EXAMINATION OF ABDOMEN & PELVIS

The Liver is normal in size and shows a normal parenchymal reflectivity. No focal lesion is seen. The Hepatic veins appear normal. There is no evidence of any dilated IHBR. The portal vein appears normal.

The gall bladder is partially distended. C.B.D. is of normal caliber.

The Pancreas is normal in size and shows homogeneous reflectivity. There is no evidence of any calcification or ductal dilatation.

The spleen is normal in size and shows a homogeneous echotexture. There is no evidence of any focal lesion.

Both kidneys are normal in position and size. They show normal cortical reflectivity and cortico-medullary distinction.

The Right Kidney measures 9.6 x 3.5 cm.

The Left Kidney measures 9.3 x 4.8 cm.

There is no evidence of renal calculi, hydronephrosis, or mass noted.

There is no evidence of ascites or para aortic lymphadenopathy.

The Urinary bladder is adequately distended and shows normal wall thickness. No evidence of any intraluminal mass or calculi.

The uterus is Anteverted. It measures 6.4 x 2.9 x 4 cm.

The uterine myometrial echotexture is homogeneous. No focal lesion is seen.

The Endometrial thickness is 7 mm.

Both ovaries are well visualized and appear normal in size and reflectivity.

The Right ovary measures 2.6 x 2.5 cm.

The Left ovary measures 2.1 x 1.7 cm.

There is no evidence of any ovarian or adnexal mass lesion.

No evidence of any fluid collection in the pelvis.



MEDICOVER
HOSPITALS

Patient ID:	542411000620	Patient Name:	SHALAKA MHATRE
Age:	32YRS	Sex:	F
Accession Number:		Modality:	US
Referring Physician:	DMO	Study:	USG ABDOMEN PELVIS
Study Date:	09-Nov-2024		

IMPRESSION:

No significant abnormality is seen.

Y. Shah

Dr. Yogini Hetal Shah
MBBS, DNB, DMRD

Date: 09-Nov-2024 16:15:52

Patient ID:	542411000620	Patient Name:	SHALAKA MHATRE
Age:	32 Years	Sex:	M
Accession Number:		Modality:	DX
Referring Physician:		Study:	CHEST
Study Date:	09-Nov-2024	Study Time:	13:24:30

X RAY CHEST PA VIEW

Both lungs are clear.

The frontal cardiac dimensions are normal,

ie pleural spaces are clear.

Both hilar shadows are normal in position and density.

No diaphragmatic abnormality is seen.

The soft tissues and bony thorax are normal.

Impression:

No significant abnormality is seen.



DR. ANUPKUMAR AGRAWAL
Consultant & HOD Radiology
MBBS, MD

Date: 09-Nov-2024 13:39:17

Rate 62 . Sinus rhythm.....normal P axis, V-rate 50- 99
 . Borderline short PR interval.....PR int <120ms
 PR 113 . RSR' in V1 or V2, probably normal variant.....small R' only
 QRSD 86 . Baseline wander in lead(s) I,III,aVL
 QT 405
 QTc 412

WNL
FA

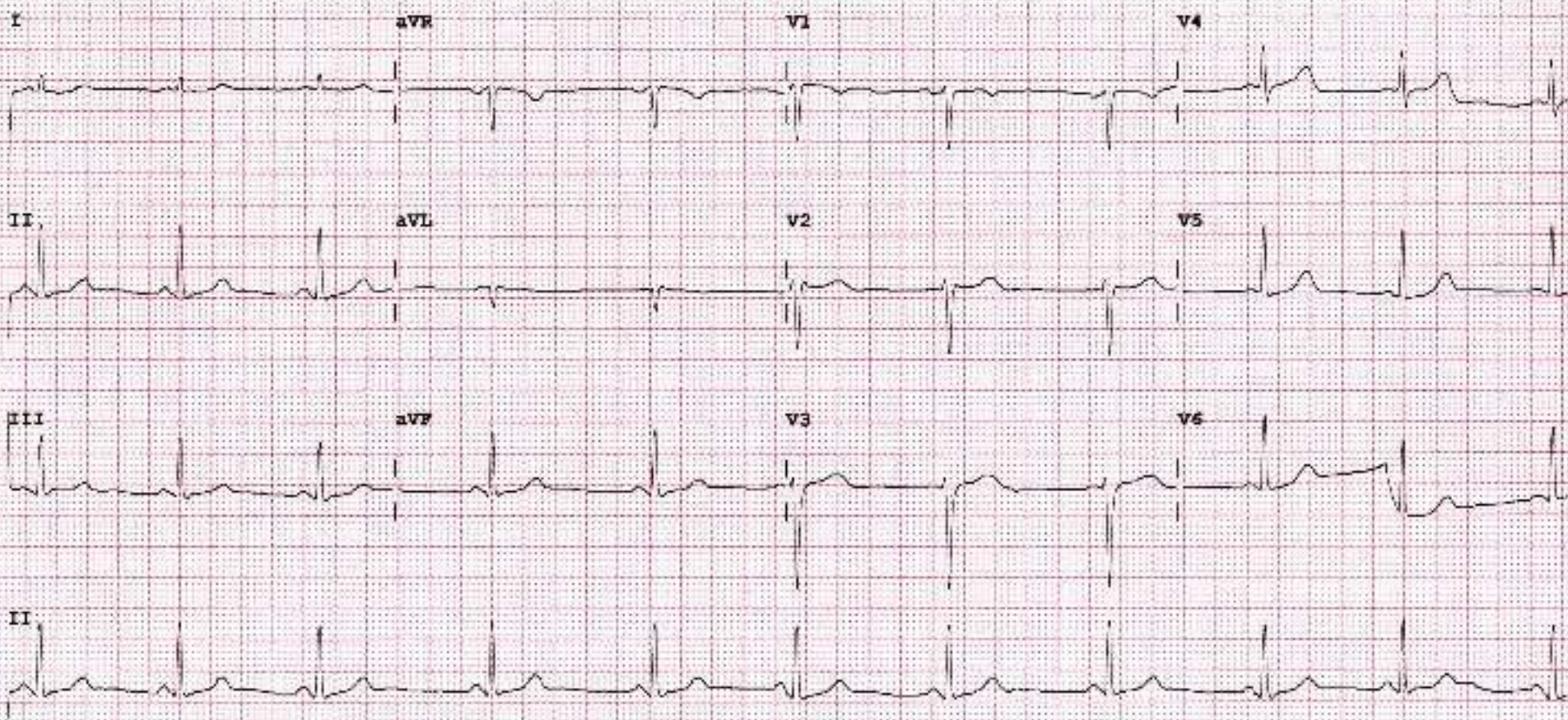
--AXIS--

P 68
 QRS 77
 T 67

- OTHERWISE NORMAL ECG -

12 Lead; Standard Placement

Unconfirmed Diagnosis





MEDICOVER
HOSPITALS

NAVI MUMBAI

2D ECHO CARDIOGRAPHY WITH COLOR DOPPLER

<i>Name</i>	: Mrs. Shalaka Mhatre	<i>Date:-</i> 09/11/2024
<i>Age / Sex</i>	: 32 Yrs / Female	UMR No. 00620
<i>Referred By</i>	: Health check up	

FINDINGS:

- No left ventricle regional wall motion abnormality.
- Normal left ventricle systolic function. LVEF = 60%.
- No left ventricle diastolic dysfunction.
- Trivial mitral regurgitation.
- No aortic regurgitation. No aortic stenosis.
- Trivial tricuspid regurgitation. No pulmonary hypertension.
PASP = 24 mm Hg.
- No left ventricle clot / vegetation / pericardial effusion.
- Intact IAS and IVS.
- Normal left atrium and left ventricle dimensions.
- Normal right atrium and right ventricle dimensions.
- Normal right ventricle systolic function. No hepatic congestion.

IMP:

- No RWMA.
- Trivial MR and TR. No PH.
- Normal LV and RV systolic function.

DR. KESHAV KALE
DNB (Cardiology), MD (Medicine), MBBS
PhD (Cardiology), MNAMS, LL.B (Law)
FSCAI (USA), AFACC (USA), FESC (EU)
Consultant & Interventional Cardiologist





MEDICOVER
HOSPITALS

NAVI MUMBAI

M-MODE MEASUREMENTS:

LA	34	mm
AO root	29	mm
AO CUSP SEP	18	mm
LVID(s)	32	mm
LVID(d)	41	mm
IVS(d)	10	mm
LVPW(d)	10	mm
RVID(d)	29	mm
RA	31	mm
LVEF	60	%

	PEAK	MEAN	Vmax	Gradient of Regurgitation
MITRAL	N			Trivial
AORTIC	7			Nil
TRICUSPID	N			Trivial
PULMONERY	4.1			Nil



MEDICAL HEALTH CHECK- UP ASSESMENT FORM

NAME : Mr / (Mrs) Shalaka . Mhaskar .

DATE: 09/11/24.

AGE : 32 YRS / F

SEX: Male / (Female)

NMU: NMU000 542411000620

DOCTOR'S NAME:

TEMP :	97.7	° f	BP :	100/60	mmHg
PULSE :	70	b/m	HEIGHT :	158	cm
RR :	20	b/m	WEIGHT :	48.9	kg
SPO2 :	98	%	HGT:	—	

REMARK:




**MEDICOVER
HOSPITALS**

NAVI MUMBAI

Mrs. Malaka Mhatre, F, 32yrs.

c/o Routine check up -

O/E - ST, CaT

= partially impacted 

Adm,

- Scoring & polishing

- X^u 

Dr. Binola Singh





MEDICOVER HOSPITALS

DEPARTMENT OF OPHTHALMOLOGY

NAVI MUMBAI

DATE: 09/11/24

PATIENT NAME: Mrs Shalaka Mahabre

AGE/SEX 32/F

UMR NO: S2241000620

	RE	LE
VA (DISTANCE) <u>20/100</u>	6/6	6/6
VA (NEAR) <u>20/30</u>	Nc	Nc
COLOUR VISION	Normal	Normal

			SPHERE	CYLINDER	AXIS	VA
MRx	O R	D	-2.00	—		6/6, Nc
	O L	S	-2.25	—		6/6, Nc

HISTORY :

- NO H/O DM, HTN, Hypo
- NO H/O Ocular discharge, CBV
- NO H/O spectacle correction

OCULAR FINDINGS :

(BE) - Ant seg WNL

Disc (BE) - 0.3

ADVICE:

Refresh Tears eod qid 17 77 X 1 month

AS
(DR. ANUSHREE VANKAR)

