

Name : Mr. KUMAR RAJESH (49 /M)

Date : 28/09/2024

Address : SARUMOTARIYA, GUWAHATI, KAMRUP(M), ASSAM, INDIA

Examined by: Dr .PRABIN KUMAR SAIKIA

UHID : AHLG2.0000044935

Package : MediWheel Full Body Health Check up-Male Above 40Yrs

AHC No : APHCAH28337



## CHIEF COMPLAINTS

MediWheel Full Body Health Check up-Male Above 40Yrs

## PRESENT KNOWN ILLNESS

Diabetes mellitus - type 2; Since - 2; YRS;  
Medication - stopped without medical advice

Hypertension Since - 15; YRS;  
Medication - stopped with medical advice



## DRUG ALLERGY

NO KNOWN ALLERGY :28/09/2024



## SYSTEMIC REVIEW

### Cardiovascular system

- Nil Significant

### Respiratory system

- Nil Significant

### Oral and dental

- Adv: Scaling and polishing. Extraction

### Gastrointestinal system

Appetite - normal; Abdominal pain - no; Dyspepsia - no; Peptic ulcer - no; Bowel habits - regular; Piles - no

### Genitourinary system

- Nil Significant

### Central nervous system

Dizziness - no; Concentration - good; Sleep - good

### Musculoskeletal system

Spine and joints  
Shoulder (right) - pain

### Weight

- stable



## Surgical history

Hydrocelectomy right - 1993

## Immunization history

- Covid Dose2



## Personal history

Marital status - Married  
No. of children - 1  
Male - 1  
Diet - Vegetarian  
Alcohol - does not consume alcohol  
Smoking - No  
Chews tobacco - No  
Physical activity - Mild



## Family history

Father - has expired  
Aged - 65 YRS  
Cause - renal disease  
Mother - alive  
Aged - 65 YRS  
Brothers - 2  
Sisters - 1  
Coronary artery disease - none  
Cancer - None

## PHYSICAL EXAMINATION



### General

Height - 173  
Weight - 69  
BMI - 23.05  
Waist circumference - 95  
Hip - 92  
Waist/ Hip ratio - 1.03  
Pallor - No  
Oedema - no

Name : Mr. KUMAR RAJESH (49 /M)

UHID : AHLG2.0000044935

Date : 28/09/2024

Package : MediWheel Full Body Health Check up-Male Above 40Yrs

AHC No : APHCAH28337

SpO2 - 100% RA

## Head and ENT

Nose - Deviation of septum to right  
Others - Nose: Bilateral HIT+

## Cardiovascular system

Heart rate (Per minute) - 70  
Rhythm - Regular  
- B.P. Sitting  
Systolic(mm of Hg) - 120  
Diastolic(mm of Hg) - 90  
Heart sounds - S1S2+

## Respiratory system

Rate of respiration(per minute) - 20  
Breath sounds - Normal vesicular breath sounds

## Abdomen

Organomegaly - No  
Tenderness - No

## Eyes

Eye vision - Normal  
Eye vision - BCVA. BE 6/6. N6  
Pupil - Normal  
Intraocular pressure - 12 mmHg (R), 15 mmHg (L)  
Advice for spectacle - Yes  
- Adv: Fundus

Printed By : HEALTH CHECK REPORT

Name : Mr. KUMAR RAJESH (49 /M)

UHID : AHLG2.0000044935

Date : 28/09/2024

Package : MediWheel Full Body Health Check up-Male Above 40Yrs

AHC No : APHCAH28337

## Executive Summary



1. Type 2 Diabetes mellitus (FBS 200 mg/dL, PPBS 330 mg/dL, HbA1c 10.0%)
2. Fatty liver Grade I
3. Gall bladder Sludge
4. Right Renal Calculi (6 mm) cortical cysts (largest 20 x 15 mm)
5. Dyslipidemia (Ch 210 mg/dL, LDL 144 mg/dL, Tg 191 mg/dL)

## Wellness Prescription

### Advice On Diet :-



Dietician consultation

### Advice On Physical Activity :-



Regular exercise

## Medications

- |                            |  |
|----------------------------|--|
| 1. TAB ISTAMET DXR 1000 MG | 1 tab once daily before breakfast x continue |
| 2. CAP DV 60K              | 1 cap once monthly x continue                |
| 3. TAB ROSUVAS 10 MG       | 1 tab once daily at bedtime x continue       |

## Follow-up and Review Plan



Review check after 3 months with FBS, PPBS, HbA1c.



Scan the QR code in AskApollo App to book your follow-up appointments and investigations

Dr. PRABIN KUMAR SAIKIA

AHC Physician / Consultant Internal Medicine

Printed By : HEALTH CHECK REPORT

Note :- The Health Check-up examinations and routine investigations have certain limitations and may not be able to detect all the diseases. Any new or persisting symptoms should be brought to the attention of the Consulting Physician. Additional tests, consultations and follow up may be required in some cases.

Dr. Prabin Kumar Saikia  
MD (Gen Medicine), FCGP, FICP, PGDHHM  
Registration No.-7523, Assam  
Consultant Physician, APHC  
Apollo Hospital Guwahati-781005

Name : Mr. KUMAR RAJESH (49 /M)

UHID : AHLG2.0000044935


Date : 28/09/2024

Package : MediWheel Full Body Health Check up-Male Above 40Yrs

AHC No : APHCAH28337

## Medications

- |                            |  |
|----------------------------|--|
| 1. TAB ISTAMET DXR 1000 MG | 1 tab once daily before breakfast x continue |
| 2. CAP DV 60K              | 1 cap once monthly x continue                |
| 3. TAB ROSUVAS 10 MG       | 1 tab once daily at bedtime x continue       |



Dr. PRABIN KUMAR SAIKIA

AHC Physician / Consultant Internal Medicine

Dr. Prabin Kumar Saikia  
MD (Gen Medicine), FCGP, FICP, PGDHHM  
Registration No.-7523, Assam  
Consultant Physician, APHC  
Apollo Hospitals Guwahati-781005

DEPARTMENT OF BIOCHEMISTRY

Name : Mr. KUMAR RAJESH Age : 49Yr 8Mth 13Days Gender : Male  
 UHID : AHLG2.0000044935 / APHCAH28337 W/BNo/RefNo : AHC  
 SIN \ LRN : 125490814 \ 125490815 \ 125490818 \ 125490819 \ 11105638  
 Specimen : Serum  
 Ref Doctor : Dr. Prabin Kumar Saikia



Collected on : 28-SEP-2024 11:14:31 AM Received on : 28-SEP-2024 12:18:58 PM Reported on : 28-SEP-2024 03:16:19 PM

MediWheel Full Body Health Check up-Male Above 40Yrs

TEST NAME	RESULT	BIOLOGICAL REFERENCE INTERVALS	UNITS
TOTAL T3: TRI IODOTHYRONINE - SERUM (Eclia)	1.1 *	Healthy Adults Euthyroid: 1.2-3.1	nmol/L
TOTAL T4: THYROXINE - SERUM (Eclia)	79	Healthy Adults Euthyroid: 66-181	nmol/L
TSH: THYROID STIMULATING HORMONE - SERUM (Eclia)	3.02	Healthy Adults Euthyroid:0.270 - 4.20	uIU/mL
PROSTATIC SPECIFIC ANTIGEN (PSA TOTAL) (Eclia)	1.06	Healthy Men: <=2.0	ng/mL
GLUCOSE - PLASMA (POST PRANDIAL) Hexokinase	330 *	Normal: <140 Pre-Diabetic: 140-199 Diabetic :->=200	mg/dL
VLDL CHOLESTEROL - SERUM CALCULATED.	38 *	Desirable:<30	
AST (SGOT) - SERUM (UV With P5P-IFCC)	20	Healthy Adults:15 - 37	U/L
ALT(SGPT) - SERUM (UV With P5P-IFCC)	29	Healthy Males:-16-63 U/L	U/L
PROTEIN, TOTAL - SERUM (Biuret)	8.2	Healthy Adults:6.4-8.3	mg/dl

DEPARTMENT OF BIOCHEMISTRY

Name : Mr. KUMAR RAJESH Age : 49Yr 8Mth 13Days Gender : Male  
 UHID : AHLG2.0000044935 / APHCAH28337 W/BNo/RefNo : AHC  
 SIN \ LRN : 125490814 \ 125490815 \ 125490818 \ 125490819 \ 11105638  
 Specimen : Serum  
 Ref Doctor : Dr. Prabin Kumar Saikia



Collected on : 28-SEP-2024 11:14:31 AM Received on : 28-SEP-2024 12:18:58 PM Reported on : 28-SEP-2024 03:16:19 PM

URIC ACID - SERUM (Modified Uricase)	6.0	Healthy Men: 3.5 - 7.2	mg/dL
ALKALINE PHOSPHATASE - SERUM PNPP,AMP Buffer-IFCC	110	Healthy Adults:40-150	U/L
GGTP: GAMMA GLUTAMYL TRANSPEPTIDASE - SERUM (L-gamma-glutamyl-3-carboxy-4-nitranilide)	37	Healthy Men:15 - 85	U/L
BILIRUBIN, TOTAL - SERUM (Modified Doumas Ref. method/Jendrassik & Grof.)	2.2 *	Healthy Adults:<=1.0	mg/dL
BILIRUBIN CONJUGATED (DIRECT) - SERUM (Jendrassik & Grof)	0.3	Healthy Adults:0.0-0.5	mg/dL
CREATININE - SERUM JAFTE METHOD	0.9	Healthy Men: 0.72 - 1.25	mg/dL
ALBUMIN - SERUM (Brom Cresol Green)	4.4	Healthy Adults-3.5-5.2	g/dL
GLOBULIN-SERUM(Calculated)	3.8 *	Healthy Adults :1.8 - 3.6	
ALBUMIN:GLOBULIN-SERUM(RATIO)(Calculated)	1 *	0 - 0	
HDL CHOLESTEROL - SERUM / PLASMA (Direct Measurement)	42	Low: <40 High: >=60	mg/dL
TOTAL CHOLESTEROL/HDL CHOLESTEROL RATIO(Calculated)	5.0 *	Desirable :< 4.5	

DEPARTMENT OF BIOCHEMISTRY

Name : Mr. KUMAR RAJESH Age : 49Yr 8Mth 13Days Gender : Male  
 UHID : AHLG2.0000044935 / APHCAH28337 W/BNo/RefNo : AHC  
 SIN \ LRN : 125490814 \ 125490815 \ 125490818 \ 125490819 \ 11105638  
 Specimen : Serum  
 Ref Doctor : Dr. Prabin Kumar Saikia



Collected on : 28-SEP-2024 11:14:31 AM Received on : 28-SEP-2024 12:18:58 PM Reported on : 28-SEP-2024 03:16:19 PM

LDL CHOLESTEROL - SERUM(DIRECT LDL) (Homogenous Method)	144 *	Optimal:<100 Near Optimal:100-129 Borderline High:130-159 High:160-189 Very High:>=190	mg/dL
CHOLESTEROL - SERUM (Cholesterol Oxidase)	210 *	Desirable:<200 Borderline:200 - 240 High Risk:>=240	mg/dL
TRIGLYCERIDES - SERUM (Glycerol Phosphate Oxidase)	191 *	Normal : <150 Borderline High :150-199 High : 200-499 Very High : >=500	mg/dL
UREA - SERUM (Enzymatic,Urease-GLDH) (Urease)	22	<50 years:19-44	mg/dL
GLUCOSE -PLASMA (FASTING) Hexokinase	200 *	Non-Diabetic: <=100 Pre-Diabetic: 100-125 Diabetic: >=126	mg/dL

TOUCHING LIVES



DEPARTMENT OF BIOCHEMISTRY

Name : Mr. KUMAR RAJESH Age : 49Yr 8Mth 13Days Gender : Male  
UHID : AHLG2.0000044935 / APHCAH28337 W/BNo/RefNo : AHC  
SIN \ LRN : 125490814 \ 125490815 \ 125490818 \ 125490819 \ 11105638  
Specimen : Serum  
Ref Doctor : Dr. Prabin Kumar Saikia



Collected on : 28-SEP-2024 11:14:31 AM Received on : 28-SEP-2024 12:18:58 PM Reported on : 28-SEP-2024 03:16:19 PM

Report Status:Final

\* END OF REPORT \*



CHECKED BY 1078452  
1078550

Printed On : 29-SEP-2024 11:58:23 AM

*M. Saikia*  
Dr. MOUSHUMI SAIKIA,  
MBBS,MD  
REG NO.14979 AMC  
CONSULTANT BIOCHEMIST

- DR. T. SARMA, DCP    DR. P. GOSWAMI, MD    DR. M. SAIKIA, MD(BIOCHEMISTRY)    DR. A. VERMA, DCP    DR. M. BARMAN, MD  
DR. D.J. LAHON, MD (MICRO)    DR. M. SARMA, MD (MICRO)    DR. POOJA KESHAN, MD (PATHO)    DR. N. MAHANTA, MD (PATHO)

\* The results relate to sample tested only. Partial reproduction of reports is prohibited.





MC-3480

DEPARTMENT OF BIOCHEMISTRY

Name : Mr. KUMAR RAJESH Age : 49Yr 8Mth 13Days Gender : Male  
 UHID : AHLG2.0000044935 / APHCAH28337 W/BN/RefNo : AHC  
 SIN \ LRN : 125490816 \ 11105638  
 Specimen : Whole blood  
 Ref Doctor : Dr. Prabin Kumar Saikia



Collected on : 28-SEP-2024 11:14:31 AM Received on : 28-SEP-2024 12:21:39 PM Reported on : 28-SEP-2024 01:47:01 PM

MediWheel Full Body Health Check up-Male Above 40Yrs

TEST NAME	RESULT	BIOLOGICAL REFERENCE INTERVALS	UNITS
GLYCOSYLATED HEMOGLOBIN (HBA1C) - WHOLE BLOOD	10.0 *	GOAL:<6.5% Prediabetic:5.7-6.4%	%
GLYCOSYLATED HEMOGLOBIN (HbA1C) - WHOLE BLOOD		Diabetic:>6.5% Non-diabetic:<5.7%	
		Uncontrolled-diabetics>8%	
Mean Plasma Glucose (MPG) Estimate:	240.3000		mg/dL

Report Status:Final

\* END OF REPORT \*

CHECKED BY 1078450  
155038

*Pooja Keshan*

Printed On : 29-SEP-2024 11:58:36 AM

Dr.Pooja Keshan MBBS,MD  
Reg No 21460 AMC

Page 1 of 1  
CONSULTANTS

- DR. T. SARMA, DCP    DR. P. GOSWAMI, MD    DR. M. SAIKIA, MD(BIOCHEMISTRY)    DR. A. VERMA, DCP    DR. M. BARMAN, MD  
 DR. D.J. LAHON, MD (MICRO)    DR. M. SARMA, MD (MICRO)    DR. POOJA KESHAN, MD (PATHO)    DR. N. MAHANTA, MD (PATHO)

\* The results relate to sample tested only. Partial reproduction of reports is prohibited.

Name : Mr. KUMAR RAJESH  
 Age : 49Yr 8Mth 13Days Gender : Male  
 UHID : AHLG2.0000044935 / APHCAH28337 W/BN/RefNo : AHC  
 SIN ILRN : 125490813 \ 125490812 \ 11105638  
 Specimen : Urine  
 Ref Doctor : Dr. Prabin Kumar Saikia



Collected on : 28-SEP-2024 11:14:31 AM Received on : 28-SEP-2024 01:37:13 PM Reported on : 28-SEP-2024 01:43:07 PM

MediWheel Full Body Health Check up-Male Above 40Yrs

TEST NAME	RESULT	BIOLOGICAL REFERENCE INTERVALS	UNITS
<b>HEMOGRAM(CBC+ESR+RECTIC+PS)</b>			
Hemoglobin	15.5	13.0 - 18.0	g/dl
RBC COUNT	5.10	4.5 - 5.5	Million/ul
MCV	92.7 *	82.0 - 92.0	fl
MCH	30.4	26.0 - 32.0	pg
MCHC	32.8	31.0 - 36.0	g/dl
RDW-CV	13.6	11.6 - 14	%
RETICULOCYTE COUNT	3.22 *	Healthy Adult -:0.5-2.5%	%
Platelet Count	137 *	150 - 400	10 <sup>3</sup> /mm <sup>3</sup>
TLC/WBC Count	5.30	4.0 - 11.0	10 <sup>3</sup> /mm <sup>3</sup>
ERYTHROCYTE SEDIMENTATION RATE (ESR)	18 *	0 - 10	mm/1st hr
<b>Differential Count</b>			
Neutrophils	73.3	45 - 75	%
Lymphocytes	18.5 *	20 - 40	%
Eosinophils	3.6	1 - 6	%
Monocytes	4.0	2 - 10	%
Basophils	0.6	0 - 2	%
<b>PERIPHERAL SMEAR</b>			
RBC:	Normocytic & normochromic		
WBC:	Total and Differential counts are within normal limits		
Platelets:	Adequate on the smear		
Hemoparasites	No hemoparasites		
PACKED CELL VOLUME (PCV)	47.3	40 - 50	%

Page 02 of 02 **CONSULTANTS**

DR. T. SARMA, DCP    DR. P. GOSWAMI, MD    DR. M. SAIKIA, MD(BIOCHEMISTRY)    DR. A. VERMA, DCP    DR. M. BARMAN, MD  
 DR. D.J. LAHON, MD (MICRO)    DR. M. SARMA, MD (MICRO)    DR. POOJA KESHAN, MD (PATHO)    DR. N. MAHANTA, MD (PATHO)

\* The results relate to sample tested only. Partial reproduction of reports is prohibited.

Name : Mr. KUMAR RAJESH Age : 49Yr 8Mth 13Days Gender : Male  
 UHID : AHLG2.0000044935 / APHCAH28337 W/BN/RefNo : AHC  
 SIN \LRN : 125490813 \ 125490812 \ 11105638  
 Specimen : Urine  
 Ref Doctor : Dr. Prabin Kumar Saikia



Collected on : 28-SEP-2024 11:14:31 AM Received on : 28-SEP-2024 01:37:13 PM Reported on : 28-SEP-2024 01:43:07 PM

URINE- BENICE JONES PROTEINS	Negative	Negative
URINE SUGAR	Trace	
URINE ROUTINE (CUE)		
Color:	Pale yellow	Pale Yellow/amber
Transparency:	Clear	Clear
Specific Gravity(Strip Method)	1.015 *	1.016 - 1.026
pH(Strip Method+ Ph Paper)	6.0	4.6 - 8
Glucose:(Benedicts+Strip Method)	Trace	Negative
Protein :(Strip+Heat Method)	Nil	Negative
DEPOSITS:(Microscopy)		
RBC	Not seen	Upto 3 Cells/hpf
WBC/Pus Cells	1-2 /HPF	Upto to 5 Cells/hpf
Squamous epithelial cells	0-1 /HPF	Up to 20
Casts:(Microscopy)	Not Detected	Absent /lpf
Crystals:	Not Detected	Absent /lpf
Nitrite	Negative	Negative
Report Status:Final		

\* END OF REPORT \*

TOUCHING LIVES

CHECKED BY : 1078444

Printed On : 29-SEP-2024 11:59:04 AM

DR. TRIDIB SARMA, D.C.P  
CONSULTANT PATHOLOGIST

CONSULTANTS

DR. T. SARMA, DCP    DR. P. GOSWAMI, MD    DR. M. SAIKIA, MD(BIOCHEMISTRY)    DR. A. VERMA, DCP    DR. M. BARMAN, MD  
 DR. D.J. LAHON, MD (MICRO)    DR. M. SARMA, MD (MICRO)    DR. POOJA KESHAN, MD (PATHO)    DR. N. MAHANTA, MD (PATHO)

\* The results relate to sample tested only. Partial reproduction of reports is prohibited.

Name : Mr. KUMAR RAJESH      Age : 49Yr 8Mth 13Days      Gender : Male  
 ID : AHLG2.0000044935 / APHCAH28337      W/BNo/RefNo : AHC  
 SIN \LRN : 125490817 \ 11105638  
 Specimen : Blood  
 Ref Doctor : Dr. Prabin Kumar Saikia



Collected on : 28-SEP-2024 11:14:31 AM    Received on : 28-SEP-2024 11:36:15 AM    Reported on : 28-SEP-2024 12:18:30 PM


**TEST NAME**

**RESULT**

**BLOOD GROUPING AND TYPING**


ABO Group: O  
 Rh (D) Type: POSITIVE  
 Report Status:Final

\* END OF REPORT \*



CHECKED BY : 1078548

Printed On : 28-SEP-2024 12:19:31 PM

  
**CONSULTANTS**

DR. DEEPA BHUYAN  
MOIC, BLOOD BANK

\* The results relate to sample tested only.Partial reproduction of reports is prohibited.

**DEPARTMENT OF RADIOLOGY & IMAGING**

Division of Computerised Radiography & IITV, DEXA, Computed Tomography & MRI

Patient ID:	AHLG2.0000044935	Patient Name:	KUMAR RAJESH
Age:	49 Years	Sex:	M
Accession Number:	17002.124256207	Modality:	DX
Study Date:	28-Sep-2024	Study:	X-RAY CHEST PA
Referring Physician:	Prabin Kumar Saikia		

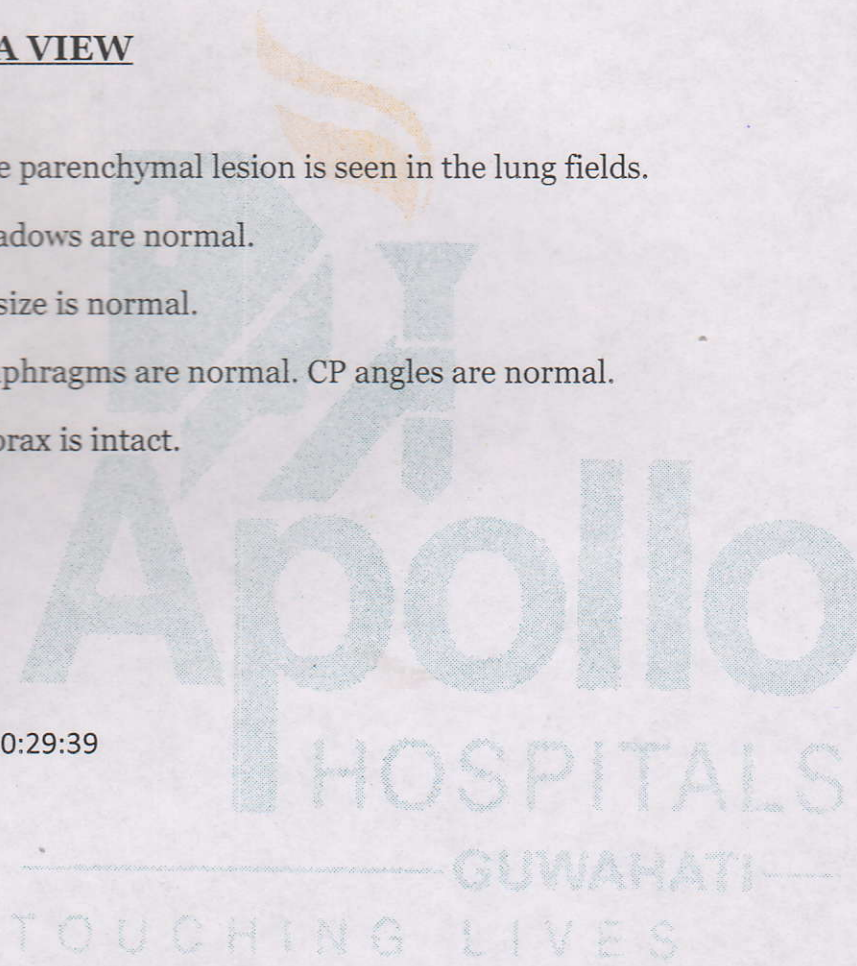
**CHEST PA VIEW**

- No active parenchymal lesion is seen in the lung fields.
- Hilar shadows are normal.
- Cardiac size is normal.
- Hemidiaphragms are normal. CP angles are normal.
- Bony thorax is intact.

*Meghali*

Dr. Meghali Gohain, MD  
Consultant Radiology

Date: 30-Sep-2024 10:29:39



Patient ID:	0000044935	Patient Name:	KUMAR RAJESH
Age:	49	Sex:	M
Accession Number:		Modality:	US
Referring Physician:	DR P KR SAIKIA	Study:	W/A
Study Date:	28-Sep-2024		

**USG OF WHOLE ABDOMEN**

**LIVER**

The liver is normal in size with increased parenchymal echotexture. No focal lesion is seen. The intrahepatic portal and hepatic venous system are normal. The intrahepatic bile ducts are not dilated.

**GALL BLADDER**

The gall bladder is normally distended and shows smooth contour. GB sludge noted. There is no obvious echoreflexive calculus in the gall-bladder. GB wall thickness is within normal limit.

**CBD**

The CBD is normal in course and calibre. No obvious luminal pathology in visualized portion.

**SPLEEN**

The spleen is normal in size and echotexture. No focal lesion is noted.

**PANCREAS**

The pancreas is normal in size and echotexture. No focal lesion is seen. Pancreatic duct is not dilated.

**KIDNEYS**

Right kidney normal in size, smaller compared to left. Both the kidneys are normal in shape, position and echotexture. Cortico-medullary differentiation is maintained. Few (up to 3) calculi noted in upper pole of right kidney largest measuring 6 mm. thin walled cortical cysts noted in upper and lower pole of right kidney, few with internal calcifications, largest measuring 20 x 15 mm in lower pole. Ureters are not dilated.

Right kidney measures – 80 x 39 mm

Left kidney measures – 104 x 55 mm

**URINARY BLADDER**

The urinary bladder is normal in capacity and contour. The wall is not thickened. No intraluminal calculus or mass is seen.

**PROSTATE**

The prostate gland is normal in size. It weighs about 13 gms.

**SEMINAL VESICLE**

Both the seminal vesicles appear normal.

No ascites is seen.

**Impression:**

- **Grade I hepatic steatosis.**
- **GB sludge.**
- **Right renal calculi.**
- **Right renal cortical cyst.**



**Dr. Sukanya Goswami**  
Consultant Radiologist, MD

Date: 28-Sep-2024 17:29:50

**Patient Details** : Mr. KUMAR RAJESH | Male | 49Yr 8Mth 13Days

**UHID** : AHLG2.0000044935

**Patient Location:** AHC

**Patient Identifier:** APHCAH28337



**DRN** : 100187715

**Completed on :** 28-SEP-2024 11:30

**Ref Doctor** : Dr. Prabin Kumar Saikia

**ECG**

**IMPRESSION .:**

ECG TRACING IS WITHIN NORMAL LIMITS

--- END OF THE REPORT ---

**Dr. Niranta Konwar**  
MBBS, PGDCC.  
Jr. Consultant Cardiologist  
Apollo Hospitals, Guwahati