

Name : Mr. Narasimha Murthy T N

Age: 58 Y

UHID:CJPN.0000072028

Address :blr

Sex: M



Plan : ARCOFEMI MEDIWHEEL MALE AHC CREDIT PAN
INDIA OP AGREEMENT

OP Number:CJPNOPV178762

Bill No :CJPN-OCR-66628

Date : 11.10.2023 08:21

Sno	Service Type/ServiceName	Department
1	ARCOFEMI - MEDIWHEEL - FULL BODY STANDARD PLUS MALE - PAN INDIA - FY2324	
1	GAMMA GLUTAMYL TRANSFERASE (GGT)	
2	HbA1c, GLYCATED HEMOGLOBIN	
3	LIVER FUNCTION TEST (LFT)	
4	X-RAY CHEST PA	
5	GLUCOSE, FASTING	
6	HEMOGRAM + PERIPHERAL SMEAR	
7	FITNESS BY GENERAL PHYSICIAN	
8	COMPLETE URINE EXAMINATION	
9	PERIPHERAL SMEAR	
10	ECG	
11	BLOOD GROUP ABO AND RH FACTOR	
12	LIPID PROFILE	
13	BODY MASS INDEX (BMI)	
14	OPHTHAL BY GENERAL PHYSICIAN	
15	RENAL PROFILE/RENAL FUNCTION TEST (RFT/KFT)	
16	THYROID PROFILE (TOTAL T3, TOTAL T4, TSH)	
17	GLUCOSE, POST PRANDIAL (PP), 2 HOURS (POST MEAL)	

Dental - 22

Audio - 21 -

6

Weight = 80.9 kg

Height = 166 cm

Waist = 101 cm

Hcp = 113 cm

BP = 163/90 mmHg

PR = 66 bpm

Mr. narasimha murthy
ID: cfpn/72028

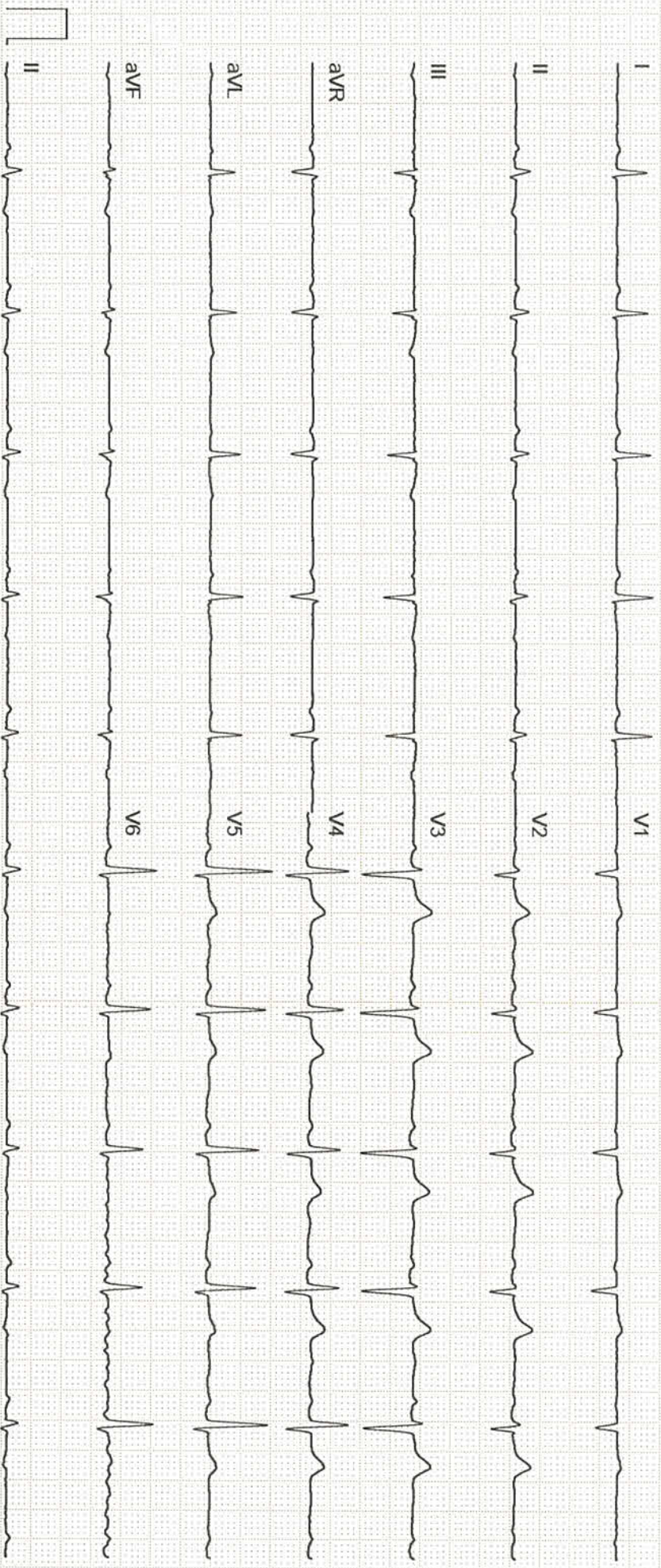
11.10.2023 10:50:27
Apollo Clinic
J.P. Nagar
Bangalore

65 bpm
163 / 90 mmHg

18 Years 166 cm Male
80.0 kg

QRS : 88 ms
QT / QTcBaz : 402 / 418 ms
PR : 170 ms
P : 110 ms
RR / PP : 930 / 923 ms
P / QRS / T : 21 / -15 / -39 degrees

Normal sinus rhythm
Nonspecific T wave abnormality
Abnormal ECG



GE MAC2000 1.1 12SL™ V241 25 mm/s 10 mm/mV ADS 0.56-20 Hz 50 Hz 2x5x6_25_R1

Unconfirmed

Patient Name : Mr. Narasimha Murthy T N
UHID : CJPN.0000072028
Reported on : 11-10-2023 10:05
Adm/Consult Doctor :

Age : 58 Y M
OP Visit No : CJPNOPV178762
Printed on : 11-10-2023 10:06
Ref Doctor : SELF

DEPARTMENT OF RADIOLOGY

X-RAY CHEST PA

Both lung fields and hila are normal .
No obvious active pleuro-parenchymal lesion seen .
Both costophrenic and cardiophrenic angles are clear .
Both diaphragms are normal in position and contour .
Thoracic wall and soft tissues appear normal.

CONCLUSION :

No obvious abnormality seen.

Printed on:11-10-2023 10:05

---End of the Report---


Dr. KUSUMA JAYARAM
MBBS,DMRD
Radiology

Name - Narasimha murthy TN
Age - 58 y/m

Date - 11/10/23

Height :	Weight :	BMI :	Waist Circum :
Temp :	Pulse :	Resp :	B.P :

General Examination / Allergies
History

C/O - Routine Eye

checkup

H/O PUP - using glass

H/O Eye St - No

Clinical Diagnosis & Management Plan

UNVH $\left\{ \begin{array}{l} 6/9 \quad N_{18} \\ 6/9 \quad N_{18} \end{array} \right.$

2 PUP UN $\left\{ \begin{array}{l} 6/6 \quad N_6 \\ 6/6 \quad N_6 \end{array} \right.$

Continue the same power

Follow up date:

After 6 months

Doctor Signature

Patient Name : Mr. Narasimha Murthy T N

Age/Gender : 58 Y/M

UHID/MR No. : CJPN.0000072028

OP Visit No : CJPNOPV178762

Sample Collected on :

Reported on : 11-10-2023 10:06

LRN# : RAD2122282

Specimen :

Ref Doctor : SELF

Emp/Auth/TPA ID : 919535046667

DEPARTMENT OF RADIOLOGY

X-RAY CHEST PA

Both lung fields and hila are normal .

No obvious active pleuro-parenchymal lesion seen .

Both costophrenic and cardiophrenic angles are clear .

Both diaphragms are normal in position and contour .

Thoracic wall and soft tissues appear normal.

CONCLUSION :

No obvious abnormality seen.

Dr. KUSUMA JAYARAM

MBBS,DMRD

Radiology