

**CERTIFICATE OF MEDICAL FITNESS**

This is to certify that I have conducted the clinical examination

of Gauran Kolhe on 26/08/2024

After reviewing the medical history and on clinical examination it has been found that he/she is

	Tick
<ul style="list-style-type: none"> <li>• Medically Fit</li> </ul>	<input checked="" type="checkbox"/>
<ul style="list-style-type: none"> <li>• Fit with restrictions/recommendations</li> </ul> <p>Though following restrictions have been revealed, in my opinion, these are not impediments to the job.</p> <p>1.....</p> <p>2.....</p> <p>3.....</p> <p>However the employee should follow the advice/medication that has been communicated to him/her.</p> <p>Review after _____</p>	
<ul style="list-style-type: none"> <li>• Currently Unfit.</li> </ul> <p>Review after _____ recommended</p>	
<ul style="list-style-type: none"> <li>• Unfit</li> </ul>	

APOLLO CLINIC - AUNDH  
Dr. PRIYANKA LADI  
MBBS  
Family Physician  
Reg. No: 271005008/2024

Dr. \_\_\_\_\_  
**Medical Officer**  
**Apollo Clinic, (Aundh, Pune)**

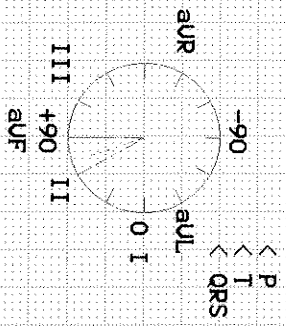
*This certificate is not meant for medico-legal purposes*

HR **49** bpm

*Sinus Brady cardia*

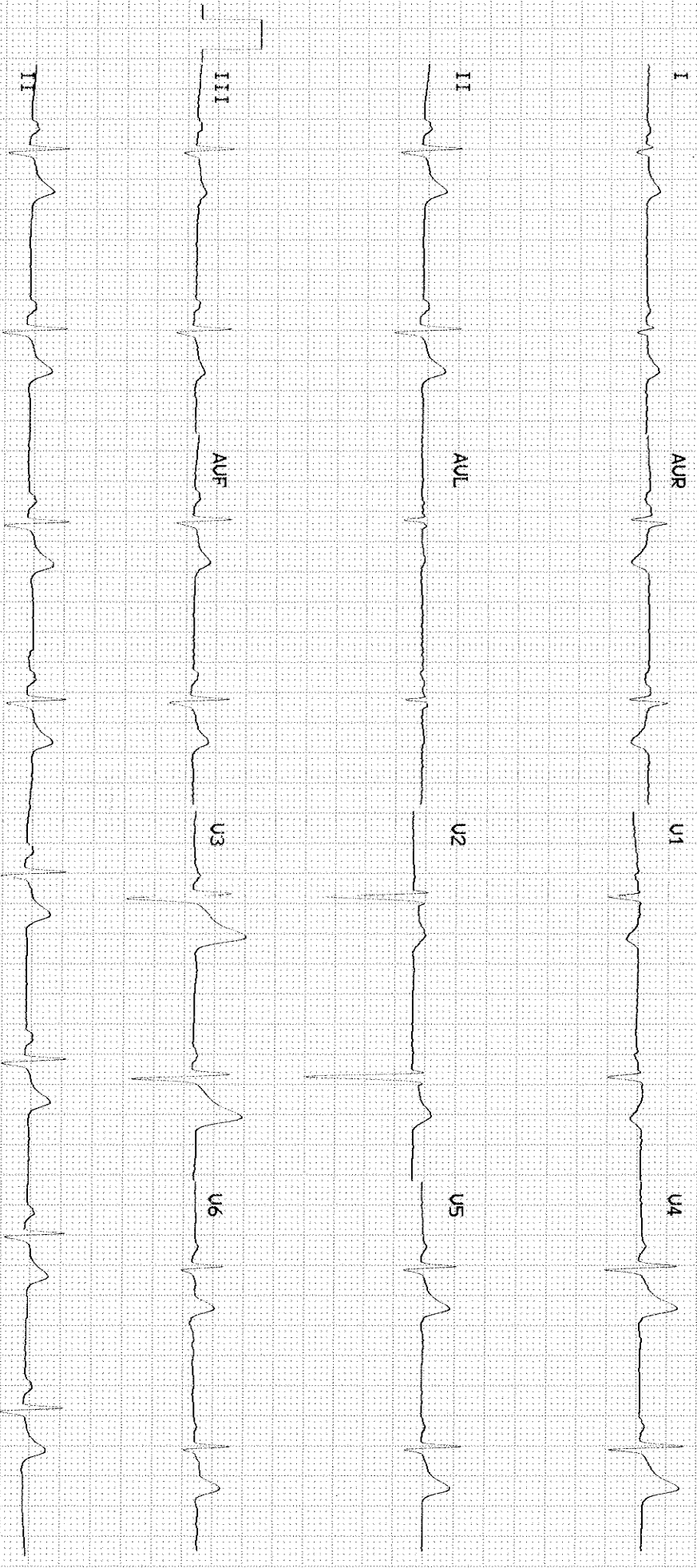
APOLLO CLINIC - AUINDH  
 Dr. PRIYANKA LADI  
 MBBS  
 Family Physician  
 Reg. No: 2019065008/2024

Measurement Results:  
 QRS : 106 ms  
 QT/QTcB : 420 / 382 ms  
 PR : 160 ms  
 P : 126 ms  
 RR/PP : 1208 / 1160 ms  
 P/QRS/T : 70° / 90° / 60 degrees  
 QTd/QTcBd : 42 / 38 ms  
 Sokolow : 1.1 mV  
 NK : 6



Interpretation:  
 RSR' pattern  
 sinus bradycardia  
 minor right axis deviation  
 probably normal ECG

Unconfirmed report.



Patient Name : Mr. Gaurav Kolhe  
UHID : CAUN.0000145297  
Reported on : 26-08-2024 14:41  
Adm/Consult Doctor :

Age : 25 Y M  
OP Visit No : CAUNOPV175967  
Printed on : 26-08-2024 14:41  
Ref Doctor : SELF

**DEPARTMENT OF RADIOLOGY**

**X-RAY CHEST PA**

No evidence of any focal lesion.

Trachea is central in position.

Costophrenic angles are clear.

Cardio thoracic ratio is normal.

Cardiac silhouette is well maintained.

Mediastinal and hilar regions are normal.

Both diaphragmatic domes are well visualized and normal.


Visualized skeleton and soft tissues around thoracic cage appear normal.

**COMMENT:** No significant abnormality seen.

Please correlate clinically.

Printed on:26-08-2024 14:41

---End of the Report---



**Dr. SUHAS SANJEEV KATHURIA**  
**MBBS,DMRE, RADIOLOGY**  
Radiology

Patient Name : MR. Ganesh Kolhe

Date : 26/08/24

AGE/Sex : 25/M

UHID/ MR NO :

	RIGHT EYE	LEFT EYE
FAR VISION	6/6	6/6
NEAR VISION	N6	N6
ANTERIOR SEGMENT PUPIL	No-Error	No-Error
COLOUR VISION	No-Error	No-Error
FAMILY / MEDICAL HISTORY	N/A	N/A

Impression: \_\_\_\_\_

\_\_\_\_\_

\_\_\_\_\_

Adv.: -

Optometrist: -  


Mr. Yogesh Avaghad

Apollo Clinic – Aundh Pune

**Apollo Health and Lifestyle Limited**

(CIN - U85110TG2000PLC115819)

Regd. Office: 1-10-60/62, Ashoka Raghupathi Chambers, 5th Floor, Begumpet, Hyderabad, Telangana - 500 016.

Ph.No: 040-4904 7777, Fax No: 4904 7744 | Email ID: enquiry@apollohl.com | www.apollohl.com

APOLLO CLINICS NETWORK MAHARASHTRA

Pune (Aundh | Kharadi | Nigdi Pradhikaran | Viman Nagar | Wanowrie)

Online appointments: www.apolloclinic.com

TO BOOK AN APPOINTMENT

 **1860 500 7788**

Date : 26-08-2024  
 MR NO : CAUN.0000145297  
 Name : Mr. Gaurav Kolhe  
 Age/ Gender : 25 Y / Male

Department : GENERAL  
 Doctor :  
 Registration No :  
 Qualification :

Consultation Timing: 09:09

HIPS-74

Height : 170	Weight : 50	BMI :	Waist Circum : 68
Temp :	Pulse : 74	Resp :	B.P : 120/70

**General Examination / Allergies History**

w/o Lt shoulder dislocation during football in 2021.

**Clinical Diagnosis & Management Plan**

**Present complains -** No current complaints  
**Comorbidity -** No w/o DM/HTN/TB/BA/epilepsy  
**Allergies -** None  
**Surgical H/O** None  
**Family H/O** Father - DM2  
**Addiction -** None

OE

CVS-  
 CNS-  
 P/A-  
 Chest-  
 } NAD.

Follow up date:



Doctor Signature