







Patient Name : Mrs.ARCHANA KUMARI	Collected : 09/Nov/2024 09:29AM
Age/Gender : 40 Y 4 M 21 D/F	Received : 09/Nov/2024 12:03PM
UHID/MR No : CKOR.0000184438	Reported : 09/Nov/2024 12:28PM
Visit ID : CKOROPV431220	Status : Final Report
Ref Doctor : Self	Sponsor Name : ARCOFEMI HEALTHCARE LIMITED
Emp/Auth/TPA ID : 22S37366	

**DEPARTMENT OF BIOCHEMISTRY**

**ARCOFEMI - MEDIWHEEL - FULL BODY ANNUAL PLUS CHECK ADVANCED - FEMALE - 2D ECHO - PAN INDIA - FY232**

Test Name	Result	Unit	Bio. Ref. Interval	Method
<b>GLUCOSE, FASTING , NAF PLASMA</b>	90	mg/dL	70-100	HEXOKINASE


**Comment:**

**As per American Diabetes Guidelines, 2023**

Fasting Glucose Values in mg/dL	Interpretation
70-100 mg/dL	Normal
100-125 mg/dL	Prediabetes
≥126 mg/dL	Diabetes
<70 mg/dL	Hypoglycemia

**Note:**

- The diagnosis of Diabetes requires a fasting plasma glucose of > or = 126 mg/dL and/or a random / 2 hr post glucose value of > or = 200 mg/dL on at least 2 occasions.
- Very high glucose levels (>450 mg/dL in adults) may result in Diabetic Ketoacidosis & is considered critical.

  
Dr Priya Murthy  
M.B.B.S.,M.D(Pathology)  
Consultant Pathologist





Patient Name : Mrs.ARCHANA KUMARI	Collected : 09/Nov/2024 12:45PM
Age/Gender : 40 Y 4 M 21 D/F	Received : 09/Nov/2024 05:29PM
UHID/MR No : CKOR.0000184438	Reported : 09/Nov/2024 06:26PM
Visit ID : CKOROPV431220	Status : Final Report
Ref Doctor : Self	Sponsor Name : ARCOFEMI HEALTHCARE LIMITED
Emp/Auth/TPA ID : 22S37366	

**DEPARTMENT OF BIOCHEMISTRY**

**ARCOFEMI - MEDIWHEEL - FULL BODY ANNUAL PLUS CHECK ADVANCED - FEMALE - 2D ECHO - PAN INDIA - FY232**

Test Name	Result	Unit	Bio. Ref. Interval	Method
<b>GLUCOSE, POST PRANDIAL (PP), 2 HOURS , SODIUM FLUORIDE PLASMA (2 HR)</b>	95	mg/dL	70-140	HEXOKINASE

**Comment:**

It is recommended that FBS and PPBS should be interpreted with respect to their Biological reference ranges and not with each other.  
 Conditions which may lead to lower postprandial glucose levels as compared to fasting glucose levels may be due to reactive hypoglycemia, dietary meal content, duration or timing of sampling after food digestion and absorption, medications such as insulin preparations, sulfonylureas, amylin analogues, or conditions such as overproduction of insulin.

**Dr.Govinda Raju N L**  
 MSc,PhD(Biochemistry)  
 Consultant Biochemistry

**Dr Priya Murthy**  
 M.B.B.S,M.D(Pathology)  
 Consultant Pathologist



SIN No:KOR241100593

This test has been performed at Apollo Health & Lifestyle Ltd, RRL BANGALORE Laboratory

APOLLO HEALTH AND LIFESTYLE LIMITED - 101E BANGALORE

APOLLO Health and Lifestyle Limited

APOLLO CLINIC'S NETWORK

Telengana: Hyderabad | AS Rao Nagar | Chanda Nagar | Koradige | Palakurthi | Nizampet | Vijaynagar | Uppal | Andhra Pradesh: Vijaya Vittala | Karnataka: Bangalore - Basavanagudi | Bellary | Electronic City | Frazer Town | HF Layout | India

Other Pradesh: Oberoi Road | Gurgaon | Ahmedabad | Gwalior | Faridkot | Amritsar | Chandigarh | Haryana: Panipat | Tamil Nadu: Chennai











Patient Name : Mrs.ARCHANA KUMARI	Collected : 09/Nov/2024 09:29AM
Age/Gender : 40 Y 4 M 21 D/F	Received : 09/Nov/2024 12:23PM
UHID/MR No : CKOR.0000184438	Reported : 09/Nov/2024 03:08PM
Visit ID : CKOROPV431220	Status : Final Report
Ref Doctor : Self	Sponsor Name : ARCOFEMI HEALTHCARE LIMITED
Emp/Auth/TPA ID : 22S37366	

**DEPARTMENT OF BIOCHEMISTRY**

**ARCOFEMI - MEDIWHEEL - FULL BODY ANNUAL PLUS CHECK ADVANCED - FEMALE - 2D ECHO - PAN INDIA - FY232**

Test Name	Result	Unit	Bio. Ref. Interval	Method
<b>RENAL PROFILE/KIDNEY FUNCTION TEST (RFT/KFT) , SERUM</b>				
CREATININE	0.63	mg/dL	0.66 - 1.09	Modified Jaffe, Kinetic
UREA	16.40	mg/dL	17-43	GLDH, Kinetic Assay
BLOOD UREA NITROGEN	7.7	mg/dL	8.0 - 23.0	Calculated
URIC ACID	4.82	mg/dL	2.6-6.0	Uricase PAP
CALCIUM	8.70	mg/dL	8.8-10.6	Arsenazo III
PHOSPHORUS, INORGANIC	3.22	mg/dL	2.5-4.5	Phosphomolybdate Complex
SODIUM	138	mmol/L	136-146	ISE (Indirect)
POTASSIUM	4.2	mmol/L	3.5-5.1	ISE (Indirect)
CHLORIDE	107	mmol/L	101-109	ISE (Indirect)
PROTEIN, TOTAL	7.45	g/dL	6.6-8.3	Biuret
ALBUMIN	4.21	g/dL	3.5-5.2	BROMO CRESOL GREEN
GLOBULIN	3.24	g/dL	2.0-3.5	Calculated
A/G RATIO	1.3		0.9-2.0	Calculated

  
**Dr.Govinda Raju N L**  
 MSc,PhD(Biochemistry)  
 Consultant Biochemistry

  
**Dr Priya Murthy**  
 M.B.B.S,M.D(Pathology)  
 Consultant Pathologist









Patient Name : Mrs.ARCHANA KUMARI	Collected : 09/Nov/2024 09:29AM
Age/Gender : 40 Y 4 M 21 D/F	Received : 09/Nov/2024 12:15PM
UHID/MR No : CKOR.0000184438	Reported : 09/Nov/2024 06:45PM
Visit ID : CKOROPV431220	Status : Final Report
Ref Doctor : Self	Sponsor Name : ARCOFEMI HEALTHCARE LIMITED
Emp/Auth/TPA ID : 22S37366	

**DEPARTMENT OF IMMUNOLOGY**

**ARCOFEMI - MEDIWHEEL - FULL BODY ANNUAL PLUS CHECK ADVANCED - FEMALE - 2D ECHO - PAN INDIA - FY232**

High	High	High	High	Pituitary Adenoma; TSHoma/Thyrotropinoma
------	------	------	------	--

  
**Dr.Govinda Raju N L**  
 MSc,PhD(Biochemistry)  
 Consultant Biochemistry

  
**Dr Priya Murthy**  
 M.B.B.S,M.D(Pathology)  
 Consultant Pathologist



SIN No:KOR241100497

This test has been performed at Apollo Health & Lifestyle Ltd, RRL BANGALORE Laboratory.

APOLLO HEALTH AND LIFESTYLE LIMITED - RRL BANGALORE

APOLLO Health and Lifestyle Limited

Regd. Office: 10/22/20, Anand Nagar, 4th Cross, 4th Stage, 4th Block, Bengaluru, Karnataka, India. Phone: 9845111111

www.apolloclinic.com | Email ID: enquiry@apolloclinic.com, Ph.No: 080-4664 7777, Fax No: 4664 7766

APOLLO CLINIC'S NETWORK

Telangana: Hyderabad (45) | Andhra Pradesh: Vizag (1) | Karnataka: Bangalore (1) | Kerala: Kochi (1) | Maharashtra: Mumbai (1) | Odisha: Bhubaneswar (1) | Tamil Nadu: Chennai (1) | West Bengal: Kolkata (1) | Gujarat: Gandhinagar (1) | Haryana: Gurgaon (1) | Punjab: Ludhiana (1) | Rajasthan: Jaipur (1) | Uttar Pradesh: Lucknow (1) | Bihar: Patna (1) | Jharkhand: Ranchi (1) | Assam: Dispur (1) | West Bengal: Kolkata (1) | Odisha: Bhubaneswar (1) | Karnataka: Bangalore (1) | Kerala: Kochi (1) | Tamil Nadu: Chennai (1) | Maharashtra: Mumbai (1) | Gujarat: Gandhinagar (1) | Haryana: Gurgaon (1) | Punjab: Ludhiana (1) | Rajasthan: Jaipur (1) | Uttar Pradesh: Lucknow (1) | Bihar: Patna (1) | Jharkhand: Ranchi (1) | Assam: Dispur (1)



Patient Name : Mrs.ARCHANA KUMARI	Collected : 09/Nov/2024 09:29AM
Age/Gender : 40 Y 4 M 21 D/F	Received : 09/Nov/2024 04:44PM
UHID/MR No : CKOR.0000184438	Reported : 09/Nov/2024 05:29PM
Visit ID : CKOROPV431220	Status : Final Report
Ref Doctor : Self	Sponsor Name : ARCOFEMI HEALTHCARE LIMITED
Emp/Auth/TPA ID : 22S37366	

**DEPARTMENT OF CLINICAL PATHOLOGY**

**ARCOFEMI - MEDIWHEEL - FULL BODY ANNUAL PLUS CHECK ADVANCED - FEMALE - 2D ECHO - PAN INDIA - FY232**

Test Name	Result	Unit	Bio. Ref. Interval	Method
<b>COMPLETE URINE EXAMINATION (CUE) , URINE</b>				
<b>PHYSICAL EXAMINATION</b>				
COLOUR	PALE YELLOW		PALE YELLOW	Visual
TRANSPARENCY	CLEAR		CLEAR	Physical Measurement
pH	5.5		5-7.5	Double Indicator
SP. GRAVITY	1.010		1.002-1.030	Bromothymol Blue
<b>BIOCHEMICAL EXAMINATION</b>				
URINE PROTEIN	NEGATIVE		NEGATIVE	Protein Error Of Indicator
GLUCOSE	NEGATIVE		NEGATIVE	Glucose Oxidase
URINE BILIRUBIN	NEGATIVE		NEGATIVE	Azo Coupling Reaction
URINE KETONES (RANDOM)	NEGATIVE		NEGATIVE	Sodium Nitro Prusside
UROBILINOGEN	NORMAL		NORMAL	Modified Ehrlich Reaction
NITRITE	NEGATIVE		NEGATIVE	Diazotization
LEUCOCYTE ESTERASE	NEGATIVE		NEGATIVE	Leucocyte Esterase
<b>CENTRIFUGED SEDIMENT WET MOUNT AND MICROSCOPY</b>				
PUS CELLS	1-2	/hpf	0-5	Microscopy
EPITHELIAL CELLS	2-3	/hpf	<10	Microscopy
RBC	NIL	/hpf	0-2	Microscopy
CASTS	NIL		0-2 Hyaline Cast	Microscopy
CRYSTALS	ABSENT		ABSENT	Microscopy

**Comment:**

All urine samples are checked for adequacy and suitability before examination. All abnormal chemical examination are rechecked and verified by manual methods. Microscopy findings are reported as an average of 10 high power fields.



**Dr. Vidya Aniket Gore**  
M.B.B.S,M.D(Pathology)  
Consultant Pathologist



**Dr Priya Murthy**  
M.B.B.S,M.D(Pathology)  
Consultant Pathologist











---

Patient Name	: Mrs. Archana Kumari	Age	: 40Yrs 4Mths 25Days
UHID	: CKOR.0000184438	OP Visit No.	: CKOROPV431220
Printed On	: 12-11-2024 07:16 AM	Advised/Pres Doctor	: --
Department	: Cardiology	Qualification	: --
Referred By	: Self	Registration No.	: --
Employer Id	: 22S37366		

---

**DEPARTMENT OF CARDIOLOGY**

---

ECHO

---End Of The Report---



Dr.MOHAN MURALI  
MBBS, DNB General Medicine, DrNB Cardiology  
ANP20130001911KTK  
Cardiology

Patient Name	: Mrs. Archana Kumari	Age	: 40Yrs 4Mths 22Days
UHID	: CKOR.0000184438	OP Visit No.	: CKOROPV431220
Printed On	: 09-11-2024 06:28 AM	Advised/Pres Doctor	: --
Department	: Cardiology	Qualification	: --
Referred By	: Self	Registration No.	: --
Employer Id	: 22S37366		

## DEPARTMENT OF CARDIOLOGY

### Observation :-

1. Normal Sinus Rhythm.
2. Heart rate is 60 beats per minutes.
3. No pathological Q wave or ST-T changes seen.
4. Normal P,Q,R,S,T waves and axis.
5. No evidence of chamber, hypertrophy or enlargement seen.

### Impression:

NORMAL RESTING ECG.

NOTE:KINDLY TAKE A PHOTOCOPY OF THE GRAPH FOR FUTURE REFERENCE IF NEEDED

---End Of The Report---



Dr.MOHAN MURALI  
MBBS, DNB General Medicine, DrNB Cardiology  
ANP20130001911KTK  
Cardiology

**Name :** Mrs. Archana Kumari      **Age :** 40Y 4M 21D      **UHID :** CKOR.0000184438  
**Address :** Koramangala Vi Bk Bangalore Karnataka INDIA 560095      **sex :** Female  
**Plan :** ARCOFEMI MEDIWHEEL FEMALE AHC  
 CREDIT PAN INDIA OP AGREEMENT  
**OP No:** CKOROPV431220  
**Bill No:** CKOR-OCR-85217  
**Date:** Nov 9th, 2024, 9:07 AM



Sno.	Service Type/Service Name	Department	
1	ARCOFEMI - MEDIWHEEL - FULL BODY ANNUAL PLUS CHECK ADVANCED - FEMALE - 2D ECHO - PAN INDIA - FY2324		
1	ULTRASOUND - WHOLE ABDOMEN → (18)	Ultrasound Radiology	<input type="checkbox"/>
2	FITNESS BY GENERAL PHYSICIAN	Consultation	<input type="checkbox"/>
3	HbA1c, GLYCATED HEMOGLOBIN	Biochemistry	<input type="checkbox"/>
4	LBC PAP TEST- PAPSURE → (03) After 5 days	Histopathology	<input type="checkbox"/>
5	COMPLETE URINE EXAMINATION	Clinical Pathology	<input type="checkbox"/>
6	SJNO MAMMOGRAPHY - SCREENING → (18)	Mammography	<input type="checkbox"/>
7	BLOOD GROUP ABO AND RH FACTOR	Blood Bank	<input type="checkbox"/>
8	LIVER FUNCTION TEST (LFT)	Biochemistry	<input type="checkbox"/>
9	GLUCOSE, POST PRANDIAL (PP), 2 HOURS (POST MEAL)	Biochemistry	<input type="checkbox"/>
10	GLUCOSE, FASTING	Biochemistry	<input type="checkbox"/>
11	OPHTHAL BY GENERAL PHYSICIAN	Consultation	<input type="checkbox"/>
12	DIET CONSULTATION	General	<input type="checkbox"/>
13	DENTAL CONSULTATION → (15)	Consultation	<input type="checkbox"/>
14	BODY MASS INDEX (BMI)	General	<input type="checkbox"/>
15	X-RAY CHEST PA ✓ (11)	X Ray Radiology	<input type="checkbox"/>
16	HEMOGRAM + PERIPHERAL SMEAR	Haematology	<input type="checkbox"/>
17	PERIPHERAL SMEAR	Haematology	<input type="checkbox"/>
18	LIPID PROFILE	Biochemistry	<input type="checkbox"/>
19	2 D ECHO	Cardiology	<input type="checkbox"/>
20	GYNAECOLOGY CONSULTATION → (03)	Consultation	<input type="checkbox"/>
21	ECG → (14)	Cardiology	<input type="checkbox"/>
22	THYROID PROFILE (TOTAL T3, TOTAL T4, TSH)	Biochemistry	<input type="checkbox"/>
23	ENT CONSULTATION → (23) After 15 days	Consultation	<input type="checkbox"/>
24	URINE GLUCOSE(POST PRANDIAL)	Clinical Pathology	<input type="checkbox"/>
25	URINE GLUCOSE(FASTING)	Clinical Pathology	<input type="checkbox"/>
26	GAMMA GLUTAMYL TRANSFERASE (GGT)	Biochemistry	<input type="checkbox"/>
27	RENAL PROFILE/RENAL FUNCTION TEST (RFT/KFT)	Biochemistry	<input type="checkbox"/>

Vit B12, D, Ca.  
 Dental → Cleaning required  
 Physio - (17)  
 Ht - 159 cm  
 wt - 67.4 kg  
 Bp - 113/74 mm/Hg  
 P - 68 bpm



## Apollo Clinic

### Consent Form

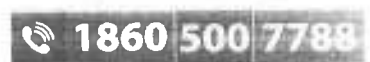Patient Name: ..... ARCHANA KUMARI ..... Age: ..... 40 .....  
 UHID Number: ..... Company Name: .....

I  Mr/<sup>✓</sup> Mrs/ Miss: ..... Employee of .....  
 (Company) want to inform you that I am ~~not~~ getting the ..... consultation .....  
 Test which is a part of health check package.

Reason if any: ..... I will be coming on Friday .....  
 And I claim the above statement in my full consciousness.

Patient Signature: ..... Archana Kumar ..... Date: ..... 9/11/24 .....

**Apollo Health and Lifestyle Limited**





# OPHTHAL REPORT

NAME: Mrs. Dechana Kumari

AGE: 40 GENDER: MALE/FEMALE

## RIGHT EYE

	SPH	CYL	AXIS	VA
DV	$\pm$			6/6
NV				N6

	SPH	CYL	AXIS	VA
DV	$\pm$			6/6
NV				N6

REMARK:

DATE: 09.11.2024

Am2.  
OPTOMETRIST

BRING THIS PRESCRIPTION IN YOUR NEXT VISIT





**Patient Name : Mrs. Archana Kumari**

**Patient ID : 184438**

**Age : 40 Years**

**Sex: Female**

**Referring Doctor : H/C**

**Date: 09.11.2024**

**SONOMAMMOGRAPHY**

Both breast shows normal parenchymal echotexture. There is no evidence of distortion of parenchymal architecture.

There is no evidence of focal solid, cystic lesions or calcifications seen.

The nipple and areolar region show no abnormality.

The bilateral axillary region shows no abnormality and there is no evidence of enlarge lymph nodes.

**IMPRESSION: NORMAL SONOMAMMOGRAPHY STUDY – BIRADS 1**

**DR VINOD JOSEPH DNB,DMRD  
RADIOLOGIST**

Patient Name : Mrs. Archana Kumari

Patient ID: 184438

Age : 40Year(s)

Sex: Female

Referring Doctor : H/C

Date:09.11.2024

**ULTRASOUND ABDOMEN AND PELVIS**

**Liver** is normal in size and shows normal echo pattern. No biliary dilatation .No focal lesion

**Portal vein** is normal in size, course and caliber. CBD is not dilated.

**Gall bladder** is not visualized

**Pancreas** to the extent visualized, appears normal in size, contour and echogenicity

**Spleen** is normal in size, shape, contour and echopattern. No evidence of mass or focal lesion.

**Right kidney** is normal in size, position, shape and echopattern. Corticomedullary differentiation is maintained. No evidence of calculi or hydronephrosis.

**Left kidney** is normal in size, position, shape and echopattern.corticomedullary differentiation is maintained. No evidence of calculi or hydronephrosis.

**Urinary Bladder** is well distended. wall thickness is normal. No internal echoes.

**Uterus:** is normal in size. Endometrial echoes are normal

**Endometrium:** measures 5.0mm.

Both ovaries normal in size and echopattern,

**Both adnexa:** Normal, no mass seen.

There is no ascites.

**IMPRESSION: NO SIGNIFICANT ABNORMALITY DETECTED**

**DR VINOD JOSEPH DNB,DMRD  
RADIOLOGIST**



NAME: Mrs> ARCHANA KUMARI

AGE:40Y

SEX: FEMALE

DATE: 09/11/2024

## ECHOCARDIOGRAPHY REPORT

### MEASUREMENT

AO – 25(20 – 35)mm	LIVD d – 35(36-52)mm	IVS – 10(06 – 11)mm
LA -26(19- 40)mm	LVID s 22(23- 39)mm	PWD – 11(06- 11)mm
EF – 60(>50%)	RVID-20	

### VALVES

Mitral Valve	: NORMAL
Aortic Valve	: NORMAL
Tricuspid Valve	: Normal,
Pulmonary Valve	: Normal,

### CHAMBERS

Left Atrium	: Normal
Right Atrium	: Normal
Left Ventricle	: Normal
Right Ventricle	: Normal

### SEPTAE

IVS	: Intact
IAS	: Intact



**GREAT ARTERIES**

Aorta : Normal  
Pulmonary Artery : Normal

**DOPPLER DATA**

Mitral : E > A , 0.7 / 0.5  
Aortic : Normal , 1.0 m/s,  
Tricuspid : Normal , 0.4 / 0.6  
Pulmonary : Normal, 1.10

WALL MOTION ABNORMALITIES : No RWMA

Pericardium : Normal

**FINAL DIAGNOSIS**

**NORMAL CHAMBERS AND DIMENSIONS  
NO RWMA , NORMAL LV EF -60%  
NORMAL DIASTOLIC FUNCTION  
NO OBVIOUS CLOTS/ EFFUSION/ VEGETATION**

**DR. MOHAN MURALI**  
**DNB(MED), DNB(CARDIOLOGY)**  
**CONSULTANT CARDIOLOGIST**

U/C

Date : 9/11/24  
MR No :  
Name *M*: Archana  
Age/Gender : 40yo  
Mobile no :

Department : OBSTETRICS & GYNAECOLOGY  
Consultant : DR JYOTHI RAJESH  
REG NO; KMC-42823  
Qualification : DGO, (DNB)  
Consulting Timings: 9.30am TO 12.00PM  
phone no: 9972044580, 7338064558

Height :	Weight :	BMI :	Waist Circum :
Temp :	Pulse :	Resp :	B.P :

General Examination / Allergies  
History

Clinical Diagnosis & Management Plan

No gynae complaints  
MVA - PANC-epidural emb - 13/10  
9/11  
OBV: P2L2 L0 3 1/2 yrs LSC  
Bridal  
Past H - NOS  
Family H - PANC - DM  
O/E - Pap after period

Follow up date:

*[Signature]*  
Doctor Signature

DE MAC1200 ST  
Female

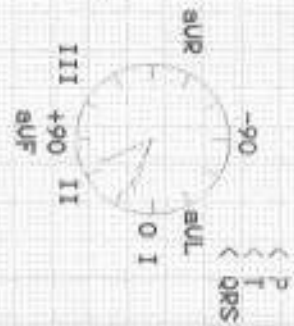
MRS ARCHANA, KUMARI 000194438, APOLLO MEDICAL CENTRE, KORAMANGALA

HR 60 bpm

AGE: 40

Measurement Results:

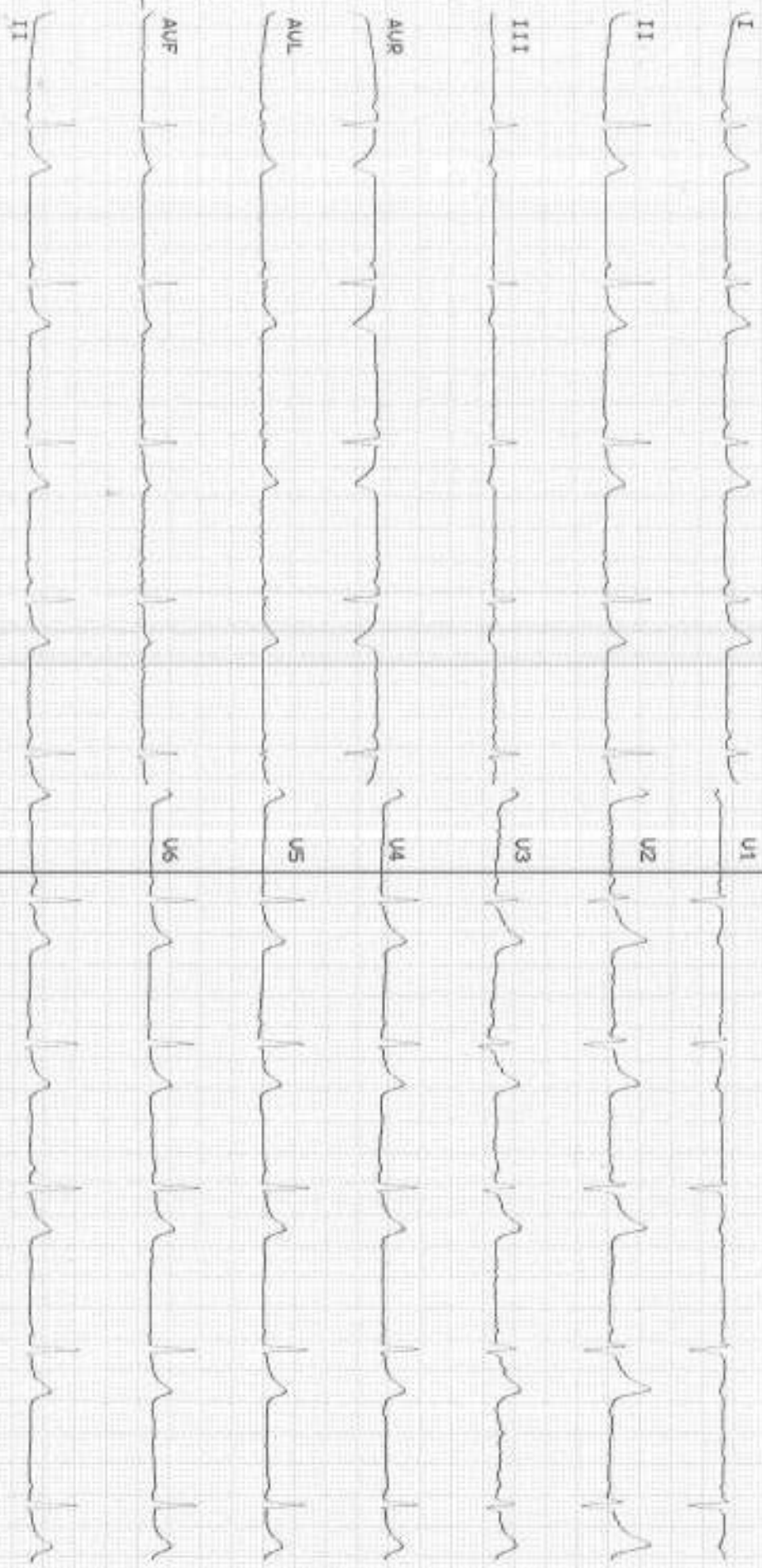
PR : 390 / 393 ms  
QT/QTcB : 390 / 393 ms  
PR : 128 ms  
P : 90 ms  
RR/PP : 984 / 1000 ms  
P/QRS/T : 20 / 65 / 25 degrees  
QTd/QTcBd : 30 / 30 ms  
Sokolow : 1.1 mV  
NK : 8



Interpretation:

*(Signature)*

Unconfirmed report.



09 Nov 2024 09:59:55 25mm/s 10mm/mV AEC 50Hz 0.08 20Hz 6.712 4.0mV 0.2 (21.1)



Patient Name	: Mrs. Archana Kumari	Age	: 40Yrs 4Mths 21Days
UHID	: CKOR.0000184438	OP Visit No.	: CKOROPV431220
Printed On	: 09-11-2024 11:58 AM	Advised/Pres Doctor	: --
Department	: Cardiology	Qualification	: --
Referred By	: Self	Registration No.	: --
Employee Id	: 22S37366		

**DEPARTMENT OF CARDIOLOGY**

**Observation :-**

1. Normal Sinus Rhythm.
2. Heart rate is 60 beats per minutes.
3. No pathological Q wave or ST-T changes seen.
4. Normal P,Q,R,S,T waves and axis.
5. No evidence of chamber, hypertrophy or enlargement seen.

**Impression:**

**NORMAL RESTING ECG.**

**NOTE:KINDLY TAKE A PHOTOCOPY OF THE GRAPH FOR FUTURE REFERENCE IF NEEDED**

---End Of The Report---



**Dr.MOHAN MURALI**  
MBBS, DNB General Medicine, DrNB Cardiology  
ANP20130001911KTK  
Cardiology



Patient Name	: Mrs. Archana Kumari	Age	: 40Yrs 4Mths 21Days
UHID	: CKOR.0000184438	OP Visit No.	: CKOROPV431220
Printed On	: 09-11-2024 12:39 PM	Advised/Pres Doctor	: --
Department	: Radiology	Qualification	: --
Referred By	: Self	Registration No.	: --
Employeer Id	: 22S37366		

**DEPARTMENT OF RADIOLOGY**

**X RAY CHEST PA**

Both lungs fields appear normal.

Both hilae are normal.

Both costophrenic and cardiophrenic angles are normal.

The cardiac and mediastinal shadows appear normal.

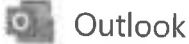Bones and soft tissues appear normal.

**IMPRESSION : NORMAL STUDY.**

---End Of The Report---

*P.J. Vinod*

Dr.VINOD P JOSEPH  
MBBS, DNB, DMRD  
25487  
Radiology



**Health Check up Booking Confirmed Request(22S37366),Package Code-PKG10000376,  
Beneficiary Code-322506**

From Mediwheel <wellness@mediwheel.in>

Date Tue 05-11-2024 16:25

To ASHISH KUMAR KESHRI <ASHISH.KESHRI2@bankofbaroda.com>

Cc customercare@mediwheel.in <customercare@mediwheel.in>

**सावधान:** यह मेल बैंक डोमेन के बाहर से आया है. अगर आप प्रेषक को नहीं जानते तो मेल में दी गयी फ. **CAUTION:** THIS MAIL IS ORIGINATED FROM OUTSIDE OF THE BANK'S DOMAIN. DO

**011-41195959**

Dear **MR. KESHRI ASHISH KUMAR,**

We are pleased to confirm your health checkup booking request with the following details.

**Hospital Package Name** : Mediwheel Full Body Annual Plus Check Advanced - Female

**Name of Diagnostic/Hospital** : Apollo Medical Centre - Koramangala

**Address of Diagnostic/Hospital-** : Apollo Medical centre, Plot 51, 5th Block, Opp. Jyothi Nivas College, Koramangala - 5600095

**City** : Bangalore

**State** : Karnataka

**Pincode** : 560095

**Appointment Date** : 09-11-2024

**Confirmation Status** : Booking Confirmed

**Preferred Time** : 08:00 AM - 08:30 AM

**Booking Status** : Booking Confirmed

Member Information		
Booked Member Name	Age	Gender
ARCHANA KUMARI	40 year	Female

**Note - Please note to not pay any amount at the center.**

**Instructions to undergo Health Check:**

- Please ensure you are on complete fasting for 10-To-12-Hours prior to check.
- During fasting time do not take any kind of medication, alcohol, cigarettes, tobacco or any other liquids (except Water) in the morning.
- Bring urine sample in a container if possible (containers are available at the Health Check centre).

- Please bring all your medical prescriptions and previous health medical records with you.
- Kindly inform the health check reception in case if you have a history of diabetes and cardiac problems.

**For Women:**

- Pregnant Women or those suspecting are advised not to undergo any X-Ray test.
- It is advisable not to undergo any Health Check during menstrual cycle.

Request you to reach half an hour before the scheduled time.

In case of further assistance, Please reach out to Team Mediwheel.

---

Thanks,  
Mediwheel Team  
Please Download Mediwheel App

You have received this mail because your e-mail ID is registered with **Arcofemi Healthcare Limited** This is a system-generated e-mail please don't reply to this message.

Please visit to our Terms & Conditions for more informaion. [Click here to unsubscribe.](#)

@ 2024 - 25, Arcofemi Healthcare Pvt Limited.(Mediwheel)





अर्चना कुमारी  
Archana Kumari  
जन्म तारीख/DOB:19/06/1984  
महिला Female

5524 8200 5907

आधार - आम आदमी का अधिकार