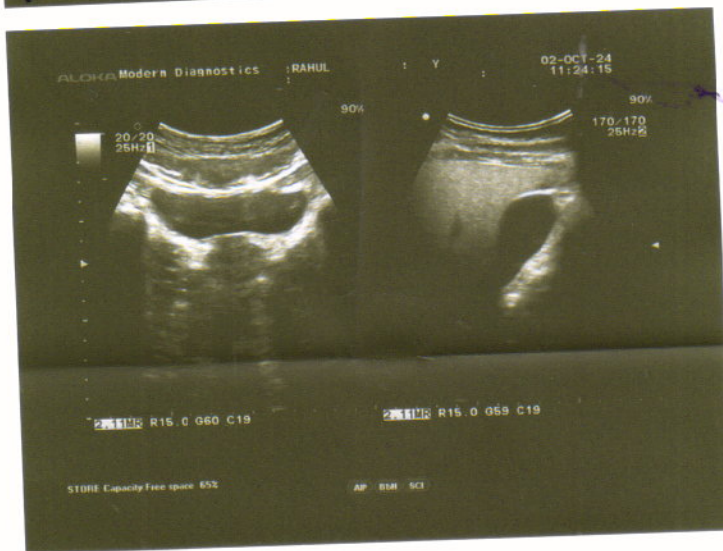
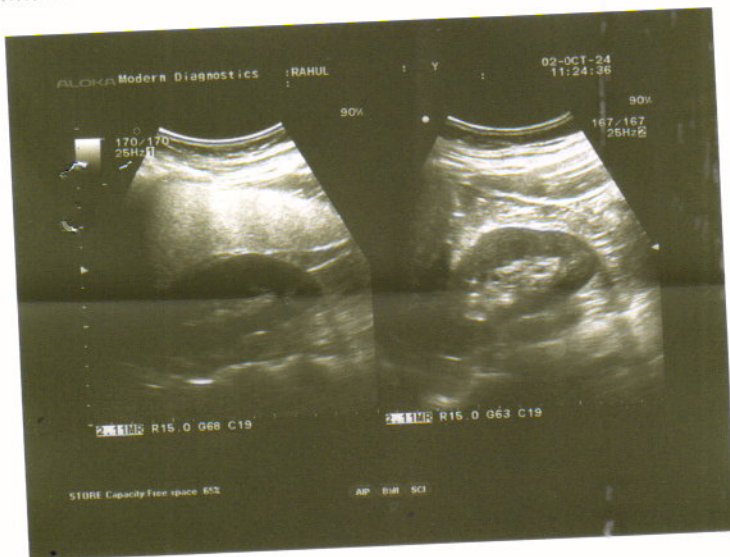
Dr. Prashant Naik

M.D. (Radiology)

Reg. No. 58314

Time : 5.00 pm to 7.00 pm By Appointment

Dr. Kedar Athawale

DMRD DNB (Radiology)

Reg. No. 84908

Time : 11.00 am to 1.00 pm By Appointment

• DIGITAL X-RAY • SONOGRAPHY • COLOUR DOPPLER

Patient's Name Mr Rahul Lad
Ref By Dr Dr V.M.Nadkarni
Date Oct 02, 2024

USG ABDOMEN & PELVIS

Liver normal in size, shape & outline & reveals normal echo-texture.
No focal lesion seen. Intra hepatic biliary and portal vein radicles normal.
Gall bladder physiologically distended & shows clear contents. No calculi. No e/o cholecystitis.
Portal vein & CBD normal. No calculus in CBD.
Spleen & visualized pancreas show normal size & echoanatomy. Tail of pancreas not visualized due to unavoidable bowel gas.
Both kidneys normal in size, shape, outline & position.
Right kidney :- 90mm x 40mm.
Left kidney :- 91mm x 46 mm.
No hydronephrosis, hydroureter on either side. No calculus seen in both kidneys or in visualized ureters.
Cortico-medullary differentiation normal.
Urinary bladder is well filled. No mural or luminal pathology seen.
Prostate normal in size, echotexture; measures 30mmx25mmx24mm.
Aorta & IVC normal. No lymphadenopathy. No loculated or free fluid collection seen in abdomen or pelvis. No abnormally dilated bowel loops seen.

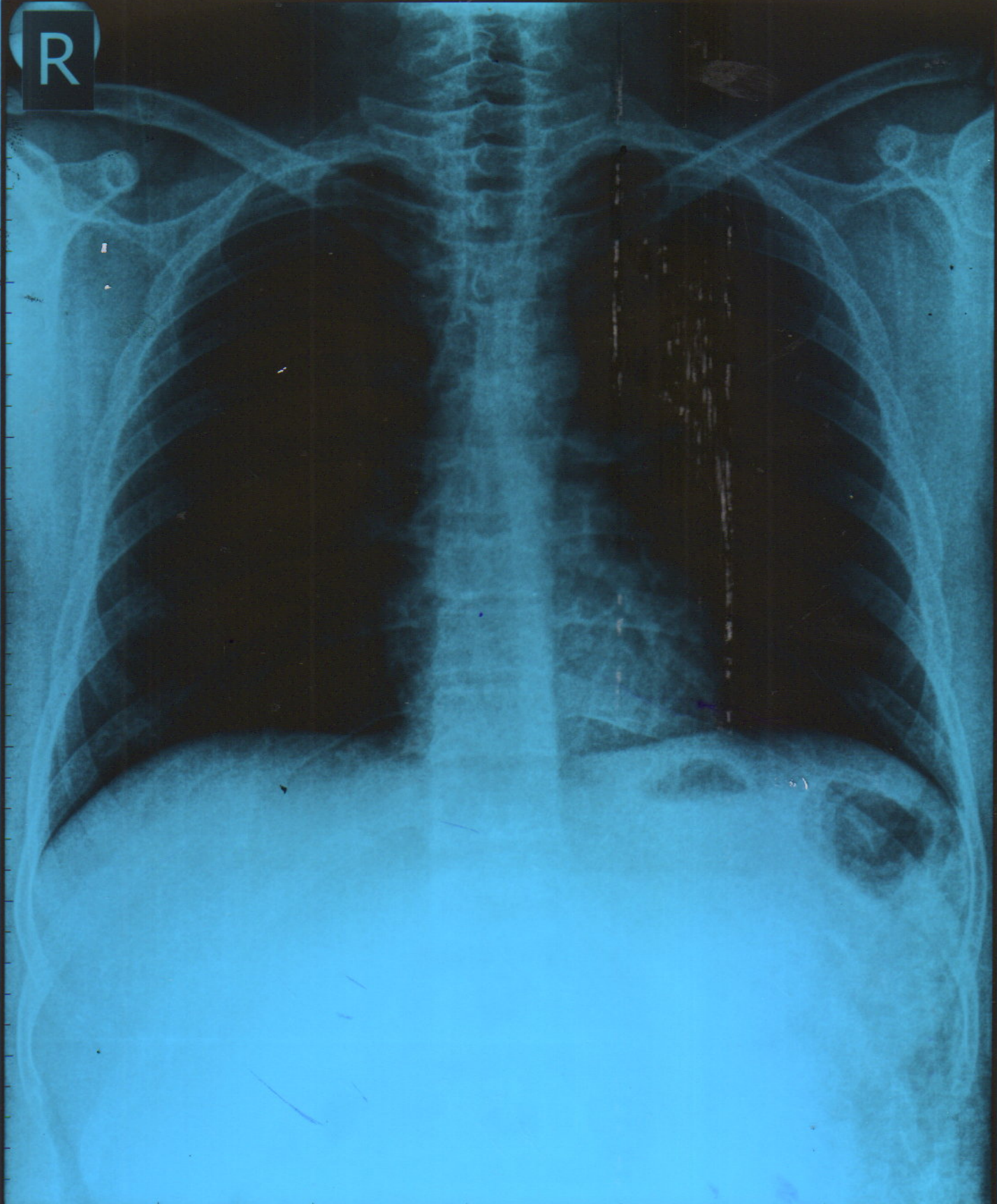
IMPRESSION

No abnormality appreciated in this USG study of Abdomen & Pelvis

Dr. Kedar Athawale
DMRD, DNB
Thanks for referral

DR. KEDAR ATHAWALE
DMRD DNB (Radiology)
Reg. No. 84908

R

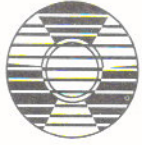

RAHUL LAD Male / 31 YRS

Chest PA

02/10/2024 06:09:09 PM

SHRI DASHABHUJA X-RAY CLINIC. PUNE. 020-25468187.



SHRI DASHABHUJA
X-RAY CLINIC

Digital X-Ray (CR System) Available
OPG Facility Available

GANGAVATARANA, Ground Floor, Plot
No. 7, S. No. 42 A/1A/2F, Dashbhujja
Ganesh Colony, Near Dashbhujja
Ganesh Temple, Karve Rode,
Pune. 411038.
Clinic : 2546 8187, 8308839383
Res : 2422 1359, 9822041859

Dr. LALIT P. PATHAK

M. D. Radiologist
Reg. No. 52382

Timing : 9.00 a.m. To 1.30 p.m.
4.30 p.m. To 8.30 p.m.
SUNDAY CLOSED

NAME:MR RAHUL LAD.

DATE:2 10 2024.

REF BY:DR VIVEK NADKARNI.

X RAY CHEST PA VIEW.

Both the domes of the diaphragm are clear & at normal position.

The heart,the aorta,the mediastinum & the pulmonary vasculature
reveal no abnormality.

Lungs show no acute or active parenchymal pathology.

Pleural sinuses are clear on both sides.

There is no evidence of any hilar or mediastinal lymphadenopathy.

No pathology is evident in the thoracic bony cage &
the soft tissues.

CONCLUSION:NORMAL X RAY CHEST PA VIEW.

Dr.Lalit Pathak MD(Radiology)

CBCT, OPG & PORTABLE X-RAY FACILITY AVAILABLE

(P.T.O)