



भारत सरकार  
GOVERNMENT OF INDIA



ਸੁਨੀਲ ਕੁਮਾਰ ਖਰੇ

Sunil Kumar Khare

ਜਨਮ ਮਿਤੀ/ DOB: 01/07/1971

ਮਰਦ / MALE



9686 3000 1765

ਆਧਾਰ-ਆਮ ਆਦਮੀ ਦਾ ਅਧਿਕਾਰ



# THAREJA NURSING HOME



DIGITAL X-RAY, OPG, COMPUTERISED ECG & EEG, DIAGNOSTIC  
LABORATORY EQUIPED WITH COMPUTERISED AUTO ANALYZER & CBC

1, Ram Kuteer, Company Bagh Road, ALWAR - 301001 (Raj.) Ph: 0144-2700184, 2331842

PROPOSAL NO. PKG10000236

Patient Name MR SUNIL KUMAR KHARE

Ref. By Dr. M. N. THAREJA

Date 23/04/2022

Age 50 Yrs.

Sex M

Details of packages		Patients report	Units	Normal value
HB		14.6	gm%	M-13.5-18, F-11.5-16.5
TRBC		5.0	million /cu mm	M-4.0-5.5, F-3.9-5.6
TWBC		5800	cu mm	4000-11000
DLC	Polymorphs	55	%	42-75
	Lymphocytes	42	%	20-50
	Eosinophil	03	%	1-6
	ESR	02	mm 1 <sup>st</sup> Hr.	M-0-9, F-0-20
Platelets		251000	Lack / cu mm	1.5-4
PCV		40.9	%	37-54
MCV		81.6	Cubicmicrons	86-98
MCH		29.1	Picograms	26-34
MCHC		35.7	%	32-36
Blood Grouping & Rh Factor		" AB "Rh+(POSITIVE)		
BUN		12.0	mg %	M-7-20
S. Creatinine		0.81	Mg/100ml	0.9-1.4 mg /100 ml
HBsAg		-		
HIV I & II		-	Elisa Method	
HbA1C		5.0	%	4-6%
VDRL		-		

Details of packages		Patients report	Units	Normal value	
LFT	GGTP	31.0	U/L	5-60	
	SGOT	15.0	Units / ml	Upto 40	
	SGPT	27.0	Units / ml	Upto 40	
	S. Bilirubin	Total Bilirubin	0.59	mg%	Upto 1.2
		Direct Bilirubin	0.22	mg%	0-0.25
		Indirect Bilirubin	0.37	mg%	
		T. Protein	6.91	Gm%	6.2-8.3
	S. Albumin	4.12	Gm%	3.2-5.3	
	Globulin	2.79	Gm%		
	Alkaline phosphate	121.0	IU/L	60 - 170	
S. Calcium	-	Gm%	8.5-10.5		
Uric Acid	4.0	Mg%	2.5-7 mg%		
Blood Sugar Fasting		85.0	Mg%	60-110 mg %	
Blood Sugar PP		117.0	Mg%	Upto 160	
Lipid Profile	S. Cholesterol	198.0	mg%	120-220	
	S. Triglycerides	120.0	mg/ml	Upto 170	
	HDL Cholesterol	60.0	IU/L		
	LDL cholesterol	114.0	IU/L	450 at 37° C	
	VLDL	26.0	mg %	Upto 35	

### Routine Urine Analysis

Physical/ Chemical	Microscopic:	
Appearance	Clear	RBCs Nil
Specific Gravity	1010	WBCs 1-2/HPF
Ph	ACIDIC	Epith. Cells 1-2/HPF
Albumin	Nil	Casts Nil
Glucose F	NIL	Crystals Nil
Ketones	----	Bacteria Nil
Blood	Nil	Glucose P.P. NIL

Signature of Technician

Signature of Doctor

This Report is not Valid for Medical Legal Purpose



# THAREJA NURSING HOME



DIGITAL X-RAY, OPG, COMPUTERISED ECG & EEG, DIAGNOSTIC  
LABORATORY EQUIPED WITH COMPUTERISED AUTO ANALYZER & CBC

1, Ram Kuteer, Company Bagh Road, ALWAR - 301001 (Raj.) Ph: 0144-2700184, 2331842

PROPOSAL NO. PKG10000236

Patient Name MR SUNIL KUMAR KHARE

Ref. By Dr. M. N. THAREJA

Date 23/04/2022


Age 50 Yrs.

Sex M

**PART - X-RAYED :** X-RAY CHEST PA VIEW  
**REPORT :** X-RAY CHEST P.A. VIEW  
:- Chest is bilaterally symmetrical.  
:- C.P. Angles are clear.

**CONCLUSION: Normal Study**

  
Signature of Technician

  
Dr. M. N. THAREJA

Signature of Doctor

MBBS

Thareja Nursing Home  
Alwar-301001, (Raj.)

This Report is not Valid for Medical Legal Purpose



# THAREJA NURSING HOME

1, Ram Kuteer Company Bagh Road, ALWAR - 301001 (Raj.)  
Mob. 9982111801, Ph. 0144-2700184, 2331842, Telefax: 0144-2342339  
E-mail: drmnthareja@yahoo.com



Name Mr. Sunil ji Age ..... Yr OPD/UHID ..... Date 23/4/22  
Address ..... Mobile No.....

VITALS	B.P.	Pulse	Temp.	Wt.	Ht.	Allergies
--------	------	-------	-------	-----	-----	-----------

### Complaints

General check up done.

### Findings

oral hygiene status: fair.  
→ spacing  $\frac{||}{||}$

### Investigation

→ Calculect +  
→ Carious  $\frac{||}{||}$   
→ Bruxism.  
→ Gen Attrition

### Treatment

→ Edge to Edge bit.  
→ AM. Scaling & Polishing  
→ An Night Guard.  
Done.

**Dr. Prerna Thareja**  
MDS (Endodontics)  
Diploma in Oral Implantology  
Diploma in Hospital Administration  
Ex Senior Resident AIIMS, Jodhpur  
Life Member QCI A-3574

### DR. M.N. THAREJA

7233 (RMC)  
Male Infertility Specialist

### DR. SAVITA THAREJA

7600 (RMC)  
Female Infertility Specialist

### DR. JAYANT THAREJA

A-0824 (RSDC)  
M.D.S.  
Oral & Maxillo - Facial Surgery  
Ex Resident Trauma Centre,  
AIIMS, Delhi

### DR. SHIVANI THAREJA

10807 / 31220 (RMC)  
Ophthalmologist  
Cornea Specialist

### DR. PRERNA THAREJA

A-3574  
MDS (Endodontics)  
Root Canal Specialist  
Ex Resident  
AIIMS, Jodhpur

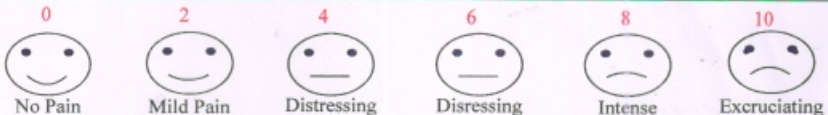### DR. H.R. GUPTA

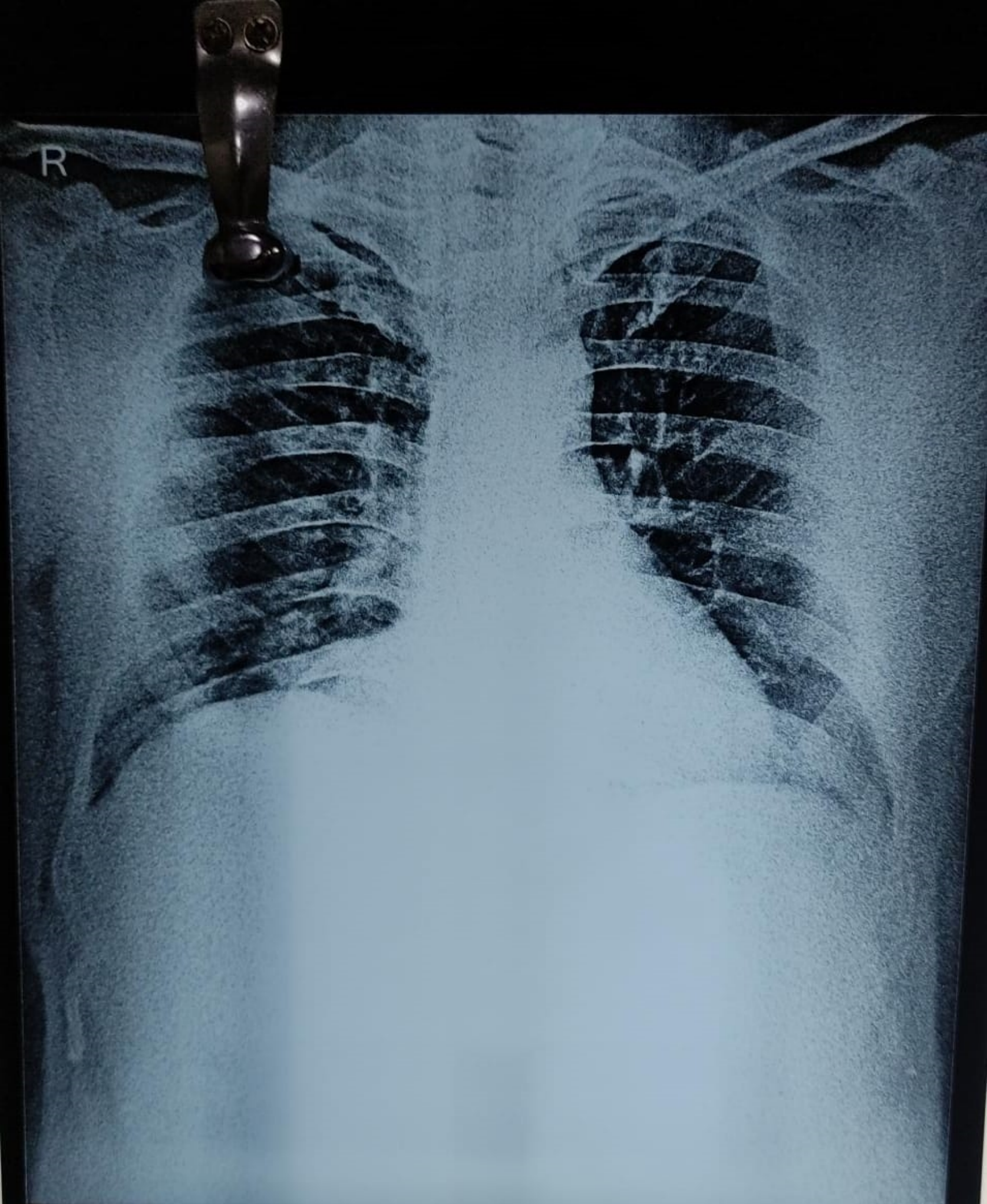
1744 (RMC)  
Senior Consultant  
M.S. Gen Surgeon

### DR. VARUN SAPRA

Reg. No. 70990 (DMC)  
MBBS DNB ORTHO, D.ORTHO  
Joint Replacement &  
Arthroscopy Surgeon

### Pain Scale





R

MR. SUNIL KUMAR KHARE AGE 50Y. 08 50 M CHEST, P->A  
THAREJA NURSING HOME ALWAR

PAT NAME:

Mr. Sunil Kumar Kharia

HR: 63/min

PR: 0°

SINUS RHYTHM

Intervals:

QRS -11°

LEFTWARD AXIS

Age: 50 M / F

RR: 94 ms

T: 9°

OTHERWISE NORMAL ECG

CMV: KG

PR: 118 ms

P (11) 0.12 mV

5.70

mHG

QRS: 80 ms

S (U1) -0.30 mV

10 mm/mV

23/4/22

QT: 364 ms

R (V5) 1.93 mV

10 mm/mV

10 mm/mV

UNCONFIRMED REPORT

10 mm/mV

QTc: 375 ms

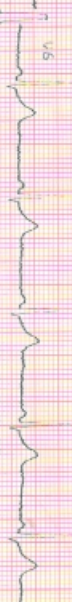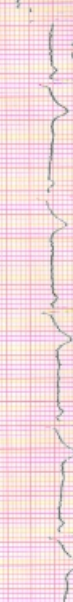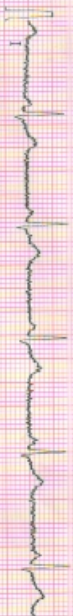Sokol: 2.34 mV

10 mm/mV

10 mm/mV

UNCONFIRMED REPORT

10 mm/mV



25 mm/s

0.05-35 Hz

F50

5a ZI:BP-R-22 10:18:20

RT-2 C.S.05

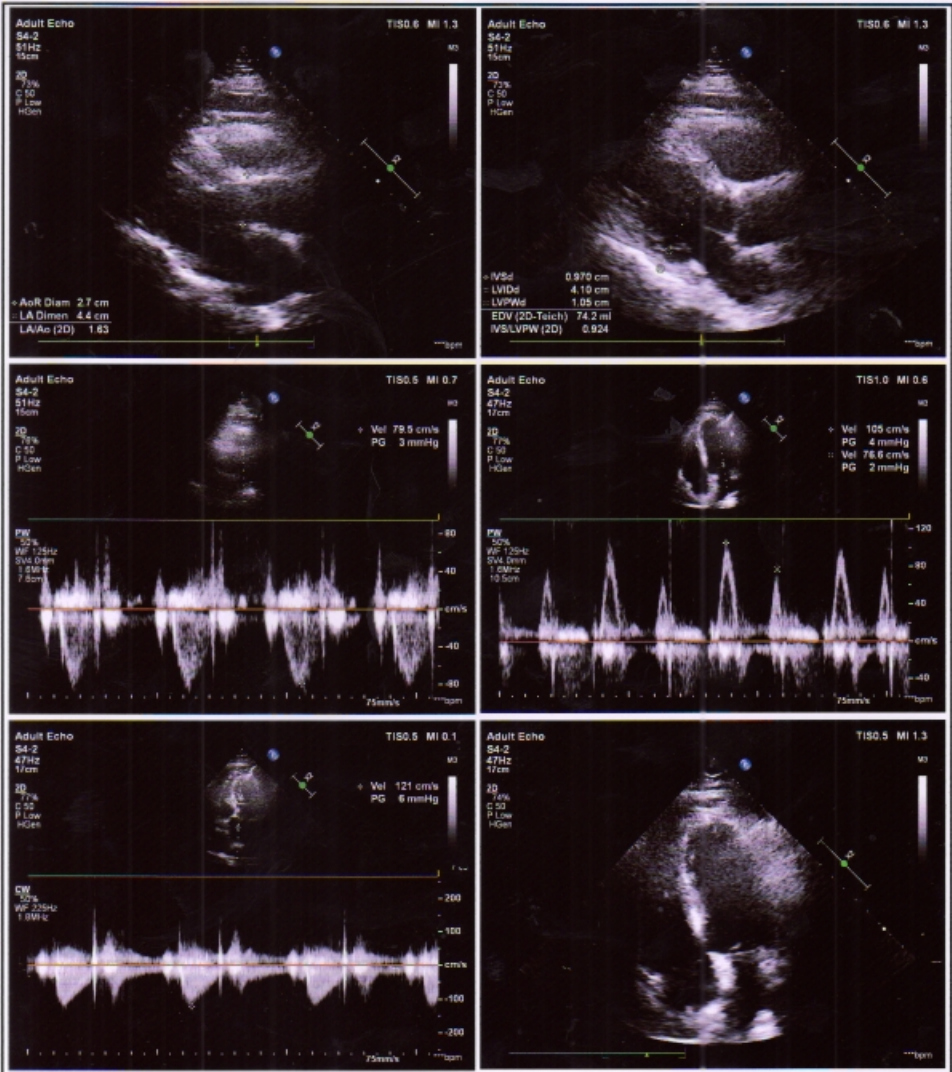
SCHILLER

PART NO.2 1570017M

0033

008

## Images





# GUPTA ENT AND HEART CENTRE

Dayanand Marg, Nangli Circle, Alwar (Raj.) Ph. 0144-3591336 | M. 7378184427

## Echocardiography Report

Name : Mr. Sunil Kumar Refd by: Dr. M. N. Thareja  
Age / Sex : 50yrs./male Date : 23 April 2022

**Clinical Diagnosis :** For Cardiac Evaluation  
**2D Echocardiography Findings**  
Mitral Valve : Normal  
Aortic Valve : Normal  
Tricuspid Valve : Normal  
Pulmonary Valve : Normal  
Left Atrium : 4.4cm: Dilated  
Left Ventricle : Normal LV size with normal LV systolic function. No RWMA

LVIDd	4.1cm.	IVSd	0.9cm.	EF	60%	Visual
LVIDs	2.4cm.	PWd	1.0cm.	EF	%	F.S.

Right Atrium : Normal  
Right Ventricle : Normal  
Aorta : 2.7cm: Normal  
Pulmonary Artery : Normal  
Pulmonary Veins : Normal  
Superior Venacava : Normal  
Inferior Venacava : Normal  
Pericardium : Normal  
Intracardiac Masses : No Intracardiac masses seen  
IAS/IVS : Intact

### Doppler Findings:

Valve	Peak Velocity (cm/s)	Peak Gradient (mmHg)	Mean Gradient (mmHg)	Regurgitation Grade	others/comments
Mitral Valve	E-/A-105/76			No MR	
Aortic Valve	121				
Tricuspid Valve				No TR, No PAH.	
Pulmonary Valve	79				

**Diagnosis :** Transthoracic echo done in supine position at resting heart rate of 70bpm, shows **Normal LV size with normal LV systolic function. LVEF~60% (Visual). No RWMA.**  
Dilated LA, other cardiac chambers are normal in size.  
No MR, No TR, No PAH.  
Normal MIP.  
No pericardial effusion /Vegetation /Clot Intracardiac masses seen.  
Normal left sided arch of aorta, No Coarctation.

Dr. Prachi Gupta  
MBBS, PGCC  
(Non-invasive cardiologist) Invasive  
Gupta ENT and Heart Centre  
Nangli Circle, Alwar

Please correlate clinically





# THAREJA NURSING HOME

1, Ram Kuteer Company Bagh Road, ALWAR - 301001 (Raj.)  
Mob. 9982111801, Ph. 0144-2700184, 2331842, Telefax: 0144-2342339  
E-mail: drmnthareja@yahoo.com



Name ..... Sunil Kumar ..... Age 50 ..... Yr OPD/UHID ..... Date 23/11/20  
Address ..... Mobile No.....

VITALS	B.P.	Pulse	Temp.	Wt.	Ht.	Allergies
--------	------	-------	-------	-----	-----	-----------

Complaints

Routine eye check up

Findings

Distance vision  $\leftarrow$  6/6  
 $\leftarrow$  6/8

Investigation

Colour vision was  
Near vision  $\leftarrow$  R N/6  
with glasses  $\leftarrow$  N/6

Treatment

**DR. M.N. THAREJA**  
7233 (RMC)  
Male Infertility Specialist

**DR. SAVITA THAREJA**  
7600 (RMC)  
Female Infertility Specialist

**DR. JAYANT THAREJA**  
A-0824 (RSDC)  
M.D.S.  
Oral & Maxillo - Facial Surgery  
Ex Resident Trauma Centre,  
AIIMS, Delhi

**DR. SHIVANI THAREJA**  
10807 / 31220 (RMC)  
Ophthalmologist  
Cornea Specialist

**DR. PRERNA THAREJA**  
A-3574  
MDS (Endodontics)  
Root Canal Specialist  
Ex Resident  
AIIMS, Jodhpur

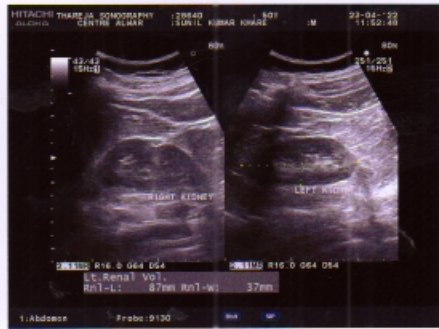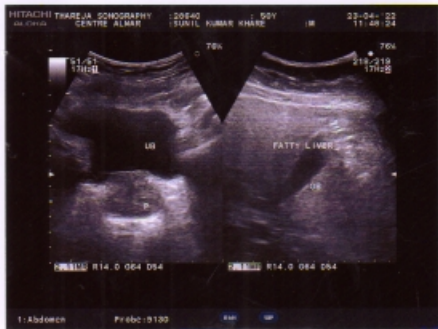**DR. H.R. GUPTA**  
1744 (RMC)  
Senior Consultant  
M.S. Gen Surgeon

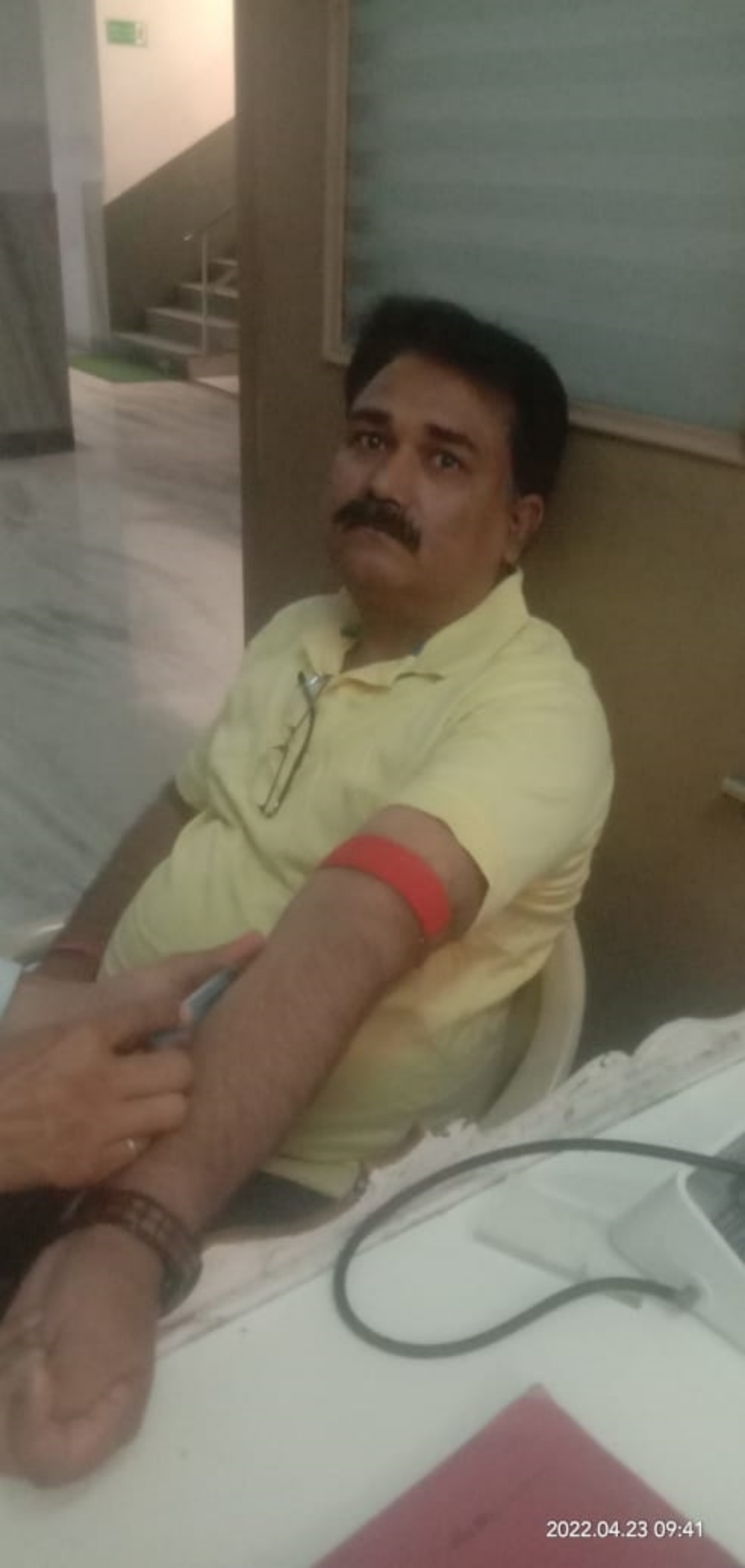**DR. VARUN SAPRA**  
Reg. No. 70990 (DMC)  
MBBS DNB ORTHO, D.ORTHO  
Joint Replacement &  
Arthroscopy Surgeon

**Dr. M. N. THAREJA**  
MBBS  
Thareja Nursing Home  
Alwar-301001 (Raj.)

**Pain Scale**

0	2	4	6	8	10
No Pain	Mild Pain	Distressing	Disressing	Intense	Excruciating





2022.04.23 09:41



# THAREJA SONOGRAPHY CENTRE

1, Ram Kuteer, Company Bagh Road, ALWAR - 📞 (0144) 2700184



This report is not valid for MLC Purpose

Ref. No.

Date.....  
23/04/2022

Name of Patient: MR. SUNIL KUMAR Age: 50 Yrs. Sex: M  
Ref. by: DR. M. N. THAREJA

## Sonography Report – abdomen

**LIVER:** Size: RL: 12.5 cm L. L.: 10.1 cm  
Margins: Round L.H.B.R: ND  
Parenchyma : Echo , Bright  
C. B. D. Size: 4.8 mm LUMEN: Clear  
P.V. Size: mm LUMEN: Clear  
GALL BLADDER : Size 4.0 X 1.9cm Lumen : Clear  
Wall thickness N  
PANCREAS: N  
SPLEEN: 9.4 cc  
KIDNELYS: Right: 8.6 X 9.4 cm Left: 8.7 X 3.7 cm

PELVICALYCAL SYSTEM:  
CORTICO – MEDU. DIFF: N

RETROPERITONEUM :  
LYMPH – NODES : Not Seen  
PLEURAL EFFUSION :

ASCITES  
URINARY BLADDER:  
Prevoiding Volume 169 cc  
Wall Thickness N

PROSTATE: N  
Size: 18.8 cc  
Parenchyma: Echo


Residual Urine C.C.  
Lumen: Clear

Capsule: Intact

SEMINAL – VASICLES: Normal

**Conclusion:- Fatty Liver**

Thanks,

  
Dr. Savita Thareja  
Reg. No. 7600  
Rajasthan Medical Council

Enclosed: Photo - 2

PLEASE NOTE: INTESTINAL PATHOLOGY CAN NOT BE RULE OUT  
This is only an opinion, not a diagnosis, which should be clinically co-related. No procedure/surgery should be undertaken simply on the basis of this opinion because Ultrasound accuracy is only 96%.

\* Subject to Alwar jurisdiction. \* Not valid for medico-legal purpose.



# THAREJA NURSING HOME



DIGITAL X-RAY, OPG, COMPUTERISED ECG & EEG, DIAGNOSTIC  
LABORATORY EQUIPED WITH COMPUTERISED AUTO ANALYZER & CBC

1, Ram Kuteer, Company Bagh Road, ALWAR - 301001 (Raj.) Ph: 0144-2700184, 2331842

Name : **SUNIL KUMAR KHARE** age **50** Sex : **MALE**

Ref. By : **M.N.THAREJA** Lab No. : Date : **April 23, 2022**

## HORMONES & MARKERS

<u>Test</u>	<u>Value</u>	<u>Units</u>	<u>Biological Ref. Values</u>
T3 (Total Triiodothyronine)	1.59	ng/dL	0.60-1.81 ng/dL Adults
T4 (TotalThyroxine)	7.60	µg/dL	3.2-12.60 µg/dL : Adults
TSH (Thyroid Stimulating Hormone)	2.99	µIU/mL	Adults : 0.35-5.50 µIU/mL

### Interpretation of TSH :-

#### Children

0 Days : 1.0-39.0 uIU/mL  
5 days : 1.7-9.1 uIU/mL  
1 year : 0.4-8.6 uIU/mL  
2 years : 0.4-7.6 uIU/mL  
3 years : 0.3-6.7 uIU/mL  
4-19 years : 0.4-6.2 uIU/mL

### Interpretation of TSH :-

#### Children

3.20 - 34.6 µIU/mL 1- 2 Days  
0.70 - 15.4 µIU/mL 3 - 4 Days  
0.70 - 9.10 µIU/mL 15 Days - 5 Months  
0.70 - 6.40 µIU/mL 5 Months - 20 Years

#### Adults

20-54 years : 0.35-5.50 uIU/mL  
55-87 years : 0.5-8.9 uIU/mL

#### Pregnancy

1st Trimester : 0.30 - 4.50 µIU/mL  
2nd Trimester : 0.50 - 4.60 µIU/mL  
3rd Trimester : 0.80 - 5.20 µIU/mL

#### Pregnancy

0.30 - 4.50 µIU/mL 1st Trimester  
0.50 - 4.60 µIU/mL 2nd Trimester  
0.80 - 5.20 µIU/mL 3rd Trimester

Method : **Fluorescence Immunoassay Technology**

Sample Type : **Fresh Blood Serum**

### Remarks :

Primary malfunction of the Thyroid gland may result in excessive (hyper) or Low (hypo) release of T3 or T4. In addition, as TSH directly affect thyroid function, malfunction of the pituitary or the hypothalamus influences the thyroid gland activity.

Disease in any portion of the thyroid-pituitary-hypothalamus system may influence the level of T3 and T4 in the blood, in Primary Hypothyroidism,

TSH levels are significantly elevated, while in secondary and tertiary hypothyroidism, TSH levels may be low. In addition, in Euthyroid sick syndrome, multiple alterations in serum thyroid function test findings have been recognized.

*Vijay*

Signature of Technician

*M.N. Thareja*

Signature of Doctor