



भारत सरकार
Government of India


भारतीय विशिष्ट पहचान प्राधिकरण
Unique Identification Authority of India

Enrollment No.: 0013/07005/04609


To
Alpi Baranwal
C/O Roshan Kumar,
Flat No 201, H-Block, Vgn Stafford,
VTC: Thirumullaivoyal,
PO: Thirumullaivoyal,
Sub District: Poonamallee, District: Tiruvallur,
State: Tamil Nadu,
PIN Code: 600062,
Mobile: 8601861706

10/02/2013

15647588



MF156475889FI



आपका आधार क्रमांक / Your Aadhaar No. :

3123 6093 1050

मेरा आधार, मेरी पहचान



भारत सरकार
Government of India



Alpi Baranwal
DOB : 01/03/1982
Female

3123 6093 1050

मेरा आधार, मेरी पहचान

10/02/2013

Alpi



सूचना

- आधार पहचान का प्रमाण है, नागरिकता का नहीं।
- सुरक्षित QR कोड/ऑफलाइन XML/ ऑनलाइन ऑथेंटिकेशन से पहचान प्रमाणित करें।

INFORMATION

- Aadhaar is a proof of identity, not of citizenship.
- Verify identity using Secure QR Code / Offline XML / Online Authentication.

- आधार देश भर में मान्य है।
- आधार कई सरकारी और गैर सरकारी सेवाओं को पाना आसान बनाता है।
- आधार में मोबाइल नंबर और ईमेल ID अपडेट रखें।
- आधार को अपने स्मार्ट फोन पर रखें, mAadhaar App के साथ।


- Aadhaar is valid throughout the country.
- Aadhaar helps you avail various Government and non-Government services easily.
- Keep your mobile number & email ID updated in Aadhaar.
- Carry Aadhaar in your smart phone – use mAadhaar App.



भारतीय विशिष्ट पहचान प्राधिकरण
Unique Identification Authority of India



Address: C/O Roshan Kumar, Flat No
201, H-Block, Vgn Stafford,
Thirumullaivoyal, Tiruvallur, Tamil
Nadu, 600062



3123 6093 1050



1947



help@uidai.gov.in



www.uidai.gov.in



MURUGAN HOSPITALS

HEALING HANDS



LAB REPORT

Patient Name : Mrs. ALPI BARANWAL

Age / Gender : 39 / Female

UHID ID : MH20210032253

Doctor Name : Dr. DMO

OP Report No. : INVA2103037

Bill No. : INV2105050

Sample Date : 05/11/2021 - 11:00 AM

Report Date : 06/11/2021 - 10:48 AM

Test Name	Result	Units	Reference Interval
HAEMATOLOGY			
Complete Blood Cell Count(CBC)			
HAEMOGLOBIN	<u>7.0</u>	gms/dl	male :13.0 - 17.0 female :12.0 - 15.0
PACKED CELL VOLUME	<u>23.6</u>	%	male : 40 - 50 female : 36 - 46
RBC COUNT	<u>3.25</u>	millions cells/cu.mm	female: 3.8 - 4.8 male : 4.5 - 5.5
TOTAL WBC	7,600	Cells/Cumm	4,000 - 11,000
Differential Count			
NEUTROPHILS	<u>72</u>	%	40 - 65
LYMPHOCYTES	<u>25</u>	%	30-50
EOSINOPHILS	03	%	01-06
MONOCYTES	<u>00</u>	%	1-10
BASOPHILS	00	%	0-2
ESR 60 MTS	<u>32</u>	mm	5 - 20
PLATELET COUNT	2.80	Lakhs/cumm	1.5 - 4.5
MCV	<u>72.9</u>	fL	76 - 96
MCH	<u>21.5</u>	pg	27 - 32
MCHC	<u>29.6</u>	gms/dl	30 - 36

INTERPRETATION: Test done on automated three part cell counter, all abnormal results are reviewed and confirmed microscopically.

BLOOD GROUPING & RH TYPING "AB" POSITIVE

Healing Hearts and Lives

264/125, Kilpauk Garden Road, Kilpauk, Chennai - 600 010.

Phone : +91 44 4644 8989 / 75500 53335 | Email : muruganhosp@gmail.com

Website : www.muruganhospitals.in



MURUGAN HOSPITALS

HEALING HANDS



LAB REPORT

Patient Name : Mrs. ALPI BARANWAL

Age / Gender : 39 / Female

UHID ID : MH20210032253

Doctor Name : Dr. DMO

OP Report No. : INVA2103037

Bill No. : INV2105050

Sample Date : 05/11/2021 - 11:00 AM

Report Date : 05/11/2021 - 06:57 PM

Test Name	Result	Units	Reference Interval
BIO CHEMISTRY			
BLOOD SUGAR FASTING	93	mgs/dl	70-110
BLOOD SUGAR POST PRANDIAL	95	mgs/dl	80- 160
SERUM URIC ACID	<u>6.0</u>	mg/dl	male 3.1-7.0 , female 2.5-5.6
SERUM CREATININE	<u>0.6</u>	mg/dl	0.7-1.4
LIPID PROFILE			
TOTALCHOLESTEROL	174	mg/dl	< 200
TRIGLYCERIDE	93	mg/dl	< 150
HDL	41	mg/dl	35 - 80
VLDL	19	mg/dl	2 to 30
LDL	114	mg/dl	<130
CHOLESTEROL/ HDL RATIO	4.2	mg/dl	

Healing Hearts and Lives

264/125, Kilpauk Garden Road, Kilpauk, Chennai - 600 010.

Phone : +91 44 4644 8989 / 75500 53335 | Email : muruganhosp@gmail.com

Website : www.muruganhospitals.in



MURUGAN HOSPITALS

HEALING HANDS



LAB REPORT

Patient Name : Mrs. ALPI BARANWAL
 Age / Gender : 39 / Female
 UHID ID : MH20210032253
 Doctor Name : Dr. DMO

OP Report No. : INVA2103037
 Bill No. : INV2105050
 Sample Date : 05/11/2021 - 11:00 AM
 Report Date : 05/11/2021 - 06:57 PM

Test Name	Result	Units	Reference Interval
LIVER FUNCTION TEST			
BILLIRUBIN(TOTAL)	0.5	mg/dl	0.0 -1.0
BILLIRUBIN(DIRECT)	0.2	mg/dl	0.1- 0.30
BILLIRUBIN(INDIRECT)	0.3	mg/dl	0.2-0.8
SGOT	19	IU/L	0-38
SGPT	10	IU/L	0.0-40
ALKALINE PHOSPHATASE	88	IU/L	40-140
			4-6Years 93-309
			13-15Years 74-390
TOTAL PROTEIN	7.0	gm/dl	6.6-8.7
ALBUMIN	4.0	gm/dl	3.5 - 5.5
GLOBULIN	3.0	gm/dl	2.0-3.5
AG RATIO	1.3		
GAMMA G T	10	U/L	male<49 female<32
BLOOD UREA NITROGEN	7.0	mg/dl	7-21
HBA1C	5.6	%	normal: <6.0 good control: 6.1-7.0 fair control: 7.1- 8.0 poor control:8.1 -10.0 unsatisfactory: >10.0

Healing Hearts and Lives

264/125, Kilpauk Garden Road, Kilpauk, Chennai - 600 010.
 Phone : +91 44 4644 8989 / 75500 53335 | Email : muruganhosp@gmail.com
 Website : www.muruganhospitals.in



MURUGAN HOSPITALS

HEALING HANDS



LAB REPORT

Patient Name : Mrs. ALPI BARANWAL

Age / Gender : 39 / Female

UHID ID : MH20210032253

Doctor Name : Dr. DMO

OP Report No. : INVA2103037

Bill No. : INV2105050

Sample Date : 05/11/2021 - 11:00 AM

Report Date : 05/11/2021 - 06:57 PM

Test Name	Result	Units	Reference Interval
<u>CLINICAL PATHOLOGY</u>			
URINE SUGAR (F)	NIL		
URINE SUGAR (PP)	NIL		
URINE ROUTINE			
COLOUR	YELLOW		
APPEARANCE	CLEAR		
REACTION	ACIDIC		
SUGAR	NIL		
ALBUMIN	NIL		
DEPOSITES			
PUS CELLS	1 - 2	/ HPF	
EPI CELLS	2- 3	/ HPF	
RBC COUNT	NIL	/ HPF	
CAST	NIL		
CRYSTALS	NIL		
OTHERS	NIL		
<u>ENDOCRINOLOGY</u>			
T3	0.740	ng/ml	0.52-1.85
T4	12.053	ug/dl	5.0 -13.0 ug/dl
TSH	4.547	uIU/ml	0.39 - 6.16 uiu/ml

Healing Hearts and Lives

264/125, Kilpauk Garden Road, Kilpauk, Chennai - 600 010.

Phone : +91 44 4644 8989 / 75500 53335 | Email : muruganhosp@gmail.com

Website : www.muruganhospitals.in



MURUGAN HOSPITALS

HEALING HANDS



LAB REPORT

Patient Name : Mrs. ALPI BARANWAL
Age / Gender : 39 / Female
UHID ID : MH20210032253
Doctor Name : Dr. DMO


OP Report No. : INVA2103037
Bill No. : INV2105050
Sample Date : 05/11/2021 - 11:00 AM
Report Date : 05/11/2021 - 06:57 PM

Test Name	Result	Units	Reference Interval
-----------	--------	-------	--------------------

SHENBAGAVALLI

Verified by

*** End of Report ***



Authorized Signature

Dr. PAVITHRA, MD.
Pathologist
Reg. No.: 78256

Healing Hearts and Lives

264/125, Kilpauk Garden Road, Kilpauk, Chennai - 600 010.
Phone : +91 44 4644 8989 / 75500 53335 | Email : muruganhosp@gmail.com
Website : www.muruganhospitals.in




MURUGAN HOSPITALS

HEALING HANDS



LAB REPORT

Reg.ID : I - 31429
 Patient Name : MRS. ALPI BARANWAL
 Contact No : -
 Age : 39 (Female)
 Referral : DR. ARUN PRAKASH S.
 Source : MURUGAN HOSPITALS
 Report ID : 45821

Reg. Date : Nov 07, 2021, 10:30 a.m.
 Sample Date : Nov 07, 2021, 10:32 a.m.
 Report Date : Nov 07, 2021, 12:19 p.m.
 Print Date : Nov 07, 2021, 02:36 p.m.
 Sample ID : 
 1921110148

Test Description	Value(s)	Reference Range
------------------	----------	-----------------

TEST REPORT

CLINICAL PATHOLOGY

STOOL ANALYSIS

MACROSCOPIC EXAMINATION

Colour : Yellowish
 Consistency : Semisolid
 Reaction (pH) : Alkaline
 Mucus : Absent
 Blood : Absent

MICROSCOPIC EXAMINATION

Pus cells : 1-2/hpf
 Epithelial cells : Nil
 Rbc : Nil
 Ova : Nil
 Cyst : Nil
 Trophozoites : Nil
 Others : Bacteria present

END OF REPORT

Dr. Hema Vaneeswari. C., MD
 CONSULTANT PATHOLOGIST

Note: All Lab test values are subjective and may have variation in context to age, gender and clinical status. The reference values given are a guidance, all variations in test values are to be interpreted with clinical correlation and physician's advice.

Healing Hearts and Lives

264/125, Kilpauk Garden Road, Kilpauk, Chennai - 600 010.

Phone : +91 44 4644 8989 / 75500 53335 | Email : muruganhosp@gmail.com

Website : www.muruganhospitals.in

ID : 2111050008
Name : MRS ALPIBARANWAL
Sex : Male
Divisions :

Date Time : 2021-11-05 11:37
Age : 39
BP : 110/70 mmHg
Bed No. :

Patient ID :
Height : 161 cm
Weight : 56 kg
Hospital No. :

Hospital : MURUGAN HOSPITAL

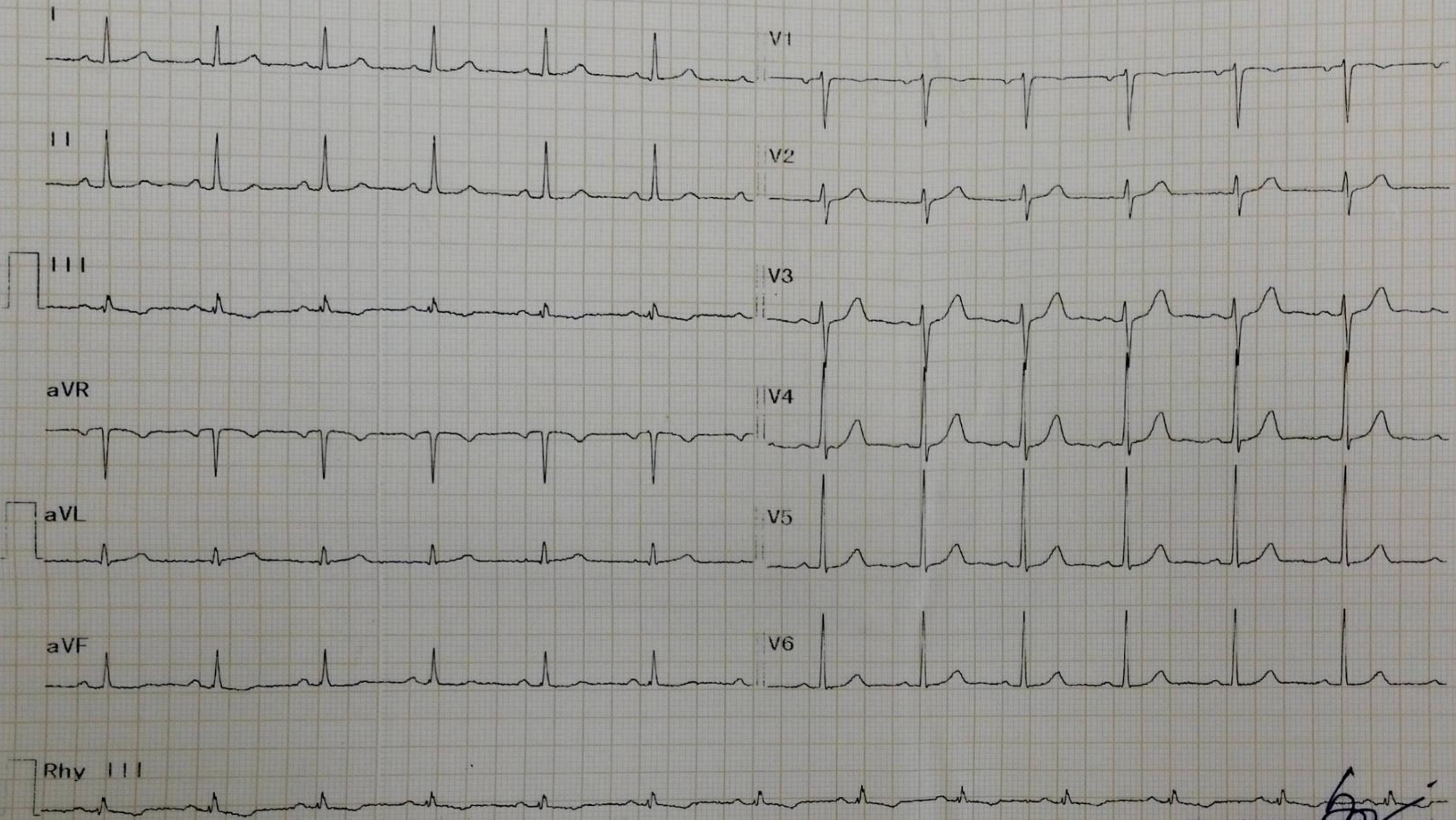
HR : 80 bpm
P Dur PR int : 95 149ms
QRS Dur : 85 ms
QT QTc int : 348 403 ms
P QRS T axis : 60 45 8 °

RV5 SV1 amp : 1.875 1.060mV
RV5+SV1 amp : 2.935mV
RV6 SV2 amp : 1.454 0.440mV

Minnesota Code

Diagnosis Info
800: Sinus Rhythm

Normal ECG



Dr. SIDHARTHAN, MD., DM.

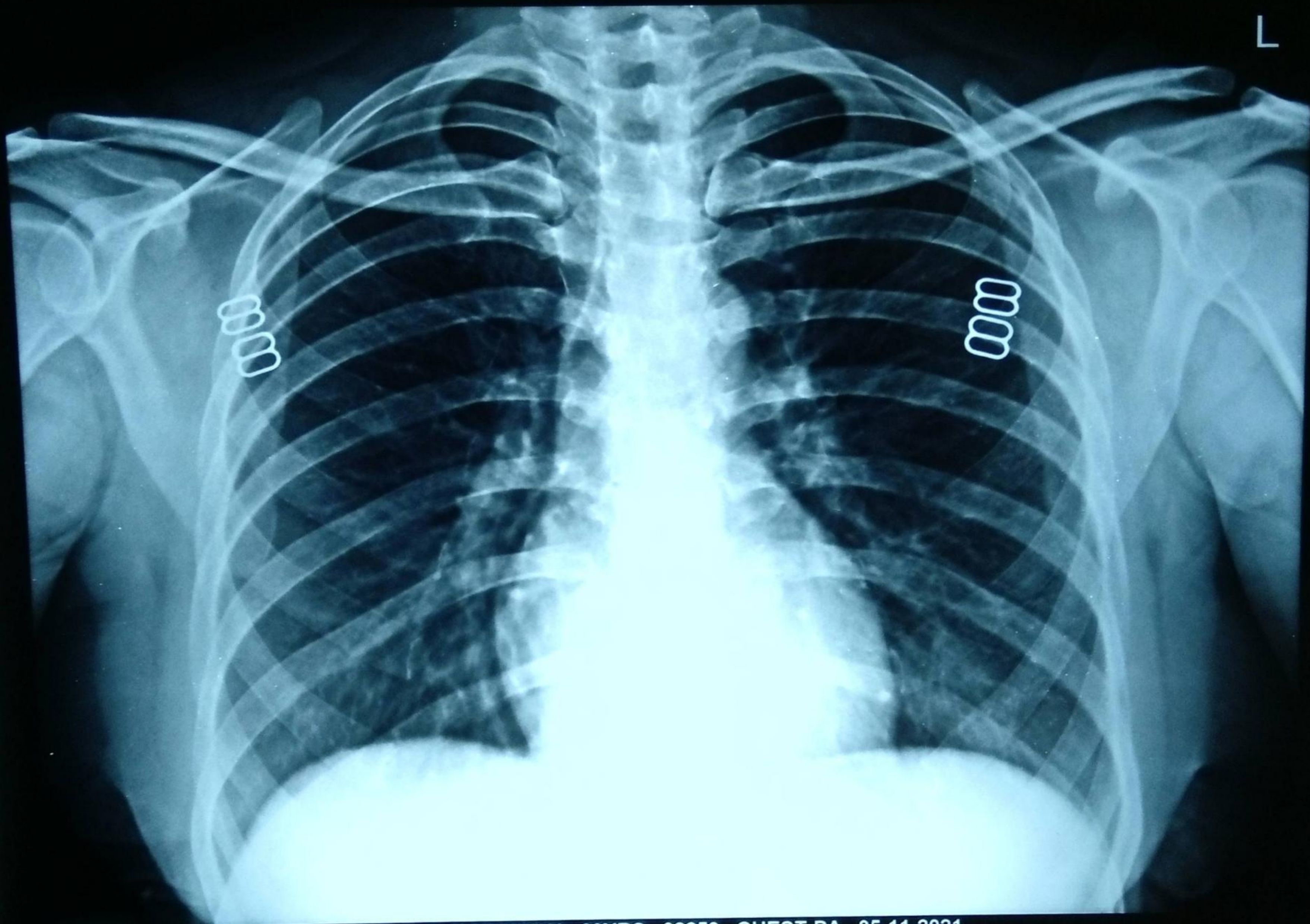
Consultant Cardiologist

Reg. No. 62979

Diagnosis for reference. ask your doctor to confirm
AUTO PRINT 6X2+1R 80bpm 10 mm mV 0.50Hz-45Hz AC 50Hz 25 mm sec

Confirmed By: _____

MICRO MED CHARTS OF BU1493/1194



MRS.ALPI BARANWAL 39YRS 32253 CHEST-PA 05-11-2021
MURUGAN HOSPITALS, KILPAUK,CHENNAI-10 PH NO: 7550053335/ 46448989



MURUGAN HOSPITALS

HEALING HANDS



SCAN REPORT

NAME :Mrs.ALPI BARANWAL

AGE / SEX : 39/YFEMALE

CONSULTANT: DR. ARUN PRAKSH

UHID NO: MH20210032253

DATE : 05- 11- 2021

OP /IP :OUT PATIENT

CHEST XRAY PA VIEW

- Trachea is in midline.
- Hila appear Normal.
- Mediastinal shadow appears normal.
- Costophrenic&Cardiophrenic angles appear free.
- Cardiothoracic ratio is within normal limits.
- Lungs fields appear clear
- Bony thorax and soft tissue appear normal

IMPRESSION:

- **No significant abnormality noted.**



CONSULTANT RADIOLOGIST

Healing Hearts and Lives

264/125, Kilpauk Garden Road, Kilpauk, Chennai - 600 010. Phone : +91 44 4644 8989 / 75500 53335

Email : muruganhosp@gmail.com | Website : www.muruganhospitals.in



MURUGAN HOSPITALS
HEALING HANDS

Date : 05/11/2021

NAME OF PATIENT : Mrs.Alpi baranwal

AGE : 39/ Y/FEMALE

Nil visual complaints

O/E

V/A

OD : 6/6 N6

OS : 6/6 N6

Within normal limits in both eyes.

IMPRESSION :

- Nil ophthalmic problem



Medical Officer

264/125, Kilpauk Garden Road, Kilpauk, Chennai - 600 010.

☎ : +91 44 4644 8989 / 75500 53335 email : muruganhosp@gmail.com

Website : www.muruganhospitals.in



MURUGAN HOSPITALS

HEALING HANDS



ECHO CARDIOGRAM REPORT

NAME: MRS.ALPI BARAMAAR

UHID NO: MH20210032253

AGE&SEX : 39Y /FEMALE

IP/OP : OUT PATIENT

CONSULTANT: DR.ARUN PRAKASH

DATE : 05-11-2021

2D PLAX (mm)

RV - 29 mm
AO - 30 mm
LA - 31 mm

COLOR DOPPLER

Normal

M-Mode (mm)

IVS - 08 mm
PW - 08 mm
LVD - 44 mm
LVS - 27 mm
EF - 69%
FS - 39%

DOPPLER (m/sec)

MITRAL E - 0.1 m/s
MITRAL A - 0.7 m/s
PULMONARY - 0.7 m/s
AORTIC - 1.3 m/s
TRICUSPID - 0.3 m/s

IMPRESSION:

No RWMA
Normal biventricular function
No pulmonary hypertension
No pericardial effusion
No clot/ Vegetation.



DR. S. DHARTHAN MD.,DM.,
CONSULTANT CARDIOLOGIST

Healing Hearts and Lives

264/125, Kilpauk Garden Road, Kilpauk, Chennai - 600 010.
Phone : +91 44 4644 8989 / 75500 53335 | Email : muruganhosp@gmail.com
Website : www.muruganhospitals.in



SCAN REPORT

NAME : MRS.ALPIBARNWAL
AGE / SEX : 39Y/FEMALE
CONSULTANT: DR.ARUN PRAKASH

UHID NO :MH20210032253
IP / OP NO:OUTPATIENT
DATE :09.11.2021

ULTRASOUND SCAN OF ABDOMEN

LIVER: Mildly enlarged in size and measures- 15.1 cm and increased in echotexture. No focal lesions are seen. No dilatation of intra-hepatic biliary radicals present. Hepatic veins and IVC appear normal. Portal vein is normal in caliber. Common bile duct is normal in caliber.

GALL BLADDER: Normal in size and wall thickness. No evidence of any calculus or mass present. No evidence of pericholecystic collections.

PANCREAS: Normal in size and echotexture. No focal lesions are seen. No evidence of calculi or calcifications. No evidence of pancreatic duct dilation.

PARA AORTIC AREAS: Aorta and IVC appear normal. No evidence of para aortic lymphadenopathy.

SPLEEN: Mildly enlarged in size and measures- 13.0 cm . Normal in echotexture. No evidence of focal lesions.

RIGHT KIDNEY: Measures 11.2 X 4.1 cm and is normal in size and echotexture. Cortico medullary differentiation is well maintained. There is no hydronephrosis or mass.

LEFT KIDNEY: Measures 9.9 X 4.3 cm and is normal in size and echotexture. Cortico medullary differentiation is well maintained. There is no hydronephrosis or mass.

Healing Hearts and Lives

264/125, Kilpauk Garden Road, Kilpauk, Chennai - 600 010. Phone : +91 44 4644 8989 / 75500 53335
Email : muruganhosp@gmail.com | Website : www.muruganhospitals.in

URINARY BLADDER: Normal in size, contour and wall thickness. There is no evidence of calculus or mass. No vesical diverticulum present.

UTERUS AND OVARES: Measures- 5.1 x 3.9 cm normal in size and normal in echotexture. ET- 3.9 mm.

Right ovary measures- 2.4 x 2.1 cm.

Left ovary measures- 3.0 x 2.0 cm.

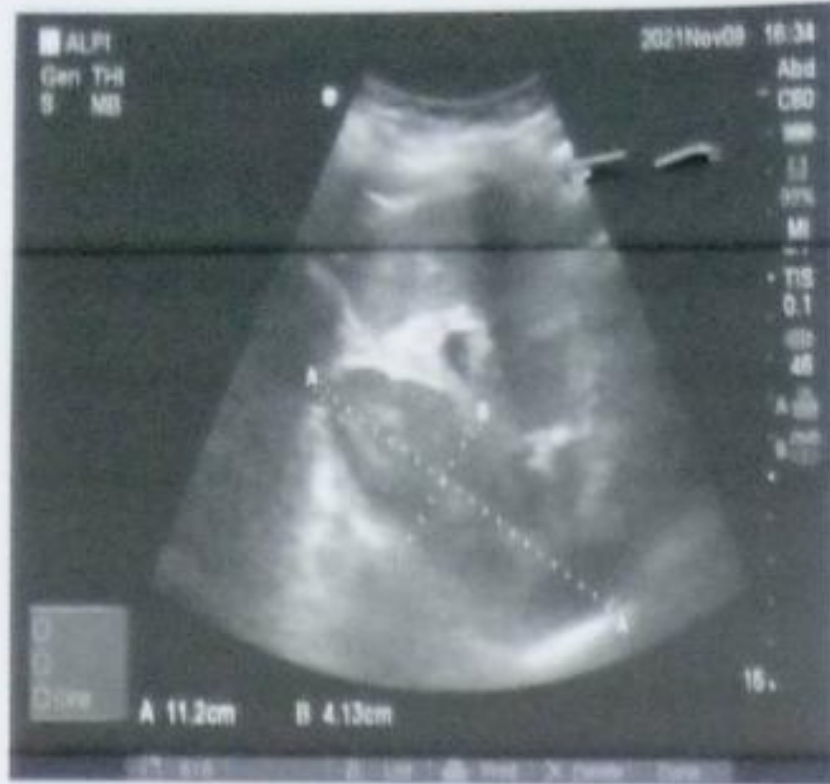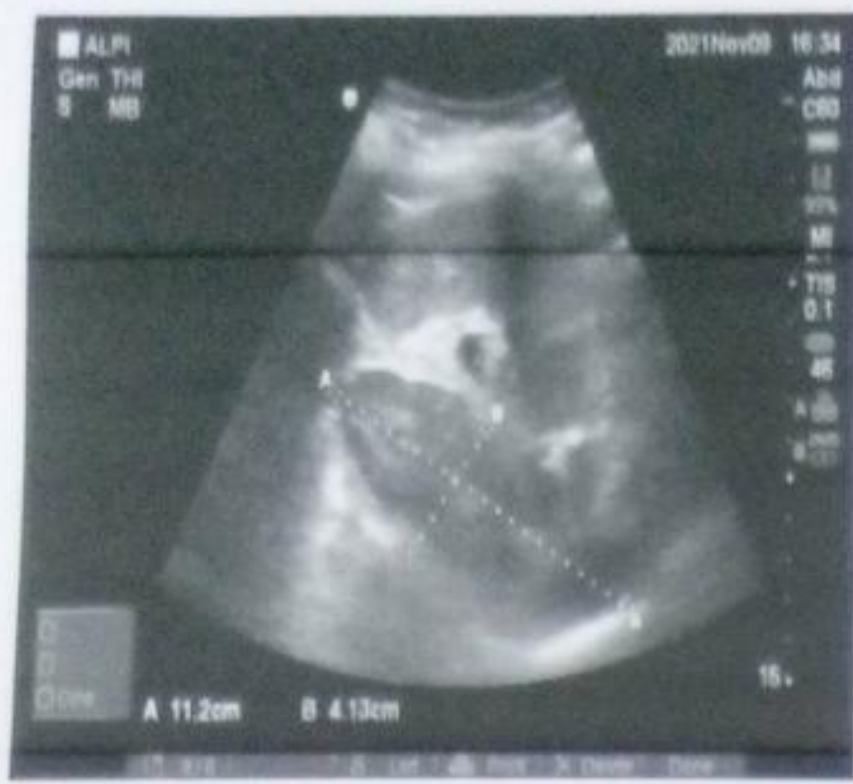Both ovaries are normal.

IMPRESSION:

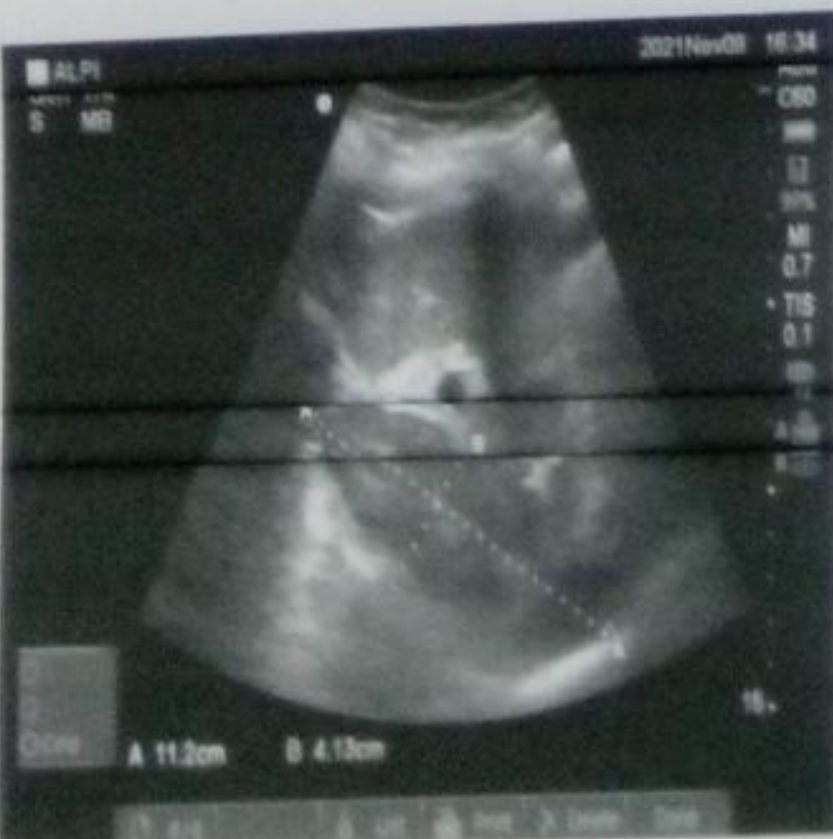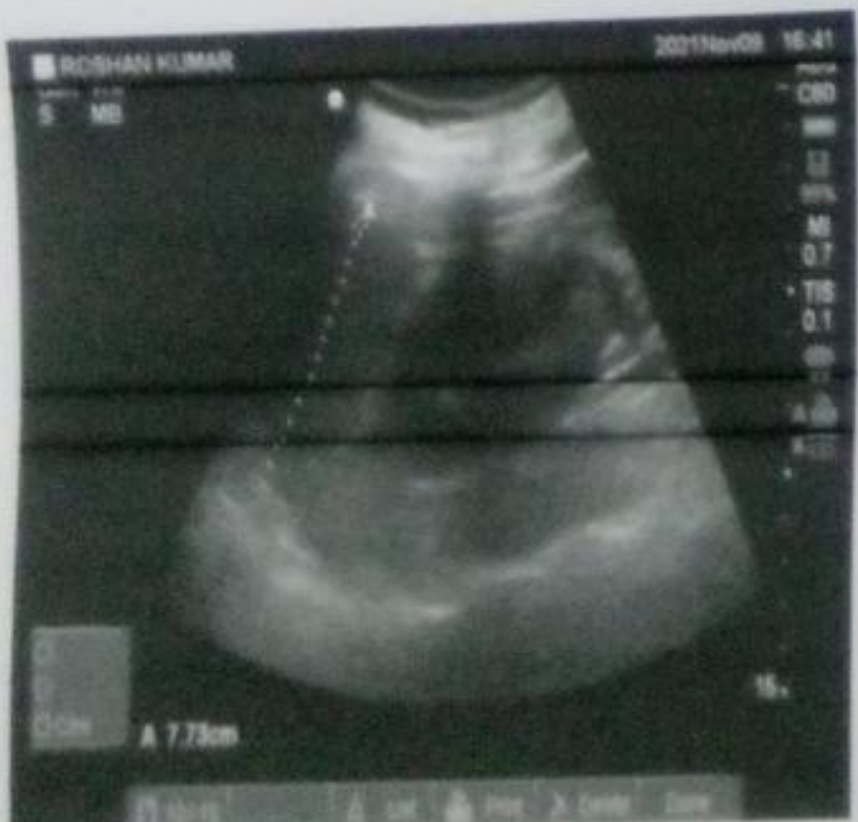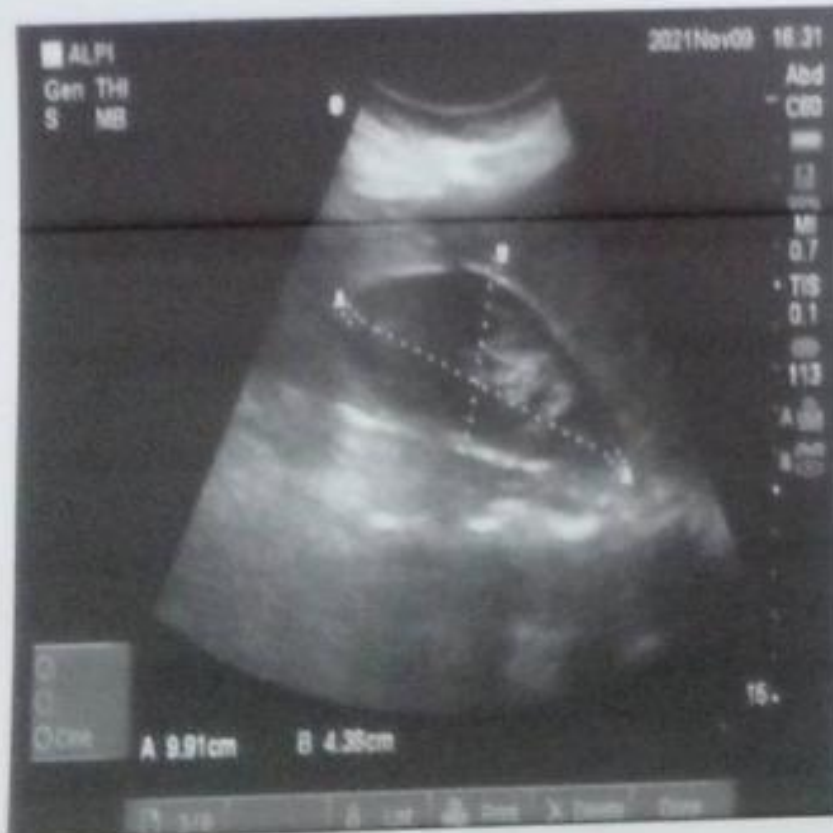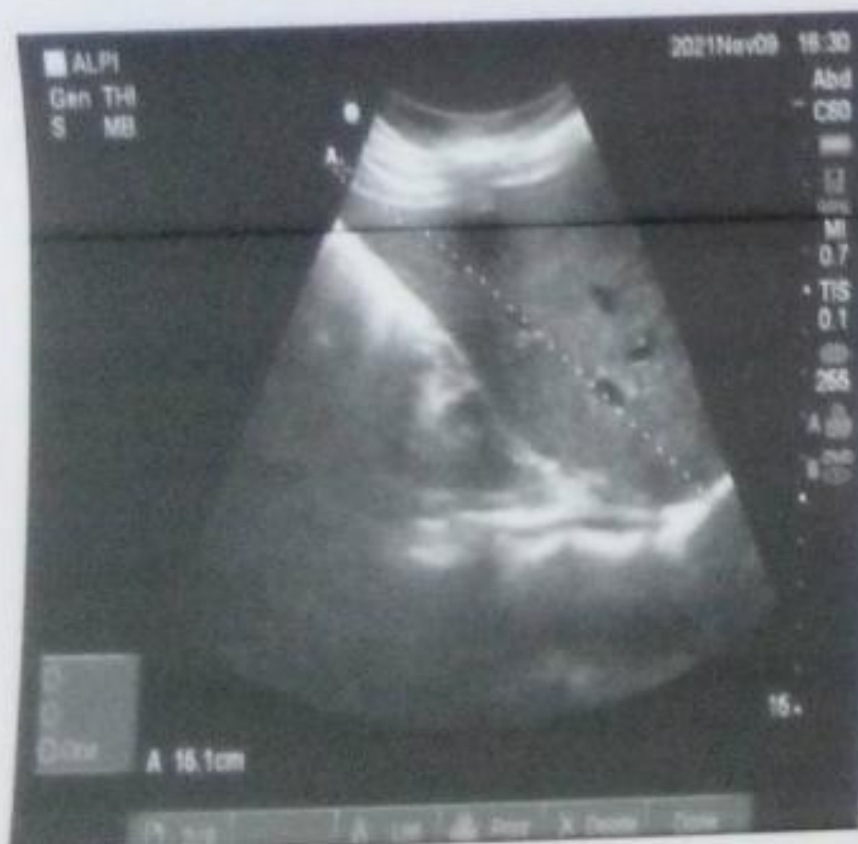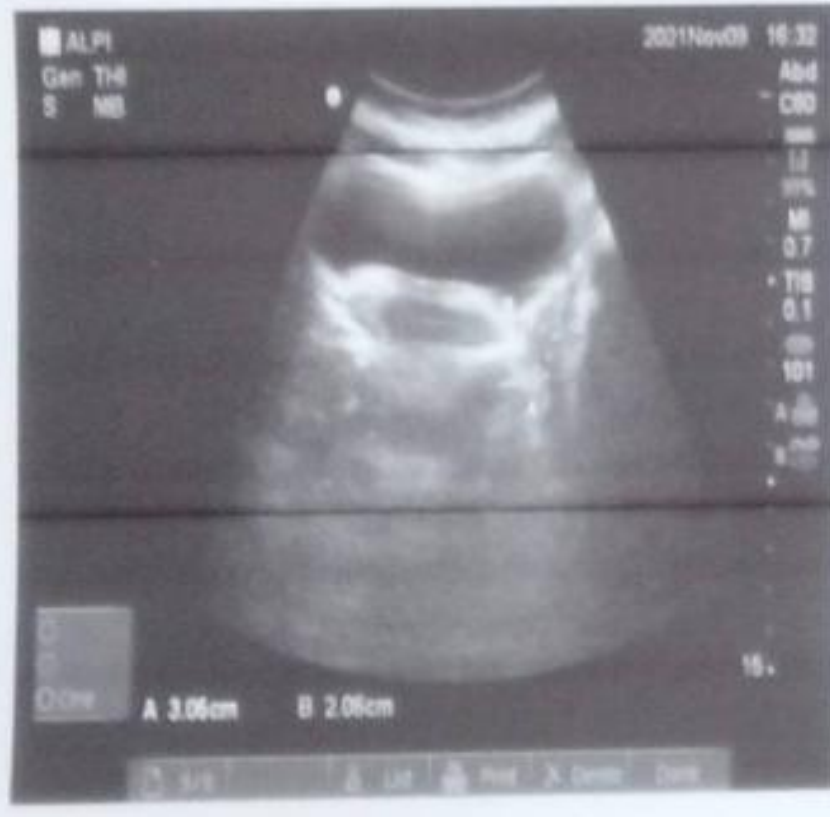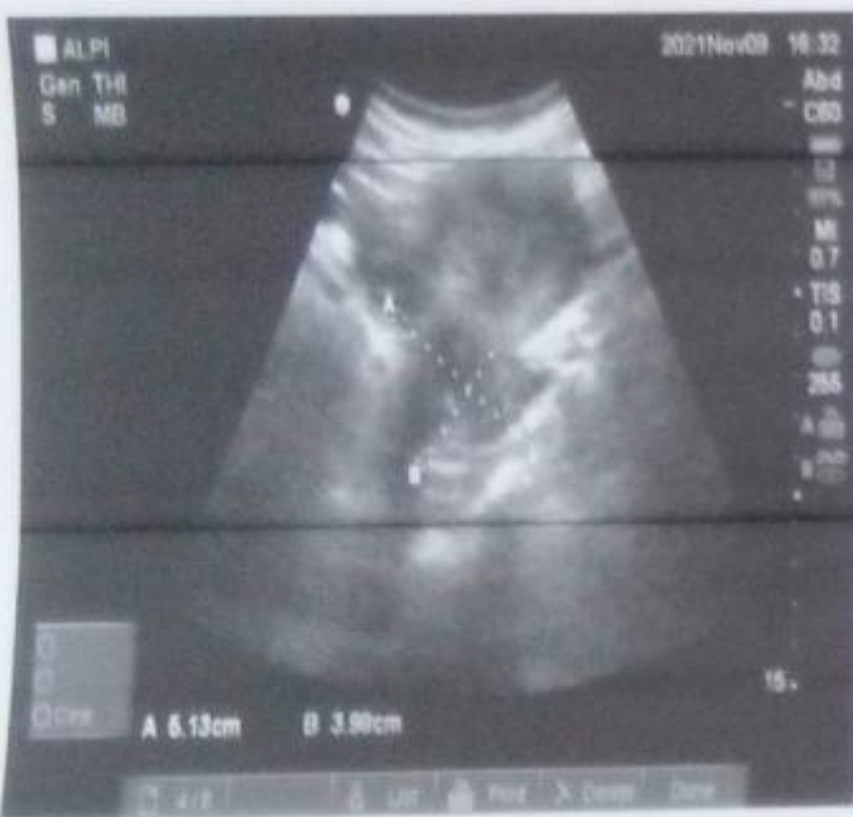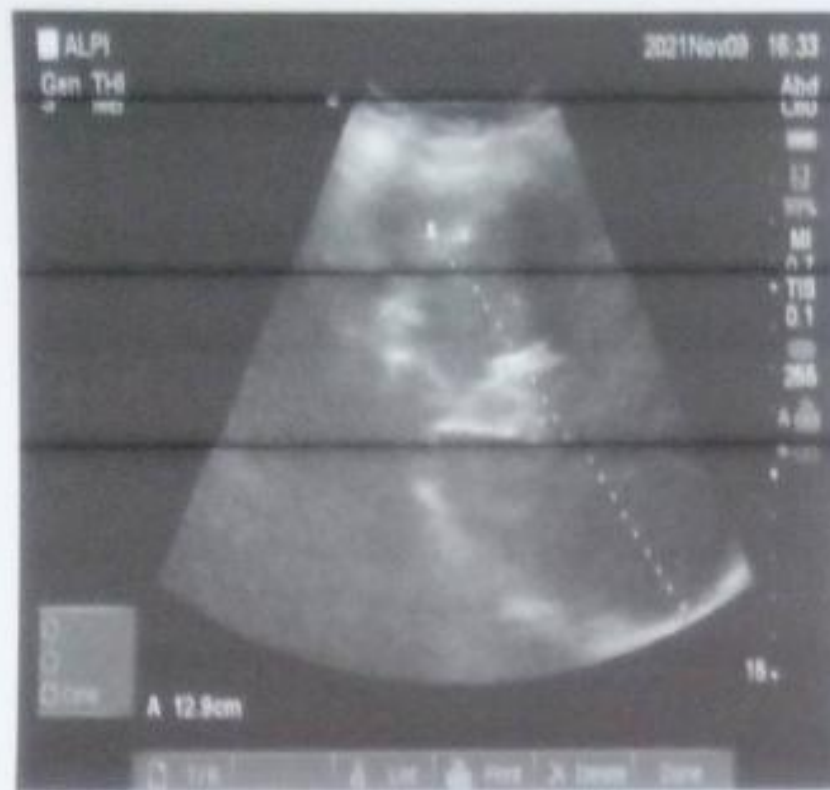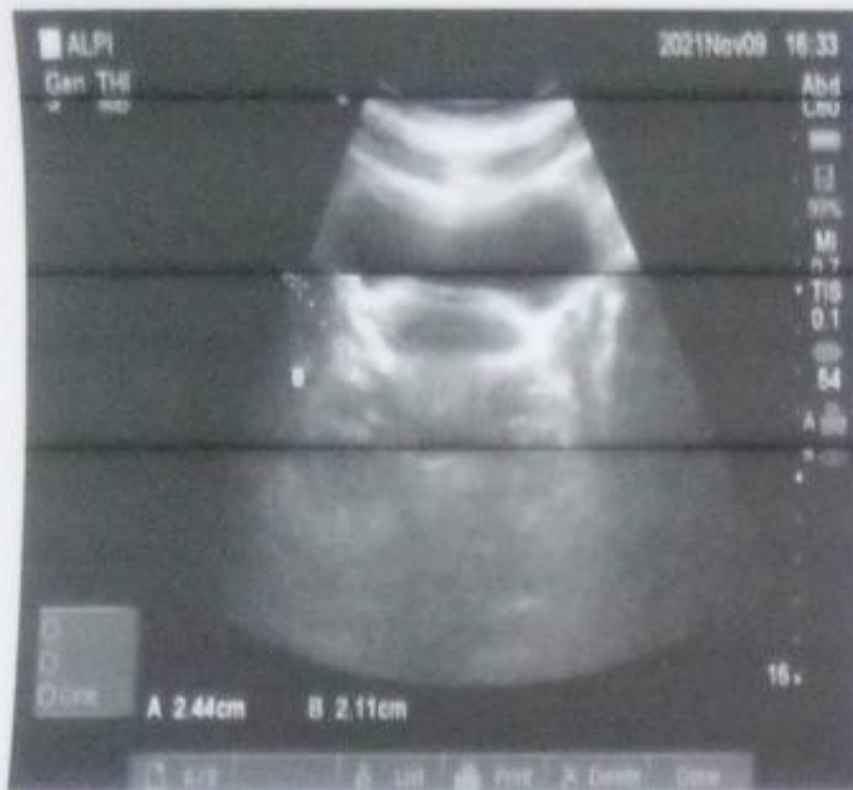- ✓ *Mild hepatomegaly with fatty infiltration.*
- ✓ *Mild splenomegaly*



*Dr. SAKTHI MDRD.,
Consultant Radiologist.*



ALPI





MURUGAN HOSPITALS

HEALING HANDS

Mrs. Alpi Baranwal, 39 years old / Female

- No dental carries
- Tonsils Normal
- No deviated nasal septum
- Throat is normal



Dr. Rathiga

264/125, Kilpauk Garden Road, Kilpauk, Chennai - 600 010.

☎ : +91 44 4644 8989 / 75500 53335 email : muruganhosp@gmail.com

Website : www.muruganhospitals.in