



MRS VISHU SINGHA

28/1/23

35 y/f

Vitals :

Chief Complaints :

Routine eyes checkup

H/O Present Illness :

VM { 6/6 unaddd

Past History :

MV { MG  
N6

MCT { 14  
14

Investigation :

Drug Allergies : (if any)

Colour Vision - Normal BE

Treatment :

Fundus - Normal

28/1/2023

P<sub>1</sub> - FTND - 4½ yrs old.

Cycles 4-5/24-25 flow (N)


LMP 16/1/23

Epo while discharge & itching for 6 months  
itching ↑ before periods.

P<sub>2</sub> P/S (H)  
WAVNS free to free

✓ PAP Smear taken

Tab Fluconazole 150mg stat  
Rpl after 3 days.  
Candida ~~tab~~ 1 HS x 6 day.  
Vaginal penary



(This is only professional opinion and not the diagnosis, Please correlate clinically)

Q Block South City 11, Sohna Road, Main Sector-47, Gurgaon, Haryana

Ph.: 0124-4900000 (100 Lines) Fax : 0124-2218733 E-mail : parkmedcenters@gmail.com

PARK GROUP OF HOSPITALS : West Delhi • South Delhi • Gurgaon • Karnal • Panipat • Hodal • Ambala • Behror

the **health** care providers

the **health** care providers





## DEPARTMENT OF PATHOLOGY

Patient Name : Ms. VISHU SINGLA  
 MR No : 670715  
 Age/Sex : 35 Years 5 Months 3 Days / Female  
 Type : OPD  
 TPA/Corporate : MEDIWHEEL PVT LTD

Bill Date : 28/01/2023  
 Reporting Date : 29/01/2023  
 Sample ID : 92837  
 Bill/Req. No. : 24031728  
 Ref Doctor : Dr.RMO

Test	Result	Bio. Ref. Interval	Units	Method
------	--------	--------------------	-------	--------

### THYROID PROFILE

TRI-IODOETHYRONINE (T3)	1.18	0.60 - 1.81	ng/ml	Chemiluminescence
THYROXINE (T4)	10.4	5.01 - 12.45	µg/dL	Chemiluminescence
THYROID STIMULATING HORMONE	2.08	0.5-5.50	µIU/ml	
SPECIMEN TYPE	SERUM			

Method : chemiluminescent immunoassay

**Note : Clinical Significance:**

Thyroid function tests (TFTs) is a collective term for blood tests used to check the function of the thyroid. TFTs may be requested if a patient is thought to suffer from hyperthyroidism (overactive thyroid) or hypothyroidism (underactive thyroid), or to monitor the effectiveness of either thyroid-suppression or hormone replacement therapy. It is also requested routinely in conditions linked to thyroid disease, such as atrial fibrillation and anxiety disorder. A TFT panel typically includes thyroid hormones such as thyroid-stimulating hormone (TSH, thyrotropin) and thyroxine (T4), and triiodothyronine (T3) depending on local laboratory policy.

Note: Please correlate with clinical condition

\*\*\*\*\* END OF THE REPORT \*\*\*\*\*



Sample no.

Dr. SONIA KUMARI  
 MBBS, MD (PATHOLOGY) Gold medalist

Dr. PRADIP KUMAR  
 Consultant (Microbiology)

Dr. NISHA TIWARI  
 MBBS, MD (Microbiology)

USER NM DINESH

(This is only professional opinion and not the diagnosis. Please correlate clinically)

Page 1 of 1

Q Block South City 11, Sohna Road, Main Sector-47, Gurgaon, Haryana  
 Ph.: 0124-4900000 (100 Lines) Fax : 0124-2218733 E-mail : parkmedicenters@gmail.com

PARK GROUP OF HOSPITALS : West Delhi • South Delhi • Gurgaon • Karnal • Panipat • Hodal • Ambala • Behror

the **health** care providers

the **health** care providers





Cert. No. MC - 4830



Cert. No. H-2016-0369

**DEPARTMENT OF PATHOLOGY**

Patient Name : Ms. VISHU SINGLA  
MR No : 670715  
Age/Sex : 35 Years 5 Months 3 Days / Female  
Type : OPD  
TPA/Corporate : MEDIWHEEL PVT LTD

Bill Date : 28/01/2023  
Reporting Date : 30/01/2023  
Sample ID : 92837  
Bill/Req. No. : 24031728  
Ref Doctor : Dr.RMO

Test	Result	Bio. Ref. Interval	Units	Method
<b>URINE C/S</b>				

NAME OF SPECIMEN	URINE	
ORGANISM IDENTIFIED	NO GROWTH SEEN IN CULTURE AFTER 48 HRS OF INCUBATION AT 37 C DEGREE.	Aerobic culture

Method : .

Note : .

\*\*\*\*\* END OF THE REPORT \*\*\*\*\*



Sample no.

Dr. SONIA KUMARI  
MBBS, MD (PATHOLOGY) Gold medalist

Dr. PRADIP KUMAR  
Consultant (Microbiology)

Dr. NISHA TIWARI  
MBBS, MD (Microbiology)

USER NM ANJALIPA911

(This is only professional opinion and not the diagnosis, Please correlate clinically) Page 1 of 1

Q Block South City 11, Sohna Road, Main Sector-47, Gurgaon, Haryana  
Ph.: 0124-4900000 (100 Lines) Fax : 0124-2218733 E-mail : parkmedicenters@gmail.com

**PARK GROUP OF HOSPITALS : West Delhi • South Delhi • Gurgaon • Karnal • Panipat • Hodal • Ambala • Behror**

the **health** care providers

the **health** care providers





Cert. No. MC - 4830



Cert. No. H-2015-0369

**DEPARTMENT OF PATHOLOGY**

Patient Name : Ms. VISHU SINGLA  
MR No : 670715  
Age/Sex : 35 Years 5 Months 3 Days / Female  
Type : OPD  
TPA/Corporate : MEDIWHEEL PVT LTD

Bill Date : 28/01/2023  
Reporting Date : 28/01/2023  
Sample ID : 92837  
Bill/Req. No. : 24031728  
Ref Doctor : Dr.RMO

Test	Result	Blo. Ref. Interval	Units	Method
<b>BLOOD SUGAR 2 HR. PP</b>				
BLOOD SUGAR P.P.	123	80 - 150	mg/dl	

\*\*\*\*\* END OF THE REPORT \*\*\*\*\*



Sample no.

**Dr. SONIA KUMARI**  
MBBS, MD (PATHOLOGY) Gold medalist

**Dr. PRADIP KUMAR**  
Consultant (Microbiology)

**Dr. NISHA TIWARI**  
MBBS, MD (Microbiology)

USER NM SONU

(This is only professional opinion and not the diagnosis, Please correlate clinically)

Q Block South City 11, Sohna Road, Main Sector-47, Gurgaon, Haryana Page 1 of 1  
Ph.: 0124-4900000 (100 Lines) Fax : 0124-2218733 E-mail : parkmedicenters@gmail.com

**PARK GROUP OF HOSPITALS : West Delhi • South Delhi • Gurgaon • Karnal • Panipat • Hodal • Ambala • Behror**

the **health** care providers the **health** care providers





## DEPARTMENT OF PATHOLOGY

Patient Name : Ms. VISHU SINGLA  
 MR No : 670715  
 Age/Sex : 35 Years 5 Months 3 Days / Female  
 Type : OPD  
 TPA/Corporate : MEDIWHEEL PVT LTD

Bill Date : 28/01/2023 10:29 AM  
 Sample Col Dt/Tm : 28/01/2023 10:39 am  
 Sample Rec Dt/Tm : 28/01/2023 10:39 am  
 Reporting Date : 2023-01-28 00:00:00-01 12:31:  
 Sample ID : 92837  
 Bill/Req. No. : 24031728

Ref Doctor : Dr.RMO

Test	Result	Bio. Ref. Interval	Units	Method
<b>BLOOD SUGAR FASTING</b>				
PLASMA GLUCOSE FASTING	91	60 - 110	mg/dl	GOD TRINDERS

\*\*\*\*\* END OF THE REPORT \*\*\*\*\*



Dr. PRADIP KUMAR  
 Consultant (Microbiology)

Dr. SONIA KUMARI  
 MD Pathology (Gold Medalist)

Dr. NISHA TIWARI  
 MBBS, MD (Microbiology)  
 USER NM SONU

(This is only professional opinion and not the diagnosis, Please correlate clinically)

Q Block South City 11, Sohna Road, Main Sector-47, Gurgaon, Haryana  
 Ph.: 0124-4900000 (100 Lines) Fax : 0124-2218733 E-mail : parkmedicenters@gmail.com

PARK GROUP OF HOSPITALS : West Delhi • South Delhi • Gurgaon • Karnal • Panipat • Hodal • Ambala • Behror

the **health** care providers the **health** care providers



Cert. No. MC - 4830



Cert. No. H-2015-0369

## DEPARTMENT OF PATHOLOGY

Patient Name : Ms. VISHU SINGLA

MR No : 670715

Age/Sex : 35 Years 5 Months 3 Days / Female

Type : OPD

TPA/Corporate : MEDIWHEEL PVT LTD

Bill Date : 28/01/2023

Reporting Date : 28/01/2023

Sample ID : 92837

Bill/Req. No. : 24031728

Ref Doctor : Dr.RMO

Test	Result	Bio. Ref. Interval	Units	Method
<b>STOOL ROUTINE AND MICROSCOPY</b>				
STOOL ROUTINE AND MICROSCOPY				
COLOUR	Yellow	Pale Yellow		Vishal
CONSISTENCY	Semi Solid	Formed		Manual
OCCULT BLOOD	NIL	NIL		Guaiac test
MUCUS	NIL	NIL		Microscopic
PUS CELL	1-2	0-5	cells/hpf	Microscopic
RBCS	NIL	NIL		
CYSTS	NIL	NIL		Microscopic
OVA	NIL	Nii		Microscopic

\*\*\*\*\* END OF THE REPORT \*\*\*\*\*



Sample no.

Dr. SONIA KUMARI  
MBBS, MD (PATHOLOGY) Gold medalist

Dr. PRADIP KUMAR  
Consultant (Microbiology)

Dr. NISHA TIWARI  
MBBS, MD (Microbiology)

USER NM NEERAJPA752

(This is only professional opinion and not the diagnosis. Please correlate clinically)

Q Block South City 11, Sohna Road, Main Sector-47, Gurgaon, Haryana

Ph.: 0124-4900000 (100 Lines) Fax : 0124-2218733 E-mail : parkmedicenters@gmail.com

Page 1 of 1

PARK GROUP OF HOSPITALS : West Delhi • South Delhi • Gurgaon • Karnal • Panipat • Hodal • Ambala • Behror

the **health** care providers

the **health** care providers





**DEPARTMENT OF PATHOLOGY**

Patient Name : Ms. VISHU SINGLA  
MR No : 670715  
Age/Sex : 35 Years 5 Months 3 Days / Female  
Type : OPD  
TPA/Corporate : MEDIWHEEL PVT LTD

Bill Date : 28/01/2023  
Reporting Date : 28/01/2023  
Sample ID : 92837  
Bill/Req. No. : 24031728  
Ref Doctor : Dr.RMO

Test	Result	Blo. Ref. Interval	Units	Method
<b>BLOOD GROUPING AND RH FACTOR</b>				
BLOOD GROUP	* B * RH POSITIVE			MATRIX GEL

\*\*\*\* END OF THE REPORT \*\*\*\*



Sample no.

Dr. SONIA KUMARI  
MBBS, MD (PATHOLOGY) Gold medalist

Dr. PRADIP KUMAR  
Consultant (Microbiology)

Dr. NISHA TIWARI  
MBBS, MD (Microbiology)

USER NM SONU

(This is only professional opinion and not the diagnosis, Please correlate clinically)

Q Block South City 11, Sohna Road, Main Sector-47, Gurgaon, Haryana  
Ph: 0124-4900000 (100 Lines) Fax: 0124-2218733 E-mail: parkmedcenters@gmail.com

Page 1 of 1

PARK GROUP OF HOSPITALS : West Delhi • South Delhi • Gurgaon • Karnal • Panipat • Hodal • Ambala • Behror

the **health** care providers

the **health** care providers





NABL  
Cert. No. MC - 4830



NABH  
Cert. No. H-2016-0369

## DEPARTMENT OF PATHOLOGY

Patient Name : Ms. VISHU SINGLA  
MR No : 670715  
Age/Sex : 35 Years 5 Months 3 Days / Female  
Type : OPD  
TPA/Corporate : MEDIWHEEL PVT LTD

Bill Date : 28/01/2023  
Reporting Date : 28/01/2023  
Sample ID : 92837  
Bill/Req. No. : 24031728  
Ref Doctor : Dr.RMO

Test	Result	Blo. Ref. Interval	Units	Method
<b>CBC</b>				
HAEMOGLOBIN	12.6	12 - 15	gm/dL	COLORIMETRY
TOTAL LEUCOCYTE COUNT	8700	4000-11000	/ $\mu$ L	ELECTRICAL
<b>DIFFERENTIAL COUNT</b>				
NEUTROPHILS	63	40.0 - 80.0	%	FLOW CYTOMETRY
LYMPHOCYTES	32	20.0 - 40.0	%	FLOW CYTOMETRY
MONOCYTES	03	2.0 - 10.0	%	FLOW CYTOMETRY
EOSINOPHILS	02	0.0 - 5.0	%	FLOW CYTOMETRY
BASOPHILS	00	0.0 - 2.0	%	FLOW CYTOMETRY
RED BLOOD CELL COUNT	4.2	3.5 - 5.5	millions/ $\mu$ L	ELECTRICAL
PACKED CELL VOLUME	37.4	35.0 - 50.0	%	ELECTRICAL
MEAN CORPUSCULAR VOLUME	89.0	83 - 101	fL	ELECTRICAL
MEAN CORPUSCULAR HAEMOGLOBIN	30.0	27 - 31	Picograms	CALCULATED
MEAN CORPUSCULAR HB CONC	33.7	33 - 37	g/dl	CALCULATED
PLATELET COUNT	291	150 - 450	thou/ $\mu$ L	ELECTRICAL
RDW	12.6	11.6 - 14.5	%	CALCULATED

\*\*\*\*\* END OF THE REPORT \*\*\*\*\*



Sample no.

Dr. SONIA KUMARI  
MBBS, MD (PATHOLOGY) Gold medalist

Dr. PRADIP KUMAR  
Consultant (Microbiology)

Dr. NISHA TIWARI  
MBBS, MD (Microbiology)

USER NM SONU

(This is only professional opinion and not the diagnosis, Please correlate clinically)

Q Block South City 11, Sohna Road, Main Sector-47, Gurgaon, Haryana  
Ph.: 0124-4900000 (100 Lines) Fax : 0124-2218733 E-mail : parkmedicenters@gmail.com

Page 1 of 1

PARK GROUP OF HOSPITALS : West Delhi • South Delhi • Gurgaon • Karnal • Panipat • Hodal • Ambala • Behror

the **health** care providers

the **health** care providers





NABL  
Cert. No. WC - 4830



NABH  
Cert. No. H-2016-0368

## DEPARTMENT OF PATHOLOGY

Patient Name : Ms. VISHU SINGLA  
MR No : 670715  
Age/Sex : 35 Years 5 Months 3 Days / Female  
Type : OPD  
TPA/Corporate : MEDIWHEEL PVT LTD

Bill Date : 28/01/2023  
Reporting Date : 28/01/2023  
Sample ID : 92837  
Bill/Req. No. : 24031728  
Ref Doctor : Dr.RMO

Test	Result	Bio. Ref. Interval	Units	Method
<b>LFT (LIVER FUNCTION TEST)</b>				
<b>LFT</b>				
TOTAL BILIRUBIN	0.4	0 - 1.2	mg/dL	DIAZO
DIRECT BILIRUBIN	0.2	0 - 0.4	mg/dL	DIAZO
INDIRECT BILIRUBIN	0.2	0.10 - 0.6	mg/dL	CALCULATED
SGOT (AST)	15	0 - 45	U/L	IFCC WITHOUT
SGPT (ALT)	42	0 - 45	U/L	IFCC WITHOUT
ALKALINE PHOSPHATASE	99	30 - 170	IU/L	MODIFIED IFCC
TOTAL PROTEINS	7.4	6.4 - 8.0	g/dL	BIURET
ALBUMIN	3.9	3.3 - 5.5	g/dL	BCG DYE
GLOBULIN	3.5	2.3 - 4.5	g/dL	CALCULATED
A/G RATIO	1.11	1.1 - 2.2		CALCULATED

\*\*\*\*\* END OF THE REPORT \*\*\*\*\*



Sample no.

Dr. SONIA KUMARI  
MBBS, MD (PATHOLOGY) Gold medalist

Dr. PRADIP KUMAR  
Consultant (Microbiology)

Dr. NISHA TIWARI  
MBBS, MD (Microbiology)

USER NM SONU

(This is only professional opinion and not the diagnosis, Please correlate clinically)

Q Block South City 11, Sohna Road, Main Sector-47, Gurgaon, Haryana Page 1 of 1  
Ph.: 0124-4900000 (100 Lines) Fax : 0124-2218733 E-mail : parkmedicenters@gmail.com

PARK GROUP OF HOSPITALS : West Delhi • South Delhi • Gurgaon • Karnal • Panipat • Hodal • Ambala • Behror

the health care providers

the health care providers





NABL  
Cert. No. MC - 4830



NABH  
Cert. No. H-2018-0369

## DEPARTMENT OF PATHOLOGY

Patient Name : Ms. VISHU SINGLA  
MR No : 670715  
Age/Sex : 35 Years 5 Months 3 Days / Female  
Type : OPD  
TPA/Corporate : MEDIWHEEL PVT LTD

Bill Date : 28/01/2023  
Reporting Date : 28/01/2023  
Sample ID : 92837  
Bill/Req. No. : 24031728  
Ref Doctor : Dr.RMO

Test	Result	Bio. Ref. Interval	Units	Method
<b>ESR (WESTERGREN)</b>				
E.S.R. - II HR.	30		mm II Hr.	Westergren

\*\*\*\*\* END OF THE REPORT \*\*\*\*\*



Sample no.

Dr. SONIA KUMARI  
MBBS, MD (PATHOLOGY) Gold medalist

Dr. PRADIP KUMAR  
Consultant (Microbiology)

Dr. NISHA TIWARI  
MBBS, MD (Microbiology)

USER NM SONU

(This is only professional opinion and not the diagnosis, Please correlate clinically) Page 1 of 1

Q Block South City 11, Sohna Road, Main Sector-47, Gurgaon, Haryana  
Ph.: 0124-4900000 (100 Lines) Fax : 0124-2218733 E-mail : parkmedicenters@gmail.com

PARK GROUP OF HOSPITALS : West Delhi • South Delhi • Gurgaon • Karnal • Panipat • Hodal • Ambala • Behror

the health care providers

the health care providers



## DEPARTMENT OF PATHOLOGY

Patient Name : Ms. VISHU SINGLA  
MR No : 670715  
Age/Sex : 35 Years 5 Months 3 Days / Female  
Type : OPD  
TPA/Corporate : MEDIWHEEL PVT LTD

Bill Date : 28/01/2023  
Reporting Date : 28/01/2023  
Sample ID : 92837  
Bill/Req. No. : 24031728  
Ref Doctor : Dr.RMO

Test	Result	Bio. Ref. Interval	Units	Method
<b>LFT (LIVER FUNCTION TEST)</b>				
LFT				
TOTAL BILIRUBIN	0.4	0 - 1.2	mg/dL	DIAZO
DIRECT BILIRUBIN	0.2	0 - 0.4	mg/dL	DIAZO
INDIRECT BILIRUBIN	0.2	0.10 - 0.6	mg/dL	CALCULATED
SGOT (AST)	15	0 - 45	U/L	IFCC WITHOUT
SGPT (ALT)	42	0 - 45	U/L	IFCC WITHOUT
ALKALINE PHOSPHATASE	99	30 - 170	IU/L	MODIFIED IFCC
TOTAL PROTEINS	7.4	6.4 - 8.0	g/dL	BIURET
ALBUMIN	3.9	3.3 - 5.5	g/dL	BCG DYE
GLOBULIN	3.5	2.3 - 4.5	g/dL	CALCULATED
A/G RATIO	1.11	1.1 - 2.2		CALCULATED

\*\*\*\*\* END OF THE REPORT \*\*\*\*\*



Sample no.

Dr. SONIA KUMARI  
MBBS, MD (PATHOLOGY) Gold medalist

Dr. PRADIP KUMAR  
Consultant (Microbiology)

Dr. NISHA TIWARI  
MBBS, MD (Microbiology)

USER NM SONU

(This is only professional opinion and not the diagnosis, Please correlate clinically) Page 1 of 1

Q Block South City 11, Sohna Road, Main Sector-47, Gurgaon, Haryana

Ph.: 0124-4900000 (100 Lines) Fax : 0124-2218733 E-mail : parkmedicenters@gmail.com

PARK GROUP OF HOSPITALS : West Delhi • South Delhi • Gurgaon • Karnal • Panipat • Hodal • Ambala • Behror

the **health** care providers

the **health** care providers



## DEPARTMENT OF PATHOLOGY

Patient Name : Ms. VISHU SINGLA  
MR No : 670715  
Age/Sex : 35 Years 5 Months 3 Days / Female  
Type : OPD  
TPA/Corporate : MEDIWHEEL PVT LTD

Bill Date : 28/01/2023  
Reporting Date : 28/01/2023  
Sample ID : 92837  
Bill/Req. No. : 24031728  
Ref Doctor : Dr.RMO

Test	Result	Bio. Ref. Interval	Units	Method
<b>KFT (RENAL PROFILE)</b>				
<b>KFT</b>				
SERUM UREA	22	10 - 45	mg/dL	UREASE-GLDH
SERUM CREATININE	1.1	0.4 - 1.4	mg/dL	MODIFIED JAFFES
SERUM URIC ACID	5.8	2.5 - 7.0	mg/dL	URICASE
SERUM SODIUM	142	136 - 148	mmol/L	ISE
SERUM POTASSIUM	3.9	3.5 - 5.5	meq/l	ISE
SERUM CALCIUM	8.6	8.5 - 10.5	mg/dL	ARSENazo III
SERUM PHOSPHORUS	2.8	2.5 - 4.5	mg/dL	AMMONIUM

\*\*\*\*\* END OF THE REPORT \*\*\*\*\*



Sample no.

Dr. SONIA KUMARI  
MBBS, MD (PATHOLOGY) Gold medalist

Dr. PRADIP KUMAR  
Consultant (Microbiology)

Dr. NISHA TIWARI  
MBBS, MD (Microbiology)

USER NM SONU

(This is only professional opinion and not the diagnosis, Please correlate clinically) Page 1 of 1

Q Block South City 11, Sohna Road, Main Sector-47, Gurgaon, Haryana  
Ph.: 0124-4900000 (100 Lines) Fax : 0124-2218733 E-mail : parkmedicenters@gmail.com

PARK GROUP OF HOSPITALS : West Delhi • South Delhi • Gurgaon • Karnal • Panipat • Hodal • Ambala • Behror

the health care providers the health care providers



DEPARTMENT OF PATHOLOGY

Patient Name : Ms. VISHU SINGLA  
MR No : 670715  
Age/Sex : 35 Years 5 Months 3 Days / Female  
Type : OPD  
TPA/Corporate : MEDIWHEEL PVT LTD

Bill Date : 28/01/2023  
Reporting Date : 28/01/2023  
Sample ID : 92837  
Bill/Req. No. : 24031728  
Ref Doctor : Dr.RMO

Test	Result	Bio. Ref. Interval	Units	Method
<b>LIPID PROFILE</b>				
LIPID PROFILE				
TOTAL CHOLESTEROL	120	0 - 250	mg/dL	CHOD -Trinder
SERUM TRIGLYCERIDES	110	60 - 165	mg/dl	GPO-TRINDER
HDL-CHOLESTEROL	39	30 - 70	mg/dl	DIRECT
VLDL CHOLESTEROL	22	6 - 32	mg/dL	calculated
LDL	59	50 - 135	mg/dl	calculated
LDL CHOLESTEROL/HDL RATIO	1.5	1.0 - 3.0	mg/dL	calculated
TOTAL CHOLESTEROL/HDL RATIO	3.0	2.0 - 5.0	mg/dl	calculated

\*\*\*\*\* END OF THE REPORT \*\*\*\*\*



Sample no.  
Dr. SONJA KUMARI  
MBBS, MD (PATHOLOGY) Gold medalist

Dr. PRADIP KUMAR  
Consultant (Microbiology)

Dr. NISHA TIWARI  
MBBS, MD (Microbiology)

USER NM SONU

(This is only professional opinion and not the diagnosis, Please correlate clinically) Page 1 of 1

Q Block South City 11, Sohna Road, Main Sector-47, Gurgaon, Haryana  
Ph.: 0124-4900000 (100 Lines) Fax : 0124-2218733 E-mail : parkmedicenters@gmail.com

PARK GROUP OF HOSPITALS : West Delhi • South Delhi • Gurgaon • Karnal • Panipat • Hodal • Ambala • Behror

the health care providers the health care providers



**DEPARTMENT OF RADIOLOGY**

Cert. No. MC-4830 Cert. No. H-2016-0369

Patient Name	Ms. VISHU SINGLA	Billed Date	: 28/01/2023	10.29 AM
Reg No	670715	Reported Date	: 28/01/2023	
Age/Sex	35 Years 5 Months 3Days / Female	Req. No.	: 24031728	
Type	OPD	Consultant Doctor	: Dr. RMO	

**X-RAY CHEST AP/PA**

X-RAY CHEST P.A. VIEW

Bilateral lungs appears normal.

No focal lung lesion seen.

No evidence of free fluid is seen.

Both hila are normal in size, have equal density and bear normal relationship.

The heart and trachea are central in position and no mediastinal abnormality is visible.

The cardiac size is normal for patient age and view.

The domes of the diaphragms are normal in position, and show smooth outline.

To be correlated clinically



Dr. ANSHU K. SHARMA  
MBBS, MD  
CONSULTANT RADIOLOGIST

Dr. MANJEET SEHRAWAT  
MBBS, MD, PDCC  
CONSULTANT RADIOLOGIST

Dr. NEENA SIKKA  
MBBS, DNB  
CONSULTANT RADIOLOGIST

(This is only professional opinion and not the diagnosis, Please correlate clinically)

Q Block South City 11, Sohna Road, Main Sector-47, Gurgaon, Haryana  
Ph.: 0124-4900000 (100 Lines) Fax : 0124-2218733 E-mail : parkmedicenters@park.com

**PARK GROUP OF HOSPITALS : West Delhi • South Delhi • Gurgaon • Karnal • Panipat • Hodal • Ambala • Behror**

the **health** care providers

the **health** care providers





**DEPARTMENT OF RADIOLOGY**

Cert. No. MC-4130 Cert. No. H-2016-0369

Patlent Name	Ms. VISHU SINGLA	Billed Date	: 28/01/2023	10.29 AM
Reg No	670715	Reported Date	: 28/01/2023	
Age/Sex	35 Years 5 Months 3Days / Female	Req. No.	: 24031728	
Type	OPD	Consultant Doctor	: Dr. RMO	

**USG WHOLE ABDOMEN**

The real time, B mode, gray scale sonography of the abdominal organs was performed.

**LIVER** : The liver is normal in size 14.1cm shape and echotexture. No evidence of any focal lesion. IHBR is not dilated.

**GALL BLADDER** : The gall bladder is well distended . No evidence any calculus or mass seen.GB wall thickness with in normal limits.No evidence of pericholecystic fluid is seen.

**BILE DUCT** :The common bile duct is normal in caliber. No evidence of calculus is noted in common bile duct.

**SPLEEN** :The spleen is normal in size 9.4cm and shape.Its echotexture is homogeneous.No evidence of focal lesion is noted.

**PANCREAS** :The pancreas is normal in size, shape, contours and echotexture.No evidence of solid or cystic mass lesion is noted.MPD is not dilated. No evidence of peripancreatic collection.

**KIDNEYS** :A calculus of size 6mm seen at lower pole of right kidney.

Bilateral kidney shows tiny concretion of size 3mm seen at upper & mid pole of right kidney & tiny concretion of size 3mm seen at mid pole of left kidney.

The bilateral kidneys are normal in size and echotexture. Cortico-medullary differentiation is maintained.There is no evidence of obvious hydronephrosis.

**URINARY BLADDER** :The urinary bladder is well distended.It shows uniformly thin walls and sharp mucosa.No evidence of calculus is seen. No evidence of mass or diverticulum is noted.

**UTERUS**: The uterus is anteverted. It measures 6.2x3.6x3.7cms. in the longitudinal, anteroposterior and transverse dimensions respectivelyThe uterine margins is smooth and does not reveal any contour abnormalities.

The uterine myometrium shows homogeneous echotexture.

No evidence of leiomyoma is noted. No solid or cystic mass lesion is noted.

The endometrial echo is in the midline and measures 6.9 mm.

The ovaries on the either side show normal echotexture.

No adnexal mass is seen.No cyst is seen in ovaries.

No evidence of ascites or interbowel free fluid is seen.

No evidence of obvious retroperitoneal or mesantric lymphadenopathy is seen.

**IMPRESSION-** Right renal calculus

Bilateral renal tiny concretion

to be correlated clinically.

Dr. ANSHU K. SHARMA  
MBBS, MD  
CONSULTANT RADIOLOGIST

Dr. MANJEET SEHRAWAT  
MBBS, MD, PDCC  
CONSULTANT RADIOLOGIST

Dr. NEENA SIKKA  
MBBS, DNB  
CONSULTANT RADIOLOGIST



(This is only professional opinion and not the diagnosis, Please correlate clinically)

Q Block South City 11, Sohna Road, Main Sector-47, Gurgaon, Haryana

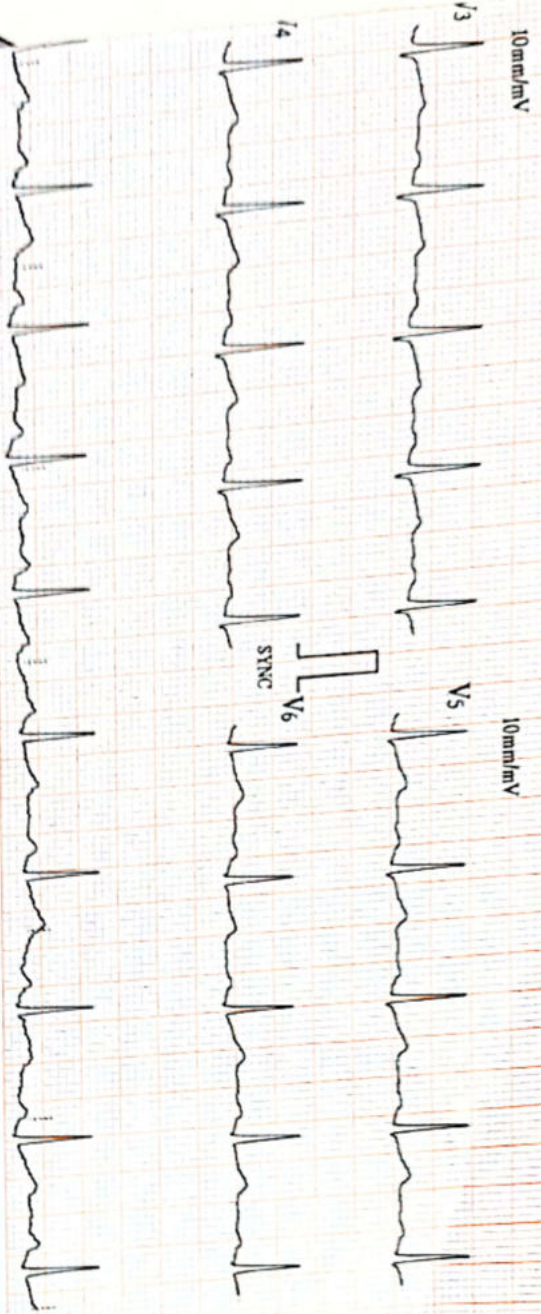
Ph.: 0124-4900000 (100 Lines) Fax : 0124-2218733 E-mail : parkmedicenters@gmail.com

**PARK GROUP OF HOSPITALS** : West Delhi • South Delhi • Gurgaon • Karnal • Panipat • Hodal • Ambala • Behror

the **health** care providers

the **health** care providers





ID : 0313

HR : 83 bpm

R-R : 716 ms

P-R : 174 ms

QRS : 87 ms

QT/QTc : 355/419 ms

P/QTc/T : 68/77/77 °

RV5/SVI : 0.940/0.370 mV

RV5+SVI : 1.310 mV

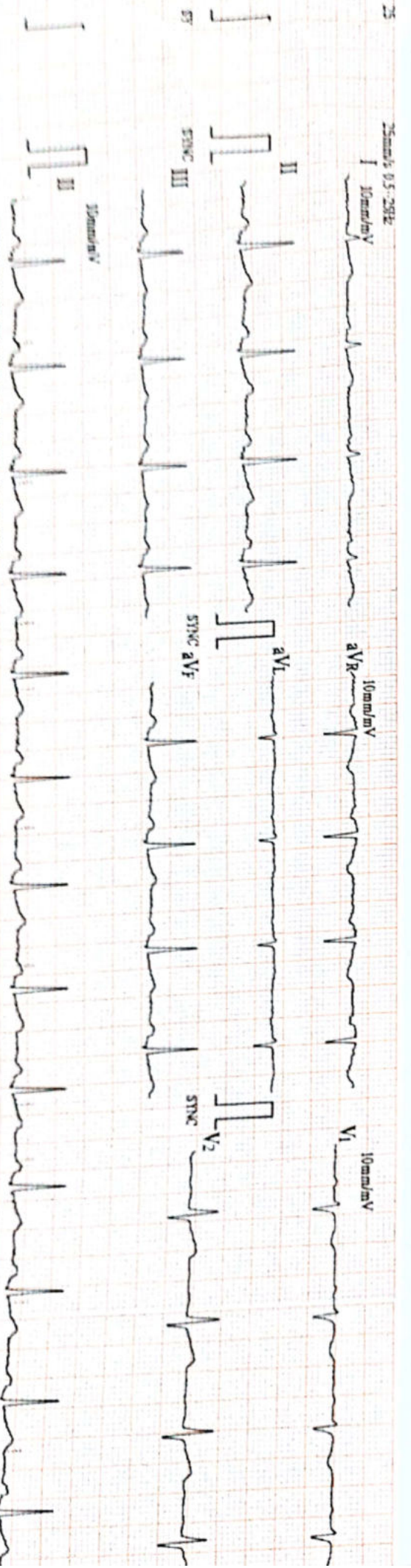
Name: Vishnu  
Sex: Male

Age: 35 yrs

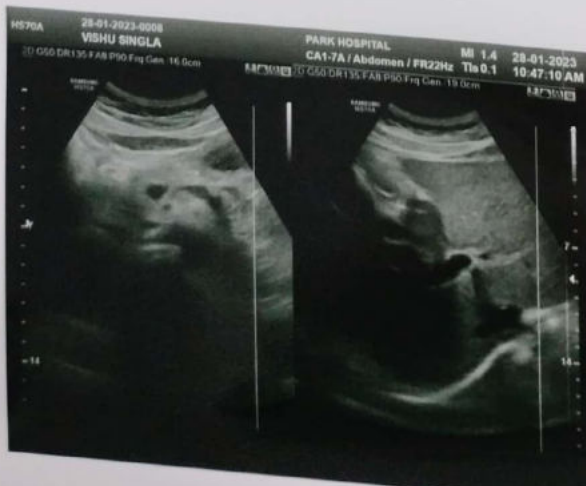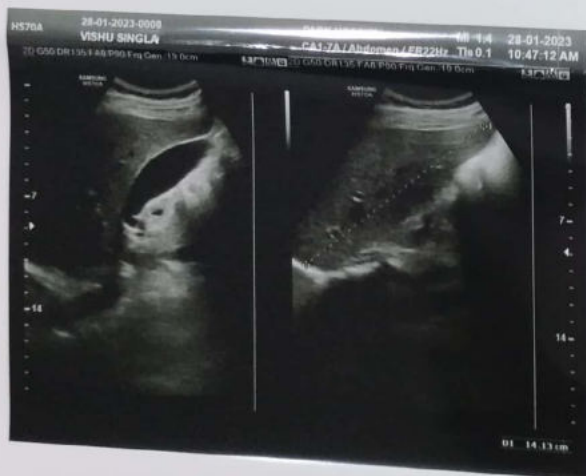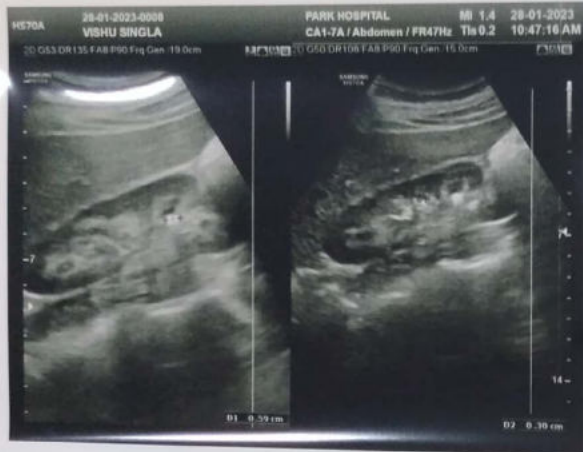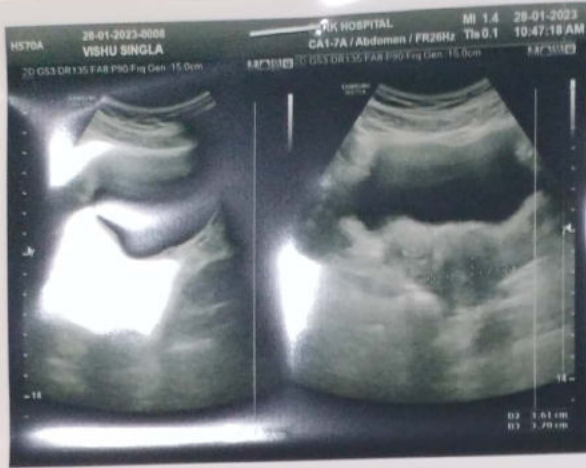28/1/23  
Ad: 18 & pm

Unconfirmed report Verified by:

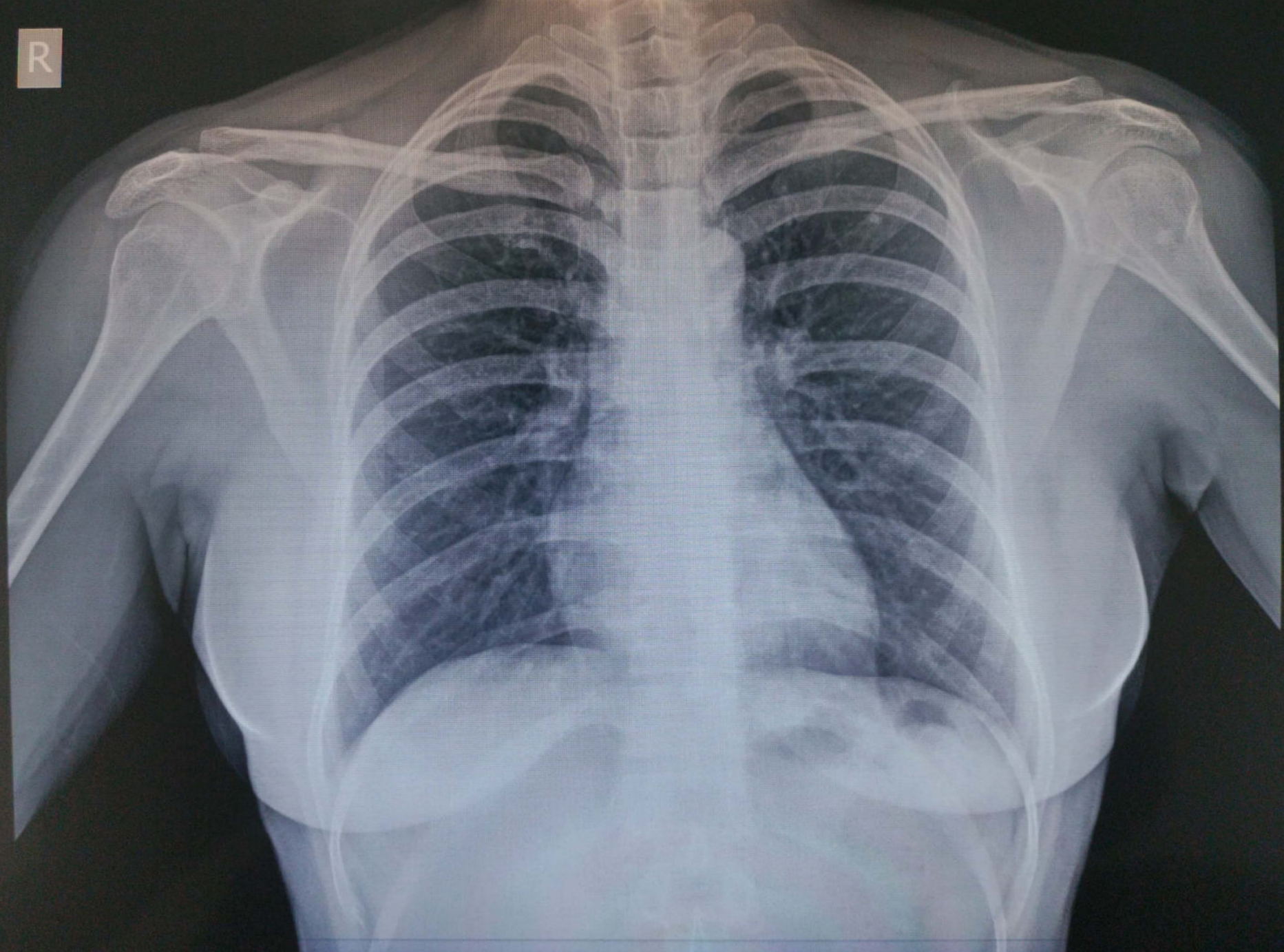
----- Sinus Rhythm  
----- T Abnormality/Flat T  
----- Marked Counter Clockwise Rotation



ECG-2023 07-0001 0100-01-01 2023-01-01 00:02



R



VISHU SINGLA 35Y Female Chest PA REQ-24031684 1/28/2023 9:52:19 AM  
PARK HOSPITAL, SOUTH CITY II, GURGAON, HARYANA