

Patient Name : Mr.SHAIK MOHAMMAD ATHIQ	Collected : 15/Nov/2024 09:34AM
Age/Gender : 39 Y 8 M 10 D/M	Received : 15/Nov/2024 11:12AM
UHID/MR No : CKON.0000441693	Reported : 15/Nov/2024 02:06PM
Visit ID : CKONOPV701163	Status : Final Report
Ref Doctor : Self	Sponsor Name : ARCOFEMI HEALTHCARE LIMITED
Emp/Auth/TPA ID : 22S38255	

DEPARTMENT OF BIOCHEMISTRY

ARCOFEMI - MEDIWHEEL - FULL BODY ANNUAL PLUS MALE - 2D ECHO - PAN INDIA - FY2324

Test Name	Result	Unit	Bio. Ref. Interval	Method
HBA1C (GLYCATED HEMOGLOBIN) , WHOLE BLOOD EDTA				
HBA1C, GLYCATED HEMOGLOBIN	6.4	%		HPLC
ESTIMATED AVERAGE GLUCOSE (eAG)	137	mg/dL		Calculated

Comment:

Reference Range as per American Diabetes Association (ADA) 2023 Guidelines:

REFERENCE GROUP	HBA1C %
NON DIABETIC	<5.7
PREDIABETES	5.7 – 6.4
DIABETES	≥ 6.5
DIABETICS	
EXCELLENT CONTROL	6 – 7
FAIR TO GOOD CONTROL	7 – 8
UNSATISFACTORY CONTROL	8 – 10
POOR CONTROL	>10

Note: Dietary preparation or fasting is not required.

- HbA1C is recommended by American Diabetes Association for Diagnosing Diabetes and monitoring Glycemic Control by American Diabetes Association guidelines 2023.
- Trends in HbA1C values is a better indicator of Glycemic control than a single test.
- Low HbA1C in Non-Diabetic patients are associated with Anemia (Iron Deficiency/Hemolytic), Liver Disorders, Chronic Kidney Disease. Clinical Correlation is advised in interpretation of low Values.
- Falsely low HbA1c (below 4%) may be observed in patients with clinical conditions that shorten erythrocyte life span or decrease mean erythrocyte age. HbA1c may not accurately reflect glycemic control when clinical conditions that affect erythrocyte survival are present.
- In cases of Interference of Hemoglobin variants in HbA1C, alternative methods (Fructosamine) estimation is recommended for Glycemic Control
 - A: HbF >25%
 - B: Homozygous Hemoglobinopathy.
 (Hb Electrophoresis is recommended method for detection of Hemoglobinopathy)



Sujana

Dr.Matta Sujana Reddy
M.B.B.S,M.D(Biochemistry)
Consultant Biochemist

Patient Name	: Mr.SHAIK MOHAMMAD ATHIQ	Collected	: 15/Nov/2024 09:34AM
Age/Gender	: 39 Y 8 M 10 D/M	Received	: 15/Nov/2024 10:24AM
UHID/MR No	: CKON.0000441693	Reported	: 15/Nov/2024 11:55AM
Visit ID	: CKONOPV701163	Status	: Final Report
Ref Doctor	: Self	Sponsor Name	: ARCOFEMI HEALTHCARE LIMITED
Emp/Auth/TPA ID	: 22S38255		

TERMS AND CONDITIONS GOVERNING THIS REPORT

1. Reported results are for information and interpretation of the referring doctor or such other medical professionals, who understand reporting units, reference ranges and limitation of technologies. Laboratories not be responsible for any interpretation whatsoever.
2. It is presumed that the tests performed are, on the specimen / sample being to the patient named or identified and the verifications of particulars have been confirmed by the patient or his / her representative at the point of generation of said specimen.
3. The reported results are restricted to the given specimen only. Results may vary from lab to lab and from time to time for the same parameter for the same patient (within subject biological variation).
4. The patient details along with their results in certain cases like notifiable diseases and as per local regulatory requirements will be communicated to the assigned regulatory bodies.
5. The patient samples can be used as part of internal quality control, test verification, data analysis purposes within the testing scope of the laboratory.
6. This report is not valid for medico legal purposes. It is performed to facilitate medical diagnosis only.



Dr.Sukumar Sannidhi
MD(Path)

Apollo Consultant Pathologist ID: 1014 - 1151101020000115519
 Regd. Office: 1-10-99/33, Ashoka Rajghatpalli Chandra, 5th Road, Bagunpally, Hyderabad, Telangana - 500 016 |
 www.apolloclinics.com, Ph.No: 040-4884 7777, Fax.No: 4884 7746

APOLLO CLINICS NETWORK:
 Telangana: Hyderabad (D'Sa Nagar) | Chandrabagan | Kondapur | Kallukunta | Khammam | Malkajgiri | Uppal | Andhra Pradesh: Mangalagiri | Madhya Pradesh: Bhopal | Karnataka: Bangalore (Basavanagudi) | Edamanki | Bidar | Mysore | Kerala: Kochi | Tamil Nadu: Chennai | West Bengal: Kolkata | Odisha: Bhubaneswar | Maharashtra: Mumbai (Bandra) | Gujarat: Gandhinagar | Rajasthan: Jaipur | Karnataka: Mysore | Karnataka: Mysore



4 Miles
 The Apollo Clinic | Cross 2-303A, Koramangala 2 Road, Bangalore
 Hyderabad: 1860 500 7788

1860 500 7788
 www.apolloclinic.com

Patient Name	: Mr. shaik mohammad athiq	Age	: 39Yrs 8Mths 11Days
UHID	: CKON.0000441693	OP Visit No.	: CKONOPV701163
Printed On	: 15-11-2024 08:24 AM	Advised/Pres Doctor	: --
Department	: Radiology	Qualification	: --
Referred By	: Self	Registration No.	: --
Employee Id	: 22S38255		

DEPARTMENT OF RADIOLOGY

ULTRASOUND WHOLE ABDOMEN

Liver appears normal in size and Grade II-increased in echotexture . No focal lesion is seen. PV and CBD normal. No dilatation of the intrahepatic biliary radicals.

Gall bladder is distended normal. No evidence of calculus. Wall thickness appears normal.No evidence of peri GB collection. No evidence of focal lesion is seen.

Spleen appears normal. No focal lesion seen. Splenic vein is normal.

Pancreas appears normal in echo pattern. No focal/mass lesion/calcification.No evidence of per pancreatic free fluid or collection. Pancreatic duct appears normal.

Both the kidneys appear normal in size, shape and echo pattern. Cortical thickness and CM differentiation are maintained. No calculus / hydronephrosis seen on either side.

Right kidney measures : 109 x 59 mm. **Left kidney measures** : 109 x 57 mm .

Urinary Bladder is well distended and appears normal. No evidence of any wall thickening or abnormality. No evidence of any intrinsic or extrinsic bladder abnormality detected.

Prostate is normal in size and echo texture. No evidence of necrosis/calcification seen. Prostate measures 27 x 29 x 39 mm,Volume--16 cc.

IMPRESSION:-

****GRADE II-FATTY LIVER.**

Suggest – clinical correlation.

(The sonography findings should always be considered in correlation with the clinical and other investigation finding where applicable.) It is only a professional opinion, Not valid for medico legal purpose.

---End Of The Report---

Dr. HARSHINI REDDY K
MBBS, MD –RADIO DIAGNOSIS
64834
Radiology

Patient Name	: Mr. shaik mohammad athiq	Age	: 39Yrs 8Mths 11Days
UHID	: CKON.0000441693	OP Visit No.	: CKONOPV701163
Printed On	: 15-11-2024 01:18 PM	Advised/Pres Doctor	: --
Department	: Radiology	Qualification	: --
Referred By	: Self	Registration No.	: --
Employee Id	: 22S38255		

DEPARTMENT OF RADIOLOGY

X-RAY CHEST PA VIEW

Both lung fields and hila are normal .

No obvious active pleuro-parenchymal lesion seen .

Both costophrenic and cardiophrenic angles are clear .

Both diaphragms are normal in position and contour .

Thoracic wall and soft tissues appear normal.

CONCLUSION :

No obvious abnormality seen

For clinical correlation.

---End Of The Report---

Dr. HARSHINI REDDY K
MBBS, MD -RADIO DIAGNOSIS
64834
Radiology

Patient Name	: Mr. shaik mohammad athiq	Age	: 39Yrs 8Mths 11Days
UHID	: CKON.0000441693	OP Visit No.	: CKONOPV701163
Printed On	: 15-11-2024 12:14 PM	Advised/Pres Doctor	: --
Department	: Cardiology	Qualification	: --
Reffered By	: Self	Registration No.	: --
Employeer Id	: 22S38255		

DEPARTMENT OF CARDIOLOGY

2 D ECHO COLOUR DOPPLER

Ao (ed)	2.8CM
LA (es)	2.8 CM
LVID (ed)	4.5CM
LVID (es)	2.9CM
IVS (Ed)	1.2 CM
LVPW (Ed)	1.2 CM
EF	62.00%
%FD	33.00%
MITRAL VALVE :	NORMAL
AML	NORMAL
PML	NORMAL
AORTIC VALVE	NORMAL
TRICUSPID VALVE	NORMAL
RIGHT VENTRICLE	NORMAL
INTER ATRIAL SEPTUM	INTACT
INTER VENTRICULAR SEPTUM	INTACT
AORTA	NORMAL
RIGHT ATRIUM	NORMAL
LEFT ATRIUM	NORMAL
Pulmonary Valve	NORMAL
PERICARDIUM	NORMAL

LEFT VENTRICLE:

NO REGION WALL MOTION ABNORMALITY

COLOUR AND DOPPLER STUDIES

PJV: 0.9 m/s

AJV: 0.9 m/s

E: 0.7 m/s

A: 0.4 m/s

IMPRESSION:-

CONCENTRIC LV HYPERTROPHY

NO DIASTOLIC DYSFUNCTION

NO RWMA

NORMAL LV FUNCTION (EF 62%)

NO MR/ AR/ TR

NO PE/ NO CLOT.

---End Of The Report---



Dr. VENKATA NEKKANTI RAYUDU

MD, DM

9242AMC

Cardiology

Patient Name	: Mr. shaik mohammad athiq	Age	: 39Yrs 8Mths 11Days
UHID	: CKON.0000441693	OP Visit No.	: CKONOPV701163
Printed On	: 15-11-2024 12:42 PM	Advised/Pres Doctor	: --
Department	: Cardiology	Qualification	: --
Referred By	: Self	Registration No.	: --
Employeer Id	: 22S38255		

DEPARTMENT OF CARDIOLOGY

Observation :-

1. Normal Sinus Rhythm.
2. Heart rate is 83 beats per minutes.
3. No pathological Q wave or ST-T changes seen.
4. Normal P,QRS,T waves and axis.
5. No evidence of chamber, hypertrophy or enlargement seen.

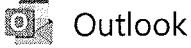
Impression:

NORMAL SINUS RHYTHM.

---End Of The Report---



Dr. VENKATA NEKKANTI RAYUDU
MD, DM
9242AMC
Cardiology



Your appointment is confirmed

From noreply@apolloclinics.info <noreply@apolloclinics.info>

Date Thu 11/14/2024 4:38 PM

To zulkhadershaik6977@gmail.com <zulkhadershaik6977@gmail.com>

Cc Hitechcity Apolloclinic <hitechcity@apolloclinic.com>; DCM Kondapur <dcm.kondapur@apolloclinic.com>; Syamsunder M <syamsunder.m@apollohl.com>

CKO/0000441693



Dear shaik mohammad athiq,

Greetings from Apollo Clinics,

Your corporate health check appointment is confirmed at **KONDAPUR** clinic on **2024-11-15** at **08:30-08:45**.

Payment Mode	
Corporate Name	ARCOFEMI HEALTHCARE LIMITED
Agreement Name	[ARCOFEMI MEDIWHEEL MALE AHC CREDIT PAN INDIA OP AGREEMENT]
Package Name	[ARCOFEMI - MEDIWHEEL - FULL BODY ANNUAL PLUS MALE - 2D ECHO - PAN INDIA - FY2324]

"Kindly carry with you relevant documents such as HR issued authorization letter and or appointment confirmation mail and or valid government ID proof and or company ID card and or voucher as per our agreement with your company or sponsor."

Note: Video recording or taking photos inside the clinic premises or during camps is not allowed and would attract legal consequences.

Note: Also once appointment is booked, based on availability of doctors at clinics tests will happen, any pending test will happen based on doctor availability and clinics will be updating the same to customers.

Instructions to be followed for a health check:

1. Please ensure you are on complete fasting for 10-To-12-Hours prior to check.
2. During fasting time do not take any kind of alcohol, cigarettes, tobacco or any other liquids (except Water) in the morning. If any medications taken, pls inform our staff before health check.

भारत सरकार
Government of India

आधार

शुक्र मुहम्मद अथिक्
Shaik Mohammed Athiq
பிறந்த நாள் / DOB : 06/09/1985
ஆண் / Male

ஆதார் என்பது அடையாளத்திற்கான சான்றாகும். குடியரிமை அல்லது பிறந்த தேதிகளை சான்றாக இது சரியாற்பட்டால் மட்டுமே பயன்படுத்தப்பட வேண்டும் (ஆன்லைன் அங்கீகரிக்க அல்லது QR குறியீட்டை ஸ்கேன் செய்தல்). (பலவேர் XMB)
Aadhaar is proof of identity, not of citizenship or date of birth. It should be used with verification (online authentication or scanning of QR code / offline XMB).

4724 9252 5143

मेरा आधार, मेरी पहचान

Aadhaar No. Issued: 30082031

CERTIFICATE OF MEDICAL FITNESS

This is to certify that I have conducted the clinical examination

of MR. Shaik Mohammed Athig on 16/11/24

After reviewing the medical history and on clinical examination it has been found that he/she is

	Tick
<ul style="list-style-type: none"> • Medically Fit 	<input checked="" type="checkbox"/>
<ul style="list-style-type: none"> • Fit with restrictions/recommendations <p>Though following restrictions have been revealed, in my opinion, these are not impediments to the job.</p> <p style="text-align: right; margin-right: 50px;">↑ Cholesterol (TG)</p> <p>1..... ↑ BP.</p> <p>2..... ↓ HDL.</p> <p>3..... ↓ LDL.</p> <p style="text-align: right; margin-right: 50px;">Infi Cardulon</p> <p>However the employee should follow the advice/medication that has been communicated to him/her.</p> <p>Review after _____</p>	<input type="checkbox"/>
<ul style="list-style-type: none"> • Currently Unfit. <p>Review after _____ recommended</p>	<input type="checkbox"/>
<ul style="list-style-type: none"> • Unfit 	<input type="checkbox"/>

Dr. Neerwanti Soni
 MBBS, DNB, DFM
 Reg. No: TSMC/111111
 Apollo Family Physician

Dr. Neerwanti Soni
 Medical Officer
 The Apollo Clinic, (Location)

This certificate is not meant for medico-legal purposes

Apollo Health and Lifestyle Limited

(CIN - U85110TG2000PLC046089) Regd. Office: 7-1-617/A, 7th Floor, Imperial Towers, Ameerpet, Hyderabad-500016, Telangana.

APOLLO CLINICS NETWORK

Andhra Pradesh: **Tirupati** (Sankarambadi Circle) **Vizag** (Seethamma Peta)

Telangana: **Hyderabad** (AS Rao Nagar | Chanda Nagar | Jubilee Hills | Kondapur | Nallakunta | Nizampet | SR Nagar | Vanasthalipuram)

Online appointments: www.apolloedoc.in | Online reports: <https://phr.apolloclinic.com> | www.apolloclinic.com

TO BOOK AN APPOINTMENT

1860 500 7788



APOLLO MEDICAL CENTER

PHYSICAL EXAMINATION FORM

DATE: 15/11/24

NAME: Mr. Shaik Mohammad Athiq

HEIGHT

172

WEIGHT

91

CHEST MEASUREMENT

107

ABDOMEN

101

PULSE

83

BP

150/100

UHID: 441693

AGE: 39/m

BMI

30.8

OUT

105

WAIST

102

HIP

105

THE APOLLO MEDICAL CENTER # 2-20/6/A, KOTHAGUDA X ROADS, NEAR HARSHA TOYOTA SHOWROOM, KONDAPUR, HITECH CITY, HYDERABAD-500032, PH.NO-040-30166600/77, EMAIL : hitechcity@apolloclinics.com



Patient Name : Mr. shaik mohammad athiq
TOUCHING LIVES
UHID : CKON.0000441693
Printed On : 15-11-2024 06:12 PM
Department : Cardiology
Referred By : Self
Employer Id : 22S38255

Age : 39Yrs 8Mths 10Days *Expertise. Closer to you.*
OP Visit No. : CKONOPV701163
Advised/Pres Doctor : --
Qualification : --
Registration No. : --

DEPARTMENT OF CARDIOLOGY

Observation :-

1. Normal Sinus Rhythm.
2. Heart rate is 83 beats per minutes.
3. No pathological Q wave or ST-T changes seen.
4. Normal P,QRS,T waves and axis.
5. No evidence of chamber, hypertrophy or enlargement seen.

Impression:

NORMAL SINUS RHYTHM.

---End Of The Report---

Dr. VENKATA NEKKANTI RAYUDU
MD, DM
9242AMC
Cardiology

Apollo Health and Lifestyle Limited

(CIN - U85110TG2000PLC046089) Regd. Office: 7-1-617/A, 7th Floor, Imperial Towers, Ameerpet, Hyderabad-500016, Telangana.

APOLLO CLINICS NETWORK

Andhra Pradesh: **Tirupati** (Sankarambadi Circle) **Vizag** (Seethamma Peta)

Telangana: **Hyderabad** (AS Rao Nagar | Chanda Nagar | Jubilee Hills | Kondapur | Nallakunta | Nizampet | SR Nagar | Vanasthalipuram)

Online appointments: www.apolloedoc.in | Online reports: <https://phr.apolloclinic.com> | www.apolloclinic.com

TO BOOK AN APPOINTMENT



1860 500 7788

Mr. Shaikh Mohammed at
ID: 441693

15.11.2024 12:31:11
APOLLO MEDICAL CENTRE
HYDERABAD

39 Years
Male

Technician:
Ordering Ph:
Referring Ph:
Attending Ph:

Location:
Order Number:
Visit:
Indication:
Medication 1:
Medication 2:
Medication 3:

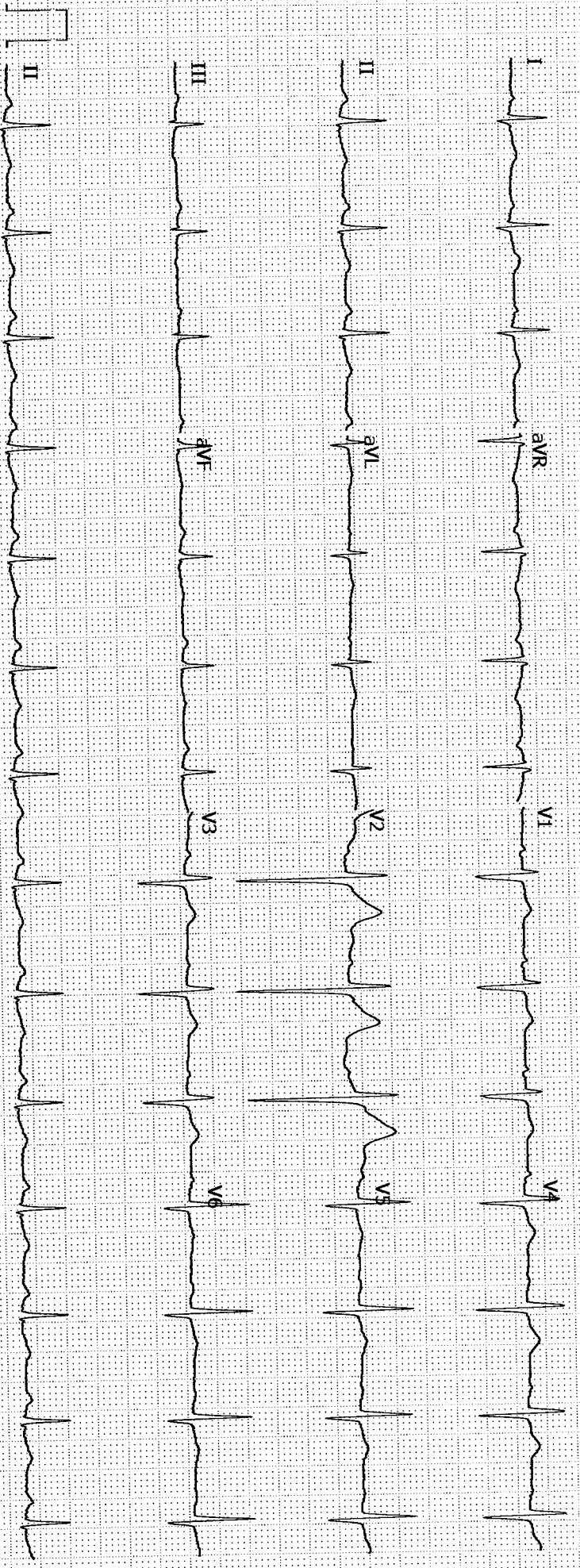
Room:

83 bpm
- / - mmHg

wjlc

QRS : 86 ms
QT / QTcBaz : 380 / 446 ms
PR : 172 ms
P : 106 ms
RR / pp : 720 / 722 ms
P / QRS / T : 64 / 58 / 19 degrees

Normal sinus rhythm
Normal ECG



GE MAC2000 1.1 12SL V241 25 mm/s 10 mm/mV ADS 0.56-40 Hz 50 Hz 4x2.5x3_25_R1 1/1

Unconfirmed



Patient Name : Mr. shaik mohammad athiq
 UHID : CKON.0000441693
 Printed On : 15-11-2024 05:44 PM
 Department : Cardiology
 Referred By : Self
 Employee Id : 22S38255

Age : 39Yrs 8Mths 10Days
 OP Visit No. : CKONOPV701163
 Advised/Pres Doctor : --
 Qualification : --
 Registration No. : --

DEPARTMENT OF CARDIOLOGY

2 D ECHO COLOUR DOPPLER

Ao (ed)	2.8CM
LA (es)	2.8 CM
LVID (ed)	4.5CM
LVID (es)	2.9CM
IVS (Ed)	1.2 CM
LVPW (Ed)	1.2 CM
EF	62.00%
%FD	33.00%
MITRAL VALVE :	NORMAL
AML	NORMAL
PML	NORMAL
AORTIC VALVE	NORMAL
TRICUSPID VALVE	NORMAL
RIGHT VENTRICLE	NORMAL
INTER ATRIAL SEPTUM	INTACT
INTER VENTRICULAR SEPTUM	INTACT
AORTA	NORMAL
RIGHT ATRIUM	NORMAL
LEFT ATRIUM	NORMAL
Pulmonary Valve	NORMAL
PERICARDIUM	NORMAL

LEFT VENTRICLE:
 NO REGION WALL MOTION ABNORMALITY

COLOUR AND DOPPLER STUDIES

PJV: 0.9 m/s
 AJV: 0.9 m/s
 E: 0.7 m/s

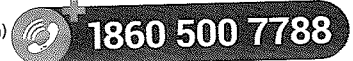A: 0.4 m/s

Apollo Health and Lifestyle Limited
 (CIN - U85110TG2000PLC046089) Regd. Office: 7-1-617/A, 7th Floor, Imperial Towers, Ameerpet, Hyderabad-500016, Telangana.

APOLLO CLINICS NETWORK

Andhra Pradesh: Tirupati (Sankarambadi Circle) **Vizag** (Seethamma Peta)
Telangana: Hyderabad (AS Rao Nagar | Chanda Nagar | Jubilee Hills | Kondapur | Nallakunta | Nizampet | SR Nagar | Vanasthalipuram)
 Online appointments: www.apolloedoc.in | Online reports: <https://phr.apolloclinic.com> | www.apolloclinic.com

TO BOOK AN APPOINTMENT



IMPRESSION:-

CONCENTRIC LV HYPERTROPHY
NO DIASTOLIC DYSFUNCTION
NO RWMA
NORMAL LV FUNCTION (EF 62%)
NO MR/ AR/ TR
NO PE/ NO CLOT.

---End Of The Report---



Dr. VENKATA NEKKANTI RAYUDU
MD, DM
9242AMC
Cardiology

Apollo Health and Lifestyle Limited

(CIN - U85110TG2000PLC046089) Regd. Office: 7-1-617/A, 7th Floor, Imperial Towers, Ameerpet, Hyderabad-500016, Telangana.

APOLLO CLINICS NETWORK

Andhra Pradesh: Tirupati (Sankarabadi Circle) **Vizag** (Seethamma Peta)

Telangana: Hyderabad (AS Rao Nagar | Chanda Nagar | Jubilee Hills | Kondapur | Nallakunta | Nizampet | SR Nagar | Vanasthalipuram)

Online appointments: www.apolloedoc.in | Online reports: <https://phr.apolloclinic.com> | www.apolloclinic.com

TO BOOK AN APPOINTMENT



1860 500 7788

Name <u>Ms. Shaik Mohammad A</u>	Date <u>15/11/24</u>
Age <u>39/4</u>	UHID No. <u>441693</u>
<input checked="" type="checkbox"/> Male <input type="checkbox"/> Female	Ref. Physician
Ref. Diagnosis	<u>Dr. Indrani</u>

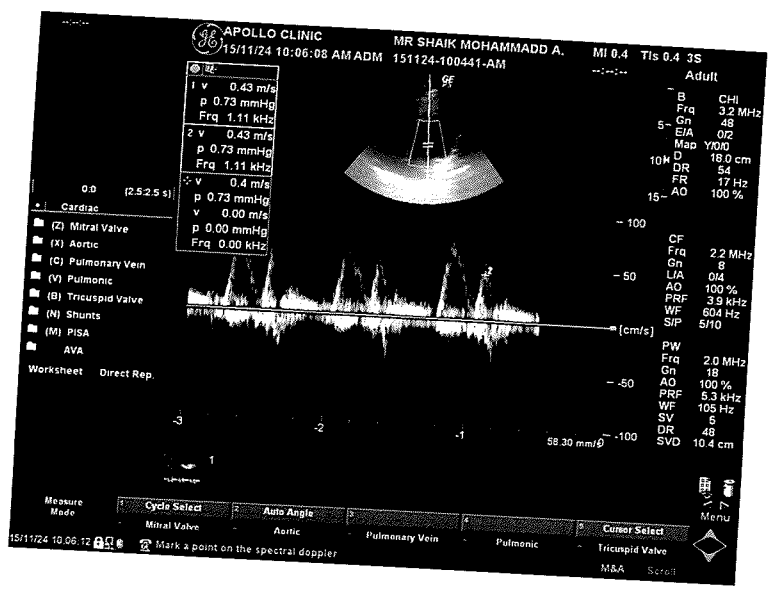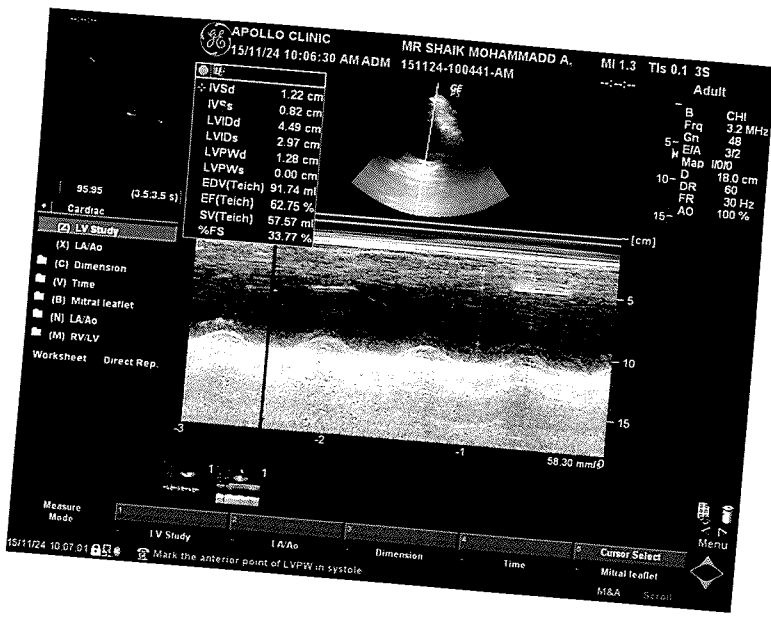
Echocardiogram Report

Echogenicity Poor Adequate Good Ht. _____ Wt. _____ BSA _____

DIMENSIONS	NORMAL	DIMENSIONS	NORMAL
Ao (ed) <u>2.8</u> cm	(1.5cm / m ²)	IVS (Ed) <u>1.2</u> cm	(0.6 - 1.2 cm)
LA (es) <u>3.8</u> cm	(1.5cm / m ²)	LVPW (Ed) <u>1.2</u> cm	(0.6 - 1.1 cm)
RVID (ed) <u>4.1</u> cm	(0.9 cm / m ²)	EF <u>62%</u>	(0.62 - 0.85)
LVID (ed) <u>4.5</u> cm	(2.6 - 3.4 cm / m ²)	% FD <u>33%</u>	(2.8% - 42%)
LVID (es) <u>2.9</u>			

MORPHOLOGICAL DATA

Mitral Valve	AML <u> </u>	Interatrial septum <u> </u>
	PML <u> </u>	Interventricular septum <u>Intact</u>
Aortic Valve	<u> </u>	Pulmonary artery <u> </u>
Tricuspid valve	<u> </u>	Aorta <u> </u>
Pulmonary valve	<u> </u>	Right atrium <u>6</u>
Right ventricle	<u> </u>	Left atrium _____



GLASS PRESCRIPTION

DATE: 15/11/24

UHID: - 41693.

PATIENT NAME: Mr. Shaik Mohammed Athiy

AGE/ GENDER: 39/m
- 9949197676.

	UAVA	SPH	CYL	AXIS	ADD	BCVA
OD	6/6					NB
OS	6/6	plano			2.	NB

COLOR VISION :

Cu - normal

INSTRUCTIONS:

BBin - normal

* - single use - Buse

SIGNATURE

⇒. Advise to use Blue protection w glasses