

**DAKSH HOSPITAL**

396 - 397, Gandhi Nagar, Scheme No. 8, ALWAR -301001

Ref. No.

Date.....

MEDICAL EXAMINATION REPORT  
Mediwheel (BOB)

Name: Mr. Gagan Singh

Age: 27 yrs

Sex: Male

Date: 28/08/2023

General Physical ExaminationHeight : 181 cm  
Pulse : 84 /mt  
Respiration : 18 /mtWeight : 73.2 kg  
BP : 120/80 mm/hg  
BMI : 22.3 kg/m<sup>2</sup>Systemic Exam:-

NORMAL

Dental Check up :-

NORMAL

Eve check-up :-

NORMAL

Skin Check up:-

NORMAL

ENT Check up:-

NORMAL

Gynae Check up:-


N/A

Impression:-

Normal.

Recommendation:-

-NO-

  
 Dr. Mukesh Kumar Gupta  
 MD Gen. Medicine  
 Reg. No 5423/16262

 डॉ० मुकेश गुप्ता  
 M.D.F.C.C.S.  
 फिजिशियन एवं मधुमेह रोग विशेषज्ञ  
 दक्ष हॉस्पिटल, अलवर  
 रजि० नं०-5423/16262

## Results

Run Date 28/08/2023 09:51:51 AM

Operator DAKSH

Last Name

Sample ID 01

First Name MR GANGAN SINGH

Department

Gender Male Age

Physician DR. MUKESH GUPTA M.D

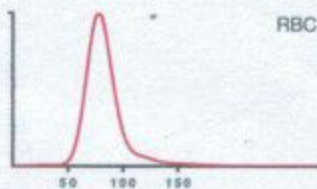
Patient ID AUTO\_PID15608

Type Man

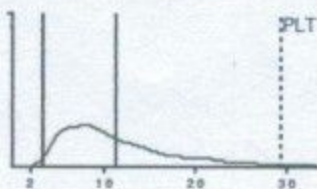
Date of birth

Sample comments

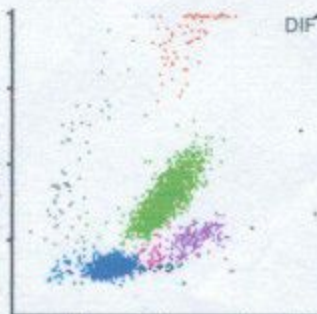
				Range
RBC	5.77	h*	10 <sup>6</sup> /μL	3.80 - 5.50
HGB	16.1		g/dL	13.0 - 17.0
HCT	51.6	*	%	39.0 - 52.0
MCV	89.4	*	μm <sup>3</sup>	76.0 - 100.0
MCH	28.0		pg	26.0 - 34.0
MCHC	31.3	L	g/dL	32.0 - 35.0
RDW-CV	15.0		%	11.0 - 16.0
RDW-SD	49.0		μm <sup>3</sup>	37.0 - 49.0



				Range
PLT	193		10 <sup>3</sup> /μL	150 - 450
PCT	0.21		%	0.15 - 0.40
MPV	10.8		μm <sup>3</sup>	8.0 - 11.0
PDW	18.6		μm <sup>3</sup>	11.0 - 22.0
P-LCC	75		10 <sup>3</sup> /μL	44 - 140
P-LCR	38.7		%	18.0 - 50.0



				Range
WBC	5.22		10 <sup>3</sup> /μL	3.50 - 10.00
	#			
NEU	2.75	1.60 - 7.00	52.8	40.0 - 75.0
LYM	2.16	1.00 - 3.00	41.5	20.0 - 45.0
MON	0.09	0.20 - 0.80	1.7	2.0 - 10.0
EOS	0.12	0.00 - 0.50	2.4	1.0 - 6.0
BAS	0.09	0.00 - 0.15	1.6	0.0 - 1.0
LIC	0.01	0.00 - 0.10	0.2	0.0 - 1.0



*[Signature]*

Dr. R.S. GUPTA  
MD (Pathology) (MAHE)  
RMC No. 7924/19778

Date :- 28/08/2023

Name :- MR. GAGAN SINGH

Age &amp; Sex :- 27Yrs/ male

Refd. :- Dr Mukesh Gupta M.D.

	TEST NAME	RESULT	REFERENCE RANGE
	ESR		12 00 - 20 mm/hrs
	Blood Group & Rh Factor	B " POSITIVE	
	HbA1C	4.3	4 - 5.6%
	Blood Sugar (F)	91.1	< 70 - 100 mg/dl
	Blood Sugar (PP)	107.1	< 140 mg/dl
	Urine Sugar (F)	NIL	-
	Urine Sugar (PP)	NIL	-
LIVER	S.Bilirubin Total	0.80	0.30 - 1.20 mg/dl
	S.Bilirubin Direct	0.20	0.10 - 0.30 mg/dl
	S.Bilirubin Indirect	0.60	0.30 - 0.90 mg/dl
	S.G.O.T.	28	> 37 u/l
	S.G.P.T.	35	> 40 u/l
	S.Alk. Phosp.	187	80 - 306 u/l
	G.G.T.	22.1	5 - 40 u/l
	Total Protein	6.9	6.5 - 8.5 gm/dl
	Albumin	3.9	3.8 - 5.4 gm/dl
	Globulin	3.3	2.3 - 3.5 gm/dl
	A/G Ratio	1.3	-
AST/ALT Ratio	0.8	-	
KIDNEY	Blood Urea	27.1	15 - 45 mg/dl
	S.Creatinine	1.2	0.60 - 1.30 mg/dl
	BUN	19.0	6 - 24 mg/dl
	S.Uric Acid -	4.9	M 3.1 - 7.0, F 2.5 - 5.6 mg/dl
	BUN/Creatinine Ratio	15.8	-
LIPID PROFILE	Total Cholesterol	160	Up to 200 mg/dl
	S.HDL	45	30 - 70 mg/dl
	S.LDL	91	Up to 170 mg/dl
	S.VLDL	24	5.0 - 40 mg/dl
	S. Triglycerides	120	Up to 170 mg/dl
	LDL/HDL Ratio	2.1	-
	Total Cholesterol/ HDL Ratio	3.5	-
THYROID	T3	115.2	40 - 181 ng/dl
	T4	8.9	4.6 - 10.5 µg/dl
	TSH	3.26	0.30 - 5.0 mIU/l

**URINE EXAMINATION**
**Microscopic Examination :**

		RBC	Absent
General/Chemical Examination:	Colour	Pale Yellow	0 - 1
	Reaction	Acidic	0 - 1
	Specific Gravity	QNS	Absent
	Appearance	Clear	Absent
	Albumin	Nil	Absent
	Sugar	Nil	Absent
			Other

**X-RAY CHEST**

NORMAL STUDY

**STOOL EXAMINATION**
**Microscopic Examination :**

General/Chemical Examination:		RBC	-
	Colour	-	-
	Consistency	-	-
	PH	-	-
	Reducing Substances	-	-

Dr. R.S. GUPTA  
 MD (Pathology) (MAHE)  
 Doctor Reg. No. 7924/19778

**TECHNOLOGIST**

All investigation have their own limitations regarding the sensitivity & specificity of individual assay procedures, isolated laboratory investigations never confirm the final diagnosis of the disease. They only help in arriving at a diagnosis in conjunction with clinical presentation and other related investigations. Report is not valid for medico-legal purpose subject to ALWAR jurisdiction only.



# दक्ष हॉस्पिटल

396, गाँधी नगर स्कीम नं.8, अलवर (राज०) ☎ 0144-2703340

## Sonography / 2D Echo Cardiography / Doppler Report

### 2D/ ECHO REPORT

Name: - Mr Gagan Singh

Age: - 27 Yrs

Date: - 28-Aug-23

Reg. No.: - Alw/2009/04  
BOB health checkup

PROCEDURES:

M-MODE/2D/DOPPLER/COLOR/CONTRASTB.A.S. M<sup>2</sup>

MEASUREMENT:			DOPPLER:				
AOD	27	NORMAL (20- 37mm)	MV	0.54	NORMAL (0.8- 1.3)	MR	No
LA	25.9	(19- 40mm)	AV	1.3	(1.2- 1.8)	AR	No
AVO	20	(12- 25mm)	TV	0.6	(0.3- 0.8)	TR	No
RVDd	15.5	(03- 09mm)	PV	0.8	(0.7- 1.1)	PR	No
LVDd	50	(37- 56mm)	MITRAL VALVE-				
LVDs	29.7	(22- 40mm)			AML	Normal	
IVS d	9.7	(06- 12mm)			PML	Normal	
IVS s	15		AORTIC VALVE				
PWd	3	(05- 10mm)				Normal	
LV FUNCTION			TV & PV are normal.				
M- E- S Separation		<0.9cm					
Minor		24.42%					
LV Ejection Fraction	72%	65 +/- 12%					

LV WALL MOTION: NO RWMA  
ALL CARDIAC CHAMBERS ARE NORMAL  
ALL VALVES ARE NORMAL  
NO CLOT, VEGETATION, PERICARDIAL EFFUSION

FINAL DIAGNOSIS: NORMAL STUDY

Adv: - Follow up/ review at higher center for confirmation

Note:- Please Correlate clinically. Due to technical limitations as well as inaccuracies inherent in the laboratory and statistical analysis of biological process. Diagnostic accuracy of ECHO is up to 95% only.  
Report is not valid for medico-legal purpose.

  
Dr. Mukesh Kumar Gupta  
DR. MUKESH GUPTA  
Physician & Cardiologist  
RM 5423/16262



"भ्रूण लिंग परीक्षण की शिकायत  
104 टोल फ्री सेवा पर भी की  
जा सकती है"

भ्रूण लिंग परीक्षण की शिकायत 104 टोल फ्री सेवा पर भी की जा सकती है।



# दक्ष हॉस्पिटल

396, गाँधी नगर स्कीम नं.8, अलवर (राज०) ☎ 0144-2703340

## Sonography / 2D Echo Cardiography / Doppler Report

Name: MR. GAGAN SINGH /M/27 YRS

Date: 28-Aug-23

BOB HEALTH CHECK UP

### U.S.G. OF ABDOMEN & PELVIS

#### LIVER

Liver is normal in size shape with normal echo-texture. Intra hepatic biliary radicals are not dilated. No evidence of focal or diffuse lesion.

#### GALL BLADDER

Gall bladder is normal dilated. Lumen clear. Wall thickness normal. CBD normal

#### PANCREAS

Pancreas is normal in size, shape & echo-texture.

#### SPLEEN

Normal in size with normal shape & echo- texture.

#### BOTH KIDNEY

Both kidneys are normal in size shape and echo- texture.

PROSTATE & URINARY BLADDER is normal shape, size & echo texture..

### Advice- X Ray KUB / URINE EXAM

Please correlate clinically. USG accuracy is 95 % due to technical limitations as well as inaccuracies inherent in the laboratory and statistical analysis biological process.

This report is not valid for medico-legal cases.

  
DR. MUKESH GUPTA  
SONOLOGIST  
Physician & Sonologist  
RM 5423/16262



"भ्रूण लिंग परीक्षण की शिकायत  
104 टोल फ्री सेवा पर भी की  
जा सकती है"

भ्रूण लिंग परीक्षण की शिकायत 104 टोल फ्री सेवा पर भी की जा सकती है।

ID: 911

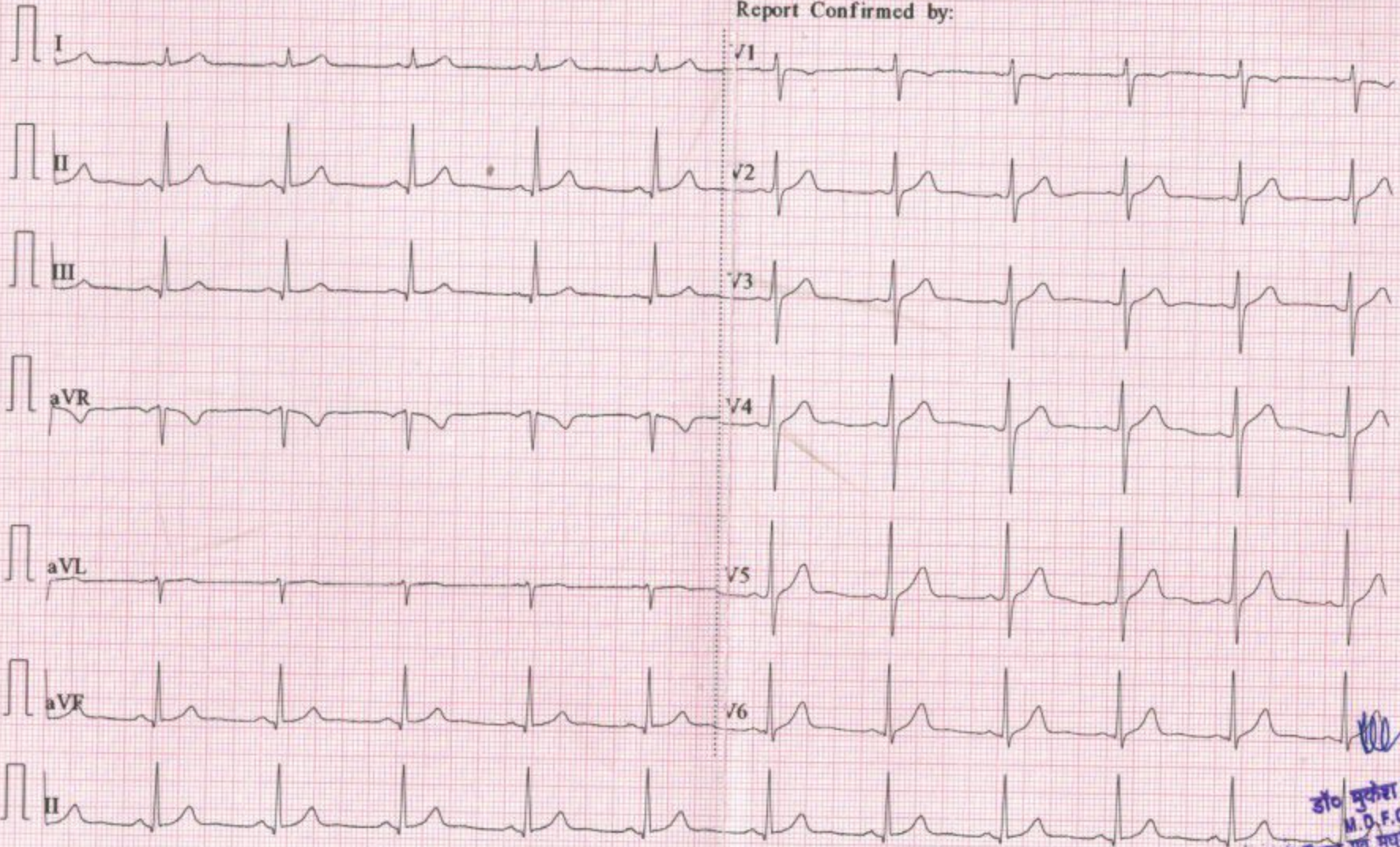
BPL - 02 28-08-2023 12:31:16

Female Years  
Req. No. :

HR : 67 bpm  
 P : 104 ms  
 PR : 132 ms  
 QRS : 94 ms  
 QT/QTcBz : 380/402 ms  
 P/QRS/T : 56/75/56 °  
 RV5/SV1 : 1.377/0.553 mV

Diagnosis Information:  
 Sinus rhythm  
 Normal ECG

Report Confirmed by:



डॉ० मुकेश गुप्ता  
 M.D.F.C.C.S.  
 वरुण हॉस्पिटल, अलवर  
 रजि० नं०-5423/18262

2100

R



A frontal chest X-ray showing the ribcage, spine, and lung fields. The lungs appear clear with no significant opacities. The heart size is within normal limits. A small 'R' marker is visible in the upper left corner. There is some faint blue ink scribbled at the bottom center of the image.

VIJAY DIAGNOSTIC CENTRE 1/16 KALA KUAN .ALWAR

2438