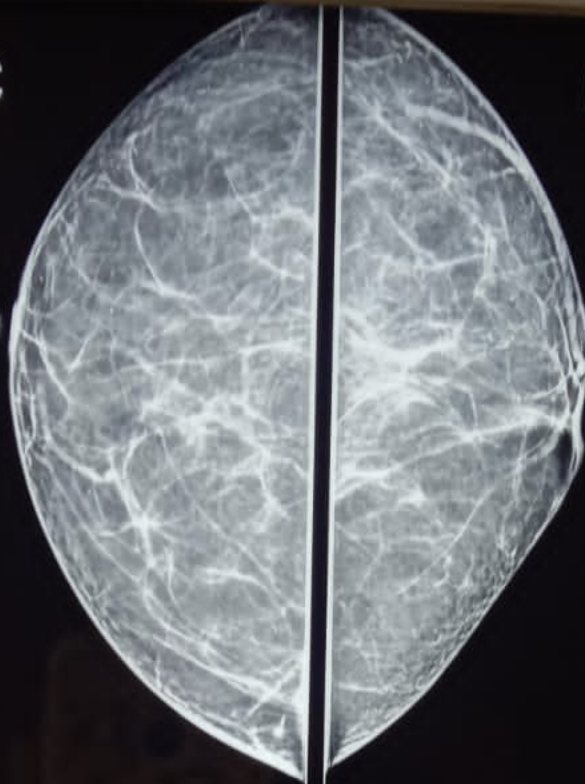


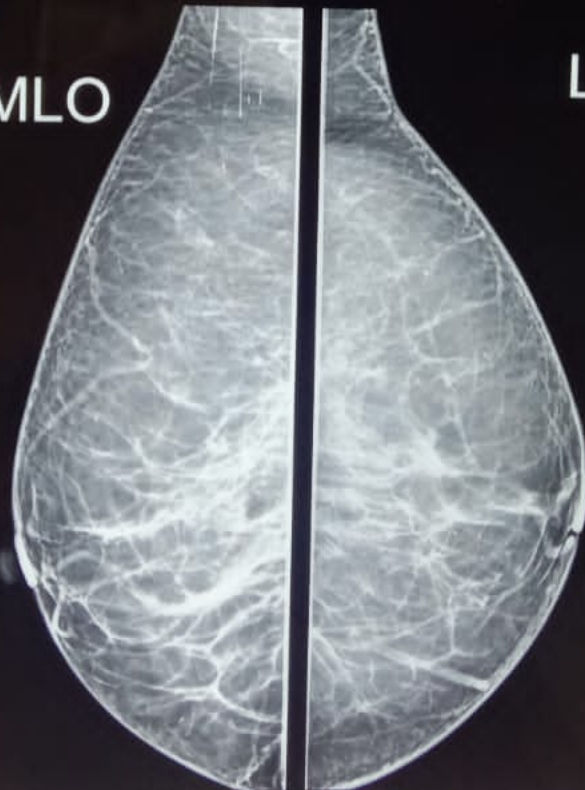RCC

LCC



RMLO

LMLO

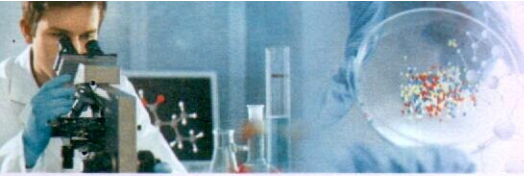

VIDHI DIAGNOSTICS
PUSHPABEN PARMAR 52/YRS F 13-May-23 MAMMOGRAPHY 1 13052309



Shot on Y12
Vivo AI camera

2023.05.14 11:29



Pathology Department



Patient's name : PARMAR PUSHPABEN
Age/Sex : 52 Years/Female
Referred by : Dr. MEDIWHEEL
Collection Time : 11:32

Reg. ID : P-788-23
Accession : 5434
Order Dt/time : 13/05/2023 11:32

Complete Blood Count

Sample Type: EDTA

| Test Name | Result | Units | Biological Reference Interval |
|---|-------------|-----------|-------------------------------|
| <u>Blood Counts</u> | | | |
| Haemoglobin : | 11.4 | Gms% | 12.5 - 16.0 |
| Total R.B.C. : | 4.10 | mill/c.mm | 4.2 - 5.4 |
| Total W. B. C. : | 4220 | /cu mm | 4000 - 10500 |
| Platelet Count : | 246000 | /cu.mm | 1,50,000 - 4,50,000 |
| <u>Differential Count</u> | | | |
| Neutrophils : | 58 | % | 40 - 70 |
| Lymphocytes : | 36 | % | 20 - 40 |
| Eosinophils : | 03 | % | 1 - 4 |
| Monocytes : | 03 | % | 2 - 6 |
| Basophils : | 00 | % | 0 - 01 |
| <u>Blood Indices</u> | | | |
| P. C. V : | 35.6 | % | 37 - 47 |
| M. C. V. : | 86.9 | fl | 78 - 100 |
| M.C.H : | 27.8 | pg | 27 - 31 |
| M. C. H. C : | 32.0 | % | 32 - 36 |
| R.D.W : | 15.4 | % | 11.5 - 14.0 |
| <u>E.S.R.(Westergren Method)</u> | | | |
| After one hour : | 06 | mm/hr | 3 - 12 |

TESTS DONE ON FULLY AUTOMATED HEMATOLOGY ANALYZER.

Dr. Gayatri M. Mehta

M. D. (Patho)

Reg. No. G-32215

DR GAYATRI MEHTA
MD(PATHOLOGY)

DR. ANAND D. PARIKH
MD(PATHOLOGY)

LAB USE ONLY (Entered by :GM Enter Date/Time:14/05/2023 11:41:00 AM) (Verify by :GM Verify Date/Time:14/05/2023 11:41:00 AM)

ISO 9001:2015 Certified Diagnostics Center

Vidhi Imaging Center | Pathology Department

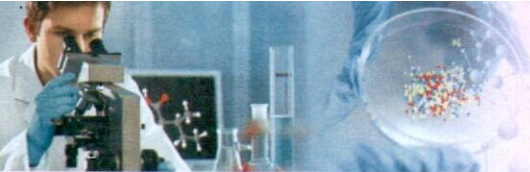L-86, Swatantra Senani Nagar, Opp. Akharnagar Petrol Pump, Nr. Akharnagar Circle, Nava-Vadaj, Ahmedabad - 380 013.

Ph. (Pathology) : 079-2762 1406, 8849893954 M. 98799 29406, 98250 09406, E-mail : vidhidiagnostics@gmail.com, Web. : www.vidhidiagnostics.com

Time (Pathology) : Mon. to Sat. 8.30 am to 8.00 pm, Sunday 9 am to 12 Noon

Pathology means science behind medicine

CT SCAN & CBCT FACILITY NOW AVAILABLE



Pathology Department

VIDHI[®]
DIAGNOSTICS

Creating Life in Gujarat

Patient's name : PARMAR PUSHPABEN
Age/Sex : 52 Years/Female
Referred by : Dr. MEDIWHEEL
Collection Time : 11:32

Reg. ID : P-788-23
Accession : 5434
Order Dt/time : 13/05/2023 11:32

Blood Group

Sample Type: EDTA sample.

| Test Name | Result |
|-----------|----------------------------------|
| BG : | " A " |
| RH : | POSITIVE |
| Remarks | Done by forward grouping method. |

Dr. Gayatri M. Mehta
M. D. (Patho)

Reg. No. G-32215

DR GAYATRI MEHTA
MD(PATHOLOGY)

DR. ANAND D. PARIKH
MD(PATHOLOGY)

LAB USE ONLY (Entered by :GM Enter Date/Time:14/05/2023 11:37:00 AM) (Verify by :GM Verify Date/Time:14/05/2023 11:37:00 AM)

ISO 9001:2015 Certified Diagnostics Center

Vidhi Imaging Center | Pathology Department

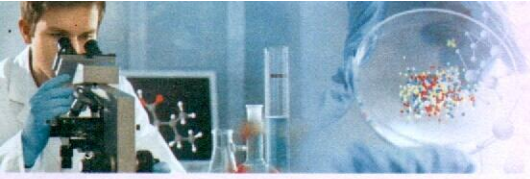L-86, Swatantra Senani Nagar, Opp. Akhbarnagar Petrol Pump, Nr. Akhbarnagar Circle, Nava-Vadaj, Ahmedabad - 380 013.

Ph. (Pathology) : 079-2762 1406, 8849893954 M. 98799 29406, 98250 09406, E-mail : vidhidiagnostics@gmail.com, Web. : www.vidhidiagnostics.com


Time (Pathology) : Mon. to Sat. 8.30 am to 8.00 pm, Sunday 9 am to 12 Noon

Pathology means science behind medicine

CT SCAN & CBCT FACILITY NOW AVAILABLE



Pathology Department



Patient's name : PARMAR PUSHPABEN
Age/Sex : 52 Years/Female
Referred by : Dr. MEDIWHEEL
Collection Time : 11:32

Reg. ID : P-788-23
Accession : 5434
Order Dt/time : 13/05/2023 11:32

Blood Glucose

Sample Type: Serum

| Test Name | Result | Units | Biological Reference Interval |
|--|--------|-------|-------------------------------|
| Fasting Blood Glucose : <i>GOD-POD Method.</i> | 99.2 | mg/dl | 70 - 110 |

Blood Glucose

Sample Type: Serum

| Test Name | Result | Units | Biological Reference Interval |
|---|--------|-------|-------------------------------|
| Post Prandial Blood Glucose After 2hr. : <i>GOD-POD Method.</i> | 138.9 | mg/dl | 80 - 140 |

Dr. Gayatri M. Mehta
M. D. (Patho)

Reg. No. G-32215
DR GAYATRI MEHTA
MD(PATHOLOGY)

DR. ANAND D. PARIKH
MD(PATHOLOGY)

LAB USE ONLY (Entered by :GM Enter Date/Time:14/05/2023 11:51:00 AM) (Verify by :GM Verify Date/Time:14/05/2023 11:52:00 AM)

ISO 9001:2015 Certified Diagnostics Center

Vidhi Imaging Center | Pathology Department

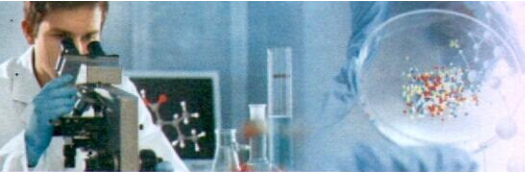L-86, Swatantra Senani Nagar, Opp. Akhbarnagar Petrol Pump, Nr. Akhbarnagar Circle, Nava-Vadaj, Ahmedabad - 380 013.

Ph. (Pathology) : 079-2762 1406, 8849893954 M. 98799 29406, 98250 09406, E-mail : vidhidiagnostics@gmail.com, Web. : www.vidhidiagnostics.com

Time (Pathology) : Mon. to Sat. 8.30 am to 8.00 pm, Sunday 9 am to 12 Noon

Pathology means science behind medicine

CT SCAN & CBCT FACILITY NOW AVAILABLE



Pathology Department

VIDHI
DIAGNOSTICS



Patient's name : PARMAR PUSHPABEN
Age/Sex : 52 Years/Female
Referred by : Dr. MEDIWHEEL
Collection Time : 11:32

Reg. ID : P-788-23
Accession : 5434
Order Dt/time : 13/05/2023 11:32

HbA1C

Sample Type: Serum

| Test Name | Result | Units | Biological Reference Interval |
|--|--------|-------|--|
| HbA1C : | 5.4 | % | Non-diabetic: 4.2-6.2 Pre-diabetic : 6.3-7.2 Diabetic : 7.3-8.2 |
| Mean Blood Glucose of Last 03 : months. | 108 | mg/dl | |

Comment

*As per the new 2009 update of American Diabetes Association regarding HbA1C & Mean Blood Glucose relationship.

NOTE:

This test is used to monitor diabetic patients compliance with the therapeutic regimen and logo It's level is proportional to both the average blood glucose concentration and the life span of the red blood cells (RBC) in circulation. HbA1c values are free of day to day glucose fluctuations and are unaffected by exercise or recent food intake.

Dr. Gayatri M. Mehta

M. D. (Patho)

Reg. No. G-32215

DR GAYATRI MEHTA
MD(PATHOLOGY)

DR. ANAND D. PARIKH
MD(PATHOLOGY)

LAB USE ONLY (Entered by :GM Enter Date/Time:14/05/2023 11:41:00 AM) (Verify by :GM Verify Date/Time:14/05/2023 11:41:00 AM)

ISO 9001:2015 Certified Diagnostics Center

Vidhi Imaging Center | Pathology Department

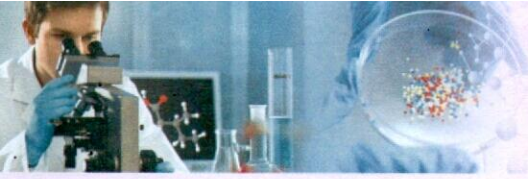L-86, Swatantra Senani Nagar, Opp. Akhbarnagar Petrol Pump, Nr. Akhbarnagar Circle, Nava-Vadaj, Ahmedabad - 380 013.

Ph. (Pathology) : 079-2762 1406, 8849893954 M. 98799 29406, 98250 09406, E-mail : vidhidiagnostics@gmail.com, Web. : www.vidhidiagnostics.com

Time (Pathology) : Mon. to Sat. 8.30 am to 8.00 pm, Sunday 9 am to 12 Noon

Pathology means science behind medicine

CT SCAN & CBCT FACILITY NOW AVAILABLE



Pathology Department



Patient's name : PARMAR PUSHPABEN
Age/Sex : 52 Years/Female
Referred by : Dr. MEDIWHEEL
Collection Time : 11:32

Reg. ID : P-788-23
Accession : 5434
Order Dt/time : 13/05/2023 11:32

Lipid Profile

Sample Type: Serum

| Test Name | Result | Units | Biological Reference Interval |
|---|--------|-------|-------------------------------|
| S. Cholesterol : Oxidase-esterase method. | 196 | mg/dl | 0 - 200 |
| S. Triglyceride : Enzymatic Colorimetry method | 97.2 | mg/dL | 0 - 200 |
| S. HDL - Cholesterol : Serum by Enzymatic method. | 39.9 | mg/dL | 35 - 65 |
| S. LDL - Cholesterol : Serum by Enzymatic method | 124.4 | mg/dL | 0 - 130 |
| S. VLDL - Cholesterol : | 19.44 | mg/dL | 0 - 30 |
| S. Chole/HDL.Ratio : | 4.91 | | 1 - 6 |
| S. LDL/ HDL Cholesterol Ratio : | 3.12 | | 0 - 3.5 |

Dr. Gayatri M. Mehta
M. D. (Patho)
Reg. No. G-32215
DR GAYATRI MEHTA
MD(PATHOLOGY)

DR. ANAND D. PARIKH
MD(PATHOLOGY)

LAB USE ONLY (Entered by :GM Enter Date/Time:14/05/2023 11:42:00 AM) (Verify by :GM Verify Date/Time:14/05/2023 11:42:00 AM)

ISO 9001:2015 Certified Diagnostics Center

Vidhi Imaging Center | Pathology Department

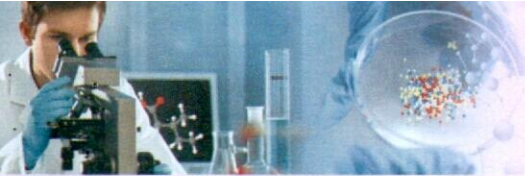L-86, Swatantra Senani Nagar, Opp. Akhbarnagar Petrol Pump, Nr. Akhbarnagar Circle, Nava-Vadaj, Ahmedabad - 380 013.

Ph. (Pathology) : 079-2762 1406, 8849893954 M. 98799 29406, 98250 09406, E-mail : vidhidiagnostics@gmail.com, Web. : www.vidhidiagnostics.com

Time (Pathology) : Mon. to Sat. 8.30 am to 8.00 pm, Sunday 9 am to 12 Noon

Pathology means science behind medicine

CT SCAN & CBCT FACILITY NOW AVAILABLE



Pathology Department



Patient's name : PARMAR PUSHPABEN
Age/Sex : 52 Years/Female
Referred by : Dr. MEDIWHEEL
Collection Time : 11:32

Reg. ID : P-788-23
Accession : 5434
Order Dt/time : 13/05/2023 11:32

Liver Function Test

Sample Type: Serum

| Test Name | Result | Units | Biological Reference Interval |
|---|--------|--------|-------------------------------|
| S.G.P.T (ALT) : Serum by IFCC method | 11.7 | U/L | 0 - 40 |
| S.G.O.T (AST) : Serum by IFCC method | 12.0 | U/L | 0 - 37 |
| ALK.PHOSPHATASE : Serum by PNP method | 49 | U/L | 35-104 |
| G.G.T : | 16.3 | U/L | 8 - 78 |
| <u>Bilirubin</u> | | | |
| Total : Serum by Diazo method | 0.57 | mg/dl | Up to 1.2 |
| Direct : Serum by Diazo method | 0.22 | mg/dl | 0-0.7 |
| Indirect : | 0.35 | mg/dl | 0 - 0.5 |
| <u>Serum Proteins</u> | | | |
| Total Protein, : Serum by Biuret method | 6.55 | gms/dl | 6.4 - 8.5 |
| Albumin : Serum by BCG method | 4.08 | gms/dl | 3.97-4.94 |
| Globulins : | 2.47 | gms/dl | 2.3 - 3.5 |
| A/G Ratio : | 1.652 | | 0.9 - 2.9 |

Dr. Gayatri M. Mehta
M. D. (Patho)

Reg. No. G-32215

DR GAYATRI MEHTA
MD(PATHOLOGY)

DR. ANAND D. PARIKH
MD(PATHOLOGY)

LAB USE ONLY (Entered by :GM Enter Date/Time:14/05/2023 11:42:00 AM) (Verify by :GM Verify Date/Time:14/05/2023 11:42:00 AM)

ISO 9001:2015 Certified Diagnostics Center

Vidhi Imaging Center | Pathology Department

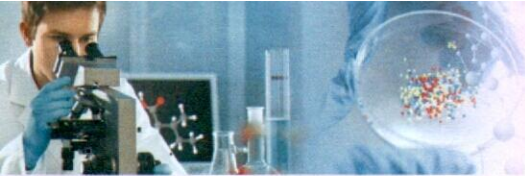L-86, Swatantra Senani Nagar, Opp. Akhbarnagar Petrol Pump, Nr. Akhbarnagar Circle, Nava-Vadaj, Ahmedabad - 380 013.

Ph. (Pathology) : 079-2762 1406, 8849893954 M. 98799 29406, 98250 09406, E-mail : vidhidiagnostics@gmail.com, Web. : www.vidhidiagnostics.com

Time (Pathology) : Mon. to Sat. 8.30 am to 8.00 pm, Sunday 9 am to 12 Noon

Pathology means science behind medicine

CT SCAN & CBCT FACILITY NOW AVAILABLE



Pathology Department

Patient's name : PARMAR PUSHPABEN
Age/Sex : 52 Years/Female
Referred by : Dr. MEDIWHEEL
Collection Time : 11:32

Reg. ID : P-788-23
Accession : 5434
Order Dt/time : 13/05/2023 11:32

Renal Function Test

Sample Type:

| Test Name | Result | Units | Biological Reference Interval |
|---|--------|--------|-------------------------------|
| Urea, Serum by GLDH method : | 22.7 | mg/dl | 10 - 50 |
| S.Uric acid, Serum by Uricase method : | 5.3 | mg/dl | 2.6-6.0 |
| Bun : | 10.6 | mg/dl | 6-20 |
| Creatinine, Serum by Enzymatic reaction : | 0.67 | mg/dl | 0.5-1.2 |
| <u>SERUM PROTEINS</u> | | | |
| Total Protein (Serum by Biuret method) : | 6.55 | gms/dl | 6.4 - 8.5 |
| Albumin (Serum by BCG method) : | 4.08 | gms/dl | 3.97-4.94 |
| Globulins : | 2.47 | gms/dl | 2.3 - 3.5 |
| A/G Ratio : | 1.652 | | 0.9 - 2.9 |

Dr. Gayatri M. Mehta
M. D. (Patho)
Reg. No. G-32215
DR GAYATRI MEHTA
MD(PATHOLOGY)

DR. ANAND D. PARIKH
MD(PATHOLOGY)

LAB USE ONLY (Entered by :GM Enter Date/Time:14/05/2023 11:43:00 AM) (Verify by :GM Verify Date/Time:14/05/2023 11:43:00 AM)

ISO 9001:2015 Certified Diagnostics Center

Vidhi Imaging Center | Pathology Department

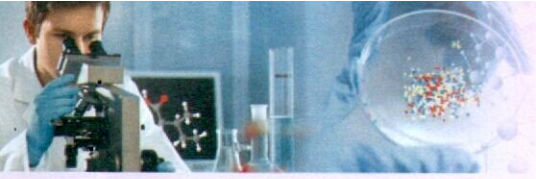L-86, Swatantra Senani Nagar, Opp. Akhbarnagar Petrol Pump, Nr. Akhbarnagar Circle, Nava-Vadaj, Ahmedabad - 380 013.

Ph. (Pathology) : 079-2762 1406, 8849893954 M. 98799 29406, 98250 09406, E-mail : vidhidiagnostics@gmail.com, Web. : www.vidhidiagnostics.com

Time (Pathology) : Mon. to Sat. 8.30 am to 8.00 pm, Sunday 9 am to 12 Noon

Pathology means science behind medicine

CT SCAN & CBCT FACILITY NOW AVAILABLE



Pathology Department



Patient's name : PARMAR PUSHPABEN
Age/Sex : 52 Years/Female
Referred by : Dr. MEDIWHEEL
Collection Time : 11:32

Reg. ID : P-788-23
Accession : 5434
Order Dt/time : 13/05/2023 11:32

Thyroid Function Test

Sample Type: Serum

| Test Name | Result | Units | Biological Reference Interval |
|------------------------|--------------|-------|-------------------------------|
| TOTAL T3 : | 0.85 | ng/ml | 0.84 - 2.0 |
| TOTAL T4 : | 6.7 | ug/dl | 5.1 - 14.0 |
| TSH(Ultra sensitive) : | <u>5.226</u> | mIU/L | 0.27 - 4.2 |

Dr. Gayatri M. Mehta
M. D. (Patho),
Reg. No. G-32215

DR GAYATRI MEHTA
MD(PATHOLOGY)

DR. ANAND D. PARIKH
MD(PATHOLOGY)

LAB USE ONLY (Entered by :GM Enter Date/Time:14/05/2023 11:52:00 AM) (Verify by :GM Verify Date/Time:14/05/2023 11:52:00 AM)

ISO 9001:2015 Certified Diagnostics Center

Vidhi Imaging Center | Pathology Department

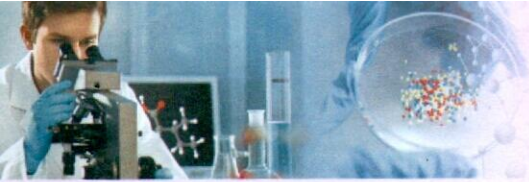L-86, Swatantra Senani Nagar, Opp. Akhbarnagar Petrol Pump, Nr. Akhbarnagar Circle, Nava-Vadaj, Ahmedabad - 380 013.

Ph. (Pathology) : 079-2762 1406, 8849893954 M. 98799 29406, 98250 09406, E-mail : vidhidiagnostics@gmail.com, Web. : www.vidhidiagnostics.com

Time (Pathology) : Mon. to Sat. 8.30 am to 8.00 pm, Sunday 9 am to 12 Noon

Pathology means science behind medicine

CT SCAN & CBCT FACILITY NOW AVAILABLE



Pathology Department



Patient's name : PARMAR PUSHPABEN
Age/Sex : 52 Years/Female
Referred by : Dr. MEDIWHEEL
Collection Time : 11:32

Reg. ID : P-788-23
Accession : 5434
Order Dt/time : 13/05/2023 11:32

Urine Analysis

Sample Type: Urine

| Test Name | Result | Units | Biological Reference Interval |
|---------------------------------------|-----------------------|--------|-------------------------------|
| <u>Physical Examination</u> | | | |
| Quantity : | 30 | ml | 0 - 500 ml |
| Colour : | Yellow | | Pale Yellow |
| Transparency : | Slight Turbid. | | Clear |
| Reaction : | Acidic | | 4.6 - 8.0 |
| Specific Gravity : | 1.025 | | 1.016 - 1.022 |
| Sediment : | Present | | |
| <u>Chemical Examination</u> | | | |
| Albumin : | Present (Faint Trace) | | Absent |
| Sugar : | NIL | | Absent |
| Acetone : | Absent | | Absent |
| Bile Salts : | Absent | | Absent |
| Bile Pigments : | Absent | | Absent |
| Urobilogen : | Absent | | Absent |
| Nitrites : | Absent | | Absent |
| <u>Microscopic Examination</u> | | | |
| Red blood Cells : | 2-3 | /h.p.f | Absent |
| Pus Cells : | 1-2 | /h.p.f | Absent |
| Epithelial Cells : | 2-3 | /h.p.f | < 10.0 |
| Amorphous : | Absent | /h.p.f | Absent |
| Bacteria : | Absent | /h.p.f | Absent |
| Crystals : | Absent | /h.p.f | Absent |
| Casts : | Absent | /h.p.f | Absent |
| Fungus : | Not seen | /h.p.f | Absent |

Dr. Gayatri M. Mehta
M. D. (Patho)

Reg. No. G-32215

DR GAYATRI MEHTA
MD(PATHOLOGY)

DR. ANAND D. PARIKH
MD(PATHOLOGY)

ISO 9001:2015 Certified Diagnostics Center

LAB USE ONLY (Entered by :GM) Ent Date/Time: 14/05/2023 11:53:00 AM Verify Date/Time: 14/05/2023 11:53:00 AM

L-86, Swatantra Senani Nagar, Opp. Akhbar Nagar Petrol Pump, Nr. Akhbar Nagar Circle, Nava-Vadaj, Ahmedabad - 380 013.

Ph. (Pathology) : 079-2762 1406, 8849893954 M. 98799 29406, 98250 09406, E-mail : vidhidiagnostics@gmail.com, Web. : www.vidhidiagnostics.com

Time (Pathology) : Mon. to Sat. 8.30 am to 8.00 pm, Sunday 9 am to 12 Noon

Pathology means science behind medicine

CT SCAN & CBCT FACILITY NOW AVAILABLE



To,

The Coordinator,
Mediwheel (Arcofemi Healthcare Limited)
Helpline number: 011- 41195959

Dear Sir / Madam,

Sub: Annual Health Checkup for the employees of Bank of Baroda

This is to inform you that the following spouse of our employee wishes to avail the facility of Cashless Annual Health Checkup provided by you in terms of our agreement.

| PARTICULARS OF HEALTH CHECK UP BENEFICIARY | |
|---|----------------------------|
| NAME | PUSHPABEN PARVINBHAIPARMAR |
| DATE OF BIRTH | 07-08-1970 |
| PROPOSED DATE OF HEALTH CHECKUP FOR EMPLOYEE SPOUSE | 13-05-2023 |
| BOOKING REFERENCE NO. | 23J52969100058456S |
| SPOUSE DETAILS | |
| EMPLOYEE NAME | MR. PARMAR PRAVIN V |
| EMPLOYEE EC NO. | 52969 |
| EMPLOYEE DESIGNATION | DAFTARY |
| EMPLOYEE PLACE OF WORK | AHMEDABAD,NAVRANGPURA |
| EMPLOYEE BIRTHDATE | 19-01-1965 |

This letter of approval / recommendation is valid if submitted along with copy of the Bank of Baroda employee id card. This approval is valid from **26-04-2023** till **31-03-2024**. The list of medical tests to be conducted is provided in the annexure to this letter. Please note that the said health checkup is a **cashless facility** as per our tie up arrangement. We request you to attend to the health checkup requirement of our employee's spouse and accord your top priority and best resources in this regard. The EC Number and the booking reference number as given in the above table shall be mentioned in the invoice, invariably.

We solicit your co-operation in this regard.

Yours faithfully,

Sd/-

Chief General Manager
HRM Department
Bank of Baroda

(Note: This is a computer generated letter. No Signature required. For any clarification, please contact Mediwheel (Arcofemi Healthcare Limited))

Medical Examination Report

Date : 13-05-2023

1. Personal Particulars

Name : Pushpaben Parmar

Age : 52 years Gender : Male / Female

Marital Status : Married

Past & Present Medical History : No Cataract surgery was done in both eye 7 years ago.


2. Clinical Medical Examination

Height : 143 cm


Weight : 51 kg


Blood Pressure : 120/78 mmHg


Pulse : 64 p/min

General Condition : 


Skin : 

Central Nervous System : 

Head & Neck : 

Cardiovascular System : 

Chest : 

Abdomen : 

Limbs : 

Last menstrual period : -

Vision: Right: 6/6 with spec NIG Left: 6/6 with spec NIG

Colour vision : Normal/Colour Blind

Personal Habit : NO

Remarks : Fit / ~~Unfit~~ for employment

Dr. Vidhi D. Modh


M.B.B.S

Dr's name, signature & chop Reg. No. G-14540

Vidhi Diagnostics
L-85, Swatantra-Senani Nagar,
Opp. Akhbarnagar Bus Terminals,
Nr. Akhbarnagar Circle,
New Wadaj, Ahmedabad-13.

HR : 64 bpm
 PR : 146 ms
 QRS : 96 ms
 QT/QTc : 378/390 ms
 P/QRS/T : 52/51/95 deg.
 RV5/SV1 : 1.330/-0.876 mv
 RV5+SV1 : 2.206 mv

** borderline ECG **
 Sinus rhythm
 Nonspecific T wave abnormality

Vidhi Diagnostics

L-86, Swatantra-Senani Nagar,
 Opp. Akhbarnagar Bus Terminals,
 Nr. Akhbarnagar Circle,
 New Wadaj, Ahmedabad-13.

Name: pushpaben parmar

Age: 52yrs

Sex: Female

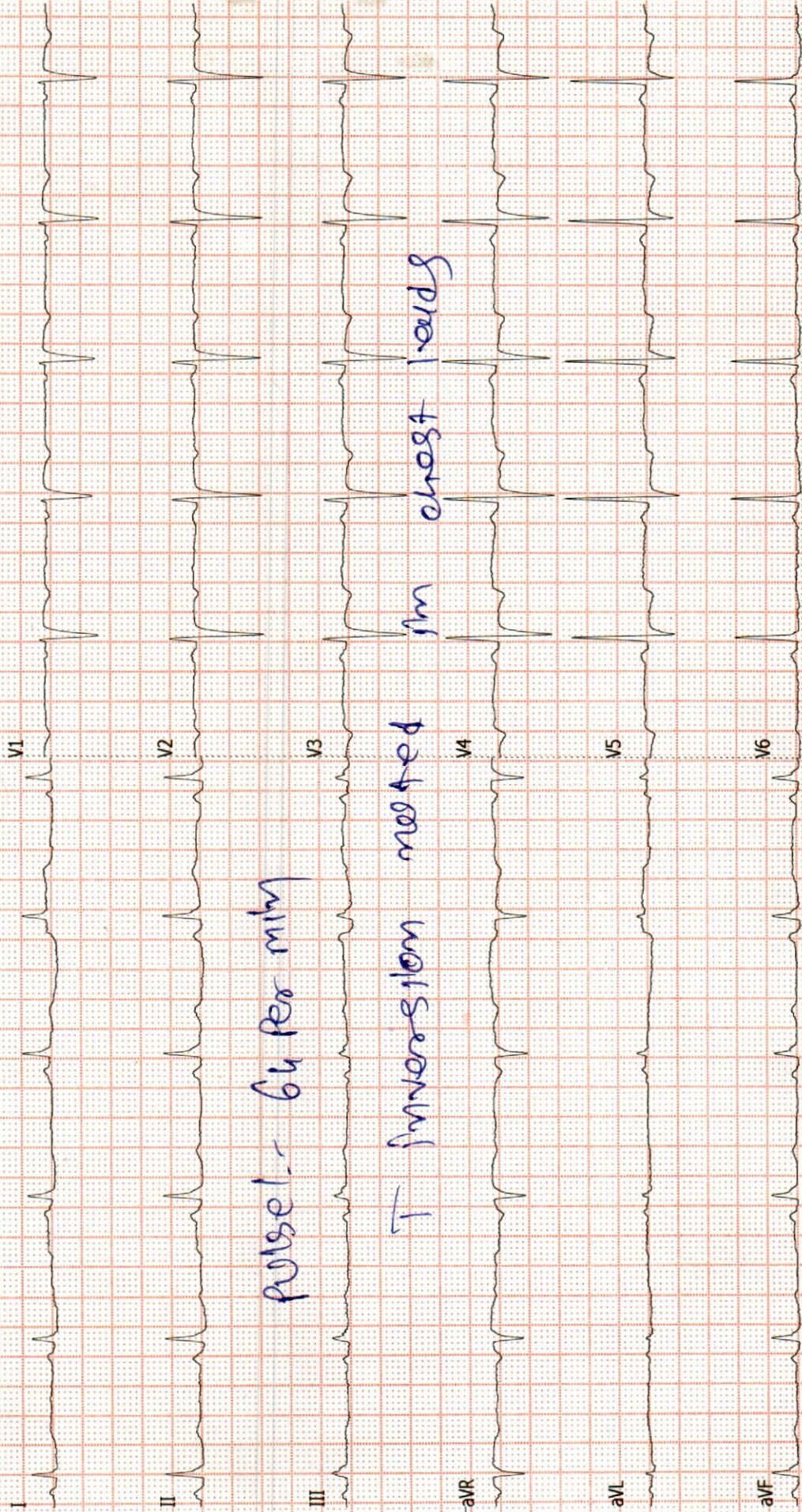Hospital:

Dr. Avinash Bhoskar
 MBBS, D Cardio

Department: Reg. No.: G-45946

0.67Hz - 35Hz AC 50Hz 25 mm/s 10 mm/mv

Need to be confirmed by doctor. Doctor Name:



Dr. Dinesh S. Modh

M.D., D.M.R.E. (Radiodiagnosis)

Consultant Radiologist & Sonologist

Ex. Junior Lecturer, B.J. Medical College, Civil Hospital, A'bad.

Panel Doctor of L.I.C.



Patient's name : PUSHPABEN PARMAR
Reg. ID : R-1680-23
Referred by : Dr. MEDIWHEEL

Age/Sex : 52 Years/Female
Accession : 5430
Date : 13/05/2023

X-RAY CHEST (PA VIEW)

Both lung fields appear normal.
No e/o consolidation or cavitations is seen.
Both costo-phrenic angles appear clear.
Cardiac size is within normal limits.
Both domes of diaphragm appear normal.
Bony thoracic cage appears normal.

Thanks for reference.

Dr. Dinesh S. Modh
MD DMRE (Radiodiagnosis)
G-23825

DR DINESH S. MODH

M.D. DMRE(RADIODIAGNOSIS)

ISO 9001:2015 Certified Diagnostics Center

Vidhi Imaging Center

L-86, Swatantra Senani Nagar, Opp. Indian Oil Petrol Pump, Akhbarnagar Circle, Nava Vadaj, Ahmedabad - 380 013.

Phone : (Radiology) 079-2762 1406 | M. 98799 29406, 98250 09406 | Time (Radiology) : Mon. to Sat. 9 am to 2 pm, 5 to 9 pm, Sunday 9 am to 12 Noon
E-mail : vidhidiagnostics@gmail.com, Website : www.vidhidiagnostics.com

Multislice CT Scan | CBCT-Dental Scan | Live 3D-4D Sonography | Colour Doppler | Echo Cardiography | Interventional Radiology | Maxillofacial Radiology | Fetal Medicine
Digital X-Ray | Digital Mammography | Digital OPG/TMJ | ECG/TMT/PFT/EEG/EMG | Audiometry | Pathology Laboratory | Health Check Up Plans | Pre Employment Check Up

CT SCAN & CBCT FACILITY NOW AVAILABLE

Dr. Dinesh S. Modh

M.D., D.M.R.E. (Radiodiagnosis)

Consultant Radiologist & Sonologist

Ex. Junior Lecturer, B.J. Medical College, Civil Hospital, A'bad.

Panel Doctor of L.I.C.



Patient's name : PUSHPABEN PARMAR
Reg. ID : R-1680-23
Referred by : Dr. MEDIWHEEL

Age/Sex : 52 Years/Female
Accession : 5430
Date : 13/05/2023

DIGITAL MAMMOGRAPHY

Digital mammography was done on Siemens mammomat-3000.

Reason for exam: - Screening.

Bilateral digital cranio-caudal and medio-lateral oblique views were taken.

The breast tissue is homogeneously dense with fibro-fatty tissue on both sides.

No masses, no architectural distortion, no suspicious calcifications, no asymmetries or other abnormalities are seen.

No e/o radio-opaque or radiolucent mass lesion is seen.

No e/o skin thickening is seen.

Nipple and sub-areolar tissue appear normal.

Axillary tail appears normal.

USG:-Normal.

Assessment:-Negative (BI-RADS category-1)

BI-RADS category

- 0- incomplete
- 1- Negative
- 2- Benign
- 3- Probably benign
- 4- Suspicious abnormality.
- 5- Highly suggestive of malignancy
- 6- Known biopsy-proven malignancy.

The false negative mammography is approximately 10%. Management of palpable abnormality must be based upon clinical grounds.

Thanks for reference.

Dr. Dinesh S. Modh
MD DMRE (Radiodiagnosis)

DR DINESH S. MODH

M.D. DMRE(RADIODIAGNOSIS)

ISO 9001:2015 Certified Diagnostics Center

Vidhi Imaging Center

L-86, Swatantra Senani Nagar, Opp. Indian Oil Petrol Pump, Akhbarnagar Circle, Nava Vadaj, Ahmedabad - 380 013.

Phone : (Radiology) 079-2762 1406 | M. 98799 29406, 98250 09406 | Time (Radiology) : Mon. to Sat. 9 am to 2 pm, 5 to 9 pm, Sunday 9 am to 12 Noon

E-mail : vidhidiagnostics@gmail.com, Website : www.vidhidiagnostics.com

Multislice CT Scan | CBCT-Dental Scan | Live 3D-4D Sonography | Colour Doppler | Echo Cardiography | Interventional Radiology | Maxillofacial Radiology | Fetal Medicine
Digital X-Ray | Digital Mammography | Digital OPG/TMJ | ECG/TMT/PFT/EEG/EMG | Audiometry | Pathology Laboratory | Health Check Up Plans | Pre Employment Check Up

CT SCAN & CBCT FACILITY NOW AVAILABLE

Dr. Dinesh S. Modh

M.D., D.M.R.E. (Radiodiagnosis)

Consultant Radiologist & Sonologist

Ex. Junior Lecturer, B.J. Medical College, Civil Hospital, A'bad.

Panel Doctor of L.I.C.



Patient's name: PUSHPABEN PARMAR
Reg. ID : R-1680-23
Referred by : Dr. MEDIWHEEL

Age/Sex : 52 Years/Female
Accession : 5430
Date : 13/05/2023

USG ABDOMEN

LIVER: - Liver appears normal in size & show normal echotexture. No evidence of diffuse or focal lesion is seen. Intrahepatic biliary radicals appear normal. Portal vein and CBD appear normal. No e/o calculus is seen in bile duct.

GALL BLADDER: - Gall bladder is distended & appears normal. No evidence of calculus or cholecystitis is seen. No evidence of pericholecystic fluid is seen.

SPLEEN: - Spleen appears normal in size & shows normal echotexture. No evidence of diffuse or focal lesion is seen.

PANCREAS: - Pancreas appears normal size and echopattern. No e/o diffuse or focal lesion is seen. Main pancreatic duct appears normal.

KIDNEY: - Both Kidneys appear normal in size & echotexture.

No e/o calculus or hydronephrosis or hydroureter is seen in either side.

Cortico-medullary differentiation is maintained on either side.

Both suprarenal regions appear normal.

RIF & BOWEL LOOPS (By high frequency probe): - Normal.

No evidence of pre & para aortic lymphadenopathy is seen.

No evidence of free fluid is seen in abdomen.

No evidence of dilated or thickened bowel loops is seen.

Urinary bladder: - appears normal. No e/o calculus or mass lesion is seen in bladder.

Uterus appears normal in size and echopattern.

No evidence of diffuse or focal lesion is seen.

Both adnexal regions appear normal.

No e/o free fluid is seen in pouch of Douglas.

Thanks for reference.

Dr. Dinesh S. Modh
MD DMRE (Radiodiagnosis)
G-23825

DR DINESH S. MODH

M.D. DMRE(RADIODIAGNOSIS)

ISO 9001:2015 Certified Diagnostics Center

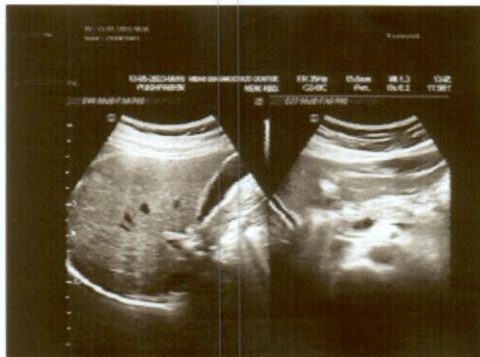
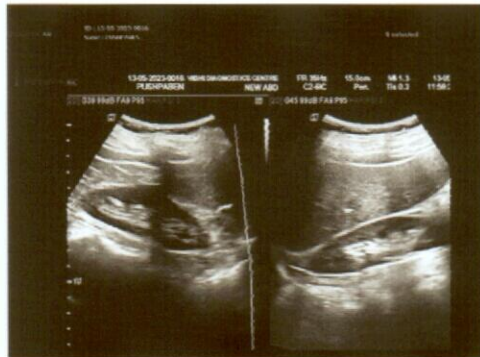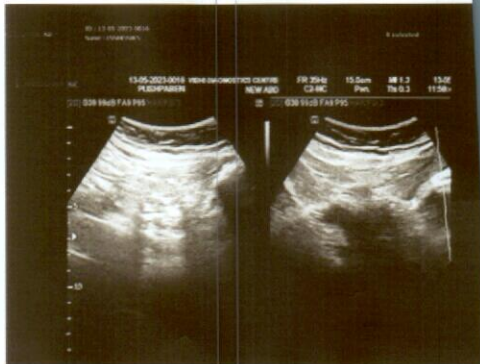
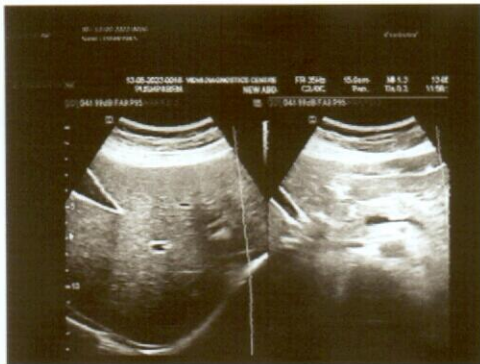
Vidhi Imaging Center

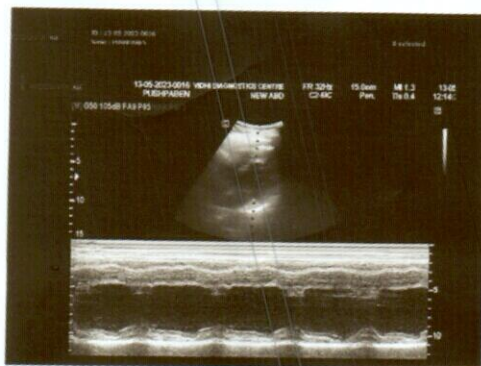
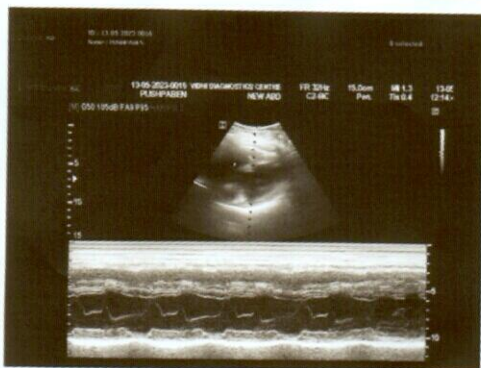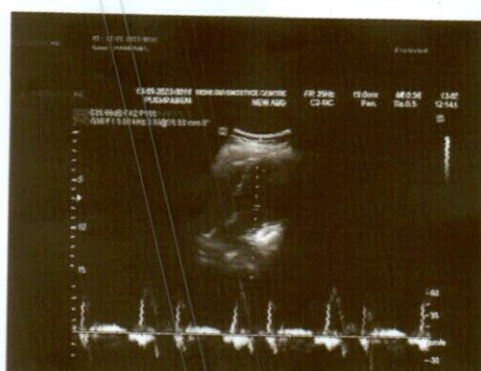
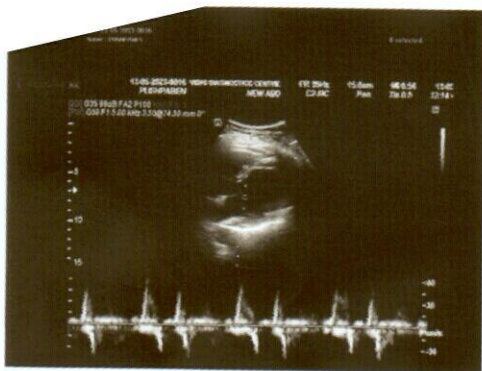
L-86, Swatantra Senani Nagar, Opp. Indian Oil Petrol Pump, Akhbarnagar Circle, Nava Vadaj, Ahmedabad - 380 013.

Phone : (Radiology) 079-2762 1406 | M. 98799 29406, 98250 09406 | Time (Radiology) : Mon. to Sat. 9 am to 2 pm, 5 to 9 pm, Sunday 9 am to 12 Noon
E-mail : vidhidiagnostics@gmail.com, Website : www.vidhidiagnostics.com

Multislice CT Scan | CBCT-Dental Scan | Live 3D-4D Sonography | Colour Doppler | Echo Cardiography | Interventional Radiology | Maxillofacial Radiology | Fetal Medicine
Digital X-Ray | Digital Mammography | Digital OPG / TMJ | ECG / TMT / PFT / EEG / EMG | Audiometry | Pathology Laboratory | Health Check Up Plans | Pre Employment Check Up

CT SCAN & CBCT FACILITY NOW AVAILABLE





હતો ત્યારબાદ રાષ્ટ્રીય આયોજન અને તપાસ
લેનો ઉપયોગ કરવામાં આવે
ર ઘટિ પણા



ભારતીય વિશિષ્ટ ઓળખાણ પ્રાધિકરણ

ભારત સરકાર

Unique Identification Authority of India

Government of India


નોંધણીની ઓળખ / Enrollment No.: 2141/43473/00490

To,
પરમાર પુષ્પાબેન
Parmar Pushpaben
W/O: Pravinbhai
C-501
Akshya Recidency
Sneh Plaza Chandkheda
Ahmedabad
Chandkheda Ahmadabad City Ahmedabad
Gujarat 382424

Ref: 3187 / 290 / 226085 / 226161 / P



SB247100364FH



તમારો આધાર નંબર / Your Aadhaar No. :

7611 6800 6510

મારો આધાર, મારી ઓળખ




ભારત સરકાર

Government of India



પરમાર પુષ્પાબેન
Parmar Pushpaben
જન્મ તારીખ / DOB : 07/08/1970
સ્ત્રી / Female



7611 6800 6510

મારો આધાર, મારી ઓળખ

Dr. Vidhi D. Modh
MBBS
Reg. No. G-74540

Vidhi Diagnostics
L-86, Swatantra-Senani Nagar,
Opp. Akhbarnagar Bus Terminals,
Nr. Akhbarnagar Circle,
New Wadaj, Ahmedabad-13.



May 13, 2023 11:27:48 AM

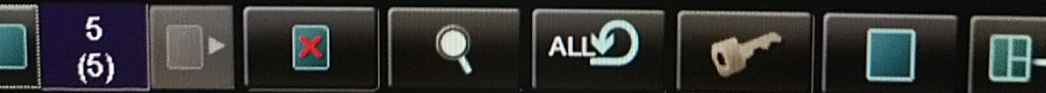
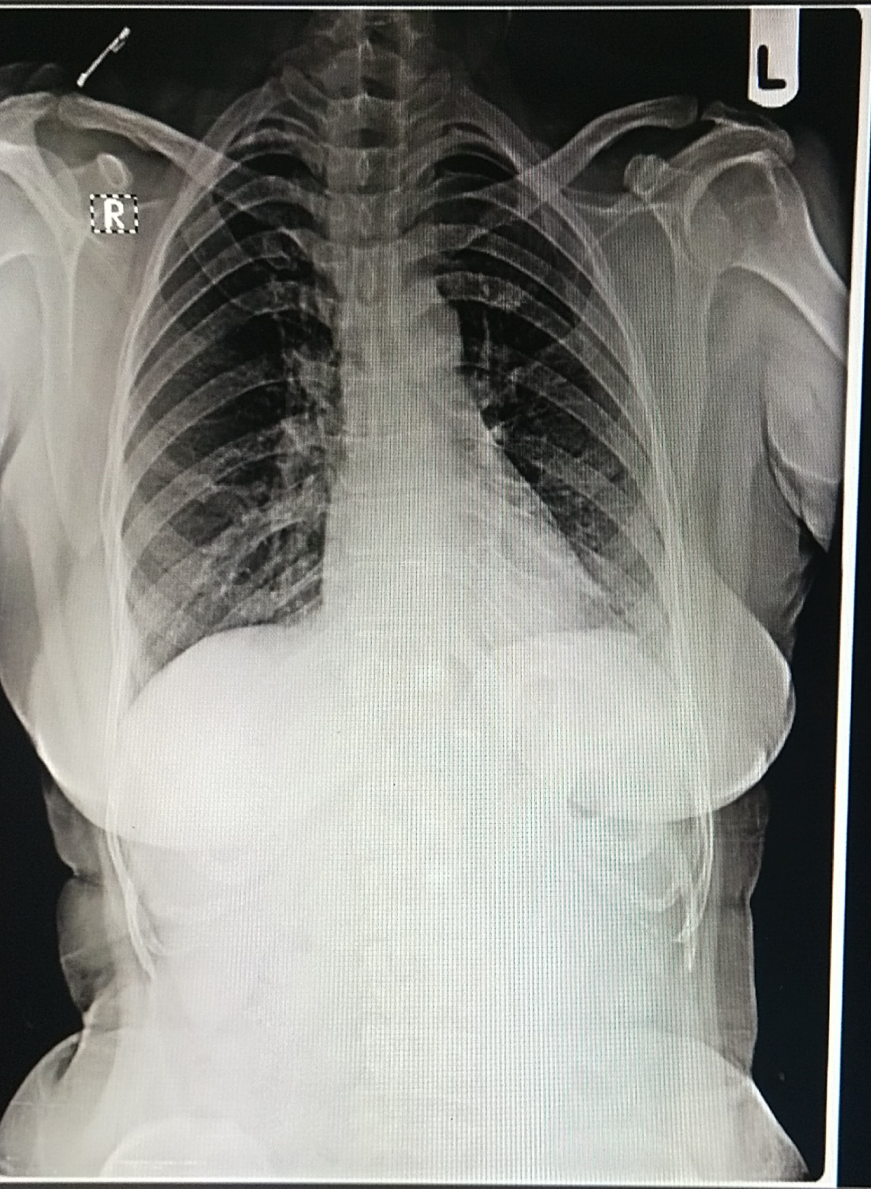
Nirnay Nagar
Ahmedabad
Gujarat

Vidhi Diagnostics

L-86, Swatantra-Senani Nagar,
Opp. Akhbarnagar Bus Terminals,
Nr. Akhbarnagar Circle,
New Vadaj, Ahmedabad-13.

Dr. Vidhi D. Modh
MBBS
Reg. No. 8-74540

009
PUSHPABEN PARMAR 52/Y



DELL