

28/3/22

Mr. Chandrdeep Tigga
42/M.

Eye check up

	(R)	(L)
VA	G/G N ₆ ⓐ	G/G N ₆ ⓐ
M/S	ⓐ	ⓐ
Color vn	ⓐ	ⓐ
Glucose chart		ⓐ
Fundus :	ⓐ	

nppe both eyes: within normal limits
y

ECHO Report

Date- 27/03/2022

Patient Details

Patient ID –

Name- MR CHANDRADEEP TIGGA
Age- 42 YEARS
Gender- MALE
Blood Group NOT DETERMINED
Referral Doctor MEDIWHEEL

ECHO Identification Detail

Doctor Incharge DR MAHESH PADSALGE

Clinical Status of Patient

ECHO Code

Finding description-

- 1. Normal cardiac chambers dimensions.**
- 2. Normal LV systolic function .**
- 3. No RWMA.**
- 4. All cardiac valves are structurally normal.**
- 5. Trivial MR, Trivial PR,NO AR.**
- 6. No PAH.**
- 7. Normal RV systolic function.**
- 8. No clot/vegetation/pericardial effusion.**
- 9. No coarctation of aorta.**

Chamber Dimensions-M mode Findings

Lvid (Diastole) 35-56(mm)	-	44.00	Lvid (Systole) 24-42 (mm)	-	28.00
IVS (Diastole) 8-12(mm)	-	10.00	IVS (Systole) 14-42 (mm)	-	40.00
LVPWT (Diastole) 6-11(mm)	-	10.00	EPSS	-	4.00
LVEF (%)	-	65%	LVFS (%)	-	36.00

LV Volume (Diastolic)(mm3)

Meridional Wall Stress in System

Cubed LV+ myocardial volume (mm3)

Aortic root 22-37(mm)	-	25.00
Left Atrium Length (mm)	-	24.00
Left Atrium Volume (mm3)		
RV size		Normal
RV volume (mm3)		
Pericardium		Normal
Effusion		None
Resp Variation		Present
Predicted RV Systolic Pressure		

LV Volume (Systolic)(mm3)

Cubbed LV Volume in Diastole (mm3)

Velocity of circumferential Shortening (mm)

Left Atrium Width (mm)		
Left Atrium Area (mm2)		
RV Function		Normal
RA Size		Normal

IVC Size (mm) 13 COLLAPSIBLE

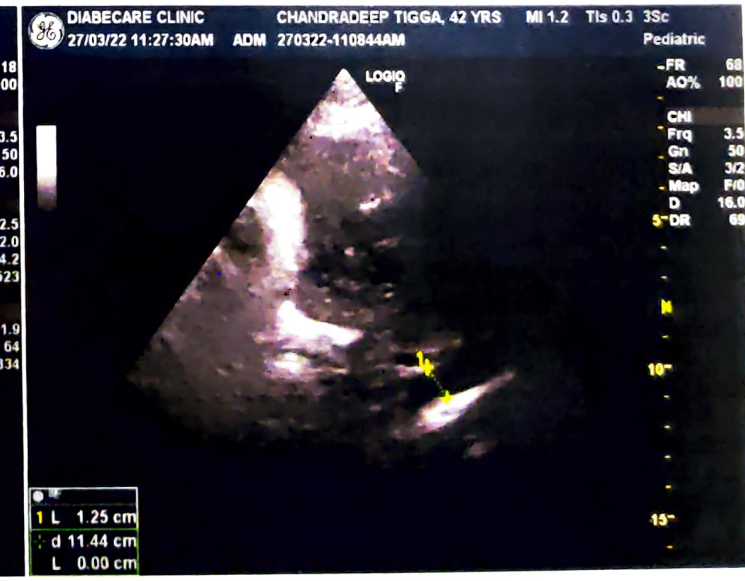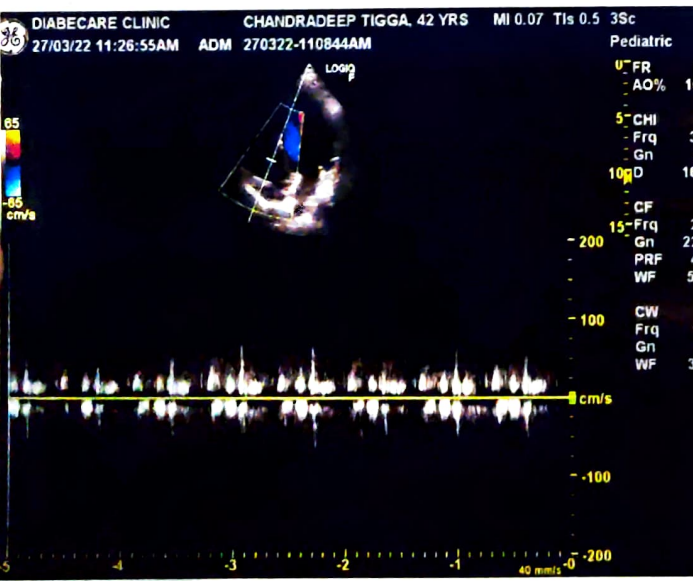
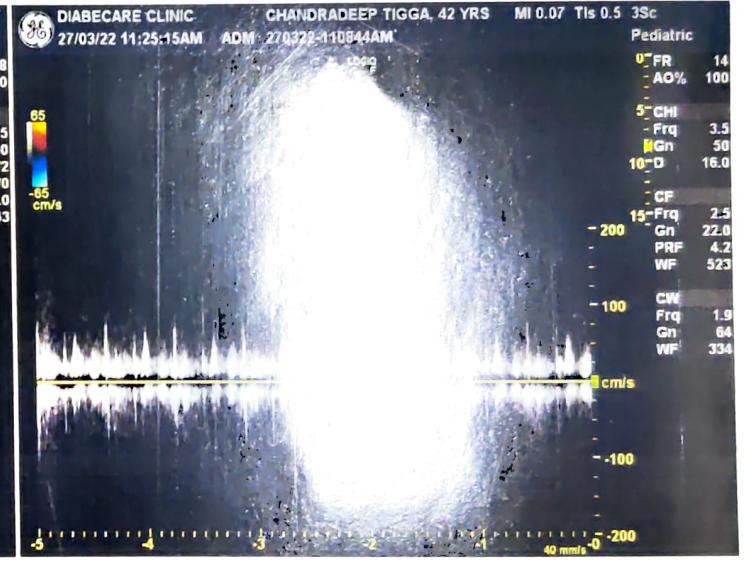
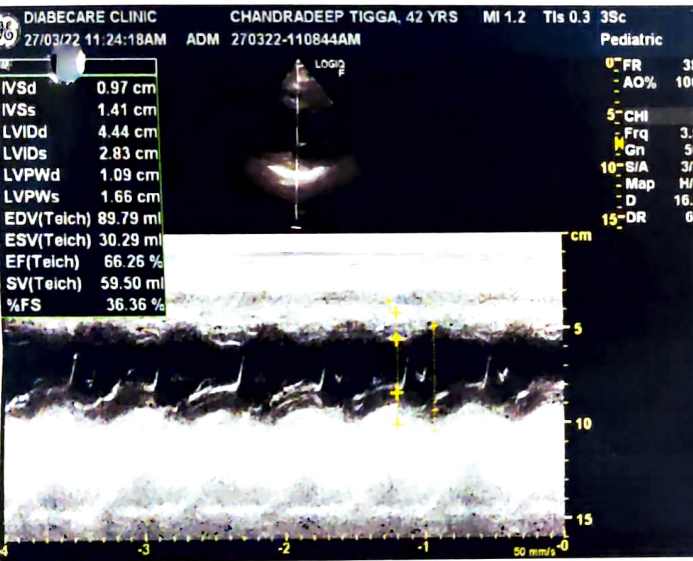
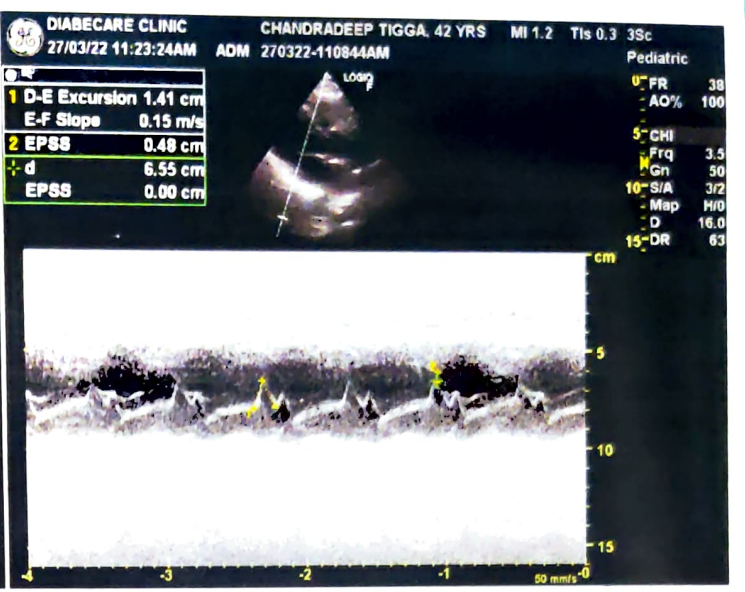
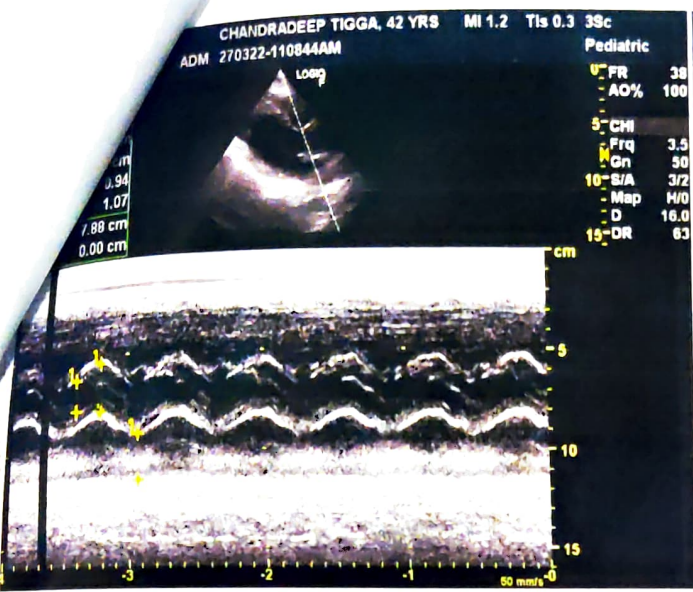


Dr. Mahesh Padsalge



Dr. Mahesh V. Padsalge

MD. (Medicine)
 Consultant Physician
 Reg. No. 91424 (MMC)



Name : MR CHANDRADEEP TIGGA	Age/sex: 42 Yrs. /MALE
Ref by: MEDIWHEEL	Date: 28-Mar-22

ULTRASOUND EXAMINATION OF ABDOMEN & PELVIS

Findings-

The Liver is normal in size, shape and echogenicity. No focal lesion is seen. The Hepatic veins appear normal. There is no IHBR dilatation. The portal vein appears normal.

The gall bladder is distended . The proximal C.B.D. is normal caliber

Visualized head of Pancreas appears normal in size and reflectivity. The pancreatic duct is not dilated. Rest of the pancreas and retro peritoneum is obscured by bowel gases

The spleen is normal in size, No focal lesion is seen. Splenic vein is normal at hilum.

Both kidneys are normal in position and size. They show normal cortical reflectivity and cortico-medullary differentiation. There is no evidence of renal calculus, hydronephrosis or mass.

Right kidney measures 9.0 x 4.0 cm

Left kidney measures 9.2 x 4.5 cm

The Urinary bladder is partially distended. No evidence of any intraluminal mass or calculi.

The visualized Prostate appears normal in size, shape and homogenous echotexture, its measures 2.9x 3.4 x 3.4cm-18 cc

There is no free fluid is seen in the pelvis. No probe tenderness in present study.

IMPRESSION :-

- **No significant abnormality is seen in present study.**
- **Adv : clinical correlation.**

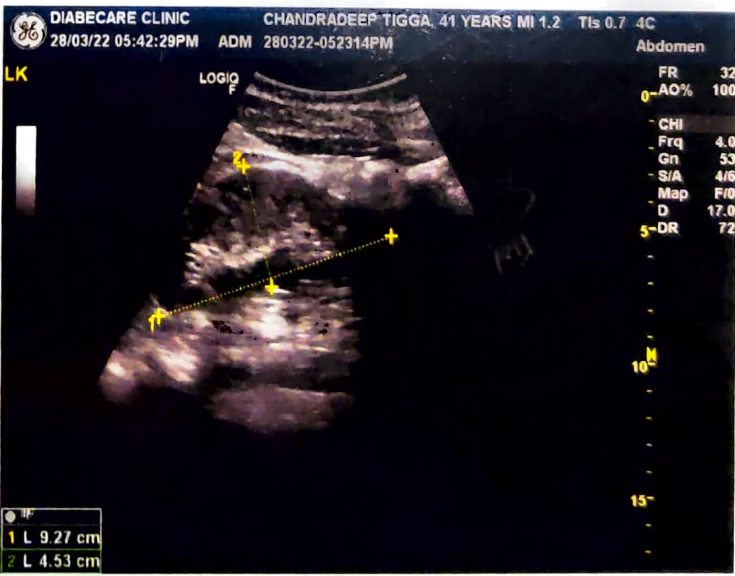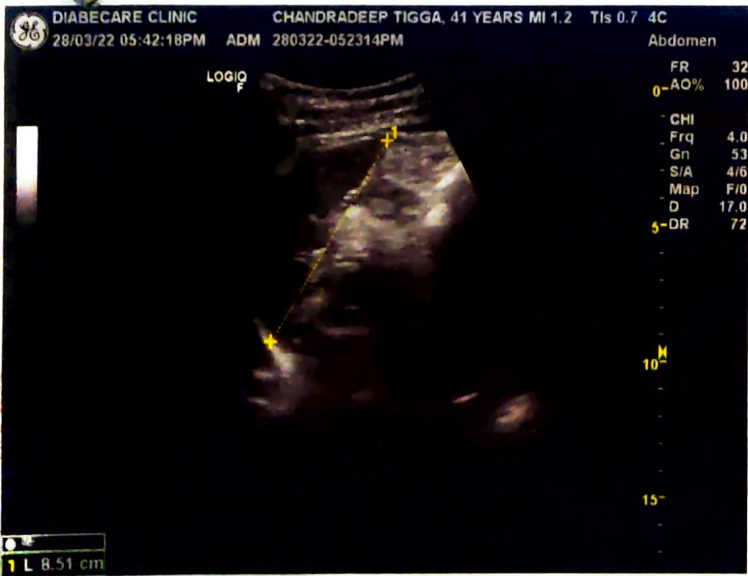
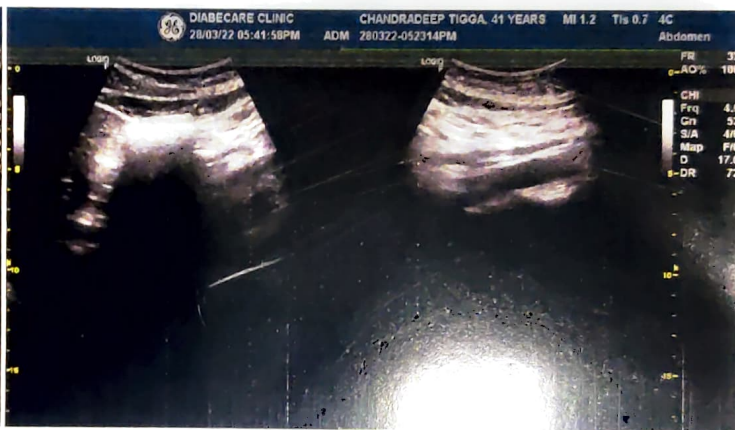
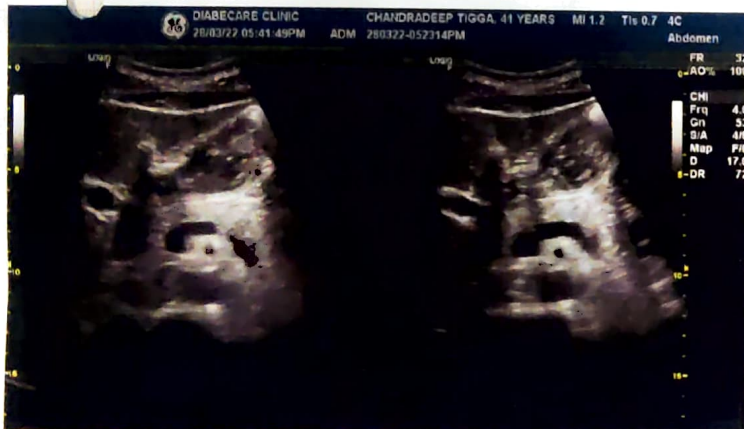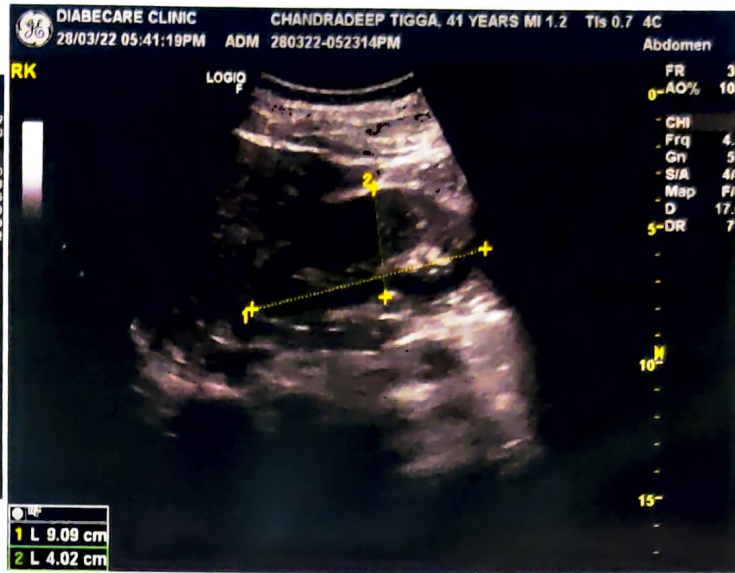
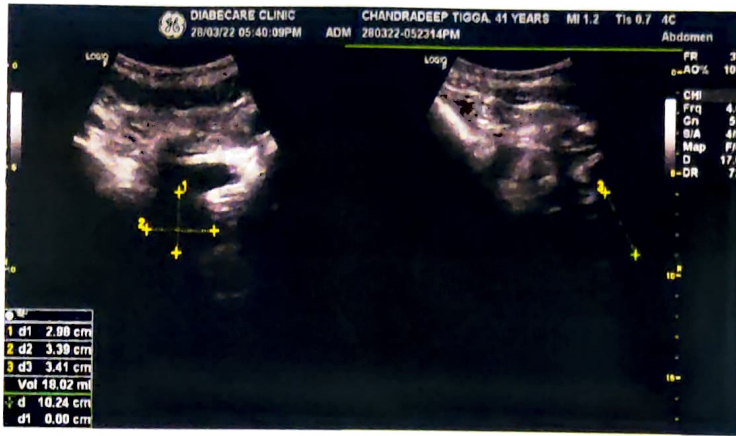


Dr. MRUDULA BABAR
CONSULTANT RADIOLOGIST

Dr. MRUDULA BABAR
DMRE.CPS Mumbai 2009
(RADIOLOGIST)
Reg. No. 2005/03/2139

93 bpm

Vital Signs™ 226 166 05



Chandradeep tiggla
ID: ct

Male

27.03.2022 10:55:36
DIABETES, DIABETES & ENDOCRINE
OPP. GRAND CENTRAL MALL
SEAWOOD

93 bpm
-- / -- mmHg

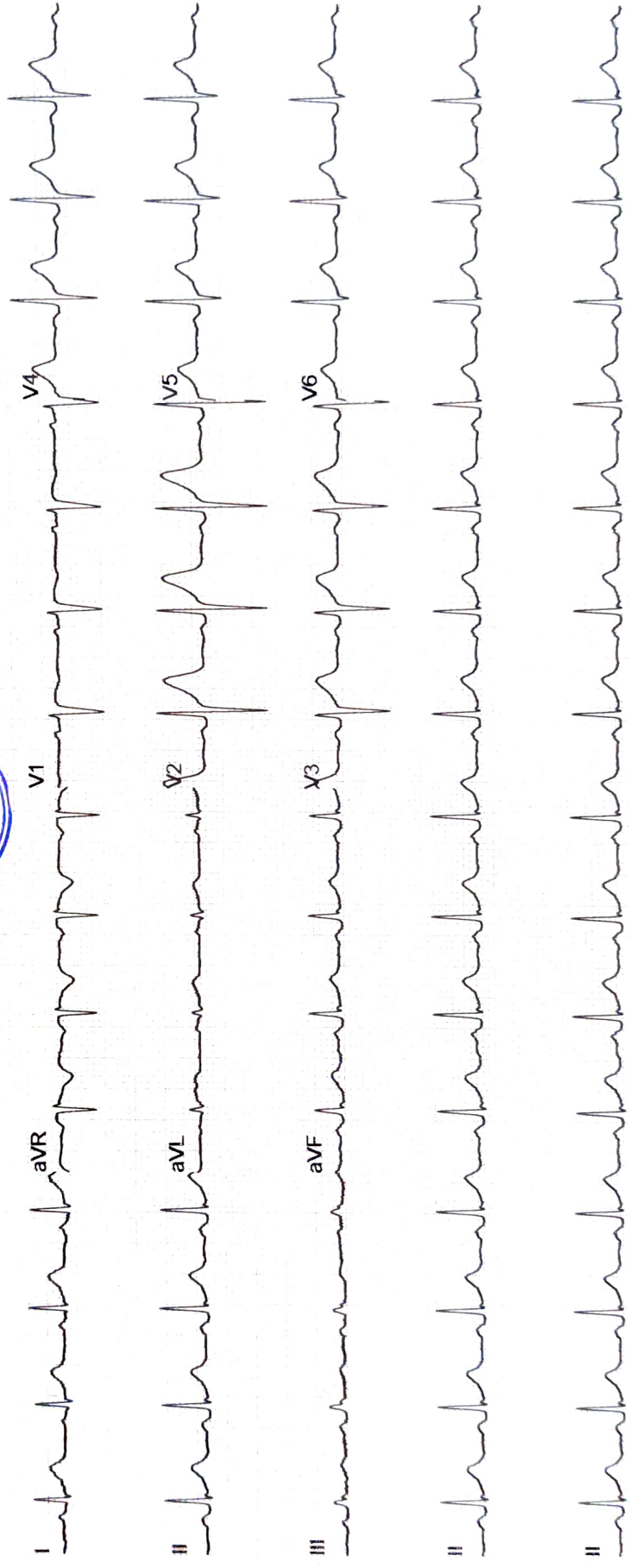
CS
within normal limit

Normal sinus rhythm
Normal ECG

QRS : 72 ms
QT / QTcBaz : 340 / 422 ms
PR : 138 ms
P : 94 ms
RR / PP : 644 / 645 ms
P / QRS / T : 48 / 48 / 33 degrees



Dr. Mahesh V. Padsalge
MD. (Medicine)
Consultant Physician
Reg. No. 91424 (MMC)




भारत सरकार
GOVERNMENT OF INDIA


चंद्रदीप टिग्गा
Chandrdeep Tigga
DOB: 18-11-1980
Gender: Male




4065 6099 6359

आधार - आम आदमी का अधिकार


Handwritten signature




Dr. Mahesh V. Padsalge
 MD. (Medicine)
 Consultant Physician
 Reg. No. 91424 (MMC)


भारतीय विशिष्ट पहचान प्राधिकरण
UNIQUE IDENTIFICATION AUTHORITY OF INDIA

विवरण/आईडी नं: थड्डेडस टिग्गा, फ्लॉट नं 605, ए/4, हिमालया नीपचएस लिमिटेड, लोकधाणा, आईसीआईसी बैंक जवळ, कल्याण ईस्ट, कल्याण, काटेमनिवाली, कल्याण, ठाणे, महाराष्ट्र, 421306

Address:
S/o: Thaddeus Tigga, Flat No 605, A/4, Himalaya Chs Ltd, Lokdhana, Near Icici Bank, Kalyan East, Kalyan, Katenanivali, Kalyan, Thane, Maharashtra, 421306



1947 1800 300 1947  help@uidai.gov.in  www.uidai.gov.in  P.O. Box No.1947, Bengaluru-560 081



NAME - CHANDRDEEP TIGGA

DATE- 27/03/2022

AGE- 42/M

X-RAY CHEST PA

THE SOFT TISSUES AND BONY THORAX ARE NORMAL.

BOTH THE COSTOPREHNIC AND CARDIOPHRENIC ANGLES ARE CLEAR.

THE LUNG FIELDS ARE NORMAL.

CARDIAC SHAPE AND SIZE APPEARS NORMAL.

BOTH THE HILA ARE NORMAL IN DENSITY AND POSITION.

BOTH THE DOMES OF DIAPHRAGM AND MEDIASTINUM ARE NORMAL.

IMPRESSION: NORMAL CHEST X-RAY.

For, [Signature]

DR. VIJAYA WARUDKAR
RADIOLOGIST

Dr. VIJAYA WARUDKAR
DMRD (Mumbai 2003)
(RADIOLOGIST)
Reg. No. 2003/08/2853