

Dr. Vandana G. Powar M.B.B.S., D.C.P.
Consultant Pathologist



PARTH
PATHOLOGY LABORATORY
(Computerised)

LAB - Shop No. 7, "Diwan Towers" Mangalwar Peth, Near Mirajkar Tikli, Opp. Nutan Marathi High School, Kolhapur. Mob. 9158529408, 9422047480, 9921285167

DATE – 11/01/2023

INS .COMPANY – MEDIWHEEL LIFE INS.

PATIENT NAME- RUPALI KAMBLE

AGE – 32/ FEMALE

HEIGHT – 143 cm

WEIGHT – 73 kg

BLOOD PRESSURE – 139mmHg /95mmHg

PULES - 86

FIT TO PERFORM TO ALL DUTIES

LABORATORY
PATHOLOGIST
Dr. Vandana G. Powar
M.B.B.S., D.C.P.
Reg. No. 68137

All Biochemistry Tests Done By Computerised Auto Analyser

HAEMATOLOGY | CLINICAL PATHOLOGY | BIOCHEMISTRY | SEROLOGY | MICROBIOLOGY | HISTOPATHOLOGY

24 Hours Emergency Service

Home Service Available

भारत सरकार
GOVERNMENT OF INDIA

रूपाली अमर कांबळे
Rupali Amar Kamble

जन्म वर्ष / Year of Birth : 1990
स्त्री / Female

7493 2246 1772

आधार - सामान्य माणसाचा अधिकार

Rokamble

Power
Dr. Vandana G. Power
M.B.B.S., D.C.P.
Reg. No. 68137





AB - Shop No. 7, "Diwan Towers" Mangalwar Peth, Near Mirajkar Tikti, Opp. Nutan Marathi High School, Kolhapur. Mob. 9158529408, 9422047480, 9921285167

NAME : MRS. RUPALI KAMBLE

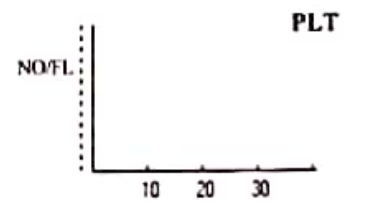
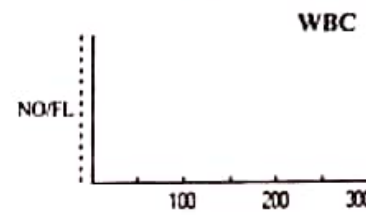
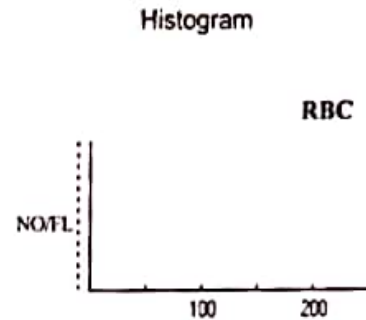
DATE : 11/01/2023 PT.NO. : 204 11012

REF BY : Dr. MEDIWHEEL LIFE INS

AGE : 32. Yrs. SEX : F

HAEMOGRAM WITH INDICES

Test	Result	Units	Normal Range
Haemoglobin	12.7	g/dl	12-16
RBC Count	4.55	millions / cu-mm	4.5 - 6.5
PCV	40.3	%	40 - 54
MCV	88.6	fL	80 - 96
MCH	27.9	Pg	27 - 33
MCHC	31.5	gm/dl	33 - 36
RDW CV	13.3	%	11.0 - 14.5
WBC Count	9200	/cumm	4000 - 11000
Neutrophils	75	%	55 - 75
Lymphocytes	20	%	20 - 50
Eosinophils	03	%	1 - 6
Monocytes	02	%	2-10
Basophils	00	%	0 - 1
Platelet Count	274000	/ul	150000 - 450000
MPV	8.4	fL	7.4 - 10.4
PDW	9.4	%	8-12
P-LCR	14.4	%	15-35
E.S.R.	09	mm at 1hr	0-15
(By Wintrobe Method)			
RBC Morphology	Normochromic, Normocytic.		
WBC Morphology	Within Normal Limits		
Platelets	Adequate		



* Blood group - 'O' Rh Positive

Dr. Vandana G. Powar
M.B.B.S., D.C.P.
Reg. No. 68137



PATHOLOGIST

DR. VANDANA POWAR
M.B.B.S., D.C.P.

All Biochemistry Tests Done By Computerised Auto Analyser

HAEMATOLOGY | CLINICAL PATHOLOGY | BIOCHEMISTRY | SEROLOGY | MICROBIOLOGY | HISTOPATHOLOGY

24 Hours Emergency Service

Home Service Available



PT.NAME : MRS. RUPALI KAMBLE
REF. BY : DR. MEDIWHEEL LIFE INS

DATE : 11/01/2023
AGE : 32 Yrs. SEX : F
PT.NO. : 204 110123

BIOCHEMISTRY TEST REPORT

			<u>Normal Range</u>
Fasting Plasma Glucose	: 88.5	mg/dl	60-110 mg/dl
2 Hrs. Plasma Glucose	: 112.3	mg/dl	90-140 mg/dl
S. Creatinine	: 0.7	mg/dl	0.6 - 1.4 mg/dl
Blood Urea	: 20.7	mg/dl	12-42 mg/dl
Blood Urea Nitrogen	: 9.67	mg/dl	5 - 21 mg/dl
S. Uric acid	: 4.8	mg/dl	2.6 -6.0 mg/dl
CHOLESTEROL	: 158.9	mg/dl	0-250 mg/dl
HDL Cholesterol	: 33.2	mg/dl	30 - 70 mg/dl
S. Triglycerides	: 97.6	mg/dl	0-170 mg/dl
LDL Cholesterol	: 106.2	mg/dl	60 - 150 mg/dl
TC/HDL Ratio	: 4.8		0 - 5
LDLC/HDL Ratio	: 3.2		2.5 - 3.5

Dr. Vandana G. Powar
M.B.B.S., D.C.P.
Reg No. 68137



PATHOLOGIST

DR. VANDANA POWAR
M.B.B.S., D.C.P.

All Biochemistry Tests Done By Computerised Auto Analyser

HAEMATOLOGY | CLINICAL PATHOLOGY | BIOCHEMISTRY | SEROLOGY | MICROBIOLOGY | HISTOPATHOLOGY

24 Hours Emergency Service

Home Service Available

Dr. Vandana G. Powar M.B.B.S., D.C.P.
Consultant Pathologist



PARTH
PATHOLOGY LABORATORY
(Computerised)

LAB - Shop No. 7, "Diwan Towers" Mangalwar Peth, Near Mirajkar Tikti, Opp. Nutan Marathi
High School, Kolhapur. Mob. 9158529408, 9422047480, 9921285167

PT.NAME : MRS. RUPALI KAMBLE
REF. BY : DR. MEDIWHEEL LIFE INS

DATE : 11/01/2023
AGE : 32 Yrs. SEX : F
PT.NO. : 204 110123

BIOCHEMISTRY TEST REPORT

			<u>Normal Range</u>
S. Bilirubin (Total)	: 0.28	mg/dl	0 - 1.0 mg/dl
S. Bilirubin (Direct)	: 0.14	mg/dl	0 - 0.25 mg/dl
S. Bilirubin (Indirect)	: 0.14	mg/dl	0 - 0.75 mg/dl
S.G.O.T	: 29.6	IU/L	0 - 42 IU/L
S.G.P.T	: 13.0	IU/L	0 - 42 IU/L
S. Alkaline Phosphatase	: 93.7	IU/L	37 - 147 IU/L
Total Proteins	: 7.8	g/dl	6.6 - 8.3 g/dl
S. Albumin	: 4.9	g/dl	3.5 - 5.0 g/dl
S. Globulin	: 2.9	g/dl	1.5 - 3 g/dl
A/G Ratio	: 1.7 : 1		0.90 - 2.00



Dr. Vandana G. Powar
M.B.B.S., D.C.P.
Reg. No. 68137
PATHOLOGIST

DR. VANDANA POWAR
M.B.B.S., D.C.P.

All Biochemistry Tests Done By Computerised Auto Analyser

HAEMATOLOGY | CLINICAL PATHOLOGY | BIOCHEMISTRY | SEROLOGY | MICROBIOLOGY | HISTOPATHOLOGY

24 Hours Emergency Service

Home Service Available

Dr. Vandana G. Powar M.B.B.S., D.C.P.
Consultant Pathologist



PARTH
PATHOLOGY LABORATORY
(Computerised)

LAB - Shop No. 7, "Diwan Towers" Mangalwar Peth, Near Mirajkar Tikti, Opp. Nutan Marathi High School, Kolhapur. Mob. 9158529408, 9422047480, 9921285167

PT.NAME : MRS. RUPALI KAMBLE
REF. BY : DR. MEDIWHEEL LIFE INS

DATE : 11/01/2023
AGE : 32 Yrs. SEX : F
PT.NO. : 204 110123

REPORT ON % GLYCOHAEMOGLOBIN OF BLOOD

% Glycohaemoglobin of blood : 4.1 %

Estimated mean blood glucose : 71.2 mg/dl

(Reference For Guideline)

- < 6.0 - Normal
- 6.0 - 7.0 % - Good Control
- 7.0 - 8.0 % - Fair Control
- 8.0-10.0% - Unsatisfactory control
- >10.0% - Poor control



Dr. Vandana G. Powar
M.B.B.S., D.C.P.
Reg. No. 68137

PATHOLOGIST

[Signature]
DR. VANDANA POWAR
M.B.B.S., D.C.P.

All Biochemistry Tests Done By Computerised Auto Analyser

HAEMATOLOGY | CLINICAL PATHOLOGY | BIOCHEMISTRY | SEROLOGY | MICROBIOLOGY | HISTOPATHOLOGY

24 Hours Emergency Service

Home Service Available

Dr. Vandana G. Powar M.B.B.S., D.C.P.
Consultant Pathologist



PARTH
PATHOLOGY LABORATORY
(Computerised)

Shop No. 7, "Diwan Towers" Mangalwar Peth, Near Mirajkar Tikti, Opp. Nutan Marathi
High School, Kolhapur. Mob. 9158529408, 9422047480, 9921285167

PT.NAME : MRS. RUPALI KAMBLE
REF. BY : DR. MEDIWHEEL LIFE INS

DATE : 11/01/2023
AGE : 32 Yrs. SEX : F
PT.NO. : 204 110123

EXAMINATION OF URINE

Normal Range

PHYSICAL EXAMINATION

Quantity : 05 ml
Colour : Pale Yellow
Appearance : Clear
Deposit : Absent
Reaction (pH) : Acidic
Specific Gravity : 1.024

CHEMICAL EXAMINATION

Proteins : Absent
Glucose : Absent
Ketone Bodies : --
Bile Salts : Absent Absent
Bile Pigments : Absent Absent
Urobilinogen : --
Occult Blood : Absent

MICROSCOPIC EXAMINATION

Epithelial Cells : 1 - 2 /hpf
Pus Cells : 2 - 3 /hpf
Red Blood Cells : Absent /hpf
Casts : Absent
Crystals : Absent
Amorphous Deposits : Absent

OTHER FINDINGS

Yeast Cells : Absent
Trichomonas vaginalis : Absent
Bacteria : Absent
Mucus Threads : Absent
Spermatozoa : Absent

Dr. Vandana G. Powar
M.B.B.S., D.C.P.
Reg. No. 68137



PATHOLOGIST

[Signature]
DR. VANDANA POWAR
M.B.B.S., D.C.P.

All Biochemistry Tests Done By Computerised Auto Analyser

HAEMATOLOGY | CLINICAL PATHOLOGY | BIOCHEMISTRY | SEROLOGY | MICROBIOLOGY | HISTOPATHOLOGY

24 Hours Emergency Service

Home Service Available

Dr. Vandana G. Powar M.B.B.S., D.C.P.
Consultant Pathologist



PARTH
PATHOLOGY LABORATORY
(Computerised)

AB - Shop No. 7, "Diwan Towers" Mangalwar Peth, Near Mirajkar Tikli, Opp. Nutan Marathi
High School, Kolhapur. Mob. 9158529408, 9422047480, 9921285167

PATIENT NAME: - RUPALI KAMBLE

DATE: -11/01/2023

REF.BY:- MEDIWHEEL LIFE INS.

AGE/SEX:-32Y/FEMALE

BIOCHEMISTRY

SERUM VLDL : 19.3 mmol/L

NORMAL VALUE

10-50g/dl

Dr. Vandana G. Powar
M.B.B.S., D.C.P.

Reg. No. 68137

PATHOLOGIST


DR. VANDANA POWAR
M.B.B.S., D.C.P.



All Biochemistry Tests Done By Computerised Auto Analyser

HAEMATOLOGY | CLINICAL PATHOLOGY | BIOCHEMISTRY | SEROLOGY | MICROBIOLOGY | HISTOPATHOLOGY

24 Hours Emergency Service

Home Service Available

Dr. Vandana G. Powar M.B.B.S., D.C.P.
Consultant Pathologist



PARTH
PATHOLOGY LABORATORY
(Computerised)

Shop No. 7, "Diwan Towers" Mangalwar Peth, Near Mirajkar Tikti, Opp. Nutan Marathi
High School, Kolhapur. Mob. 9158529408, 9422047480, 9921285167

PATIENT NAME:- RUPALI KAMBLE

AGE - 32/SEX-FEMALE

REFERANCE = MEDIWHEEL LIFE INS

DATE - 11/01/2022

BIOCHEMISTRY

S. GAMMA.G.T : 18.6

NORMAL VALUE

10-50 mmol / L



Dr. Vandana G. Powar
M.B.B.S., D.C.P.
Reg. No. 68137
PATHOLOGIST

DR. VANDANA POWAR
M.B.B.S., D.C.P.

All Biochemistry Tests Done By Computerised Auto Analyser

HAEMATOLOGY | CLINICAL PATHOLOGY | BIOCHEMISTRY | SEROLOGY | MICROBIOLOGY | HISTOPATHOLOGY

24 Hours Emergency Service

Home Service Available

cc

11/01/2023

THE ECG OF CLIENT - RUPALI KAMBLE

IS WITHIN NORMAL LIMIT

NO ABNORMAL FINDINGS ARE DETECTED



Dr. Vandana G. Powar
MBBS, D.C.P.

Reg. No. 68137

PATHOLOGIST

DR. VANDANA POWAR
MBBS, D.C.P.

All Biochemistry Tests Done By Computerised Auto Analyser

HAEMATOLOGY | CLINICAL PATHOLOGY | BIOCHEMISTRY | SEROLOGY | MICROBIOLOGY | HISTOPATHOLOGY

24 Hours Emergency Service

Home Service Available

gest

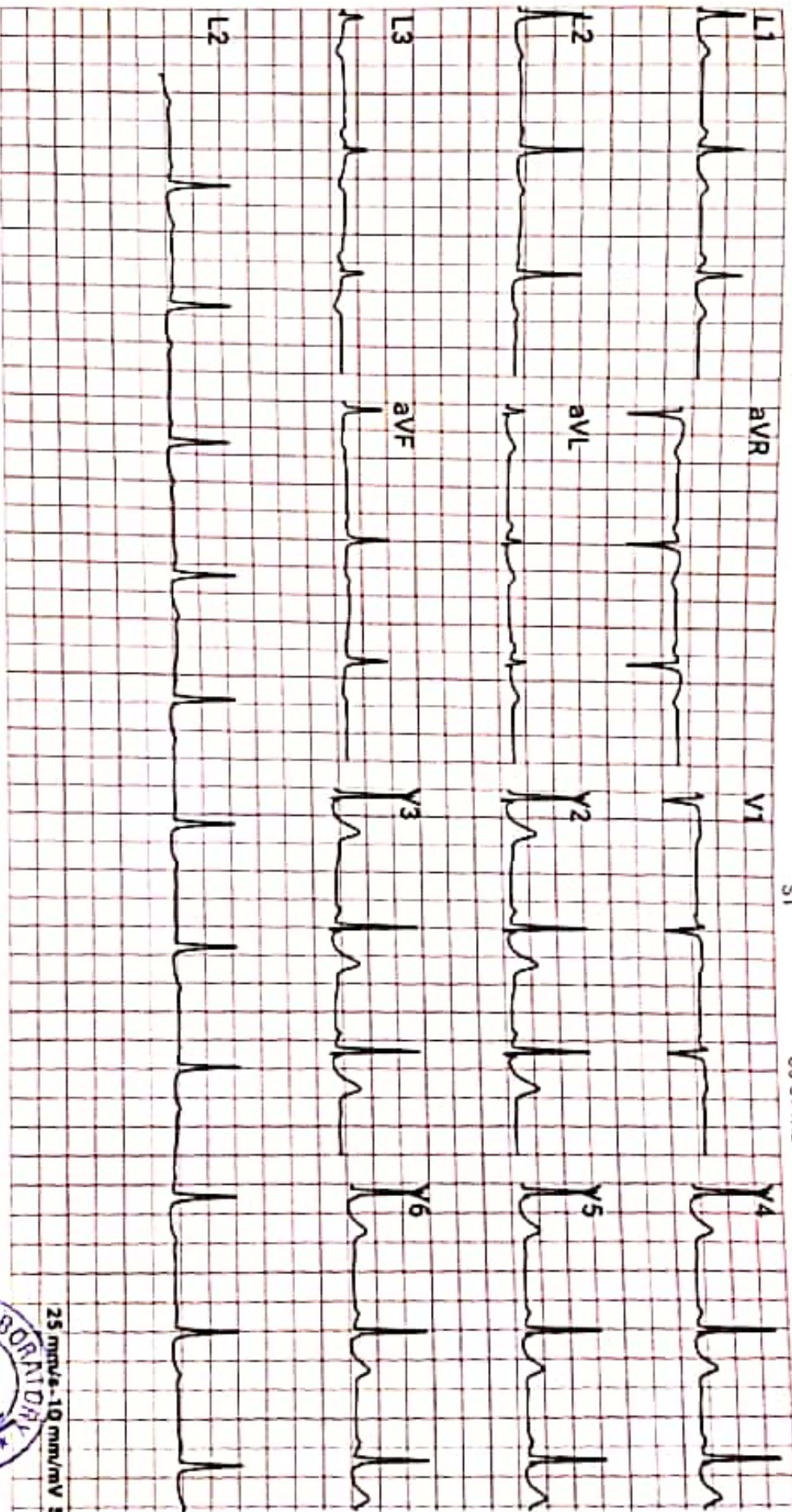
Name: Rypali Kamble

Gender / Age: 32 / female

Date & Time: 11 JAN, 2023 / 12:30AM

12 lead simultaneous EC

Heart Rate	68 bpm	QT	360.29 ms
QRS	151.71 ms	PR	142.0 ms
ST	80.67 ms	QTc	376.29 ms



Comments: Normal

Reported By



DR. VANKAR G. PAWAR
 M.B.B.S., D.C.P.

Reg. No. 68137

25 mm/s - 10 mm/mV

January 11, 2023

Dr. Vishram Mehta, M.D.

Name : Mrs. Rupali Amar Kamble.
Ref by : Dr. Vandana Powar. F / 32 yrs.

Ultrasonography of Abdomen and pelvis : [documented]

LIVER: is normal in size and normal texture The biliary radicles are normal.

GALL BLADDER: shows normal size, wall and lumen.

PORTA HEPATIS: The portal vein and the common ducts are normal in caliber.

PANCREAS: The size, echotexture and contour of pancreas are normal in caliber.

SPLEEN: shows normal in size with normal texture.

KIDNEYS: show normal position, contour & echotexture with no hydronephrosis.

There is a small 3 x 4 mm calculus in the interpolar calyx of the right kidney.

The right kidney measures 101 x 41 mm and the left measures 116 x 45 mm.

The ureters are not dilated.
The abdominal aorta, the I.V.C. and the pre and para aortic regions appear normal.

There is no ascites. No abnormal bowel could be seen.

There is 30 x 25 x 15 mm heterogeneously hyperechoic subcutaneous lesion in the right infra umbilical region, probably a lipoma.

URINARY BLADDER shows normal wall and lumen.

The uterus is anteverted and measures 49 x 49 x 40 mm. The shape, contour and textures are normal. The endometrial thickness is 3 mm.

Both ovaries are normal. There is no adnexal mass.
There is no fluid in the pouch of Douglas.

Impression : 1. Small right renal calyceal calculus.
2. Small right infra umbilical lipoma.

Vishram Mehta.

MAHALAXMI X-RAY AND SONOGRAPHY CLINIC
Eagle Pride, Below Shamrao Vitthal Bank, Mirajkar Tikiti, Kolhapur. Ph. : 2542012

Dr. Vishram Mehta, M.D.

January 11, 2023

Name

: Mrs. Rupali Amar Kamble.

F / 32 yrs.

Ref.by

: Dr. Vandana Powar.

X-Ray Chest, P.A. view :

The Pulmonary vascularity is prominent especially the upper lobe vessels.


The main pulmonary artery and the hilar vessels are prominent.

The cardio thoracic ratio is 53%.

The domes and the angles of diaphragm show no abnormality.

Impression : The mediastinal and pulmonary vascular morphology is suspicious for
? intra cardiac left to right shunt , ? mitral valve disease.

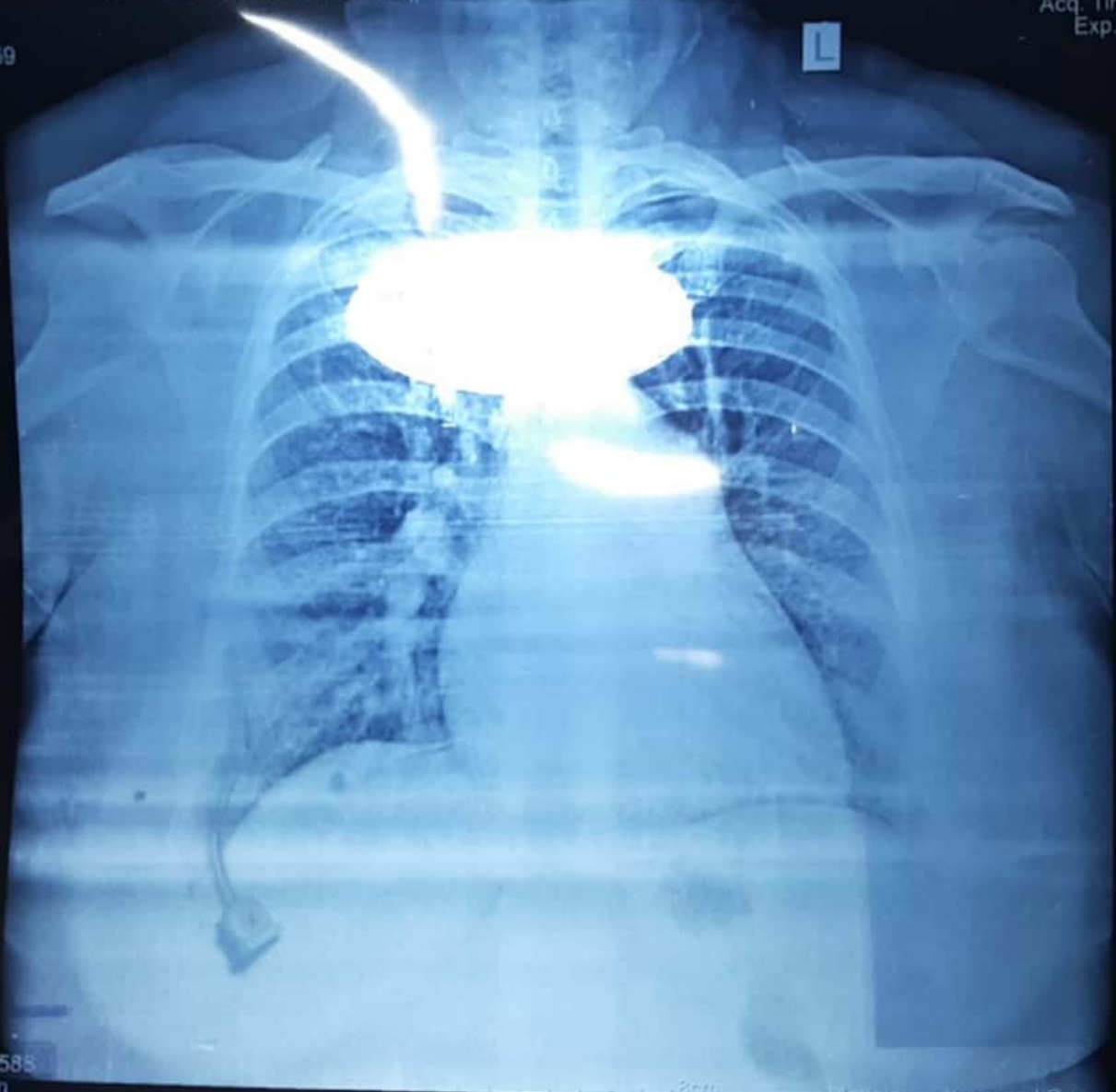
Clinical and cardiologic correlation is suggested.



Vishram Mehta

RUPALI A. KAMBLE — 32Y, DR. VANBANA POWAR,,
Sex: Female
DOB:
ID: PAT001469

Acq. Date: 11/01/2023
Acq. Time: 11:24:09
Exp. Index: 1582



CHEST
PA
W: 2880, L: 2585
Tech ID: admin

Scale: 0.54
MahaLaxmi X-ray and Sonography Clinic