

**Health Check up Booking Request(bobS28751), Beneficiary Code-40701**

1 message

Mediwheel &lt;wellness@mediwheel.in&gt;

9 February 2023 at 13:43

To: vidhidiagnostics@gmail.com

Cc: mediwheelwellness@gmail.com

**011-41195959**

Email:wellness@mediwheel.in

Dear **VIDHI DIAGNOSTICS**,**City** : Ahmedabad . **Address** : L-86 Swatantra - Senani Nagar , Opp- Akhbarnagar Bus Terminals, New Wadaj , Ahmedabad -13,

We have received the confirmation for the following booking .

**Name** : Anisha dabhi**Age** : 35**Gender** : Male**Package Name** : Medi-Wheel Metro Full Body Health Checkup Female Below 40**User Location** : ,AHMEDABAD,Gujarat,380001**Contact Details** : 8849846200**Booking Date** : 09-02-2023**Appointment Date** : 25-02-2023

Member Information			
Booked Member Name	Age	Gender	Cost(In INR)
Anisha dabhi	34	Female	Cashless
Total amount to be paid			Cashless

We will get back to you with confirmation update shortly. Please find the package details as attached for your reference.

**Package Name** : Medi-Wheel Metro Full Body Health Checkup Female Below 40 - Includes (37 )Tests**Tests included in this Package** : Ecg, TSH, X-ray Chest, Stress Test (tmt)/ 2d Echo, Blood Sugar Postprandial, A:g Ratio, Blood Group, Total Cholesterol, Triglycerides, Fasting Blood Sugar, Ultrasound Whole Abdomen , Glycosylated Haemoglobin (hba1c), Hdl, Vldl, Urine Analysis, LDL, Total Protine, General Consultation, HDL/ LDL ratio, GGT(Gamma-glutamyl Transferase), Eye Check-up consultation, ALP (ALKALINE PHOSPHATASE), Uric Acid, AST/ALT Ratio, Serum Protein, CBC with ESR, Stool Analysis, Urine Sugar Fasting, Urine Sugar PP, T3, T4, Cholesterol Total / HDL Ratio, BUN, BUN/Creatinine Ratio, Bilirubin Total & Direct and Indirect, Albumin, Globulin



## Medical Examination Report

Date : 25/02/2023

### 1. Personal Particulars

Name : Anisha Mahendrakumar Babhi

Age : 34 years Gender : Male / Female

Marital Status : MARRIED

Past & Present Medical History :

} Normal

### 2. Clinical Medical Examination

Height : 153 cm Weight : 50 kg  
Blood Pressure : 128/80 mmHg Pulse : 90 p/min

General Condition : (N) Skin : (N)  
Central Nervous System : (N) Head & Neck : (N)  
Cardiovascular System : (N) Chest : (N)  
Abdomen : (N) Limbs : (N)  
Last menstrual period : +

Vision: : Right: 6/6 with specs N/B Left: 6/6 with specs N/B

Colour vision : Normal/Colour Blind

Personal Habit : NO

Remarks : Fit / Unfit for employment

Dr. Vidhi D. Meeth  
MBBS

Reg. No. 874540

Dr's name, signature & chop

**Vidhi Diagnostics**  
L-86, Swatantra-Senani Nagar,  
Opp. Akhbarnagar Bus Terminals,  
Nr. Akhbarnagar Circle,  
New Wadaj, Ahmedabad-13.



HR : 90 bpm  
 PR : 102 ms  
 QRS : 126 ms  
 QT/QTc : 378/462 ms  
 P/QRS/T : 61/87/11 deg.  
 RV5/SV1 : 1.126/-0.285 mv  
 RV5+SV1 : 1.411 mv

\*\* abnormal ECG \*\*  
 Sinus rhythm  
 Short PR interval

# Vidhi Diagnostics

L-86, Swatantra-Senani Nagar,  
 Opp. Akhbarnagar Bus Terminals,  
 Nr. Akhbarnagar Circle,  
 New Wadaj, Ahmedabad-13.

ID: 8115

Name: anisha mahendrakumar dabhi

Age: 37ys

Sex: Female

Hospital:

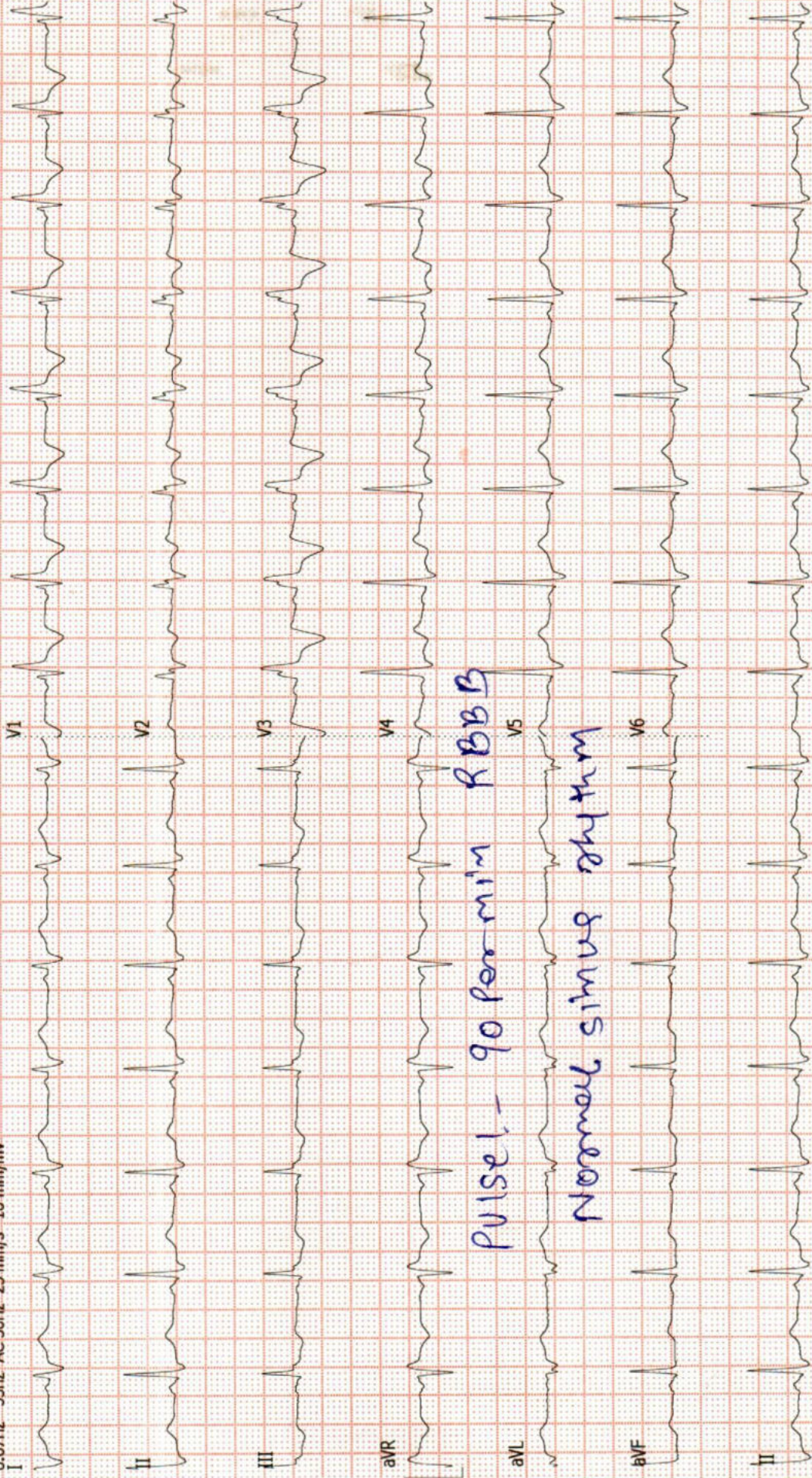
**Dr. Avinash Bhargava**  
 MBBS, MD, DNB  
 Reg. No.: G-45946

Department:

Reg. No.:

Need to be confirmed by doctor. Doctor Name:

0.67Hz - 35Hz AC 50Hz 25 mm/s 10 mm/mv





## Dr. Dinesh S. Modh

M.D., D.M.R.E. (Radiodiagnosis)

Consultant Radiologist & Sonologist

Ex. Junior Lecturer, B.J. Medical College, Civil Hospital, A'bad.



Patient's name : ANISHA MAHENDRAKUMAR DABHI  
Reg. ID : R-13586-23  
Referred by : Dr. MEDIWHEEL

Age/Sex : 34 Years/Male  
Accession : 447  
Date : 25/02/2023

### X-RAY CHEST (PA VIEW)

Both lung fields appear normal.  
No e/o consolidation or cavitations is seen.  
Both costo-phrenic angles appear clear.  
Cardiac size is within normal limits.  
Both domes of diaphragm appear normal.  
Bony thoracic cage appears normal.

Thanks for reference.

Dr. Dinesh S. Modh

MD DMRE (Radiodiagnosis)

DR DINESH S. MODH

M.D. DMRE (RADIO DIAGNOSIS)

ISO 9001:2015 Certified Diagnostics Center

Vidhi Imaging Center

L-86, Swatantra Senani Nagar, Opp. Indian Oil Petrol Pump, Akhbarnagar Circle, Nava Vadaj, Ahmedabad - 380 013.

Phone : (Radiology) 079-2762 1406 | M. 98799 29406, 98250 09406 | Time (Radiology) : Mon. to Sat. 9 am to 2 pm, 5 to 9 pm, Sunday 9 am to 12 Noon

E-mail : vidhidiagnostics@gmail.com, Website : www.vidhidiagnostics.com

Multislice CT Scan | CBCT-Dental Scan | Live 3D-4D Sonography | Colour Doppler | Echo Cardiography | Interventional Radiology | Maxillofacial Radiology | Fetal Medicine  
Digital X-Ray | Digital Mammography | Digital OPG/TMJ | ECG/TMT/PFT/EEG/EMG | Audiometry | Pathology Laboratory | Health Check Up Plans | Pre Employment Check Up

**CT SCAN & CBCT FACILITY NOW AVAILABLE**

## Dr. Dinesh S. Modh

M.D., D.M.R.E. (Radiodiagnosis)

Consultant Radiologist & Sonologist

Ex. Junior Lecturer, B.J. Medical College, Civil Hospital, A'bad.

**VIDHI**  
DIAGNOSTICS



Patient's name : ANISHA MAHENDRAKUMAR DABHI  
Reg. ID : R-13586-23  
Referred by : Dr. MEDIWHEEL

Age/Sex : 34 Years/Male  
Accession : 447  
Date : 25/02/2023

### 2D- ECHO REPORT

#### FINAL CONCLUSION:

LV IS NORMAL SIZE. GOOD LV SYSTOLIC FUNCTION NO RWMA.  
LVEF - 60%. NO CONCENTRIC LVH.  
NORMAL LV COMPLIANCE.  
LA IS NORMAL SIZE. NO LA CLOT.  
RV IS NORMAL SIZE. GOOD RV SYSTOLIC FUNCTION.  
RA IS NORMAL SIZE.  
MITRAL VALVE IS NORMAL. NO MS. MILD MR (15%). NO MVP.  
AORTIC VALVE IS NORMAL. NO AS. NO AR.  
TRICUSPID VALVE IS NORMAL. NO TR. RVSP-26 mmHg. NO PAH.

NO CLOT, NO VEGETATION, NO PERICARDIAL EFFUSION.

#### DIMENSIONS:

AORTA	2.6 C.M
LEFT ATRIUM	2.7 C.M
LVDD	4.1 C.M.
IVSD	1.0 C.M
PWD	1.0 C.M
LVDS	2.6 C.M.

#### COLOUR DOPPLER FINDING:

STRUCTURE	VELOCITY m/sec
	Max
PULMONARY VALVE	0.7
MITRAL VALVE	E : 0.7 A: 0.4
AORTIC VALVE	1.0

*Dr. Avinash Bhaskar*  
MBBS. D Cardio  
**DR AVINASH BHASKAR**

ISO 9001:2015 Certified Diagnostics Center

Vidhi Imaging Center

L-86, Swatantra Senani Nagar, Opp. Indian Oil Petrol Pump, Akharnagar Circle, Nava Vadaj, Ahmedabad - 380 013.

Phone : (Radiology) 079-2762 1406 | M. 98799 29406, 98250 09406 | Time (Radiology) : Mon. to Sat. 9 am to 2 pm, 5 to 9 pm, Sunday 9 am to 12 Noon

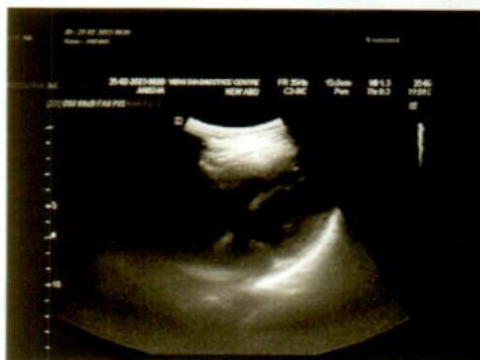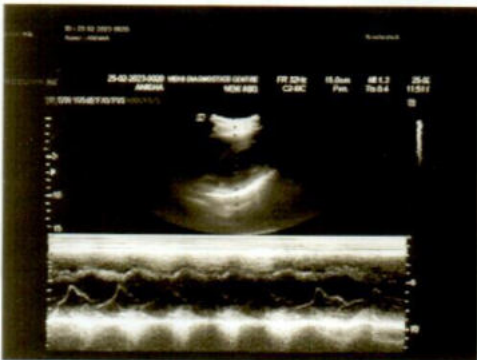
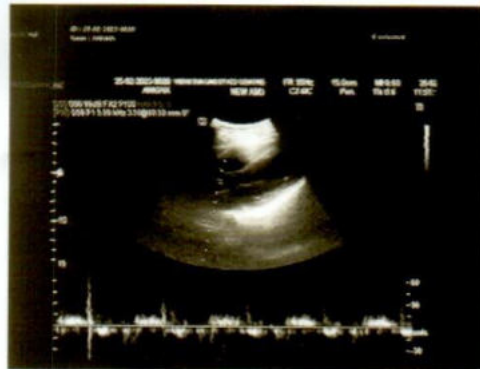
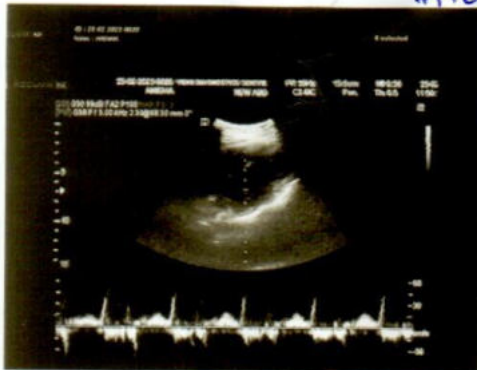
E-mail : vidhidiagnostics@gmail.com, Website : www.vidhidiagnostics.com

Multislice CT Scan | CBCT-Dental Scan | Live 3D-4D Sonography | Colour Doppler | Echo Cardiography | Interventional Radiology | Maxillofacial Radiology | Fetal Medicine  
Digital X-Ray | Digital Mammography | Digital OPG/TMJ | ECG/TMT/PFT/EEG/EMG | Audiometry | Pathology Laboratory | Health Check Up Plans | Pre Employment Check Up

**CT SCAN & CBCT FACILITY NOW AVAILABLE**



Anishel



## Dr. Dinesh S. Modh

M.D., D.M.R.E. (Radiodiagnosis)

Consultant Radiologist & Sonologist

Ex. Junior Lecturer, B.J. Medical College, Civil Hospital, A'bad.



Patient's name : ANISHA MAHENDRAKUMAR DABHI	Age/Sex : 34 Years/Male
Reg. ID : R-13586-23	Accession : 447
Referred by : Dr. MEDIWHEEL	Date : 25/02/2023

### USG ABDOMEN

**LIVER:-** Liver shows normal in size & normal echotexture. No e/o diffuse or focal lesion is seen. IHBR appear normal. PV & CBD appears normal. No e/o calculus is seen in bile duct.

**GALL BLADDER:-** Gall bladder is distended & shows small non-mobile nodule measures 3mm in posterior wall suggests p/o GB polyp likely. No evidence of pericholecystic fluid is seen.

**SPLEEN:-** Spleen appears normal in size & shows normal echotexture. No evidence of diffuse or focal lesion is seen.

**PANCREAS:-** Pancreas appears normal size and echo pattern. No e/o diffuse or focal lesion is seen. Main pancreatic duct appears normal.

**KIDNEY:-** Both Kidneys appear normal in size & echotexture.

No e/o calculus or hydronephrosis or hydroureter is seen in both sides.

Cortico-medullary differentiation is maintained on either side.

Both suprarenal regions appear normal.

**RIF & BOWEL (by high frequency probe-10Mhz): -Normal.**

No evidence of pre & para aortic lymphadenopathy is seen.

No evidence of free fluid is seen in abdomen.

No evidence of dilated or thickened bowel loops is seen.

**Urinary bladder: -** appear normal. No e/o calculus or mass lesion is seen in bladder.

Uterus appears normal size and echopattern.

Both adenexal regions appear normal.

No e/o free fluid is seen in pouch of Douglas.

Thanks for reference.

Dr. Dinesh S. Modh  
MD DMRE (Radiodiagnosis)

DR DINESH S. MODH

M.D. DMRE(RADIODIAGNOSIS)

ISO 9001:2015 Certified Diagnostics Center

Vidhi Imaging Center

L-86, Swatantra Senani Nagar, Opp. Indian Oil Petrol Pump, Akharnagar Circle, Nava Vadaj, Ahmedabad - 380 013.

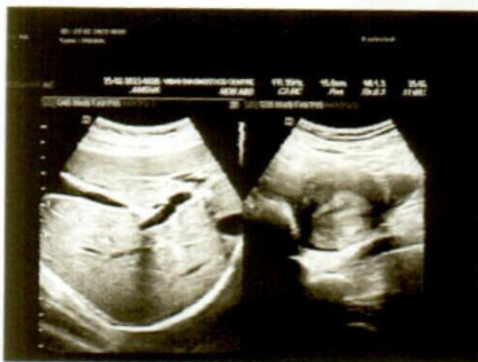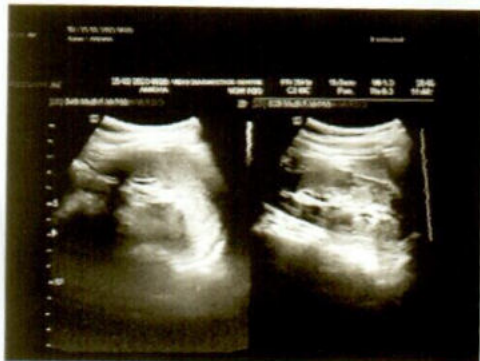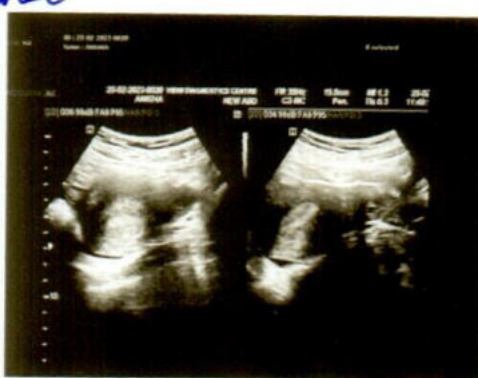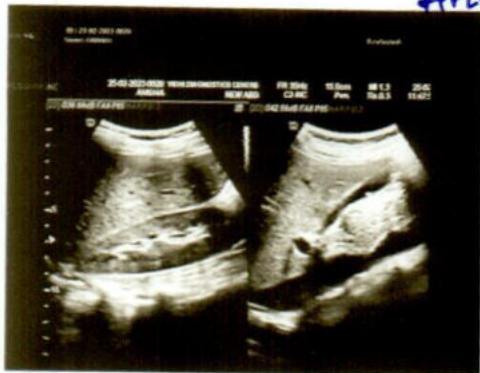Phone : (Radiology) 079-2762 1406 | M. 98799 29406, 98250 09406 | Time (Radiology) : Mon. to Sat. 9 am to 2 pm, 5 to 9 pm, Sunday 9 am to 12 Noon

E-mail : vidhidiagnostics@gmail.com, Website : www.vidhidiagnostics.com

Multislice CT Scan | CBCT-Dental Scan | Live 3D-4D Sonography | Colour Doppler | Echo Cardiography | Interventional Radiology | Maxillofacial Radiology | Fetal Medicine  
Digital X-Ray | Digital Mammography | Digital OPG/TMJ | ECG/TMT/PFT/EEG/EMG | Audiometry | Pathology Laboratory | Health Check Up Plans | Pre Employment Check Up

**CT SCAN & CBCT FACILITY NOW AVAILABLE**

*Anishel*





## Dr. Dinesh S. Modh

M.D., D.M.R.E. (Radiodiagnosis)

Consultant Radiologist & Sonologist

Ex. Junior Lecturer, B.J. Medical College, Civil Hospital, A'bad.

Panel Doctor of L.I.C.



Steel Report not Required

A.M. Desai

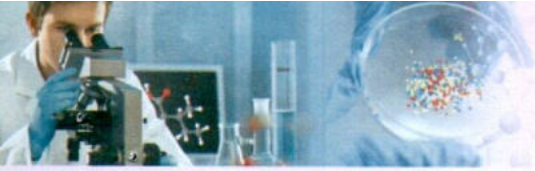ISO 9001:2015 Certified Diagnostics Center

Vidhi Imaging Center, L-86, Swatantra Senani Nagar, Opp. Akhbarnagar Petrol Pump, Nr. Akhbarnagar Circle, Nava-Vadaj, Ahmedabad - 380 013.

Phone : 079-2762 1406, Mobile : 98799 29406, 98250 09406, E-mail : vidhidiagnostics@gmail.com, Website : www.vidhidiagnostics.com

FACILITIES : Live 3D-4D Sonography | Colour Doppler | Echo Cardiography | Interventional Radiology | Fetal Medicine | Digital X-Ray  
Digital Mammography | Digital OPG / TMJ | ECG / TMT / PFT / EEG / EMG | Pathology Laboratory | Health Check Up Plans | Pre Employment Check Up





Pathology Department



Patient's name : ANISHA MAHENDRAKUMAR DABHI  
 Age/Sex : 34 Years/Female  
 Referred by : Dr. MEDIWHEEL  
 Collection Time : 09:11

Reg. ID : P-7584-23  
 Accession : 443  
 Order Dt/time : 25/02/2023 09:11

**Complete Blood Count**

Sample Type: EDTA

Test Name	Result	Units	Biological Reference Interval
<b><u>Blood Counts</u></b>			
Haemoglobin :	<b>10.3</b>	Gms%	12.5 - 16.0
Total R.B.C. :	<b>3.54</b>	mill/c.mm	4.2 - 5.4
Total W. B. C. :	5,450	/cu mm	4000 - 10500
Platelet Count :	1,88,000	/cu.mm	1,50,000 - 4,50,000
<b><u>Differential Count</u></b>			
Neutrophils :	55	%	40 - 70
Lymphocytes :	40	%	20 - 40
Eosinophils :	03	%	1 - 4
Monocytes :	02	%	2 - 6
Basophils :	00	%	0 - 01
<b><u>Blood Indices</u></b>			
P. C. V :	<b>31.1</b>	%	37 - 47
M. C. V. :	87.9	fl	78 - 100
M.C.H :	29.1	pg	27 - 31
M. C. H. C :	33.1	%	32 - 36
R.D.W :	13.9	%	11.5 - 14.0
<b><u>E.S.R.( Westergren Method )</u></b>			
After one hour :	12	mm/hr	3 - 12

TESTS DONE ON FULLY AUTOMATED HEMATOLOGY ANALYZER.

*Dr. Gayatri M. Mehta*

M. D. (Patho)

Reg. No. G-32215

DR GAYATRI MEHTA  
 MD(PATHOLOGY)

DR. ANAND D. PARIKH  
 MD(PATHOLOGY)

LAB USE ONLY (Entered by :GM Enter Date/Time:25/02/2023 1:23:00 PM) (Verify by :GM Verify Date/Time:25/02/2023 1:23:00 PM)

ISO 9001:2015 Certified Diagnostics Center  
 Vidhi Imaging Center | Pathology Department

L-86, Swatantra Senani Nagar, Opp. Akhbarnagar Petrol Pump, Nr. Akhbarnagar Circle, Nava-Vadaj, Ahmedabad - 380 013.

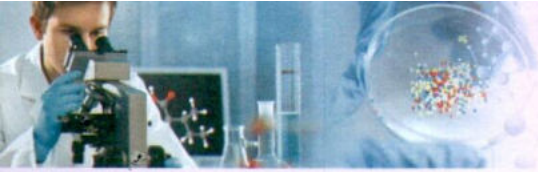Ph. (Pathology) : 079-2762 1406, 8849893954 M. 98799 29406, 98250 09406, E-mail : vidhidiagnostics@gmail.com, Web. : www.vidhidiagnostics.com

Time (Pathology) : Mon. to Sat. 8.30 am to 8.00 pm, Sunday 9 am to 12 Noon

*Pathology means science behind medicine*

**CT SCAN & CBCT FACILITY NOW AVAILABLE**





Pathology Department

**VIDHI**<sup>®</sup>  
**DIAGNOSTICS**



Patient's name : ANISHA MAHENDRAKUMAR DABHI  
Age/Sex : 34 Years/Female  
Referred by : Dr. MEDIWHEEL  
Collection Time : 09:11

Reg. ID : P-7584-23  
Accession : 443  
Order Dt/time : 25/02/2023 09:11

### Blood Group

Sample Type: EDTA sample.

Test Name	Result
BG :	" A "
RH :	POSITIVE
Remarks	Done by forward grouping method.

### Blood Glucose

Sample Type: Serum

Test Name	Result	Units	Biological Reference Interval
Fasting Blood Glucose : <i>GOD-POD Method.</i>	93.4	mg/dl	70 - 110

*Dr. Gayatri M. Mehta*  
M. D. (Patho)

*Reg. No. G-32215*

DR GAYATRI MEHTA  
MD(PATHOLOGY)

DR. ANAND D. PARIKH  
MD(PATHOLOGY)

LAB USE ONLY (Entered by :GM Enter Date/Time:25/02/2023 4:23:00 PM) (Verify by :GM Verify Date/Time:25/02/2023 4:23:00 PM)

ISO 9001:2015 Certified Diagnostics Center

Vidhi Imaging Center | Pathology Department

L-86, Swatantra Senani Nagar, Opp. Akhbarnagar Petrol Pump, Nr. Akhbarnagar Circle, Nava-Vadaj, Ahmedabad - 380 013.

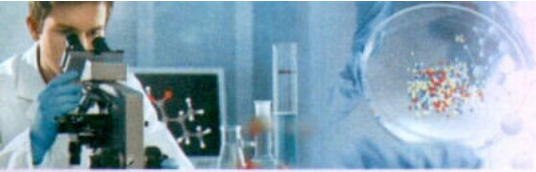Ph. (Pathology) : 079-2762 1406, 8849893954 M. 98799 29406, 98250 09406, E-mail : vidhidiagnostics@gmail.com, Web. : www.vidhidiagnostics.com

Time (Pathology) : Mon. to Sat. 8.30 am to 8.00 pm, Sunday 9 am to 12 Noon

*Pathology means science behind medicine*

**CT SCAN & CBCT FACILITY NOW AVAILABLE**





Patient's name : ANISHA MAHENDRAKUMAR DABHI  
 Age/Sex : 34 Years/Female  
 Referred by : Dr. MEDIWHEEL  
 Collection Time : 09:11

Reg. ID : P-7584-23  
 Accession : 443  
 Order Dt/time : 25/02/2023 09:11

**Lipid Profile**

Sample Type: Serum

Test Name	Result	Units	Biological Reference Interval
<b>S. Cholesterol :</b> Oxidase-esterase method.	189.0	mg/dl	0 - 200
<b>S. Triglyceride :</b> Enzymatic Colorimetry method	75.7	mg/dL	0 - 200
<b>S. HDL - Cholesterol :</b> Serum by Enzymatic method.	<b>80.8</b>	mg/dL	35 - 65
<b>S. LDL - Cholesterol :</b> Serum by Enzymatic method	93.06	mg/dL	0 - 130
<b>S. VLDL - Cholesterol :</b>	15.14	mg/dL	0 - 30
<b>S. Chole/HDL.Ratio :</b>	2.34		1 - 6
<b>S. LDL / HDL Cholesterol Ratio :</b>	1.15		0 - 3.5

*Dr. Gayatri M. Mehta*

M. D. (Patho)

Reg. No. G-32215

DR GAYATRI MEHTA  
MD(PATHOLOGY)

DR. ANAND D. PARIKH  
MD(PATHOLOGY)

LAB USE ONLY (Entered by :GM Enter Date/Time:25/02/2023 4:24:00 PM) (Verify by :GM Verify Date/Time:25/02/2023 4:24:00 PM)

ISO 9001:2015 Certified Diagnostics Center  
Vidhi Imaging Center | Pathology Department

L-86, Swatantra Senani Nagar, Opp. Akhbarnagar Petrol Pump, Nr. Akhbarnagar Circle, Nava-Vadaj, Ahmedabad - 380 013.

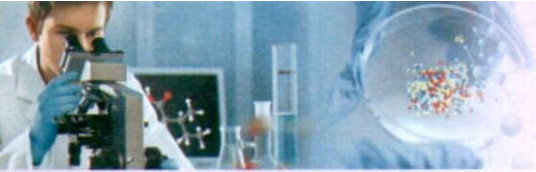Ph. (Pathology) : 079-2762 1406, 8849893954 M. 98799 29406, 98250 09406, E-mail : vidhidiagnostics@gmail.com, Web. : www.vidhidiagnostics.com

Time (Pathology) : Mon. to Sat. 8.30 am to 8.00 pm, Sunday 9 am to 12 Noon

*Pathology means science behind medicine*

**CT SCAN & CBCT FACILITY NOW AVAILABLE**





Pathology Department

**VIDHI**  
**DIAGNOSTICS**



Patient's name : ANISHA MAHENDRAKUMAR DABHI  
Age/Sex : 34 Years/Female  
Referred by : Dr. MEDIWHEEL  
Collection Time : 09:11

Reg. ID : P-7584-23  
Accession : 443  
Order Dt/time : 25/02/2023 09:11

**HbA1C**

Sample Type: Serum

Test Name	Result	Units	Biological Reference Interval
HbA1C :	5.0	%	Non-diabetic: 4.2-6.2 Pre-diabetic : 6.3-7.2 Diabetic : 7.3-8.2
Mean Blood Glucose of Last 03 months.	96.8	mg/dl	

**Comment**

\*As per the new 2009 update of American Diabetes Association regarding HbA1C & Mean Blood Glucose relationship.

**NOTE:**

This test is used to monitor diabetic patients compliance with the therapeutic regimen and logo It's level is proportional to both the average blood glucose concentration and the life span of the red blood cells (RBC) in circulation. HbA1c values are free of day to day glucose fluctuations and are unaffected by exercise or recent food intake.

*Dr. Gayatri M. Mehta*

M. D. (Patho)

DR GAYATRI MEHTA  
MD(PATHOLOGY)

DR. ANAND D. PARIKH  
MD(PATHOLOGY)

LAB USE ONLY (Entered by :GM Enter Date/Time:25/02/2023 4:24:00 PM) (Verify by :GM Verify Date/Time:25/02/2023 4:24:00 PM)

ISO 9001:2015 Certified Diagnostics Center

Vidhi Imaging Center | Pathology Department

L-86, Swatantra Senani Nagar, Opp. Akhbarnagar Petrol Pump, Nr. Akhbarnagar Circle, Nava-Vadaj, Ahmedabad - 380 013.

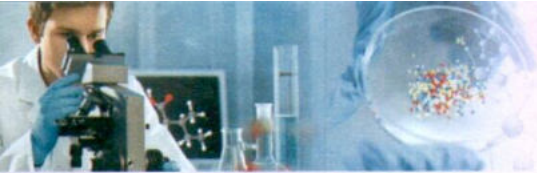Ph. (Pathology) : 079-2762 1406, 8849893954 M. 98799 29406, 98250 09406, E-mail : vidhidiagnostics@gmail.com, Web. : www.vidhidiagnostics.com

Time (Pathology) : Mon. to Sat. 8.30 am to 8.00 pm, Sunday 9 am to 12 Noon

*Pathology means science behind medicine*

**CT SCAN & CBCT FACILITY NOW AVAILABLE**





Patient's name : ANISHA MAHENDRAKUMAR DABHI  
Age/Sex : 34 Years/Female  
Referred by : Dr. MEDIWHEEL  
Collection Time : 09:11

Reg. ID : P-7584-23  
Accession : 443  
Order Dt/time : 25/02/2023 09:11

**BIOCHEMISTRY**

Sample type :Serum

Test Name	Result	Units	Biological Reference Interval
<b>Urea</b> , (Serum by GLDH method) :	15.4	mg/dl	10 - 50
<b>S.Uric acid</b> , (Serum by Uricase method) :	3.6	mg/dl	2.6-6.0
<b>Bun</b> :	7.2	mg/dl	6-20
<b>Creatinine</b> , (Serum by Enzymatic reaction) :	0.56	mg/dl	0.5-1.2
<b>S.G.P.T (ALT)</b> : (Serum by IFCC method )	18.6	U/L	0 - 40
<b>S.G.O.T (AST)</b> : (Serum by IFCC method )	19.2	U/L	0 - 37
<b>ALK.PHOSPHATASE</b> : (Serum by PNP method )	48.0	U/L	35-104
<b>G.G.T</b> :	13.2	U/L	8 - 78
<b><u>BILIRUBIN</u></b>			
<b>Total</b> :	0.92	mg/dl	Up to 1.2
<b>Direct</b> :	0.53	mg/dl	0-0.7
<b>Indirect</b> :	0.39	mg/dl	0 - 0.5
<b><u>SERUM PROTEINS</u></b>			
<b>Total Protein</b> (Serum by Biuret method) :	7.25	gms/dl	6.4 - 8.5
<b>Albumin</b> (Serum by BCG method) :	4.17	gms/dl	3.97-4.94
<b>Globulins</b> :	3.08	gms/dl	2.3 - 3.5
<b>A/G Ratio</b> :	1.354		0.9 - 2.9

*Dr. Gayatri M. Mehta*  
M. D. (Patho)  
Reg. No. G-32215  
DR GAYATRI MEHTA  
MD(PATHOLOGY)

DR.ANAND D.PARIKH  
MD(PATHOLOGY)

LAB USE ONLY (Entered by :GM Enter Date/Time:25/02/2023 4:23:00 PM) (Verify by :GM Verify Date/Time:25/02/2023 4:23:00 PM)

ISO 9001:2015 Certified Diagnostics Center  
Vidhi Imaging Center | Pathology Department

L-86, Swatantra Senani Nagar, Opp. Akhbarnagar Petrol Pump, Nr. Akhbarnagar Circle, Nava-Vadaj, Ahmedabad - 380 013.

Ph. (Pathology) : 079-2762 1406, 8849893954 M. 98799 29406, 98250 09406, E-mail : vidhidiagnostics@gmail.com, Web. : www.vidhidiagnostics.com

Time (Pathology) : Mon. to Sat. 8.30 am to 8.00 pm, Sunday 9 am to 12 Noon

*Pathology means science behind medicine*

**CT SCAN & CBCT FACILITY NOW AVAILABLE**





Pathology Department



Patient's name : ANISHA MAHENDRAKUMAR DABHI  
Age/Sex : 34 Years/Female  
Referred by : Dr. MEDIWHEEL  
Collection Time : 09:11

Reg. ID : P-7584-23  
Accession : 443  
Order Dt/time : 25/02/2023 09:11

### Thyroid Function Test

Sample Type: Serum

Test Name	Result	Units	Biological Reference Interval
TOTAL T3 :	1.36	ng/ml	0.84 - 2.0
TOTAL T4 :	7.15	ug/dl	5.1 - 14.0
TSH(Ultra sensitive) :	2.541	mIU/L	0.27 - 4.2

*Dr. Gayatri M. Mehta*  
M. D. (Patho)  
REG. No. G-32215  
DR. GAYATRI MEHTA  
MD(PATHOLOGY)

DR. ANAND D. PARIKH  
MD(PATHOLOGY)

LAB USE ONLY (Entered by :GM Enter Date/Time:25/02/2023 4:24:00 PM) (Verify by :GM Verify Date/Time:25/02/2023 4:24:00 PM)

ISO 9001:2015 Certified Diagnostics Center

Vidhi Imaging Center | Pathology Department

L-86, Swatantra Senani Nagar, Opp. Akhbarnagar Petrol Pump, Nr. Akhbarnagar Circle, Nava-Vadaj, Ahmedabad - 380 013.

Ph. (Pathology) : 079-2762 1406, 8849893954 M. 98799 29406, 98250 09406, E-mail : vidhidiagnostics@gmail.com, Web. : www.vidhidiagnostics.com

Time (Pathology) : Mon. to Sat. 8.30 am to 8.00 pm, Sunday 9 am to 12 Noon

*Pathology means science behind medicine*

**CT SCAN & CBCT FACILITY NOW AVAILABLE**





Pathology Department

**VIDHI**  
DIAGNOSTICS



Patient's name : ANISHA MAHENDRAKUMAR DABHI  
Age/Sex : 34 Years/Female  
Referred by : Dr. MEDIWHEEL  
Collection Time : 09:11

Reg. ID : P-7584-23  
Accession : 443  
Order Dt/time : 25/02/2023 09:11

**Urine Analysis**

Sample Type: Urine

Test Name	Result	Units	Biological Reference Interval
<b><u>Physical Examination</u></b>			
Quantity :	20	ml	0 - 500 ml
Colour :	Pale Yellow		Pale Yellow
Transparency :	Slight Turbid.		Clear
Reaction :	Acidic		4.6 - 8.0
Specific Gravity :	1.010		1.016 - 1.022
Sediment :	Present		
<b><u>Chemical Examination</u></b>			
Albumin :	Present (Faint Trace)		Absent
Sugar :	NIL		Absent
Acetone :	Absent		Absent
Bile Salts :	Absent		Absent
Bile Pigments :	Absent		Absent
Urobilogen :	Absent		Absent
Nitrites :	Absent		Absent
<b><u>Microscopic Examination</u></b>			
Red blood Cells :	1-2	/h.p.f	Absent
Pus Cells :	2-3	/h.p.f	Absent
Epithelial Cells :	1-2	/h.p.f	< 10.0
Amorphous :	Absent	/h.p.f	Absent
Bacteria :	Absent	/h.p.f	Absent
Crystals :	Absent	/h.p.f	Absent
Casts :	Absent	/h.p.f	Absent
Fungus :	Not seen	/h.p.f	Absent

*Dr. Gayatri M. Mehta*  
M. D. (Patho)

Reg. No. G-32215

DR GAYATRI MEHTA  
MD(PATHOLOGY)

DR. ANAND D. PARIKH  
MD(PATHOLOGY)

ISO 9001:2015 Certified Diagnostics Center

LAB USE ONLY (Entered by :GM Enter Date/Time: 25/02/2023 4:24:00 PM) (Verify by :GM Verify Date/Time: 25/02/2023 4:24:00 PM)

L-86, Swatantra Senani Nagar, Opp. Akhbarnagar Petrol Pump, Nr. Akhbarnagar Circle, Nava-Vadaj, Ahmedabad - 380 013.

Ph. (Pathology) : 079-2762 1406, 8849893954 M. 98799 29406, 98250 09406, E-mail : vidhidiagnostics@gmail.com, Web. : www.vidhidiagnostics.com

Time (Pathology) : Mon. to Sat. 8.30 am to 8.00 pm, Sunday 9 am to 12 Noon

*Pathology means science behind medicine*

**CT SCAN & CBCT FACILITY NOW AVAILABLE**





ભારતીય વિશિષ્ટ ઓળખાણ પ્રાધિકરણ

**ભારત સરકાર**  
Unique Identification Authority of India  
Government of India

નામાંકન ક્રમ સંખ્યા/ Enrolment No.: 2141/43475/96523

Download Date: 07/11/2017

Generation Date: 25/09/2017

To  
અનીશા મહેન્દ્રકુમાર ડાભી  
Anisha Mahendrakumar Dabhi  
W/O Mahendrakumar Dabhi  
B/14  
Sweta Duplex Row House  
Ranip  
Near Rupal Park, Radhaswami Road  
Ahmedabad City  
Ranip  
Ahmedabad Gujarat - 382480  
9974649392

Signature valid



તમારો આધાર નંબર / Your Aadhaar No. :

**6529 4159 5735**

મારો આધાર, મારી ઓળખ



ભારત સરકાર  
Government of India



અનીશા મહેન્દ્રકુમાર ડાભી  
Anisha Mahendrakumar Dabhi  
જન્મ તારીખ/DOB: 20/12/1988  
સ્ત્રી/ FEMALE

**6529 4159 5735**

મારો આધાર, મારી ઓળખ



સૂચના

- આધાર ઓળખાણનું પ્રમાણ છે, નાગરિકતાનું નહિ.
- ઓળખાણનું પ્રમાણ ઓનલાઇન ઓથેન્ટિકેશન દ્વારા પ્રાપ્ત કરો.
- આ ઇલેક્ટ્રોનિક પ્રક્રિયા દ્વારા બનાવેલા દસ્તાવેજ છે.

**INFORMATION**

- Aadhaar is a proof of identity, not of citizenship.
- To establish identity, authenticate online.
- This is electronically generated letter.

- આધાર દેશભરમાં માન્ય છે.
- આધાર ભવિષ્યમાં સરકારી અને બિન-સરકારી સેવાઓનો લાભ મેળવવામાં ઉપયોગી થશે.
- Aadhaar is valid throughout the country.
- Aadhaar will be helpful in availing Government and Non-Government services in future.



ભારતીય વિશિષ્ટ ઓળખાણ પ્રાધિકરણ  
Unique Identification Authority of India

**Address:**

W/O Mahendrakumar Dabhi,  
B/14, Sweta Duplex Row House,  
Near Rupal Park, Radhaswami  
Road, Ranip, Ahmedabad City,  
Ahmedabad,  
Gujarat - 382480

**સરનામું :**

W/O મહેન્દ્રકુમાર ડાભી, બી/14, શ્વેતા  
ડુપ્લેક્સ રો હાઉસ, રૂપલ પાર્ક પાસે,  
રાધાસ્વામી રોડ, રાણીપ, અમદાવાદ શહેર,  
અમદાવાદ,  
ગુજરાત - 382480

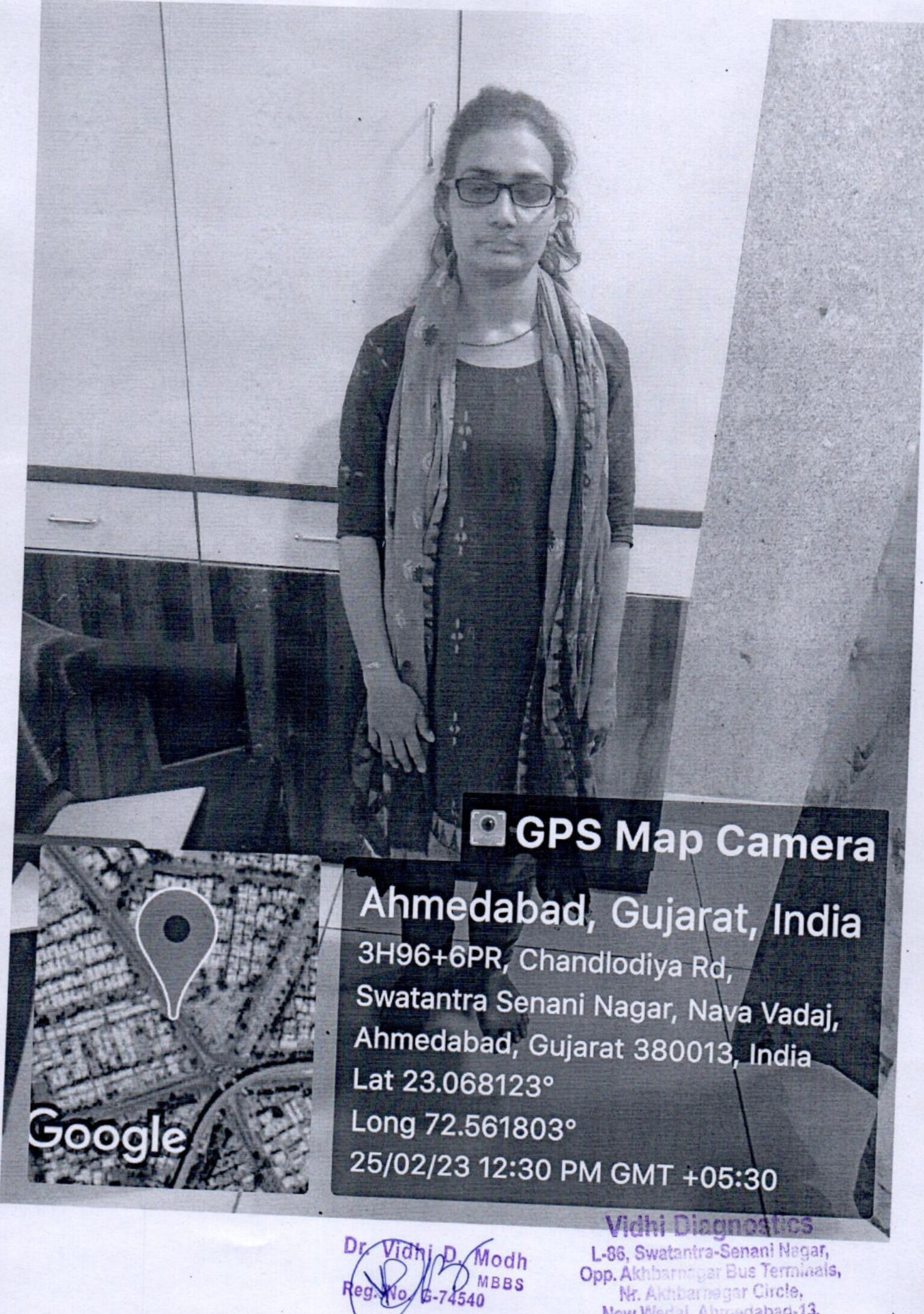
**6529 4159 5735**


*A.M. Dabhi*

Dr. Vidhi D. Modh  
MBBS  
Reg. No. G-74540

**Vidhi Diagnostics**  
L-86, Swatantra Senani Nagar,  
Opp. Akhbarnagar Bus Terminal,  
Nr. Akhbarnagar Circle,  
New Wadaj, Ahmedabad-13.





 **GPS Map Camera**

**Ahmedabad, Gujarat, India**

3H96+6PR, Chandlodiya Rd,  
Swatantra Senani Nagar, Nava Vadaj,  
Ahmedabad, Gujarat 380013, India

Lat 23.068123°

Long 72.561803°

25/02/23 12:30 PM GMT +05:30



Google

Dr. Vidhi D. Modh  
MBBS  
Reg. No. G-74540

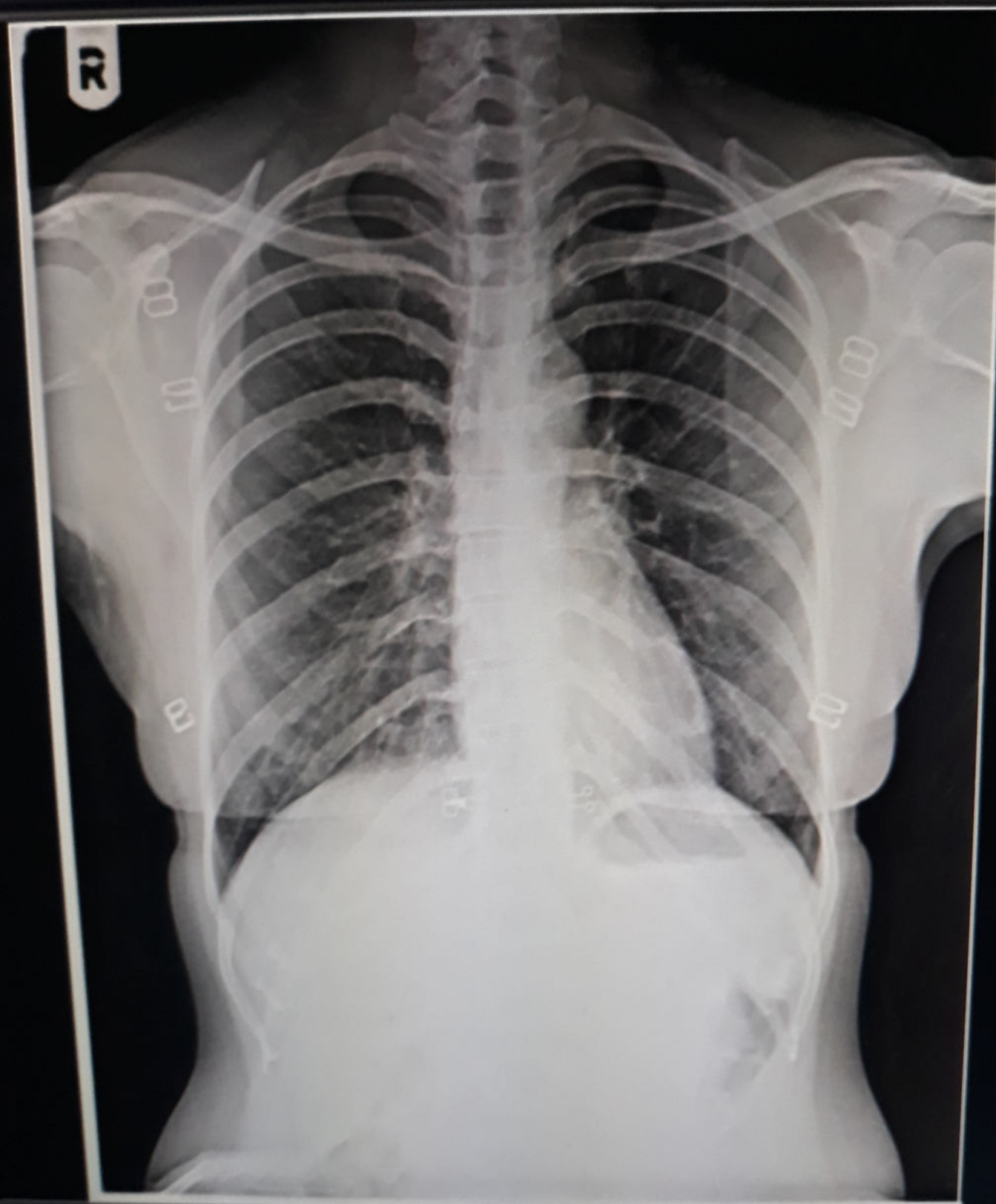**Vidhi Diagnostics**

L-86, Swatantra-Senani Nagar,  
Opp. Akhbarnagar Bus Terminals,  
Nr. Akhbarnagar Circle,  
New Wadaj, Ahmedabad-13.



ANISHA M DABHI 34YRS

25022312



1  
(1)



ALL

