

Name	ARUN KUMAR N	ID	MED111034623
Age & Gender	37Year(s)/MALE	Visit Date	3/26/2022 12:00:00 AM
Ref Doctor Name	MediWheel		

SONOGRAM REPORT WHOLE ABDOMEN

Indication: General check up

The liver is normal in size (13.6 cms) and shows mild fatty changes. No focal mass seen.

The gall bladder is normal sized and smooth walled and contains no calculus.

There is no intra or extra hepatic biliary ductal dilatation.

The pancreas shows a normal configuration and echotexture.

The pancreatic duct is normal.

The portal vein and IVC are normal.

The spleen is normal in size and measures 11.7 cm.

There is no free or loculated peritoneal fluid.

No para aortic lymphadenopathy is seen.

No abnormality is seen in the region of the adrenal glands.

The right kidney measures 9.4 x 4.0 cms.

The left kidney measures 9.0 x 4.8 cms.

Both kidneys are normal in size, shape and position. Cortical echoes are normal bilaterally.

There is no calculus or calyceal dilatation.

The ureters are not dilated.

Name	ARUN KUMAR N	ID	MED111034623
Age & Gender	37Year(s)/MALE	Visit Date	3/26/2022 12:00:00 AM
Ref Doctor Name	MediWheel		

The bladder is smooth walled and uniformly transonic. There is no intravesical mass or calculus.

The prostate measures 3.3 x 3.3 x 3.7 cms and is normal sized with a volume of 22 cc.

The echotexture is homogeneous.

The seminal vesicles are normal.

Iliac fossae are normal.

No mass or fluid collection is seen in the right iliac fossa. The appendix is not visualized.

IMPRESSION:

❖ **Mildly fatty liver.**

vj

DR. T. SANA
CONSULTANT SONOLOGIST

Name	ARUN KUMAR N	Customer ID	MED111034623
Age & Gender	37Y/M	Visit Date	Mar 26 2022 9:46AM
Ref Doctor	MediWheel		

X-RAY CHEST (PA VIEW)

Sub-optimal inspiratory effort is noted due to which cardiac size cannot be assessed.

The heart size and configuration are within normal limits. The aortic arch is normal.

The lung fields show normal broncho-vascular markings.

Both the pulmonary hila are normal in size.

The costophrenic and cardiophrenic recesses and the domes of diaphragm are normal.

The bones and soft tissues of the chest wall show no abnormality.

IMPRESSION:

- *No significant abnormality demonstrated.*


DR.REKHA S.CHERIAN, DMRD.DNB.FRCR.,
CONSULTANT RADIOLOGIST

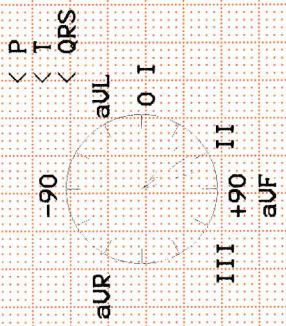
HR 73 bpm

170.0
87.6
30.7

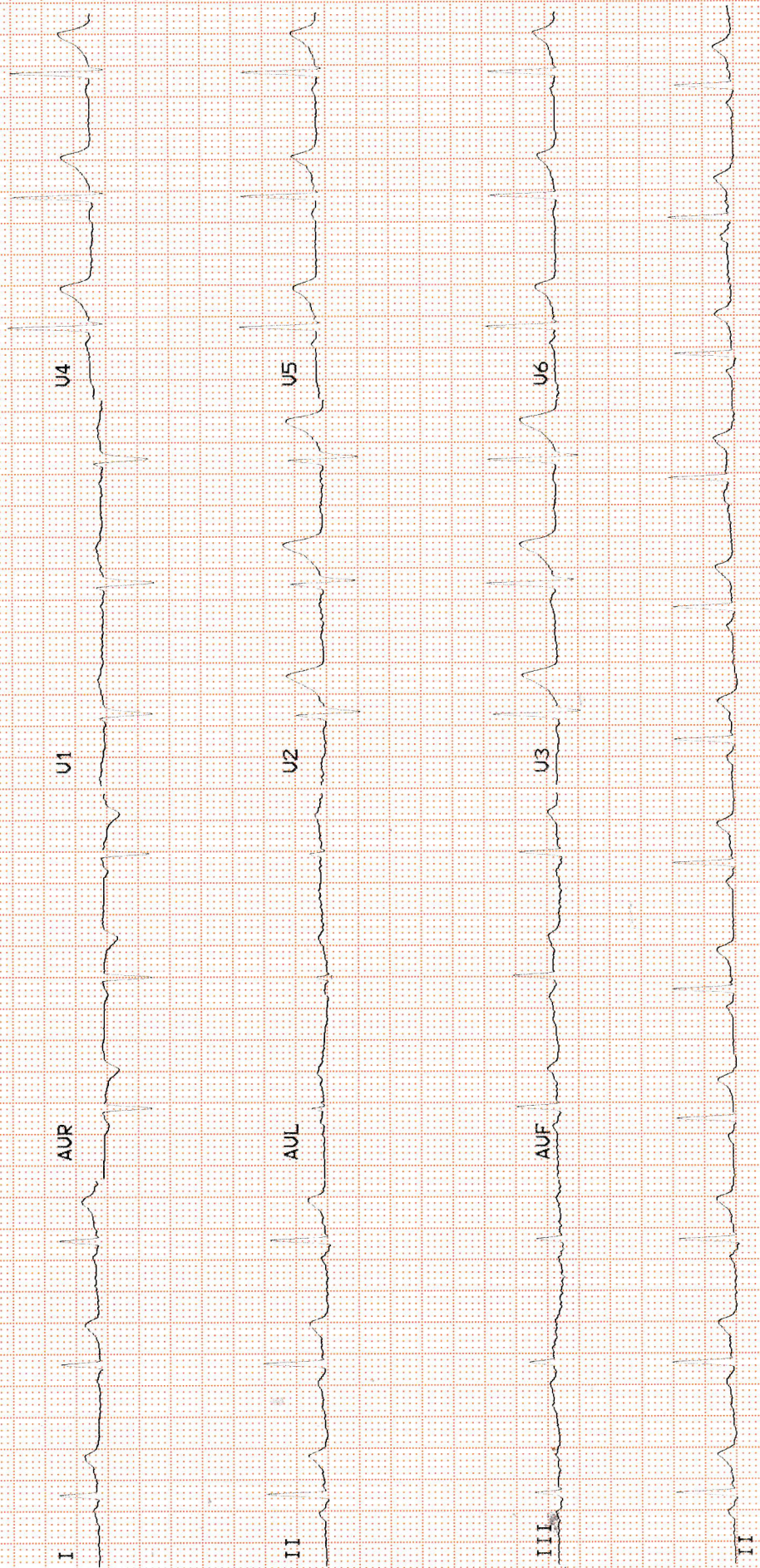
Measurement Results:

QRy : 88 ms
QT/QTcB : 378 / 416 ms
PR : 126 ms
P : 104 ms
RR/PP : 824 / 820 ms
P/QRS/T : 71 / 54 / 41 degrees

Interpretation:
12SL - Interpretation:
Normal sinus rhythm
Normal ECG



Unconfirmed report.



Name	ARUN KUMAR N	ID	MED111034623
Age & Gender	37Year(s)/MALE	Visit Date	3/26/2022 12:00:00 AM
Ref Doctor Name	MediWheel		

ECHO CARDIOGRAPHY REPORT

Measurements:-

M Mode:

IVS d	1.1 cm	IVS s	1.2 cm
LVID d	4.9 cm	LVID s	3.1 cm
LVPW d	1.1 cm	LVPW s	1.1 cm
AO	2.5 cm	LA	2.8 cm

Doppler study:

Location	m/sec	Location	m/sec
MP A vel	0.9	MV E	0.8
PGT	3 mmHg	A	0.6
AV vel	1.2	Ratio	1.36
PGT	5 mmHg	TV VEL	1.5
EF	64 %	PGT	9 mmHg
FS	35 %		

2D:

LA : NORMAL	RA : NORMAL
LV : NORMAL	RV : NORMAL
AV : NORMAL	PV : NORMAL
MV : NORMAL	TV : NORMAL
AO : NORMAL	PA : NORMAL


Name	ARUN KUMAR N	ID	MED111034623
Age & Gender	37Year(s)/MALE	Visit Date	3/26/2022 12:00:00 AM
Ref Doctor Name	MediWheel		

Observations:

- **Cardiac chambers dimension-normal**
- **No regional wall motion abnormality**
- **Normal LV systolic and diastolic function**
- **Doppler flow pattern normal**
- **No pulmonary hypertension**
- **Normal Pericardium**
- **IAS/ IVS appear Intact**
- **No mass**

CONCLUSIONS:

- ***NORMAL CARDIAC DIMENSIONS.***
- ***NO REGIONAL WALL MOTION ABNORMALITIES.***
- ***GOOD LV SYSTOLIC FUNCTION.***
- ***LVEF 64 %***



**Prof. N. Subramanian MD, DM(CARD) FRCP, FACC
Consultant Cardiologist**

Done By :-M.Padmapushani

Name	ARUN KUMAR N	ID	MED111034623
Age & Gender	37Year(s)/MALE	Visit Date	3/26/2022 12:00:00 AM
Ref Doctor Name	MediWheel		

Cardiac technologist

Name: MR. ARUN KUMAR N

Age & Sex: 37 YEARS/ MALE

Date : 26/03/2022

		Right Eye	Left Eye
DISTANT VISION	<u>Without Glasses</u>	<u>6/6</u>	<u>6/6</u>
NEAR VISION	<u>Without Glasses</u> <u>With Glass</u>	<u>N6</u>	<u>N6</u>
COLOUR VISION		NORMAL	
EXTERNAL EYE EXAMINATION		NORMAL	

REMARKS: Normal

Dr. Akila Ravikumar

Dr. Akila Ravikumar
MBBS., M.Phil., P.G.Dip. Diabetology
Regd. No. 46536
Consultant Family Physician & Diabetologist

