

DAKSH HOSPITAL

396 - 397, Gandhi Nagar, Scheme No. 8, ALWAR -301001

Ref. No.

Date.....

MEDICAL EXAMINATION REPORT

Mediwheel (BOB)

Name: Mrs. Sunita Jatav

Age: 50 yrs

Sex: Female

Date: 27/01/2024

General Physical Examination

Height : 158 cm
Pulse : 80 /mt
Respiration : 18 /mt

Weight : 75.4 Kg
BP : 150/100 mm/hg
BMI : 30.2 kg/m²

Systemic Exam:- NORMALDental Check up :- NORMALEye check-up :- NORMALSkin Check up:- NORMALENT Check up:- NORMAL

Gynae Check up:- Menopausal 17 yrs -
an - P3 Prunes
LD thin
Pap smear taken -
Flu MAD

Impression:-
DM
HTN, BMS.

Recommendation:-
- Better control of sugar / HTN / LVDL.
- Life style modification

Dr. Mukesh Kumar Gupta
MD Gen. Medicine
Reg. No 5423/16262

डॉ० मुकेश गुप्ता
M.D.F.C.C.S.
फिजिशियन एवं मधुमेह रोग विशेषज्ञ
दक्ष हॉस्पिटल, अलवर
रजि० नं०-5423/16262

Results

Run Date 27/01/2024 10:00:32 AM

Operator DAKSH

Last Name

Sample ID 5

First Name MRS SUNITA JATAV

Department

Gender Female Age

Physician DR. MUKESH GUPTA M.D

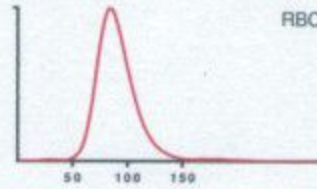
Patient ID AUTO_PID18998

Type Woman

Date of birth


Sample comments

				Range
RBC	5.24	*	10 ⁶ /μL	3.80 - 5.50
HGB	14.9		g/dL	11.5 - 15.2
HCT	47.6	h*	%	35.0 - 46.0
MCV	90.8	*	μm ³	77.0 - 97.0
MCH	28.4		pg	26.0 - 34.0
MCHC	31.3	L	g/dL	32.0 - 35.0
RDW-CV	17.6	H	%	11.0 - 17.0
RDW-SD	61.5	H	μm ³	37.0 - 49.0

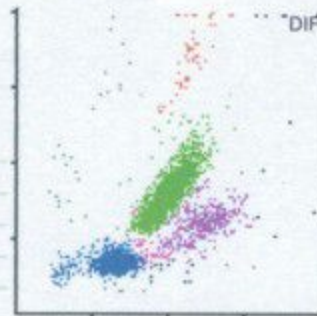


Susp. Pathologies
Anisocytosis
Macroplatelets

				Range
PLT	141	l*	10 ³ /μL	150 - 450
PCT	0.17		%	0.15 - 0.40
MPV	12.2	H	μm ³	8.0 - 11.0
PDW	23.2	h	μm ³	11.0 - 22.0
P-LCC	66		10 ³ /μL	44 - 140
P-LCR	47.1		%	18.0 - 50.0



			Range	
WBC	5.17		10 ³ /μL	3.50 - 10.00
	#		Range	%
NEU	2.62		1.60 - 7.00	50.9
LYM	2.18		1.00 - 3.00	42.3
MON	0.19	l	0.20 - 0.80	3.8
EOS	0.09		0.00 - 0.50	1.7
BAS	0.07		0.00 - 0.15	1.3 h
LIC	0.02		0.00 - 0.10	0.4



Dr. R.S. Gupta
Dr. R.S. GUPTA
MD (Pathology) (MAHE)
RMC No. 7924/19778

Date :-27/01/2024 Name :- MRS. SUNITA JATAV

Age & Sex :- 50 Yrs/ Female

Refd. :- Dr Mukesh Gupta M.D.

	TEST NAME	RESULT	REFERENCE RANGE	
	ESR	15	00 -20 mm/hrs	
	Blood Group & Rh Factor	A POSITIVE		
	HbA1C	6.8	4 - 5.6%	
	Blood Sugar (F)	165.1	< 70 - 100 mg/dl	
	Blood Sugar (PP)	185.7	< 140 mg/dl	
	Urine Sugar (F)	NIL	-	
	Urine Sugar (PP)	NIL	-	
LIVER	S.Bilirubin Total	1.3	0.30 - 1.20 mg/dl	
	S.Bilirubin Direct	0.4	0.10 - 0.30 mg/dl	
	S.Bilirubin Indirect	0.9	0.30 - 0.90 mg/dl	
	S.G.O.T.	29	> 37 u/l	
	S.G.P.T.	45	> 40 u/l	
	S.Alk. Phosp.	225	80 - 306 u/l	
	G.G.T.	20.1	5 -40 u/l	
	Total Protein	6.7	6.5 - 8.5 gm/dl	
	Albumin	3.6	3.8 - 5.4 gm/dl	
	Globulin	3.1	2.3 - 3.5 gm/dl	
	A/G Ratio	1.1	-	
AST/ALT Ratio	0.6	-		
KIDNEY	Blood Urea	31.2	15 -45 mg/dl	
	S.Creatinine	0.83	0.60 - 1.30 mg/dl	
	BUN	20.1	6 -24 mg/dl	
	S.Uric Acid	5.0	M 3.1 - 7.0, F 2.5 - 5.6 mg/dl	
	BUN/Creatinine Ratio	24.0	-	
LIPID PROFILE	Total Cholesterol	160.1	Up to 200 mg/dl	
	S.HDL	44.1	30 - 70 mg/dl	
	S.LDL	88.1	Up to 170 mg/dl	
	S.VLDL	28.1	5.0 - 40 mg/dl	
	S. Triglycerides	140.1	Up to 170 mg/dl	
	LDL/HDL Ratio	2.0	-	
	Total Cholesterol/ HDL Ratio	3.6	-	
THYROID	T3	95.1	40 - 181 ng/dl	
	T4	7.9	4.6 - 10.5 µg/dl	
	TSH	4.22	0.30 - 5.0 mIU/L	
URINE EXAMINATION			<i>Microscopic Examination:</i>	
General/Chemical Examination:	Colour	Pale Yellow	RBC	Absent
	Reaction	Acidic	WBC	2 -3
	Specific Gravity	QNS	Epithelial Cells	1-2
	Appearance	S.TURBID	Cast	Absent
	Albumin	Nil	Crystal	Absent
	Sugar	Nil	Spermatozoa	Absent
			Amorphous Sediments	Absent
		Other	Absent	
X-RAY CHEST	NORMAL STUDY			
STOOL EXAMINATION			<i>Microscopic Examination:</i>	
General/Chemical Examination:	Colour	-	RBC	-
	Consistency	-	WBC	-
			Ova & Parasites	-

Dr. R. S. GUPTA
MD (Pathology) (MAHE)
Reg. No. 7924/1978

TECHNOLOGIST

Date :- 28/01/2024

Name :- Mrs. Sunita Jatav

Refd. :- Dr Mukesh Gupta MD

Age & Sex :- 50Yrs/ Female

CYTO-PATHOLOGY

PAP SMEAR

1. Specimen type	Received two conventional smears.
2. Specimen adequacy	Smears are satisfactory for evaluation.
3. Microscopic finding	Smears are moderately cellular comprises of predominantly intermediate with mature superficial squamous epithelial cells arranged in clusters & scattered singly.
4. Inflammation	Not seen
5. Bacilli	Not seen
6. Endocervical cells	Not seen
7. Koilocytic changes	Not seen
8. Trichomonas	Not seen
9. Dysplasia	Nil
10. Neoplasia	Nil
11. Endometrial cells	Nil

Impression:- Negative for intraepithelial lesion or malignancy



Dr. R.S. GUPTA
MD (Pathology) (MAHE)
RMC No. 7924/19778

Doctor



TECHNOLOGIST

All investigation have their own limitations regarding the sensitivity & specificity of individual assay procedures, Isolated laboratory investigations never confirm the final diagnosis of the disease. They only help in arriving at a diagnosis in conjunction with clinical presentation and other related investigations. Report is not valid for medico-legal purpose subject to ALWAR jurisdiction only.



दक्ष हॉस्पिटल

396, गाँधी नगर स्कीम नं.8, अलवर (राज०) ☎ 0144-2703340

Sonography / 2D Echo Cardiography / Doppler Report

NAME :- MRS Sunita Jatav/F/50 YRS

27-Jan-24

BOB HEALTH CHECKUP

U.S.G. OF ABDOMEN & PELVIS

LIVER

Liver is 15.4 cm at MCL with normal echo-texture. Intra hepatic biliary radicals Are not dilated. No evidence of focal or diffuse lesion.

GALL BLADDER

Gall bladder is normal.

PANCREAS

Pancreas is normal in size, shape & echo-texture. No evidence of focal or diffuse lesion. MPD not dilated.

SPLEEN

9.5 cm in size with normal shape & echo- texture. Spleen vein is normal. No evidence of focal or diffuse lesion

KIDNEY

Right kidney has 4.4 mm mid pole stone without hydronephrosis.
Left kidney appear normal size, shape & echo-texture.

URINARY BLADDER

UB is normal.

UTERUS & OVARIES:

Small for age.

Impression:- Right kidney stone.

Advice- follow up/ hormonal study review at higher center for confirmation

Please correlate clinically. USG accuracy is 95 % due to technical limitations as well as inaccuracies inherent in the laboratory and statistical analysis biological process.
This report is not valid for medico-legal cases

DR. MUKESH GUPTA

Dr. Mukesh Kumar Gupta

Physician & Sonologist

RM 5423/16262



"भ्रूण लिंग परीक्षण की शिकायत

104 टोल फ्री सेवा पर भी की

जा सकती है"

भ्रूण लिंग परीक्षण की शिकायत 104 टोल फ्री सेवा पर भी की जा सकती है।



दक्ष हॉस्पिटल

396, गाँधी नगर स्कीम नं.8, अलवर (राज०) ☎ 0144-2703340

Sonography / 2D Echo Cardiography / Doppler Report

2D/ ECHO REPORT

Name: - Mrs Sunita Jatav

Age: - 50 Yrs

Date: - 27-Jan-24

Reg. No.: - Alw/2009/04
BOB health checkup

PROCEDURES: M-MODE/2D/DOPPLER/COLOR/CONTRAST B.A.S. M²

MEASUREMENT:		DOPPLER:	
AOD	25	NORMAL (20- 37mm)	MV 0.2 (0.8- 1.3)
LA	27	(19- 40mm)	AV 1.2 (1.2- 1.8)
AVO	17	(12- 25mm)	TV 0.6 (0.3- 0.8)
RVDD.	14	(03- 09mm)	PV 0.8 (0.7- 1.1)
LVDd	51	(37- 56mm)	MITRAL VALVE-
LVDs	34	(22- 40mm)	AML Normal
IVS d	11	(06- 12mm)	PML Normal
IVS s	18		
PWd	6.5	(05- 10mm)	AORTIC VALVE- CALCIFICATION
LV FUNCTION		TV & PV are normal.	
M- E- S Separation		<0.9cm	
Minor		24.42%	
LV Ejection Fraction	61%	65 +/- 12%	

A=E, LVDD
MILD CONCENTRIC LVH
LV WALL MOTION: NO RWMA
ALL CARDIAC CHAMBERS ARE NORMAL
ALL VALVES ARE NORMAL
NO CLOT, VEGETATION, PERICARDIAL EFFUSION

Adv: - Follow up/ review at higher center for confirmation

Note: - Please Correlate clinically. Due to technical limitations as well as inaccuracies inherent in the laboratory and statistical analysis of biological process. Diagnostic accuracy of ECHO is up to 95% only.
Report is not valid for medico-legal purpose.

DR. MUKESH GUPTA
PHYSICIAN

Dr. Mukesh Kumar Gupt.

Physician & Sonologist

RM 9423/10262



"भ्रूण लिंग परीक्षण की शिकायत
104 टोल फ्री सेवा पर भी की
जा सकती है"

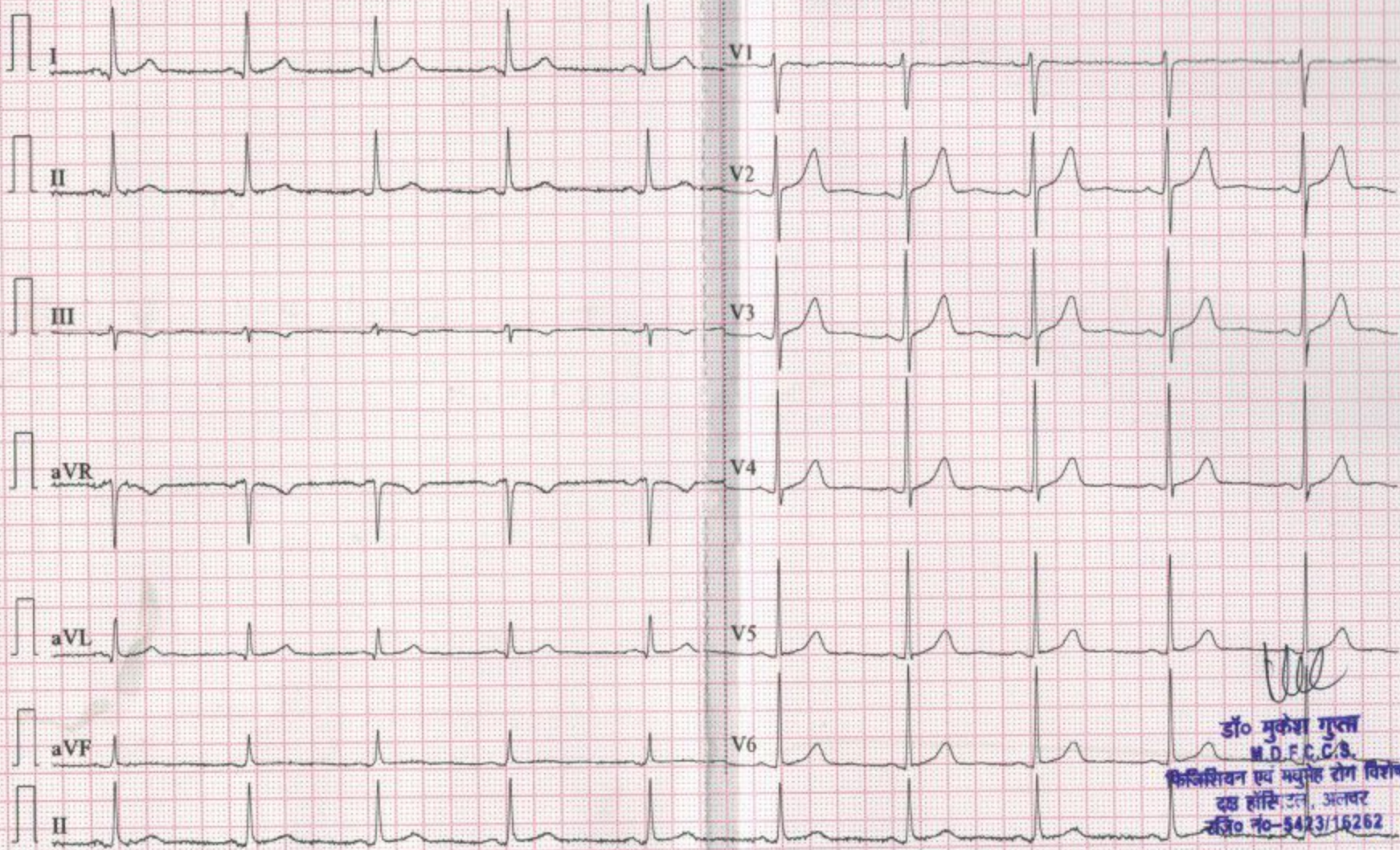भ्रूण लिंग परीक्षण की शिकायत 104 टोल फ्री सेवा पर भी की जा सकती है।

Female Years
Req. No. :

HR : 61 bpm
P : 124 ms
PR : 148 ms
QRS : 88 ms
QT/QTcBz : 420/423 ms
P/QRS/T : 29/29/24 °
RV5/SV1 : 1.838/0.874 mV

Diagnosis Information:
Sinus rhythm
Normal ECG

Report Confirmed by:



[Handwritten signature]

डॉ० मुकेश गुप्ता
M.D.F.C.C.S.
कैमिनिशियन एवं मयुमेक रोग विशेषज्ञ
दक्ष हॉस्पिटल, अलवर
फ़ोन नं०-5423/15262

R

