

**GAURAV MULTI SPECIALITY HOSPITAL
TIKHAMPUR= BALLIA**

PATIENT PRIYANKA SHARMA
REFERD BY DRD.RAI...(M.D).....

DATE 22/10/2022
AGE 36/F

CHEST X-RAY PA

INVESTIGATION: X Ray Chest PA View

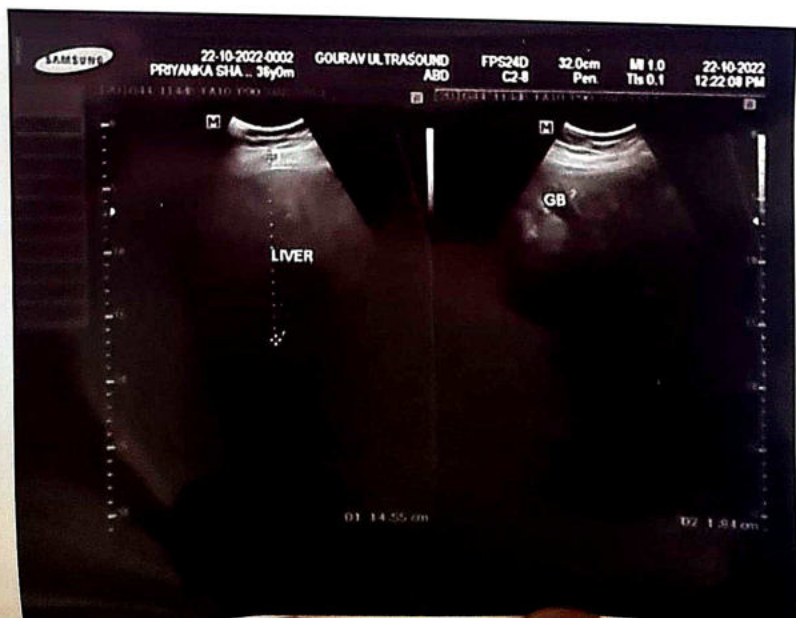
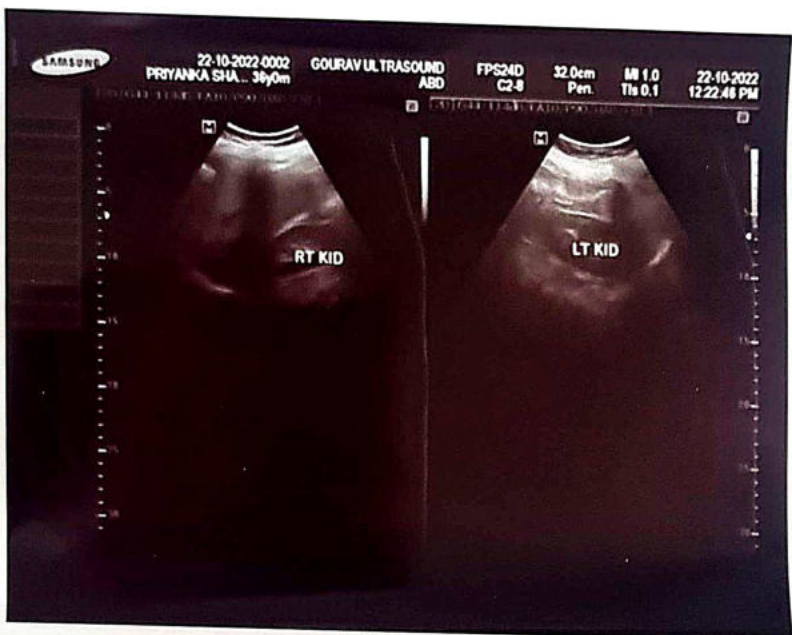
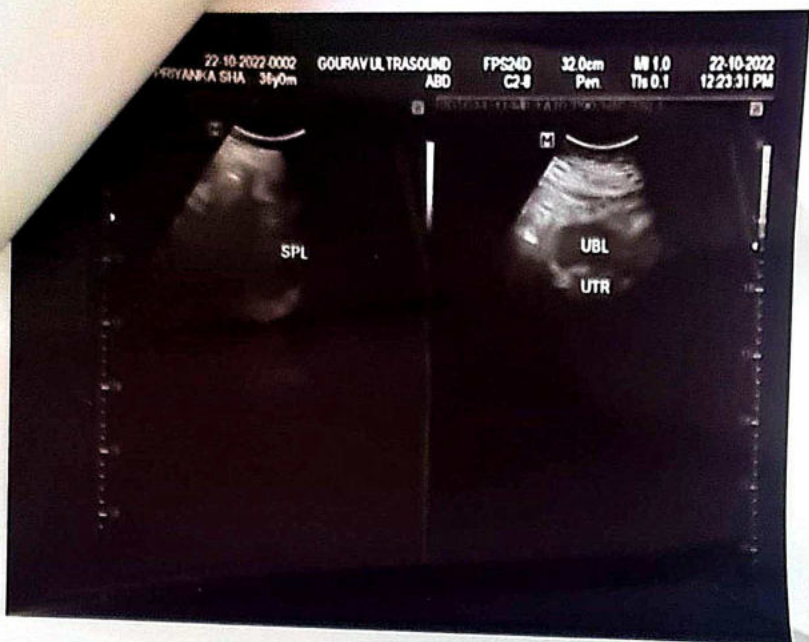- Both the lungs field are equally translucent
- Cardiac out line are normal
- The Costo-phernic angle are clear

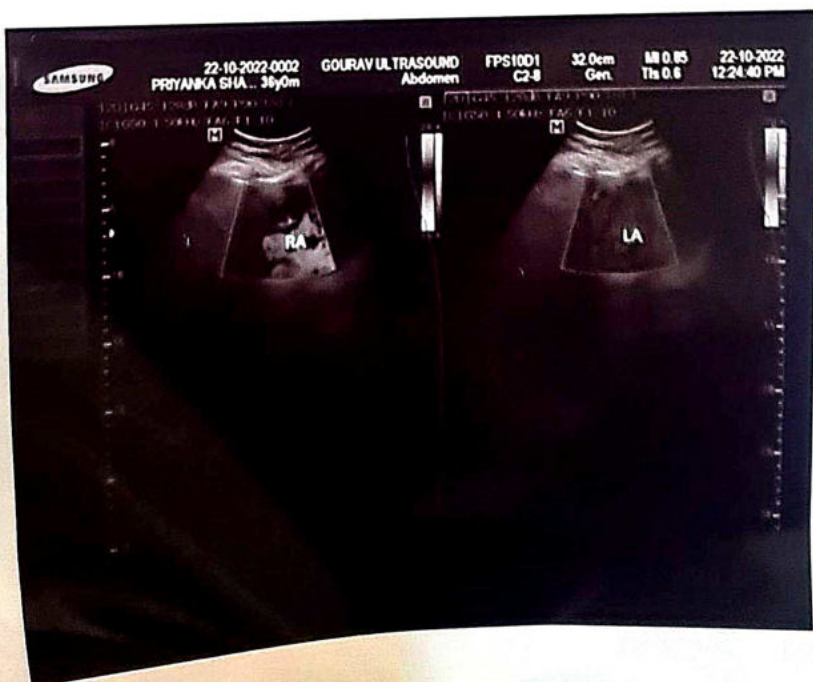
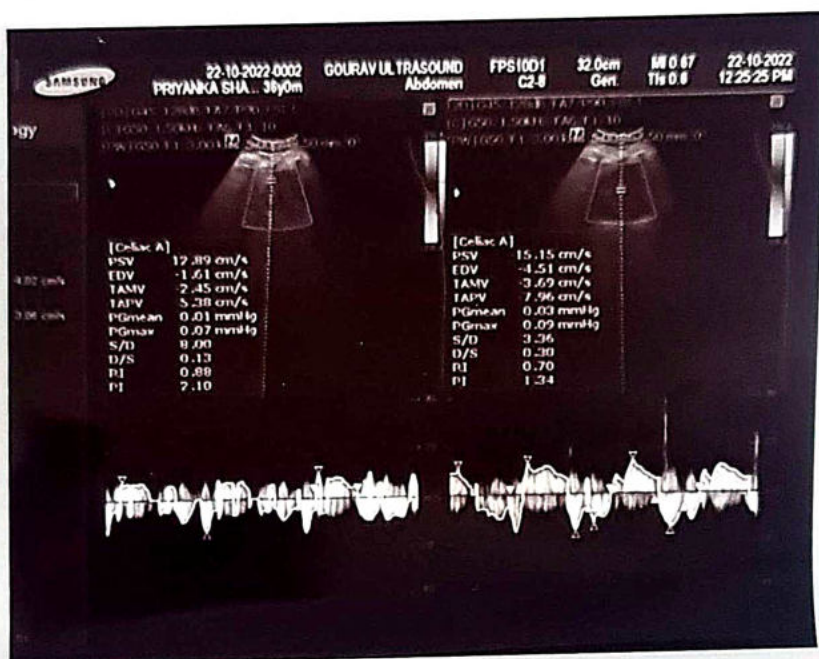
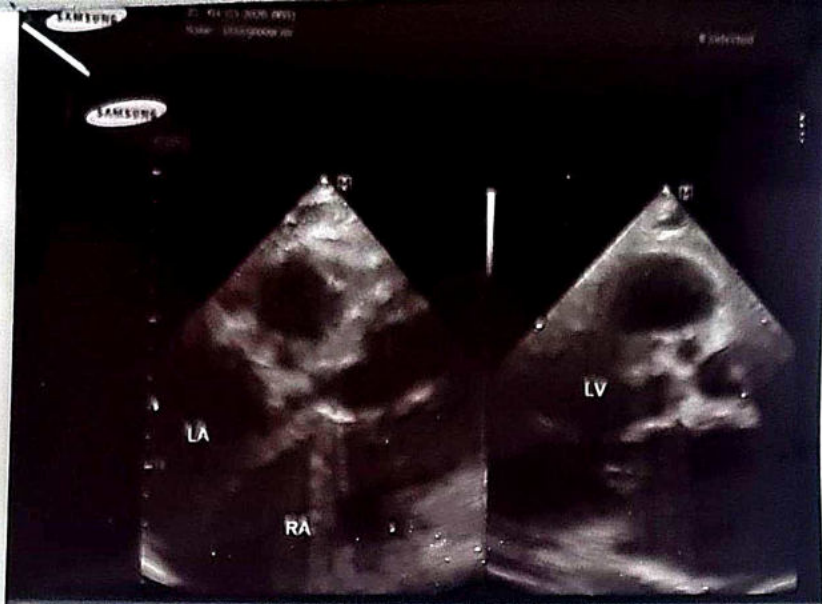
Heart size and Cardiac out line are Normal

- No hilar Meditational mass is seen
- No obvious Skeletal abnormality Seen

EMPRESSION : normal chest x ray .

Dr. Seema (Radiologist)
SIGNATURE
M.B.B.S., M.D.
Reg. No.-38790





GAURAV MULTI SPECIALITY HOSPITAL TIKHAMPUR -BALLIA

PATIENT : PRIYANKA SHARMA
REFERED BY :DR D. RAI MD

DATE :22/10/2020
AGE:36 /F

ECHOCARDIOGRAPHY & COLOR DOPPLER REPORT

QUALITY OF IMAGING : Fair

| MEASUREMENT/DIMENSIONS | ABSOLUTE VALUE | NORMAL (Adult) |
|------------------------|----------------|-------------------------|
| Aortic Root Diameter | 32.6mm. | 20 – 37 mm. < 22 mm/ m2 |
| Aortic Valve Opening | 24.4mm. | 15 – 26 mm. |
| Left Atrial Dimension | 33.2 mm. | 19 - 40 mm. < 22 mm/ m2 |
| RV Dimension | 20.6 | 07 – 26 mm. |
| RV Thickness | 07.9 mm. | 03 – 09 mm |
| LV ED Dimension | 39.6 mm. | 37 - 56 mm. < 32 mm/ m2 |
| LV ES Dimension | 31.2 mm. | 22 - 40 mm |
| IVS Thickness | 9.5 mm. | 09 – 11 mm |
| LVPW Thickness | 09.8 mm. | 05 – 11 mm |
| Mitral Valve Area | 8.28 cm2 | > 6 cm2 |
| Tricuspid Valve Area | 8.30 cm2 | > 7 cm2 |
| IVSeD / IV SeS | 08 – 09 mm | 06 – 12 mm |

| MORPHOLOGICAL | | | | | |
|-----------------|--------|-----------------|--------|----------------------|--------|
| Mitral Valve | NORMAL | Right Ventricle | Normal | Inter Atrial Septum | Normal |
| Tricuspid Valve | NORMAL | Left Ventricle | Normal | I.Ventricular Septum | Normal |
| Aortic Valve | NORMAL | Right Atrium | Normal | Aorta | Normal |
| Pulmonary Valve | NORMAL | Left Atrium | Normal | Pulmonary Artery | Normal |

2 D IMAGING :

LV & LA. are Normal & RV & RA is normal in size.

Pulmonary & Tricuspid Valves are normal.

Aortic & Mitral valve are not Stenosed.

I.V. Systolic function ; TRIVIAL.

I.V. Diastolic function : TRIVIAL.

M.R. & A.R. are not audible ; T.R. & P.R. & are not audible.

LV Ejection Fraction =59%.

RV Function ; Normal

Continued Page... 2.

GAURAV MULTI SPECIALITY HOSPITAL TIKHAMPUR -BALLIA

PATIENT : PRIYANKA SHARMA
REFERED BY : DR D. RAI MD

DATE : 22/10/2020
AGE: 36 /F

ECHOCARDIOGRAPHY & COLOR DOPPLER REPORT

Regional Wall Motion Abnormality (RWMA) : Normal at Rest.

Sinus Rhythm & No-Arrhythmia:- 72 BPM.

DOPPLER STUDY :

MR 0-0/4 ; TR 0/4 ; / AR 0-0/4 ; PR 0/4. (Normal Value 0-1 / 4).

Ao Pressure : Normal. . PASP = 29.8mm./Hg.

COLOR FLOW MAPPING :

Regurgitation Not Audible at MV, AV, : Regurgitation Not Audible at TCv.; PV.

FINAL IMPRESSION :

1. NORMAL; M.V. & A.V & NORMAL LT. ATRIUM & LT.VENTRICLE.
2. NORMAL LV EJECTION FRACTION 59%.
3. PULMONARY & TRICUSPID VALVES ARE NOT STENOSED.
4. NORMAL RV, S & D FUNTION & LV, S & D FUNTION; NORMAL PASP.
5. NORMAL RWMA AT REST; NO CARDIOMEGALY APPARENT.
6. SINUS RHYTHM; NO ARRHYTHMIA AND NO APPENDICULAR CLOT SEEN..

CARDIOLOGIST

Dr. Seema Pantley (Radiologist)

M.B.B.S., M.D.

Reg. No. 38790



भारत सरकार
Government of India



Download Date: 09/10/2020



प्रियंका शर्मा
Priyanka Sharma
जन्म तिथि/DOB: 26/07/1986
महिला/ FEMALE

Issue Date: 12/06/2017

4165 7924 4788

VID : 9169 0172 8996 3551

मेरा आधार, मेरी पहचान

DR. RAI MD (MED)
Physician
Garav Nur Home
Ball
11 (M.C.I)

GAURAV MULTISPECIALITY HOSPITAL BALLIA

DEPT OF ULTRA SONOGRAPHY

PATIENT : PRIYANKA SHARMA
REFERED BY : DR. D. RAI MD

DATE : 22/10/2020
AGE : 36 / F

WHOLE ABDOMEN : ULTRASOUND STUDY

LIVER

Liver normal in size & size 14.5 Cm. Intrahepatic biliary radicals, portal veins and hepatic veins are not dilated. Echogenicity is normal. No mass seen in liver.

GALL BLADDER

Gall bladder normal in shape and size no stone/mass seen in gallbladder wall thickness normal.

C.B.D. Normal in caliber.

PANCREAS

Pancreas is normal in shape, size and echo pattern.

SPLEEN

Spleen is normal in shape and size & size is 8.9 cm.

KIDNEYS

Both kidneys are normal in shape and size. Cortico-medullary differentiation is normal and no evidence of hydronephrosis seen at both Kidneys & No calculus is seen b/l kidneys.

URINARY BLADDER

Normal in shape, size inner mucosal thickening. Echo pattern is normal. No calculi / Mass / Lesion is seen.

UTERUS

: - It is normal in size, (58 x 30 x 30 mm.), Antiverted

& Ant flexed in position. Endometrium is Normal & regular (E.T.: -2-3 mm.)

No free fluid is seen in the cavity. No Mass / Lesion is seen

in Myometrium.

Cervix is normal ; 32 X 32 mm.

OVARIES

: - Both Ovaries are normal in size, No Cyst or mass / lesion is seen.

No large follicle seen at either Ovaries.

IMPRESSION

1. Liver normal. CBD, G.b. pancreas & spleen are normal.
2. Both kidneys normal with normal uterus & both ovaries.
3. Urinary bladder normal.
4. Gaseous bowel's loops.

SONOLOGIST
Dr. Seema Pandey (Radiologist)
M.B.B.S. M.D.
Reg. No. - 38790



Ph: 05498-241635

Gaurav Multispeciality Hospital

Near Chhaya Cinema, Tikhampur, Ballia (U.P.)

Pathology & Radiology

Regn. No.: 8585

Patient Name: Smt. PRIYANKA SHARMA

Address:

Referred By: Dr. D. RAI MD

Date : 22-10-2022

Age: 35 Years Sex: Female

Cardiac/Lipid Profile

| | | |
|-----------------------|--------------|--------------------|
| Total Serum Colestrol | 194.00 mg% | (150-250mg%) |
| Serum HDL Cholestrol | 38.00 mg/dl | (Male: 30-70mg/dl) |
| Serum LDL Cholestrol | 105.00 mg% | (60-115mg%) |
| VLDL | 30.40 mg% | (15-30mg%) |
| Serum Try Glyceride | 152.00 mg/dl | (25-160mg/dl) |

CBC

| | | |
|-----------------------|------------|-----------------------|
| Haemoglobin | 11.7 g/dl | (Male: 13.5-18.0g/dl) |
| Total Leucocyte Count | 5200 /cumm | (4000-11000/cumm) |

Differential Leucocyte Count

| | | |
|------------------|-----------------|--------------------------|
| Nutrophils | 52 % | (50-70%) |
| Eosinophils | 06 % | (1-4%) |
| Basophils | 00 % | (0-1%) |
| Lymphocytes | 42 % | (20-30%) |
| Monocytes | 00 % | (1-3%) |
| Blast Cells | 00 % | (0-1%) |
| Toxic/Bend Cells | 00 % | (0-1%) |
| Platelets Count | 01.80 Lacs/cumm | (1.5-4Lacs/cumm) |
| Total RBCs Count | 03.09 mill/cumm | (Male: 3.8-5.3mill/cumm) |
| M.C.V. | 84.9 fl | (80-100fl) |
| M.C.H. | 29.9 Pg | (27-32Pg) |
| M.C.H.C. | 34.7 g /dl | (32-36g /dl) |

Dr. CHALNA
M.B.B.S., D.C.P.
Dip. Pathology (K.I.C.)
Regd. No. 5945
Gaurav Multispeciality Hospital
Tikhampur, Ballia Centre

Note: We use sterilized disposable syringe & needle for every patient.
This report not valid for medico-legal purpose. It is to help clinician better patient management.
Discrepancies due to technical or typing error should be reported immediately within 24 hours for correction.



Ph: 05498-241635

Gaurav Multispeciality Hospital

Near Chhaya Cinema, Tikhampur, Ballia (U.P.)

Pathology & Radiology

Regn. No.: 8585

Patient Name: Smt. PRIYANKA SHARMA

Address:

Referred By: Dr. D. RAI MD

Date: 22-10-2022

Age: 35 Years Sex: Female

BIO CHEMISTRY

| | | |
|---------------------|-----------|--------------|
| Serum Calcium | 08.40 mg% | (9-11mg%) |
| Total Serum Protein | 06.90 gm% | (6-8gm%) |
| Serum Albumin | 04.50 gm% | (3-5gm%) |
| Serum Globulin | 02.40 gm% | (1.5-3.5gm%) |
| Serum Uric Acid | 03.50 mg% | (3-7mg%) |

SEROLOGICAL REPORT

| | | |
|---------------------------|--------------|----------------|
| Serum T3 (Rai Method) | 126.40 ng/dl | (70-190ng/dl) |
| Serum T4 (Rai Method) | 04.90 ug/dl | (5-12.5ug/dl) |
| Serum TSH (Rai Method) | 02.09 YU/ml | (0.3-6.5YU/ml) |

Dr. CHALMA
M.B.S., D.C.P.
D.N.B. (Pathology) (RAC)
Regd. No. - 55481
Gaurav Multispeciality Hospital
Tikhampur, Ballia

Note.: We use sterilized disposable syringe & needle for every patient.
This report not valid for medico-legal purpose. It is to help clinician better patient management.
Discrepancies due to technical or typing error should be reported immediately within 24 hours for correction.



Ph: 05498-241635

Gaurav Multispeciality Hospital

Near Chhaya Cinema, Tikhampur, Ballia (U.P.)

Pathology & Radiology

Regn. No.: 8585

Patient Name: Smt. PRIYANKA SHARMA

Address:

Referred By: Dr. D. RAI MD

Date: 22-10-2022

Age: 35 Years Sex: Female

Kidney Profile

| | | |
|------------------|-------------------|----------------------|
| Serum Urea | 24.00 mg/dl | (13-45mg/dl) |
| Serum Creatinine | 00.85 mg/dl | (Male: 0.7-1.4mg/dl) |
| Serum Sodium | 138.00 mmol/Liter | (135-155mmol/Liter) |
| Serum Potassium | 03.78 mmol/Liter | (3.5-5.5mmol/Liter) |
| Serum Chloride | 99.91 mmol/Liter | (89-111mmol/Liter) |

Liver Profile

| | | |
|----------------------------|-------------|------------|
| Serum Total Bilirubin | 00.89 mg% | (0.2-1mg%) |
| Serum Direct Bilirubin | 00.38 mg% | (0-0.2mg%) |
| Serum Indirect Bilirubin | 00.51 mg% | (0-0.8mg%) |
| SGPT | 09.00 unit | (5-35unit) |
| SGOT | 32.00 unit | (5-45unit) |
| Serum Alkaline Phosphatase | 103.00 IU/L | |

Normal Range:- Male: 50 - 126 (20-50 years), 57 - 111 (>60 years)
Normal Range:- Female: 37 - 103 (20 - 50 years), 50 - 143 (>60 years)
Higher Value Seen in growing children

HAEMATOLOGICAL REPORT

| | | |
|----------------------|-----------|---|
| E.S.R. (Windrops) | 15 mm/hr. | (Male: 0-9mm/hr.) (Female: 0-20mm/hr.) |
|----------------------|-----------|---|

BIO CHEMISTRY

| | | |
|------------------------|-----------|-------------|
| Fasting Plasma Glucose | 88.00 mg% | (70-110mg%) |
|------------------------|-----------|-------------|

DR. CHALNA
Pathologist, D.C.P.
D.M. (Pathology) (MCh)
Regd No. 2243 (MCh)
Gaurav Multispeciality Hospital
Tikhampur, Ballia

Note.: We use sterilized disposable syringe & needle for every patient.
This report not valid for medico-legal purpose. It is to help clinician better patient management.
Discrepancies due to technical or typing error should be reported immediately within 24 hours for correction.



Ph: 05498-241635

Gaurav Multispeciality Hospital

Near Chhaya Cinema, Tikhampur, Ballia (U.P.)

Pathology & Radiology

Regn. No.: 8585

Patient Name: Smt. PRIYANKA SHARMA

Address:

Referred By: Dr. D. RAI MD

Date : 22-10-2022

Age: 35 Years Sex: Female

URINE ANALYSIS

Urine Routine Analysis

Macroscopic Finding

| | |
|-------------|-------------|
| Quantity | Sufficient |
| Colour | Pale Yellow |
| Appearance | Transparent |
| Sediment | NIL |
| Reaction | 6.0 |
| Sp. Gravity | 1.012 |

Microscopic Finding

| | |
|--------------|---------------|
| Pus Cells | 4-6 /HPF |
| RBCs | Not Seen /HPF |
| Epith. Cells | 2-4 /HPF |
| Bacteria | Not Seen /HPF |
| Casts | Not Seen /HPF |
| Crystals | Not Seen /HPF |
| Spermatazoa | Not Seen /HPF |
| Parasites | Not Seen /HPF |

Chemical Finding

| | |
|---------|-----|
| Glucose | NIL |
| Protien | NIL |

REMARK Fresh Urine Sample is Examined

End of Report

DR. CHALU
B.B.S. (M.D.)
DINAKHAR PGD
Pathologist, Technician
Regd. No. 5487 (MCO)
Gaurav Multispeciality Hospital
Tikhampur, Ballia

Note.: We use sterilized disposable syringe & needle for every patient.
This report not valid for medico-legal purpose. It is to help clinician better patient management.
Discrepancies due to technical or typing error should be reported immediately within 24 hours for correction