

# REVIVAL DIAGNOSTICS



## HEALTH CHECK-UP SUMMARY

Name: Payal Parmar

Date: 10/12/2022

Email ID:

Sex: F/27 Age: 27 Years Contact No: 9726280771 Remarks:

Under-weight	<input type="checkbox"/>
Normal	<input checked="" type="checkbox"/>
Over-weight	<input type="checkbox"/>

i> **BMI**

Height (in Cm): <u>154</u>	Weight (in Kg): <u>42</u>	BMI: <u>20.02</u>
----------------------------	---------------------------	-------------------

ii> **Blood Pressure & Pulse**

110/68 mmHg  
72/min.

If high or low, whether the person is on medication: YES /  NO

iii> **Blood Tests & Lung Function Remarks**

RS  
CVS } (N)  
CVS

If abnormal, whether the person is on medication: YES /  NO

iv> **Eye Test Remarks**

Eye Test: (R) 6/6 (L) 6/6 - with specs  
Color Vision: with normal

v> **Heart Disease**

Whether any specific heart ailment detected (ECG findings):  
normal

vi> **Any other problems needing attention / Overall Assessment :**

NO

Dr. Chirag Patel  
M.B.B.S. G-49432  
Signature of the Doctor

Payal

**Revival Diagnostic**  
401, Aqua Corridor, Hazira Road, Adajan Paal, Surat-395009.  
B/s. Star Bazar, Surat-395009  
Mo. 9108744601

Laboratory Test Result are Subject to technical limitation and should be clinically correlate for final diagnosis



NAME: Payal Parmar SEX: F  
BIRTHDATE: 20/12/1994 AGE: 27

## DEPARTMENT OF OPHTHALMOLOGY

### EYE TEST:

#### 1. VISION:

RIGHT EYE - 6/6

LEFT EYE - 6/6

#### 2. COLOR VISION:

RIGHT EYE - ②

LEFT EYE - ②

#### 3. FUNDUS:

RIGHT EYE - ②

LEFT EYE - ②

### REMARKS:

**Revival Diagnostic**

401, Aqua Corridor,  
B/s. Star Bazar, Surat-395009  
Mo. 91062-28601

**Ophthalmologist/Optometrlist**

② *Payal*

Laboratory Test Result are Subject to technical limitation and should be clinically correlate for final diagnosis

4th Floor, Aqua Corridor, Hazira Road, Adajan Pal, Surat-395009.

☎ 0261 2747788, 9825947712 ✉ revivaldiagnostics.surat@gmail.com 🌐 www.revivaldignostics.com

This medical report is not intended for medico-legal purposes.



## Dental Assessment Form

NAME Poyal Parmar  
AGE 27

DATE 10/12/2022  
SEX F

### \* CHIEF COMPLAINT

- A CLINICAL FEATURES :- (2)
- 1 CAVIES :- }  
2 MISSING TOOTH :- } (2)  
3 MALOCCLUSION :- }  
4 FILLING :- }
- B DIAGNOSIS :- wound
- C PERSONAL HISTORY :- Hygienic
- D PROVISIONAL D/G :- (2)
- E MEDICAL HISTORY :- NO
- F FINAL D/G :- wound
- G TREATMENT PLAN :- NO

CLINT SIGN

Poyal

**Revival Diagnostic**  
401, Aqua  
B/g, Star Bazar, 395009  
DOCTOR SIGN  
Mo. 91062-28601

Laboratory Test Result are Subject to technical limitation and should be clinically correlate for final diagnosis

4th Floor, Aqua Corridor, Hazira Road, Adajan Pal, Surat-395009.

☎ 0261 2747788, 9825947712 ✉ revivaldiagnostics.surat@gmail.com 🌐 www.revivaldiagnostics.com

This medical report is not intended for medico-legal purposes.



Name	<b>PAYAL P PARMAR</b>	Age/Gender	<b>28Yrs/Female</b>
Reg No.	<b>3885/22</b>	Receipt No	<b>3585</b>
Referred By	<b>BOB - MEDI WHEEL(PKG10000241)</b>	Mode of Payment	<b>CREDIT</b>
Collection Type	<b>CENTER</b>	Collection DateTime	<b>10-Dec-2022 08:35 AM</b>

### **BLOOD GROUP** - 1012229 Released at 10-Dec-2022 11:20 AM

Parameter	Result	Biological Ref.Range	Method
-Blood Group	"O"		
-Rh Factor	POSITIVE		

### **CBC** - 1012227 Released at 10-Dec-2022 03:06 PM

Parameter	Result	Biological Ref.Range	Method
-Haemoglobin	13.9 gm/dL	(12 - 16 gm/dL)	Auto
-RBC Count	4.78 mill/cumm	(4.2 - 5.4 mill/cumm)	Auto
-Total WBC Count	6900 /cumm	(4000 - 10000 /cumm)	Auto
-Platelet Count	3.57 lakh/cumm	(1.5 - 4.5 lakh/cumm)	Auto

### **Blood Indices**

-HCT	42.2 %	(40 - 55 %)	Auto
-MCV	88.2 fl	(80 - 92 fl)	Auto
-MCH	29.0 pg	(27 - 31 pg)	Auto
-MCHC	32.8 gm/dL	(32 - 36 gm/dL)	Auto
-RDW	12.9 %	(11 - 15 %)	Auto

### **Diff WBC Count**

-Polymorphs	55 %	(40 - 80 %)	Microscopic, lly
-Lymphocytes	40 %	(20 - 40 %)	Microscopic, lly
-Eosinophils	03 %	(1 - 6 %)	Microscopic, lly
-Monocytes	02 %	(2 - 7 %)	Microscopic, lly
-Basophils	00 %	(0 - 1 %)	Microscopic, lly
-PLATELET ON SMEAR	Adequate		Microscopic, lly
-MALARIAL PARASITES	Malarial Parasites Not Detected		Microscopic, lly

[Test performed on Fully Automated Hematology Analyzer ERBA H-360]

**Revival Diagnostics**  
401-Aqua Corridor,  
Beside Star Bazar, Adajan,  
Surat-395007. Mo. 9825947712

Dr. Shivangi Gandhi  
M.B.B.S, M.D (Pathology)

Laboratory Test Result are Subject to technical limitation and should be clinically correlate for final diagnosis

4th Floor, Aqua Corridor, Hazira Road, Adajan Pal, Surat-395009.

0261 2747788, 9825947712 revivaldiagnostics.surat@gmail.com www.revivaldiagnostics.com

This medical report is not intended for medico-legal purposes.

# REVIVAL DIAGNOSTICS



Name	PAYAL P PARMAR	Age/Gender	28Yrs/Female
Reg No.	3885/22	Receipt No	3585
Referred By	BOB - MEDI WHEEL(PKG10000241)	Mode of Payment	CREDIT
Collection Type	CENTER	Collection DateTime	10-Dec-2022 08:35 AM

**ESR** - 1012227 Released at 10-Dec-2022 11:27 AM

Parameter	Result	Biological Ref.Range	Method
-E.S.R	06 mm/hr	(3 - 15 mm/hr)	



**Revival Diagnostics**  
401-Aqua Corridor,  
Beside Star Bazar, Adajan,  
Surat-395009. Mol 9825947712

Dr. Shivangi Gandhi  
M.B.B.S, M.D (Pathology)

Laboratory Test Result are Subject to technical limitation and should be clinically correlate for final diagnosis

📍 4th Floor, Aqua Corridor, Hazira Road, Adajan Pal, Surat-395009.

☎ 0261 2747788, 9825947712 ✉ revivaldiagnostics.surat@gmail.com 🌐 www.revivaldiagnostics.com

This medical report is not intended for medico-legal purposes.



Name	<b>PAYAL P PARMAR</b>	Age/Gender	<b>28Yrs/Female</b>
Reg No.	<b>3885/22</b>	Receipt No	<b>3585</b>
Referred By	<b>BOB - MEDI WHEEL(PKG10000241)</b>	Mode of Payment	<b>CREDIT</b>
Collection Type	<b>CENTER</b>	Collection DateTime	<b>10-Dec-2022 08:35 AM</b>

**FBS & PPBS** - 1012228 Released at 10-Dec-2022 02:18 PM

Parameter	Result	Biological Ref.Range	Method
-Fasting Blood Sugar (FBS)	92 mg/dL	70-100 mg/dl Impaired Tolerance:100-125 Diabetes Mellitus:>=126 (On more than one occasion) (American diabetes association guidelines 2022)	
-Fasting Urine Sugar	Absent		
-Fasting Urine Acetone	Absent		
-PPBS	110 mg/dL	(90 - 140 mg/dL)	
-PP2BS URINE SUGAR	Absent		
-PP2BS URINE ACETONE	Absent		

**HBA1C** - 1012227 Released at 10-Dec-2022 02:18 PM

Parameter	Result	Biological Ref.Range	Method
-HBA1C	5.1 %	HbA1C Degree of Glucose Control <5.6 % Non Diabetics 5.7 - 6.4 % Prediabetics > =6.5 % Diabetics (REF:Wallace, 11th Edition ) REMARKS: 6 - 7 % Excellent Control 7 - 8 % Good Control 8 - 10 % Unsatisfactory Control >10 % Poor Control	Boronate Affinity
-Method[]	High Performance Liquid Chromatography (HPLC)		

## Revival Diagnostics

401-Aqua Corridor,  
Beside Star Bazar, Adajan,  
Surat-395009. Mo. 9825947712

Dr. Shivangi Gandhi  
M.B.B.S, M.D (Pathology)

Laboratory Test Result are Subject to technical limitation and should be clinically correlate for final diagnosis

4th Floor, Aqua Corridor, Hazira Road, Adajan Pal, Surat-395009.

0261 2747788, 9825947712 revivaldiagnostics.surat@gmail.com www.revivaldiagnostics.com

This medical report is not intended for medico-legal purposes.



Name	<b>PAYAL P PARMAR</b>	Age/Gender	<b>28Yrs/Female</b>
Reg No.	<b>3885/22</b>	Receipt No	<b>3585</b>
Referred By	<b>BOB - MEDI WHEEL(PKG10000241)</b>	Mode of Payment	<b>CREDIT</b>
Collection Type	<b>CENTER</b>	Collection DateTime	<b>10-Dec-2022 08:35 AM</b>

### Lipid Profile - 1012229 Released at 10-Dec-2022 12:15 PM

Parameter	Result	Biological Ref.Range	Method
-Serum Cholesterol	132 mg/dL	Desirable < 200 mg/dl Borderline High : 200-239 mg/dl High : > 240 mg/dl	CHOD-PAP
-Serum Triglyceride	62 mg/dL	Normal < 150 mg/dl Borderline High : 150 - 159 mg/dl High : 200 - 499 mg/dl Very High : 500 mg/dl	GPO-POD Method
-Serum HDLD(Direct)	41 mg/dL	Normal :> 55 mg/dl Borderline : 35-55 mg/dl Undesirable: < 35 mg/dl	PVS-PEGME CHOD-POD Precipitation with
-Serum VLDL	12 mg/dL	(5 - 30 mg/dL)	Calculated
-Serum LDLD(Direct)	79 mg/dL	Optimal:< 100 mg/dl Above Optimal : 100- 129 mg/dl Borderline High : 130-159 mg/dl High : > 160-189mg/dl Very High : >190 mg/dl	Calculated
-Chol/HDL	3.22	Low risk: <3.8 Medium Risk: 3.8 to 5.9 High Risk: > 6	Calculated
-LDL/Chol	1.68	Low risk: <3.55 Medium Risk: 3.55 to 4.0 High Risk: > 6	Calculated

[Test performed on Fully Automated Biochemistry Analyzer ERBA EM200]

**Revival Diagnostics**  
401-Aqua Corridor,  
Beside Star Bazar, Adajan,  
Surat-395009. Mo. 9825947712

Dr. Shivangi Gandhi  
M.B.B.S, M.D (Pathology)

Laboratory Test Result are Subject to technical limitation and should be clinically correlate for final diagnosis

📍 4th Floor, Aqua Corridor, Hazira Road, Adajan Pal, Surat-395009.

☎ 0261 2747788, 9825947712 ✉ revivaldiagnostics.surat@gmail.com 🌐 www.revivaldiagnostics.com

This medical report is not intended for medico-legal purposes.



Name	PAYAL P PARMAR	Age/Gender	28Yrs/Female
Reg No.	3885/22	Receipt No	3585
Referred By	BOB - MEDI WHEEL(PKG10000241)	Mode of Payment	CREDIT
Collection Type	CENTER	Collection DateTime	10-Dec-2022 08:35 AM

## LIVER FUNCTION TEST (LFT) - 1012229 Released at 10-Dec-2022 12:12 PM

Parameter	Result	Biological Ref.Range	Method
-Serum Total Bilirubin	0.5 mg/dL	(0 - 1.3 mg/dL)	Diazo
-Serum Direct Bilirubin	0.2 mg/dL	(0 - 0.4 mg/dL)	Diazo
-Serum InDirect Bilirubin	0.3 mg/dL	(0.1 - 1.3 mg/dL)	Calculated
-Total Protein (TP)	6.4 gm/dL	(6.4 - 8.3 gm/dL)	Biuret
-Albumin (ALB)	3.5 gm/dL	(3.5 - 5.2 gm/dL)	BCG
-Globulin	2.9 gm/dL	(2.3 - 3.6 gm/dL)	Calculated
-A/G Ratio	1.21 gm/dL	(1 - 2.3 gm/dL)	Calculated
-SGPT(ALT)	15 U/L	(5 - 45 U/L)	IFCC, Kinetic Phosphate without Pyridoxal
-SGOT (AST)	17 U/L	(0 - 35 U/L)	IFCC, Without Pyridoxal Phosphate
-Alkaline Phosph.	63 U/L	(42 - 128 U/L)	ALP-AMP
-GGT	16 U/L	(5 - 50 U/L)	Glupa-C

[Test performed on Fully Automated Biochemistry Analyzer ERBA EM200]

REVIVAL  
DIAGNOSTICS

## Revival Diagnostics

401-Aqua Corridor,  
Beside Star Bazar, Adajan,  
Surat-395009. Mo. 9825947712

Dr. Shivangi Gandhi  
M.B.B.S, M.D (Pathology)

Laboratory Test Result are Subject to technical limitation and should be clinically correlate for final diagnosis

📍 4th Floor, Aqua Corridor, Hazira Road, Adajan Pal, Surat-395009.  
☎ 0261 2747788, 9825947712 ✉ revivaldiagnostics.surat@gmail.com 🌐 www.revivaldiagnostics.com

This medical report is not intended for medico-legal purposes.





Name	<b>PAYAL P PARMAR</b>	Age/Gender	<b>28Yrs/Female</b>
Reg No.	<b>3885/22</b>	Receipt No	<b>3585</b>
Referred By	<b>BOB - MEDI WHEEL(PKG10000241)</b>	Mode of Payment	<b>CREDIT</b>
Collection Type	<b>CENTER</b>	Collection DateTime	<b>10-Dec-2022 08:35 AM</b>

**Creatinine** - 1012229 Released at 10-Dec-2022 12:15 PM

Parameter	Result	Biological Ref.Range	Method
-Creatinine	0.8 mg/dL	(0.6 - 1.14 mg/dL)	ENZYMATIC

**BUN** - 1012229 Released at 10-Dec-2022 12:15 PM

Parameter	Result	Biological Ref.Range	Method
-Blood Urea Nitrogen (BUN)	12 mg/dL	(6 - 20 mg/dL)	Calculated

**Uric Acid** - 1012226 Released at 10-Dec-2022 12:15 PM

Parameter	Result	Biological Ref.Range	Method
-Uric Acid	4.6 mg/dL	(3.5 - 7.2 mg/dL)	Uricase-POD



**Revival Diagnostics**  
401-Aqua Corridor,  
Beside Star Bazar, Adajan  
Surat-395009. Mo. 9825947712

Dr. Shivangi Gandhi  
M.B.B.S, M.D (Pathology)

Laboratory Test Result are Subject to technical limitation and should be clinically correlate for final diagnosis

📍 4th Floor, Aqua Corridor, Hazira Road, Adajan Pal, Surat-395009.  
☎ 0261 2747788, 9825947712 ✉ revivaldiagnostics.surat@gmail.com 🌐 www.revivaldiagnostics.com

This medical report is not intended for medico-legal purposes.



Name	<b>PAYAL P PARMAR</b>	Age/Gender	<b>28Yrs/Female</b>
Reg No.	<b>3885/22</b>	Receipt No	<b>3585</b>
Referred By	<b>BOB - MEDI WHEEL(PKG10000241)</b>	Mode of Payment	<b>CREDIT</b>
Collection Type	<b>CENTER</b>	Collection DateTime	<b>10-Dec-2022 08:35 AM</b>

**Total T3 T4 TSH** - 1012229 Released at 10-Dec-2022 01:52 PM

Parameter	Result	Biological Ref.Range	Method
-Total T3	0.91 ng/ml	(0.87 - 1.78 ng/ml)	Fluorescence Immunoassay Enzyme
-Total T4	8.22 ug/dl	(4.6 - 11 ug/dl)	Fluorescence Immunoassay Enzyme
-TSH	1.84 uIU/ml	0.50 - 5.50 uIU/ml 5.5 to 15 ul U/ml - Suggested Clinical co-relation or Repeat test with new sample as physiological factors can give falslely high TSH Above 15uIU/ml Hypothyroid PREGNANT WOMEN normal ranges for TSH: 1st Trimester : 0.0878 - 2.8293 uIU/ml 2nd Trimester : 0.1998 - 2.7915 uIU/ml 3rd Trimester : 0.307 - 2.9028 uIU/ml Ref: TIETZ Fundamentals of Clinical Chemistry	Fluorescence Immunoassay Enzyme

[Test performed on Fully Automated Immunology Analyzer Maglumi-600]

**Revival Diagnostics**  
401-Aqua Corridor,  
Beside Star Bazar, Adajan,  
Surat-395009. Mo. 9825947712

Dr. Shivangi Gandhi  
M.B.B.S, M.D (Pathology)

Laboratory Test Result are Subject to technical limitation and should be clinically correlate for final diagnosis

📍 4th Floor, Aqua Corridor, Hazira Road, Adajan Pal, Surat-395009.  
☎ 0261 2747788, 9825947712 ✉ revivaldiagnostics.surat@gmail.com 🌐 www.revivaldiagnostics.com

This medical report is not intended for medico-legal purposes.



Name	PAYAL P PARMAR	Age/Gender	28Yrs/Female
Reg No.	3885/22	Receipt No	3585
Referred By	BOB - MEDI WHEEL(PKG10000241)	Mode of Payment	CREDIT
Collection Type	CENTER	Collection DateTime	10-Dec-2022 08:35 AM

**Urine Routine & Micro Examination** - 10122211 Released at 10-Dec-2022 12:16 PM

Parameter	Result	Biological Ref.Range	Method
<b>Physical Examination</b>			
-Quantity	30		Manual
-Colour	Pale Yellow	Pale Yellow	Manual
-Appearance	Clear	Clear	Manual
-Reaction (pH)	Acidic		Dipstick
-Specific Gravity	1.020		Dipstick
<b>Chemical Examination</b>			
-Proteins.	Absent		Dipstick
-Sugar	Absent		Dipstick
-Acetone.	Absent		Dipstick
-Bile Salts	Absent	Absent	Dipstick
-Bile Pigments	Absent	Absent	Dipstick
-Occult Blood Test (OBT).	Negative		Dipstick
<b>Microscopic Examination</b>			
-Pus Cells	1-2		Microscopically
-Red Blood Cells	Absent		Microscopically
-Epithelial Cells	2-3		Microscopically
-Bacteria.	Absent		Microscopically
-Crystals	Absent	Absent	Microscopically
-Others	NIL	Absent	Microscopic Examination

**Revival Diagnostics**  
 401-Aqua Corridor,  
 Beside Star Bazar, Adajan,  
 Surat-395009. Mo. 9825947712  
 Dr. Shivangi Gandhi  
 M.B.B.S, M.D (Pathology)

Laboratory Test Result are Subject to technical limitation and should be clinically correlate for final diagnosis



## 2D-ECHOCARDIOGRAPHY & COLOR DOPPLER REPORT

Name:	PAYAL P. PARMAR	Age/Gender	28Yrs /Female
Referred by.	MEDI WHEEL	Date	10/12/2022

**INDICATION:** Preventive Health check up


- **CARDIAC CHAMBERS:** Left Ventricle: Normal size, Left Atrium: Normal size.
- No e/o thrombus in LA/LV.
- **Right Atrium:** Normal size. **Right Ventricle:** Normal size,
- **Normal Right Ventricular function.** (TAPSE=20mm)
- **Normal Left Ventricular systolic function. LVEF = 60% ,**  
No regional wall abnormality. No thinning / scarring / dyskinesia of LV wall.
- **No Concentric Left Ventricular Hypertrophy.** (IVSd= 10 mm),
- **LV Compliance :**  
NO Left Ventricular Diastolic Dysfunction [LVDD].
- **VALVES:**
- Structurally Normal Mitral valve/ Aortic valve/Tricuspid valve/ Pulmonary valve .  
No significant Valvular Stenosis.
- **Doppler findings:** AV max = 1.21 m/s, PV max = 0.90 m/s.  
Trivial MR, Trivial Tricuspid regurgitation.
- **No Pulmonary Arterial Hypertension.** PASP by TRjet vel.method = 23 mmHg.
- **SEPTAE:** IAS / IVS Appear Intact.
- **IVC :** Normal in dimension and shows good inspiratory 15mm collapse.
- **OTHERS:** No e/o Pericardial effusion / vegetation.

### IMPRESSION:

**NORMAL LV SYSTOLIC FUNCTION, LVEF= 60 %, NO RWMA,  
NO LVH , NO LVDD , NO PAH.**

**Revival Diagnostic**

401, Aqua Corridor,  
E/s. Star Bazar, Surat-395009  
Mo. 91062-28601

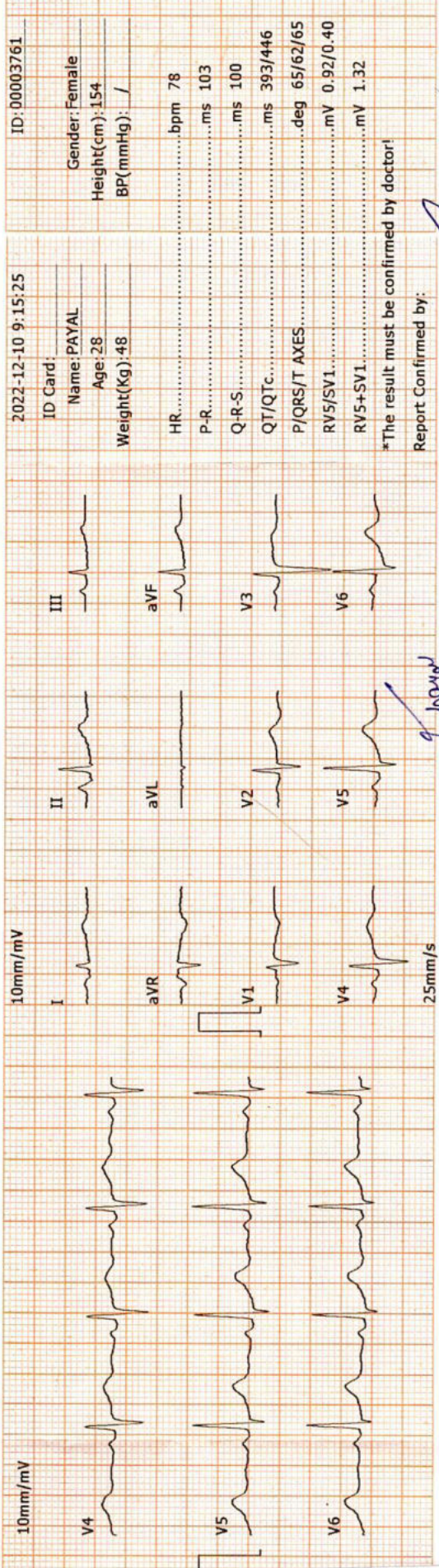
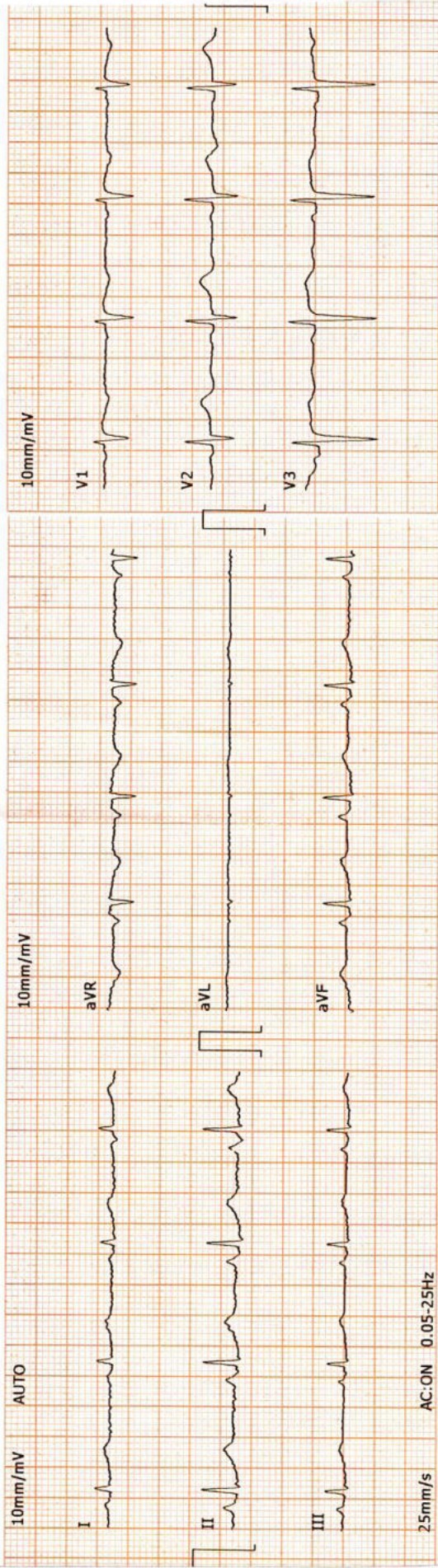
  
**DR. ADITYA BORA**  
MBBS,DNB,PGDCC  
**PHYSICIAN & CLINICAL  
CARDIOLOGIST**

Laboratory Test Result are Subject to technical limitation and should be clinically correlate for final diagnosis

📍 4th Floor, Aqua Corridor, Hazira Road, Adajan Pal, Surat-395009.

☎ 0261 2747788, 9825947712 ✉ revivaldiagnostics.surat@gmail.com 🌐 www.revivaldiagnostics.com

This medical report is not intended for medico-legal purposes.



2022-12-10 9:15:25 ID: 00003761

ID Card: \_\_\_\_\_  
 Name: PAYAL  
 Age: 28  
 Weight(Kg): 48

Gender: Female  
 Height(cm): 154  
 BP(mmHg): /

HR: ..... bpm 78  
 P-R: ..... ms 103  
 Q-R-S: ..... ms 100  
 QT/QTc: ..... ms 393/446  
 P/QRS/T AXES: ..... deg 65/62/65  
 RV5/SV1: ..... mV 0.92/0.40  
 RV5+SV1: ..... mV 1.32

\*The result must be confirmed by doctor!  
 Report Confirmed by: \_\_\_\_\_

**DR. ADITI PATEL**  
 M.B.B.S., D. CARD (MUM)  
 CLINICAL CARDIOLOGIST  
 REG.NO.G-42901

**Revival Diagnostic**  
 401, Aque Corridor,  
 B/s. Star Bazar, Surat: 395009  
 Mo. 91062-28601

# REVIVAL DIAGNOSTICS



Name	PAYAL P PARMAR	Age/Gender	28Yrs/Female
Reg No.	3885/22	Receipt No	3585
Referred By	BOB - MEDI WHEEL(PKG10000241)	Mode of Payment	CREDIT
Collection Type	CENTER	Collection DateTime	10-Dec-2022 08:35 AM

## ECG

- REPORT :

1. The rhythm is sinus.
2. Heart rate is 78 beats per minute.
3. Normal P,QRS,T wave axis.
4. Normal PR,QRS,Q.T. Duration.
5. No pathological q wave or ST-T changes seen.
6. No evidence of chamber hypertrophy or enlargement seen.

**IMPRESSION : ECG WITHIN NORMAL LIMITS**

**Revival Diagnostic**  
401, Aqua Corridor,  
S. Star Bazar, Surat-395009  
Mo. 91062-28501

**DR. ADITI PATEL** Signature  
M.B.B.S., D. CARD (MUM)  
CLINICAL CARDIOLOGIST  
REG.NO.G-42901

Laboratory Test Result are Subject to technical limitation and should be clinically correlate for final diagnosis

📍 4th Floor, Aqua Corridor, Hazira Road, Adajan Pal, Surat-395009.

☎ 0261 2747788, 9825947712 ✉ revivaldiagnostics.surat@gmail.com 🌐 www.revivaldiagnostics.com

This medical report is not intended for medico-legal purposes.



Name	<b>PAYAL P PARMAR</b>	Age/Gender	<b>28Yrs/Female</b>
Reg No.	<b>3885/22</b>	Receipt No	<b>3585</b>
Referred By	<b>BOB - MEDI WHEEL(PKG10000241)</b>	Mode of Payment	<b>CREDIT</b>
Collection Type	<b>CENTER</b>	Collection DateTime	<b>10-Dec-2022 08:35 AM</b>

## USG OF ABDOMEN & PELVIS

### LIVER:

Liver is normal in size, shape and echotexture.  
No evidence of focal SOL or dilatation of IHBR seen.  
Portahepatis appear normal.

### GALLBLADDER:

Gallbladder is distended and appears normal.  
No e/o calculus, mass lesion or changes of cholecystitis seen.

### PANCREAS:

Pancreas appears normal in size, shape and echotexture.  
No e/o focal lesion, mass or changes of pancreatitis seen.

### SPLEEN:

Spleen appears normal in size, shape and echotexture.

### PARAAORTIC REGION:

Aorta grossly appears normal. No e/o paraaortic lymphnodes seen.

### KIDNEYS:

Both kidneys appear normal in size, shape, position and echotexture.  
Cortex and collecting system of both kidneys appear normal.  
No evidence of calculus or obstructive uropathy on either side.

### URINARY BLADDER:

Bladder is distended and appears normal.  
No calculus, mass lesion or changes of cystitis is seen.

### UTERUS:

Retroverted, Normal in size, shape and echotexture with empty central uterine cavity.  
Cervix appears normal.  
No e/o focal SOL. Endometrial thickness is normal.

### OVARIES:

Both adnexal region appear normal.  
No e/o adnexal mass lesion seen on either side.  
No evidence of free fluid seen in pelvis.

**COMMENTS: NORMAL USG ABDOMEN AND PELVIS.**

**Dr. Chirag K. Patel**  
MBBS-DNB  
Reg. No. G-23509  
Revival Diagnostic  
4th Floor, Aqua Corridor  
N. Star Bazar, Hazira Main Road,  
Adajan, Surat-395009.  
No. 97200 720003  
Radiologist

Laboratory Test Result are Subject to technical limitation and should be clinically correlate for final diagnosis

📍 4th Floor, Aqua Corridor, Hazira Road, Adajan Pal, Surat-395009.

☎ 0261 2747788, 9825947712 ✉ revivaldiagnostics.surat@gmail.com 🌐 www.revivaldiagnostics.com

This medical report is not intended for medico-legal purposes.

2

NAME : PAYAL R. PARMAR  
AGE : 28 YRS/FEMALE  
REF. BY : MEDI WHEEL







Name	PAYAL P PARMAR	Age/Gender	28Yrs/Female
Reg No.	3885/22	Receipt No	3585
Referred By	BOB - MEDI WHEEL(PKG10000241)	Mode of Payment	CREDIT
Collection Type	CENTER	Collection DateTime	10-Dec-2022 08:35 AM

### CHEST RADIOGRAPH (PA VIEW)

- Hilar shadows are within normal limits.
- Pulmonary vasculature appears normal.
- Cardiac appears normal in size.
- Both dome of the diaphragm are smooth.
- Both costophrenic recesses are clear.
- Both lung fields appear normal.
- Visualized bones and soft tissue shadows appear normal.

IMPRESSION: NORMAL STUDY.

DR. CHIRAG K PATEL  
RADIOLOGIST

REVIVAL  
DIAGNOSTICS

Dr. Chirag K. Patel

MBBS-DMPD

Reg. No. G-23509

Signature  
Revival Diagnostics

4th Floor, Aqua Corridor,  
Nr. Star Bazar, Hazira Main Road,  
Adajan, Surat-395009.  
Mo. 97266 726683

Laboratory Test Result are Subject to technical limitation and should be clinically correlate for final diagnosis

📍 4th Floor, Aqua Corridor, Hazira Road, Adajan Pal, Surat-395009.

☎ 0261 2747788, 9825947712 ✉ revivaldiagnostics.surat@gmail.com 🌐 www.revivaldiagnostics.com

This medical report is not intended for medico-legal purposes.