



# SENTINI HOSPITALS

CENT PERCENT CARE



NABH ACCREDITED HOSPITAL

G. Medicine

D. Sivisha  
Age: 30/F

Dr. P. LALITHA  
Reg. No: 40050 MBBS, M.D.  
Consultant Physician & Diabetologist  
SENTINI HOSPITALS  
VIJAYAWADA - 520008  
Cell No 9848340244

Date: 10/09/22  
Dr - P. Lalitha  
Dr - K. Harish

at 50kg

- Normotensive
- Non diabetic

Came for routine checkup  
w. Abdominal Discomfort

BP - 110/80 mm of Hg

HT - Regular

CUS - S/S L+

Wgt - b/w air entry +

Adv.

1) T - PAN 40mg  
for (10)



W/O abd.  
② Study

10-09-2022 09:43:42 AM

ID : 17

Name :

Age :

Years :

Gender :

Female

HR 105 BPM

P Dur 100 ms

PR int 141 ms

QRS Dur 90 ms

QT/QTc int 323/428 ms

P/QRS/T axis 73/11/57 °

RV5+SV1 amp 1.079/1.261 mV

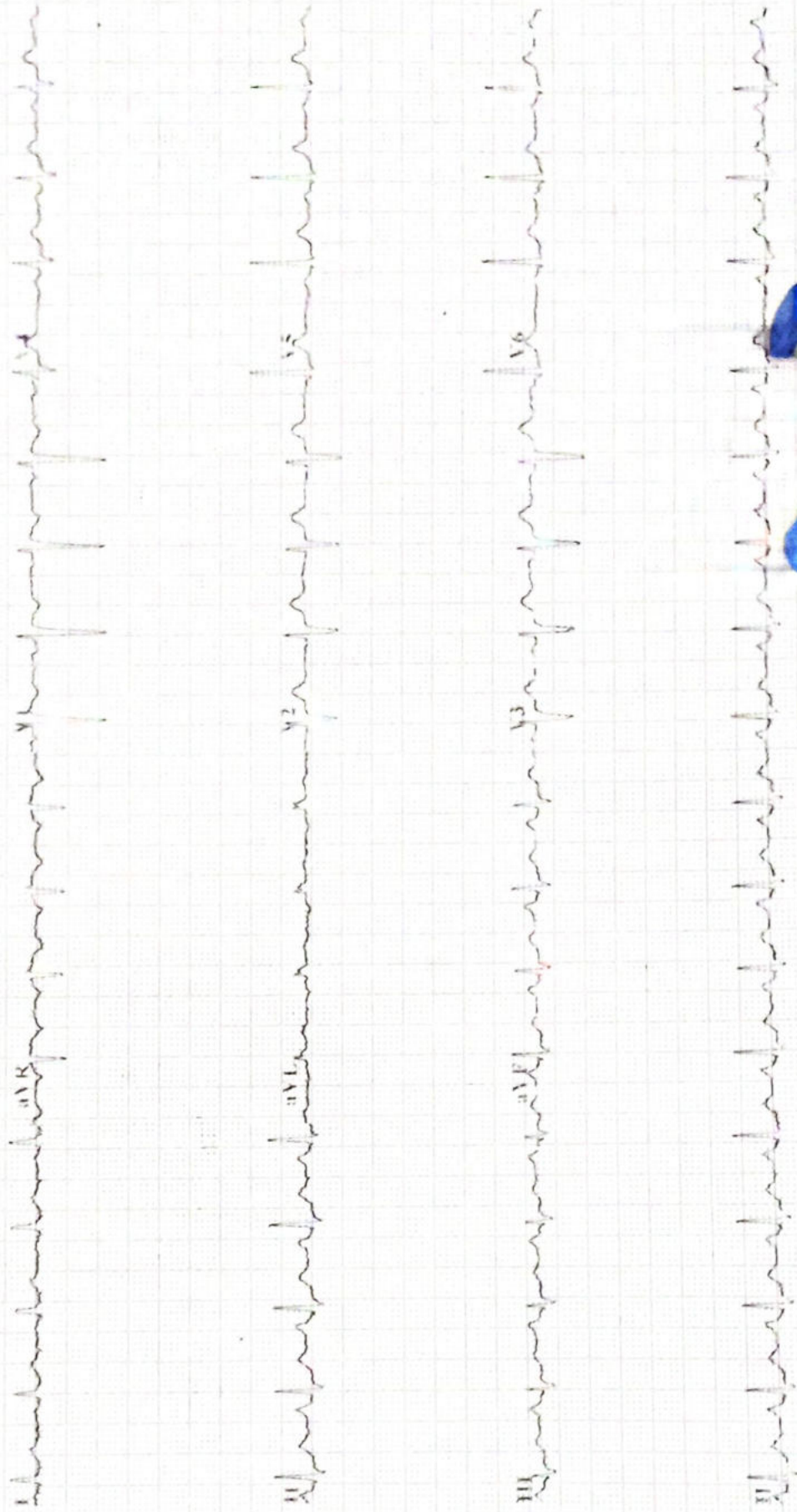
RV6+SV6 amp 2.290 mV

RV6/5V6 amp 0.332/0.563 mV

Diagnosis: Infection  
Acute myocardial infarction  
ECG

D. Srisheela  
8046

Report Confirmed by:





**Department Of Laboratory**

Date :

<b>Name</b> : Mrs. DANDABATHINA SIRISHA	<b>Age /Sex</b> : 30 Y(s)/Female
<b>Bill Date</b> : 10-Sep-2022 08:13 AM	<b>UMR No.</b> : UMR2212412
<b>Rept. Dt</b> : 10-Sep-2022 10:58 AM	<b>Bill No.</b> : BIL22018361
<b>Ref By</b> : Dr.GENERAL HEALTH CHECK UP	<b>Result No</b> : 0 / RES22019580

**Parameter**

**Result**

**Normal Values**

**LIPID PROFILE**

Fasting Blood Sugar	: 91 mg/dl	70 - 110 mg/dl
Total Cholesterol	: 161 mg/dl	150 - 240 mg/dl
Triglycerides	: 138 mg/dl	50 - 200 mg/dl
HDL Cholesterol	: 38 mg/dl	
LDL Cholesterol	: 96 mg/dl	80 - 160 mg/dl
VLDL	: 27 mg/dl	10 - 50 mg/dl
Cholesterol / HDL ratio	: 4.2	< 6
LDL / HDL	: 2.5	< 4

**LFT(LIVER FUNCTION TEST)**

Total Bilirubin	: 0.5 mg/dl	0.1 - 1.2 mg/dl
Direct Bilirubin	: 0.1 mg/dl	0.0 - 0.3 mg/dl
Indirect Bilirubin	: 0.4 mg/dl	
SGOT	: 20 IU/L	5 - 55 IU/L
SGPT	: 18 IU/L	5 - 55 IU/L
Alkaline Phosphatase	: 99 IU/L	Adult : 35 - 125 IU/L Children : 125 - 330 IU/L
Total Protein	: 6.8 gm/dl	6.0 - 8.3 gm/dl
Albumin	: 3.8 gm/dl	3.2 - 5.0 gm/dl
Globulin	: 3.0 gm/dl	2.5 - 3.0 gm/dl
A / G RATIO	:* 1.2	1.51 - 1.81

\*\*\* End Of Report \*\*\*

Lab Tech.

Bio-Chemist

Lab In-Charge

Incharge Pathologist

Correlate Clinically

We use only sterilised disposable syringes & needles.

This report is to help you for better management of patient and not valid for medicolegal purpose.

Discrepancies due to technical or typing errors should be reported within 3 days for correction.



**Department Of Laboratory**

Date :

<b>Name</b> : Mrs. DANDABATHINA SIRISHA	<b>Age /Sex</b> : 30 Y(s)/Female
<b>Bill Date</b> : 10-Sep-2022 08:13 AM	<b>UMR No.</b> : UMR2212412
<b>Rept. Dt</b> : 10-Sep-2022 10:58 AM	<b>Bill No.</b> : BIL22018361
<b>Ref By</b> : Dr.GENERAL HEALTH CHECK UP	<b>Result No</b> : 0 / RES22019580

<u>Parameter</u>	<u>Result</u>	<u>Normal Values</u>
<b>RFT (RENAL FUNCTION TEST)</b>		
BLOOD UREA	: 13 mg/dl	13 - 45 mg/dl
Serum Creatinine	: 0.7 mg/dl	0.7 - 1.4 mg/dl
<b>URINE ROUTINE EXAMINATION</b>		
Sugar	: Nil	
Albumin	: Trace	
<b>Microscopic Examination</b>		
Pus cells	: 3-4 /HPF	
Epithelial cells	: 2-3 /HPF	
RBC	: 1-2 /HPF	
Casts	: Nil /HPF	

\*\*\* End Of Report \*\*\*

Lab Tech.

Bio-Chemist

Lab In-Charge

Incharge Pathologist

Correlate Clinically, We use only sterilised disposable syringes & needles.

Discrepancies due to technical or typing errors should be reported within 3 days for correction.

This report is to help you for better management of patient and not for legal purpose.



D. SIRISHA

Date: 10/09/2022

UMR Date: 2412

Age/Sex: 30Y/F

Ref: GENERAL

**REAL TIME ULTRASONOGRAPHY OF THE ABDOMEN**

**LIVER:** Normal in size, shape and outline. Parenchymal texture Normal. No focal cystic or solid mass lesion. No intrahepatic biliary dilatation. Intrahepatic portion of IVC is normal.  
Portal vein is normal. Porta hepatis is normal.

**G. B:** Normal.

**C.B.D:** Not dilated.

**PANCREAS:** Parenchymal texture normal. No ductal dilatation. No calculi.

**SPLEEN:** Normal in size & echotexture.

**AORTA:** Normal.

**KIDNEYS:** **Right kidney** measures 9.0 x 4.2cm .  
Normal in size, shape and outline. Parenchymal texture normal.  
Corticomedullary differentiation is well made out and is normal.  
No evidence of calculi/ Hydronephrosis.

**Left kidney** measures 9.5 x 4.3cm  
Normal in size, shape and outline. Parenchymal texture normal.  
Corticomedullary differentiation is well made out and is normal.  
No evidence of calculi / Hydronephrosis.

**U.B:** Normal.

**UTERUS** : Normal

**OVARIES** : Normal

\* No evidence of free fluid / lymphadenopathy.

**IMPRESSION:**

- **NORMAL STUDY.**

- For clinical correlation & follow up.

  
Dr. P. JAYA RAM MD RE  
[Consultant Radiologist]

# Medinod - H

**IVARNA**  
Private Pte Ltd  
All rights are Reserved.

HIMS



CAPS NUM IHS 10-Sep-2022 12:39







## Department Of Laboratory

Date :

<b>Name</b> : Mrs. DANDABATHINA SIRISHA	<b>Age /Sex</b> : 30 Y(s)/Female
<b>Bill Date</b> : 10-Sep-2022 08:13 AM	<b>UMR No.</b> : UMR2212412
<b>Rept. Dt</b> : 10-Sep-2022 10:11 AM	<b>Bill No.</b> : BIL22018361
<b>Ref By</b> : Dr.GENERAL HEALTH CHECK UP	<b>Result No</b> : 0 / RES22019561

<u>Parameter</u>	<u>Result</u>	<u>Normal Values</u>
<b>CBC (COMPLETE BLOOD COUNT)</b>		
HAEMOGLOBIN	: 13.0 g/dl	11.5 - 16.0 g/dl
Total WBC Count	: 10,600 cells/cumm	4000 - 11000 cells/cumm
<b>DC COUNT</b>		
Neutrophils	: 70 %	50 - 70 %
Lymphocytes	: 25 %	15 - 40 %
Eosinophils	: 03 %	0 - 7 %
Monocytes	: 02 %	0 - 4 %
Basophils	: 00 %	0 - 1 %
RBC COUNT	:* 4.3 millions/cumm	4.5 - 6.5 millions/cumm
PLATELET COUNT	: 1.9 lakhscells/cumm	1.5 - 4.0 lakhscells/cumm
Blood Grouping & Rh Typing	: "O" POSITIVE	

\*\*\* End Of Report \*\*\*

Lab Tech.

Bio-Chemist

Lab In-Charge

Incharge Pathologist