

HEALTH CHECKUP REPORT

Patient Name: ANKITABEN PATEL
Age/Gender: 32/F
Reg. No: 389075
Package: MEDIWHEEL

DATE: 12/11/2022

COMPLAINTS (IF ANY):

- Asymptomatic

HISTORY OF HEALTH STATUS: No

PRESENT MEDICATIONS: No

HYPERSENSITIVITY TO ANY DRUG: No

PERSONAL HISTORY:

- | | | | | | |
|---------------|---|----------|-----------------------------|----|-----|
| - Bowel | : | Regular | Diet | : | Veg |
| - Micturition | : | Normal | Habits | : | No |
| - Sleep | : | Adequate | Physical Activity/Exercise: | NO | |
| - Appetite | : | Adequate | | | |

HISTORY OF ILLNESS (WITH PAST MEDICATIONS):

- LMP :- 10/10/2022

FAMILY HISTORY:

- Father , mother :- hypertension , DM

VITAL SIGNS:

- | | | | |
|------------|---------|---------|------------|
| - Height : | 154 cms | Pulse : | 100/min. |
| - Weight : | 57 Kgs | B.P.: | 130/80mmHg |



CIMS Hospital Private Limited

Post No 07, 2021, Site Panchmurt Bungalows Near Shakun Mall, Off Science City Road, Sola, Ahmedabad, Gujarat 380060

1800 309 9999 CIN No. U85110GJ2001PTC039962

At CIMS...We Care

PHYSICIAN CONSULTATION:

1) Clinical Impression

- Mild aenemia
- Polycystic ovaries

2) Recommendations

- Regular Exercise
- Iron restriction in diet
- Healthy life style

(Dr. Rashmi chovatia)

OPHTHALMO CONSULTATION:

	RE	LE
Best corrected visual acuity	6/6	6/6 (Dr. Jignesh Shah)

DENTAL CONSULTATION:

Adv:

- Cleaning

(Dr. Parvin Chandarana)

GYNEC CONSULTATION: done (Dr. devang patel)

Please take regular medicine as prescribed by the Doctor. (If given)



Dr. Devang Patel

MD (Obst. & Gynec) Gold Medalist
FNB (High Risk Pregnancy & Perinatology)
First FNB (HRP&P) of Gujarat
Feto-Maternal Medicine Specialist
Mobile: +91-98256 88956
Email : devang.patel@cimshospital.org

Mrs Ankita Patel
Age 34/4

11/11/2022

FOR OPD CONSULTATION ONLY

Dr. Umang

M/H → PAMN by amp - 10/10/2022

Allyg / NIL
B5

Md/h → NIL
Syn/h → NIL

D/E - P/A (S/T)

Adus


→ sup with repts

(A)
Ankita Patel

Reg. No : CIMS/A/2022/389075	VisitNo : HC/121122/23 [HCV]
Patient Name : Miss ANKITABEN RAVINDRABHAI PATEL	Age(Y-M-D)/Sex : 32 Y 0 M 10 D. / Female
Referring Doctor : Dr. CIMS DOCTOR	Doctor :
Ward/Room :	Bed :

ORD/121122/410 Lab No : 2022167579 LSN : 933358 (Whole Blood) Sample Quality : Normal
 Collection Time : 12/11/2022 9:40:39 Arrival : 12/11/2022 10:17:40 Validation Time : 12/11/2022 2:12:29PM

	Result	Unit	Reference Range
CBC With ESR			
TOTAL COUNT			
Hemoglobin <i>(SLS Hemoglobin Detection method)</i>	11.2	g/dl	12.5 - 16.0 g/dl
Total RBC Count <i>(Hydro Dynamic Focusing Method)</i>	5.49	mill/Cmm	4.2 - 5.4 mill/Cmm
HCT <i>(Hydro Dynamic Focusing Method)</i>	36.6	%	37 - 47 %
Total WBC Count <i>(Flow Cytometry)</i>	6650	/Cmm	4000 - 10500 /Cmm
Platelet Count <i>(Hydro Dynamic Focusing Method)</i>	228000	/Cmm	150000 - 450000 /Cmm
DIFFERENTIAL COUNT (by Flow Cytometry)			
Polymorphs	60	%	40 - 70 %
Lymphocytes	36	%	22 - 45 %
Eosinophils	01	%	01 - 04 %
Monocytes	03	%	01 - 06 %
Basophils	00	%	00 - 01 %
Immature Granulocytes	00	%	0 - 2 %
Smear Study	RBCs shows Anisocytosis(+), Microcytosis(+), Hypochromia(+). Platelets are adequate in number. Malarial Parasites are not seen. No Premature cells are seen.		
BLOOD INDICES (by Calculated Method)			
M.C.V	66.7	fl	78 - 100 fl
M.C.H	20.4	pg	27 - 31 pg
M.C.H.C.	30.6	gm/dl	32 - 36 gm/dl
RDW-CV	16.7	%	11.5 - 14.0 %
ESR (Red Cell Aggregation)			
After One Hour	35	mm	0 - 12 mm
Blood Group Rh			
ABO	"O"		


Dr. Kazumi Gondalia
 M.D. (Path)
 Consultant Pathologist
 Reg. No. : G-21729

Dr. Manisha Shah
 MD (Path & Bact)
 Consultant Pathologist
 Reg. No. : G-15496

Dr. Jitendra Nayak
 MD (Path)
 Consultant Pathologist
 Reg. No. : G-14786



CIMS Hospital Private Limited


Plot No 67/1, Opp. Panchamrut Bungalows, Near Shukan Mall, Off Science City Road, Sola, Ahmedabad - 380060, Gujarat

Reg. No : CIMS/A/2022/389075	VisitNo : HC/121122/23 [HCV]
Patient Name : Miss ANKITABEN RAVINDRABHAI PATEL	Age(Y-M-D)/Sex : 32 Y 0 M 10 D. / Female
Referring Doctor : Dr. CIMS DOCTOR	Doctor :
Ward/Room :	Bed :

ORD/121122/410 Lab No : 2022167579 LSN : 933358 (Whole Blood) Sample Quality : Normal
 Collection Time : 12/11/2022 9:40:39 Arrival : 12/11/2022 10:17:40 Validation Time : 12/11/2022 2:12:30PM

Rh	POSITIVE		
HbA1c (Glycosylated Haemoglobin)			
TEST			
HbA1c (Glyoco Hb)	5.81	%	4.8-5.9% Normal
(Immuno Turbidimetric)			5.9-7.0% Good diabetic control
			7.0-10.0% Fair diabetic control
			>10.0% Poor diabetic control
Mean Plasma Glucose	129.6	mg/dL	80 - 140 mg/dL

*** END OF REPORT ***


Dr. Kazumi Gondalia
 M.D. (Path)
 Consultant Pathologist
 Reg. No. : G-21729

Dr. Manisha Shah
 MD (Path & Bact)
 Consultant Pathologist
 Reg. No. : G-15496

Dr. Jitendra Nayak
 MD (Path)
 Consultant Pathologist
 Reg. No. : G-14786



CIMS Hospital Private Limited

Plot No 67/1, Opp. Panchamrut Bungalows, Near Shukan Mall, Off Science City Road, Sola, Ahmedabad - 380060, Gujarat

Reg. No : CIMS/A/2022/389075	VisitNo : HC/121122/23 [HCV]
Patient Name : Miss ANKITABEN RAVINDRABHAI PATEL	Age(Y-M-D)/Sex : 32 Y 0 M 10 D. / Female
Referring Doctor : Dr. CIMS DOCTOR	Doctor :
Ward/Room :	Bed :

ORD/121122/410 Lab No : 2022167580 LSN : 933358 (SERUM) Sample Quality : Normal
 Collection Time : 12/11/2022 9:40:39 Arrival : 12/11/2022 10:17:40 Validation Time : 12/11/2022 1:22:26PM

	Result	Unit	Reference Range
Creatinine <i>(Buffered Jaffe Reaction Kinetic Compensated)</i>	0.56	mg/dL	0.5 - 0.9 mg/dL
Estimated GFR	122.95	mL/min/1.73m ²	71 - 121 mL/min/1.73m ²
Fasting Glucose <i>(Hexokinase)</i>	79.5	mg/dL	70 - 100 mg/dL
Thyroid Function Test			
TOTAL T3 (T3) * <i>(Electrochemiluminescence Assay)</i>	1.26	ng/ml	0.846 - 2.02 ng/ml
TOTAL T4 (T4) * <i>(Electrochemiluminescence Assay)</i>	7.34	µgm/dl	5.13 - 14.06 µgm/dl
TSH <i>(Electrochemiluminescence Assay)</i>	2.47	µIU/ml	0.27- 4.20 µIU/ml
Uric Acid <i>(Uricase Colorimetric Enzymatic)</i>	4.59	mg/dL	2.4 - 5.7 mg/dL

*** END OF REPORT ***

Dr. Manisha Shah
MD (Path & Bact)
Consultant Pathologist
Reg. No. : G-15496

Dr. Jitendra Nayak
MD (Path)
Consultant Pathologist
Reg. No. : G-14786


Dr. Kazumi Gondalia
M.D. (Path)
Consultant Pathologist
Reg. No. : G-21729



CIMS Hospital Private Limited


Plot No 67/1, Opp. Panchamrut Bungalows, Near Shukan Mall, Off Science City Road, Sola, Ahmedabad - 380060, Gujarat

Reg. No : CIMS/A/2022/389075	VisitNo : HC/121122/23 [HCV]
Patient Name : Miss ANKITABEN RAVINDRABHAI PATEL	Age(Y-M-D)/Sex : 32 Y 0 M 10 D. / Female
Referring Doctor : Dr. CIMS DOCTOR	Doctor :
Ward/Room :	Bed :

ORD/121122/410 Lab No : 2022167580 LSN : 933358 (SERUM) Sample Quality : Normal
 Collection Time : 12/11/2022 9:40:39 Arrival : 12/11/2022 10:17:40 Validation Time : 12/11/2022 1:22:27PM

Liver Function Test

	<u>Result</u>	<u>Unit</u>	<u>Reference Range</u>
Alkaline Phosphatase <i>(PNPP, AMP Buffer Method, Colorimetric)</i>	64.6	U/L	35 - 104 U/L
Billirubin			
Total Billirubin <i>(Diazospecial Iazonium Iron with Blank)</i>	0.34	mg/dL	0.0 - 1.0 mg/dL
Direct Billirubin <i>(Diazo, (Evelyn Malloy) with Blank)</i>	0.11	mg/dL	0.0 - 0.2 mg/dL
Indirect Billirubin <i>(Calculated from Total and Direct Billirubin)</i>	0.23	mg/dL	0.0 - 0.8 mg/dL
SGPT (ALT) <i>(IFCC without pyridoxal phosphate)</i>	16.6	U/L	0 - 33 U/L
SGOT (AST) <i>(IFCC without pyridoxal 5 phosphate)</i>	16.9	U/L	0 - 32 U/L
Total Protein			
Total Proteins <i>(Biuret Method)</i>	7.51	gm/dl	6.4 - 8.3 gm/dl
Albumin <i>(Bromocresol Green Colorimetric)</i>	4.89	gm/dl	3.97 - 4.95 gm/dl
Globulin	2.62	gm/dl	2.2 - 3.5 gm/dl
A/G Ratio	1.87		0.9 - 2.1


Dr. Kazumi Gondalia
 M.D. (Path)
 Consultant Pathologist
 Reg. No. : G-21729

Dr. Manisha Shah
 MD (Path & Bact)
 Consultant Pathologist
 Reg. No. : G-15496

Dr. Jitendra Nayak
 MD (Path)
 Consultant Pathologist
 Reg. No. : G-14786



CIMS Hospital Private Limited

Plot No 67/1, Opp. Panchamrut Bungalows, Near Shukan Mall, Off Science City Road, Sola, Ahmedabad - 380060, Gujarat

Reg. No : CIMS/A/2022/389075	VisitNo : HC/121122/23 [HCV]
Patient Name : Miss ANKITABEN RAVINDRABHAI PATEL	Age(Y-M-D)/Sex : 32 Y 0 M 10 D. / Female
Referring Doctor : Dr. CIMS DOCTOR	Doctor :
Ward/Room :	Bed :

ORD/121122/410 Lab No : 2022167580 LSN : 933358 (SERUM) Sample Quality : Normal
 Collection : 12/11/2022 9:40:39AM Arrival: 12/11/2022 10:19:21 Validation Time 12/11/2022 13:14:51

<u>Lipid Profile (With Direct LDL)</u>	<u>Result</u>	<u>Unit</u>	<u>Reference Range</u>
Type of Sample	: Fasting	.	
Cholesterol (Enzymatic/Colorimetric, Cholesterol Oxidas, Esterase, Peroxidase Gen.2)	: 193.8	mg/dL	Less than 160 mg/dl Excellent Less than 200 mg/dl Desirable 200-239 mg/dl Borderline High 240 mg/dl & over High
Triglyceride (Enzymetic Colorimetric without Glycerol Blank without Serum Blank)	: 94.2	mg/dL	Less than 150 mg/dl Normal 150 - 199 mg/dl Borderline High 200-499 mg/dl High 500 mg/dl or greater Very High
HDL Cholesterol (Direct Mearuse Homogenous Technique Modified Enzymatic Colorimetric Gen. 3)	: 41	mg/dL	Less than 40 mg/dl Low 60 mg/dl or above Excellent
L D L Cholesterol (DIRECT) (Homogenous Enzymatic colorimetric Assay)	: 139.6	mg/dL	Less than 80 mg/dl Excellent Less than 100 mg/dl Optimal 100 - 129 mg/dl Near or above optimal 130 - 159 mg/dl Borderline High 160 - 189 mg/dl High 190 mg/dl & above Very High
VDL Cholesterol (Calculated)	: 18.84	mg/dL	15 - 30 mg%
Cholesterol/HDL Ratio (Calculated)	: 4.73		Normal upto 4.5
LDL/HDL Ratio (Calculated)	: 3.4		Less than 3.5

Remarks :


Dr. Kazumi Gondalia
M.D. (Path)
Consultant Pathologist
Reg. No. : G-21729

Dr. Manisha Shah
 MD (Path & Bact)
 Consultant Pathologist
 Reg. No. : G-15496

Dr. Jitendra Nayak
 MD (Path)
 Consultant Pathologist
 Reg. No. : G-14786




Print By: namrataparekh Print Date/Time: 12/11/2022 2:23:35PM NABH Page No. 002

CIMS Hospital Private Limited

Reg. No : CIMS/A/2022/389075	VisitNo : HC/121122/23 [HCV]
Patient Name : Miss ANKITABEN RAVINDRABHAI PATEL	Age(Y-M-D)/Sex : 32 Y 0 M 10 D. / Female
Referring Doctor : Dr. CIMS DOCTOR	Doctor :
Ward/Room :	Bed :

ORD/121122/410 Lab No : 2022167581 LSN : 933358 (Urine) Sample Quality : Normal
 Collection Time : 12/11/2022 9:40:39 Arrival : 12/11/2022 10:17:40 Validation Time : 12/11/2022 1:34:17PM

	Result	Unit	Reference Range
Urine R & M			
PHYSICAL EXAMINATION			
Quantity	20 cc	.	.
Colour	Pale Yellow	.	.
Transperancy	Slight Turbid	.	.
Reaction (QDS-10 Strip)	7.0	.	.
Sp. Gravity (QDS-10 Strip)	1.010	.	1.005 - 1.035 .
CHEMICAL EXAMINATION			
U. Albumin (QDS-10 Strip/Manual)	Nil	.	.
U. Glucose (QDS-10 Strip/Manual)	Nil	.	.
U. Acetone (QDS-10 Strip/Manual)	Absent	.	.
BS/BP (QDS-10 Strip/Manual)	Absent	.	.
MICROSCOPIC EXAMINATION			
Pus Cell	8-10	/H.P.F.	/H.P.F.
Red Blood Cell	Nil	/H.P.F.	/H.P.F.
Epithelial Cell	20-25	/H.P.F.	/H.P.F.
Cast	Not Seen	.	.
Crystals	Not Seen	.	.
Amorphous	Absent	.	.
Monilia	Absent	.	.
*** END OF REPORT ***			


Dr. Kazumi Gondalia
M.D. (Path)
Consultant Pathologist
Reg. No. : G-21729

Dr. Manisha Shah
 MD (Path & Bact)
 Consultant Pathologist
 Reg. No. : G-15496

Dr. Jitendra Nayak
 MD (Path)
 Consultant Pathologist
 Reg. No. : G-14786



CIMS Hospital Private Limited

Plot No 67/1, Opp. Panchamrut Bungalows, Near Shukan Mall, Off Science City Road, Sola, Ahmedabad - 380060, Gujarat

Name : Miss ANKITABEN
 RAVINDRABHAI PATEL
 Reg No : CIMS/A/2022/38907
 DoB /Sex: 02/11/1990 / Female

Dt : 12/11/2022

ECHO Report**Patient Details**

Patient ID 321060
Name Mrs. ANKITABEN RAVINDRABHAI PATEL
Age 32 Years
Gender Male
Blood Group
Referral Doctor

ECHO Identification Detail

Doctor Incharge Dr. VIPUL KAPOOR
Clinical Status Of Patient
ECHO Code RP
Finding Description

1. Normal cardiac chambers dimensions.
2. Normal LV systolic function, LVEF: 60%.
3. No RWMA.
4. Normal LV diastolic function.
6. All cardiac valves are structurally normal.
7. Trivial MR, Mild TR, Trivial PR, No AR.
8. No PAH, RVSP: 28 mmHg.
9. Normal RV systolic function.
10. No clot/vegetation/pericardial effusion.

Dr. VIPUL KAPOOR

**CIMS Hospital Private Limited**

Plot No 67/1, Opposite Panchmrut Bunglows Near Shakun Mall, Off Science City Road, Sola, Ahmedabad, Gujarat 380060

© 1800 309 9999 CIN No. U85110GJ2001PTC039962

12/11/2022

12-11-2022 10:22:49
ID: 894

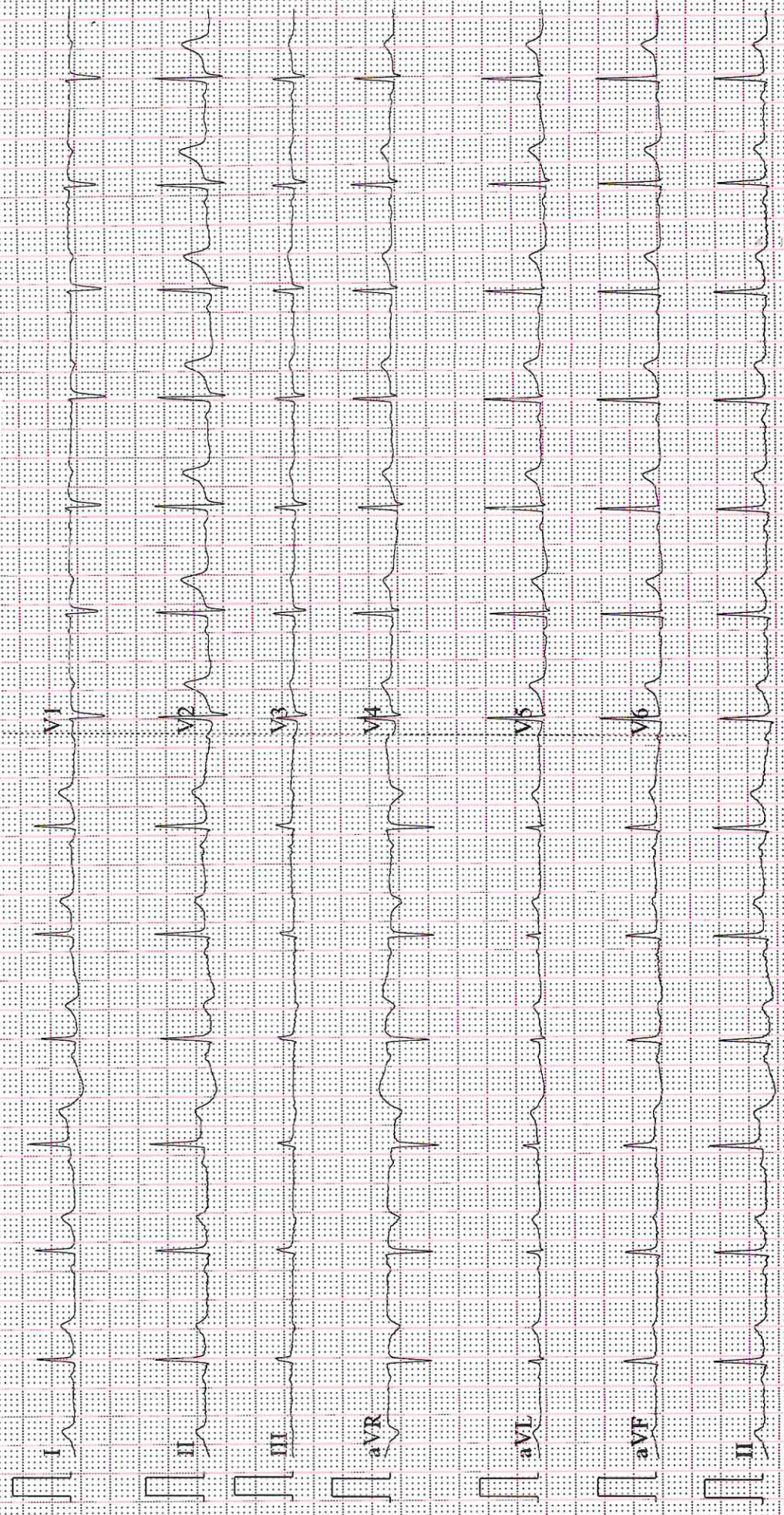
Years

HR : 81 bpm
P : 83 ms
PR : 137 ms
QRS : 75 ms
QT/QTc : 338/393 ms
P/QRS/T : 38/51/25 °
RV5/SVI : 0.775/0.521 mV

Diagnosis Information:

Name : Miss ANKITABEN
RAVINDRABHAI PATEL
Reg No : CIMS/A/2022/389075
DoB /Sex : 02/11/1990 / Female

NSR / 60bpm



Patient's Name : ANKITABEN R PATEL	Age, Sex : 32Y/F
Reg. No. (IP/OP): HC-389075	Date : 12/11/2022
Referred By Dr. : CIMS	

Plain Skiagram of Chest PA Standing View:
(Serial No-6827)

Both lung fields appear normal.

No evidence of collapse or consolidation in either lung field.
No evidence of pleural effusion or pneumothorax is seen on either side.

Mediastinal shadow appears normal.

Heart size and aorta appear normal.

Domes of diaphragm appear normal.

Bones under view appears normal.

Kindly correlate clinically.



DR KIRTAN SHAH DR DEEPA SHAH DR UMA MEHTA DR NIMISH SHARMA DR RAVINA CHAUHAN DR YASH PATEL DR SUNALI DESAI
M.D. RADIOLOG. M.D., D.M.R.E D.M.R.D. F.R.C.R D.M.R.D. (D.N.B.) M.D. RADIOLOG. M.D., D.N.B. MD, DNB, DM, FRCR
CONS. RADIOLOGIST CONS. RADIOLOGIST CONS. RADIOLOGIST CONS. RADIOLOGIST CONS. RADIOLOGIST CONS. RADIOLOGIST NEURORADIOLOGIST

Note: This is only a radiological impression and not the final diagnosis. All diagnostic modalities have their own limitations.
Therefore radiological modality report should be interpreted in correlation with clinical and pathological findings.

RADIOLOGY REPORTS ONLY



Patient's Name :ANKITABEN R PATEL	Age, Sex :32Y/F
Reg. No. (IP/OP):HC-389075	Date :12/11/2022
Referred By Dr. :CIMS	

USG OF ABDOMEN & PELVIS

LIVER: Liver is normal in size and echotexture. No evidence of focal SOL or dilatation of IHBR seen. Porta hepatitis appear normal.

GALLBLADDER: Gallbladder appeared normal. No calculus or mass lesion seen.

PANCREAS: Visualised pancreas appeared normal in size and echotexture. No focal lesion, mass or pancreatitis.

SPLEEN: Spleen appears normal in size and echotexture.

PARAAORTIC REGION: Aorta grossly appeared normal. No paraaortic lymphnodes seen.

KIDNEYS: Both kidneys appear normal in size, shape and in position.

Cortex and collecting system of both kidneys appeared normal.

No evidence of calculus or obstructive uropathy on either side.

Right kidney: 93x34mm. Left kidney: 100x49mm.

URINARY BLADDER: Bladder appeared normal. No calculus or mass lesion is seen.

UTERUS: Uterus appears normal in size and measures 84x35x45mm.

Uterus shows homogenous endometrial and myometrial echotexture.

Endometrial thickness appears normal and measures 10mm.

No fibroid or GS seen.

OVARIES: Both ovaries appear mildly enlarged in size and show multiple small peripherally arranged follicles.

No adnexal mass lesion seen on either side.

No evidence of free fluid or collection is seen in peritoneal spaces.

Normal small bowel peristalsis noted.

COMMENTS: Appearance suggests,

- Polycystic ovaries. (Adv: Hormonal evaluation).

Kindly correlate clinically.

DR KIRTAN SHAH DR DEEPA SHAH DR UMA MEHTA DR NIMISH SHARMA DR RAVINA CHAUHAN DR YASH PATEL DR SUNALI DESAI
M.D. RADIODIAG. M.D., D.M.R.E D.M.R.D. F.R.C.R D.M.R.D. (D.N.B.) M.D. RADIODIAG. M.D., D.N.B. MD, DNB, DM, FRCR
CONS. RADIOLOGIST CONS. RADIOLOGIST CONS. RADIOLOGIST CONS. RADIOLOGIST CONS. RADIOLOGIST CONS. RADIOLOGIST NEURORADIOLOGIST

Note: This is only a radiological impression and not the final diagnosis. All diagnostic modalities have their own limitations.
Therefore radiological modality report should be interpreted in correlation with clinical and pathological findings.



JCI (USA)

NABH

OUR ACCREDITATIONS

CIMS Hospital Private Limited

Plot No 67/1, Opp. Panchamrut Bunglows, Near Shukan Mall, Off Science City Road, Sola, Ahmedabad - 380060, Gujarat

© 1800 309 9999 CIN No. U85110GJ2001PTC039962