


MER- MEDICAL EXAMINATION REPORT

|  |                 |             |              |
|--|-----------------|-------------|--------------|
| Date of Examination  | 23/12/23        |             |              |
| NAME   | ADITYA KR KNARE |             |              |
| AGE  | 23              | Gender      | M Bmi - 29.1 |
| HEIGHT(cm)   | 176             | WEIGHT (kg) | 90           |
| B.P.   | 120/84          |             |              |
| ECG  | normal          |             |              |
| X Ray  | normal          |             |              |
| Vision Checkup   | normal          |             |              |
| Present Ailments   | nop             |             |              |
| Details of Past ailments (If Any)                                  | no              |             |              |
| Comments / Advice : She /He is Physically Fit                      | Medicinesy fit  |             |              |
| <p>child did not get the test because of his general decesses.</p> |                 |             |              |

  
 Signature with Stamp of Medical Examiner  
 Dr. Smita Rastogi  
 MBBS, DCP  
 Reg. No. 37370



Dear sir

You have been informed that ent opthal ,diet consultation facility is not available at our centre.

If you are ready then your test can be start.

*Shaw*






Download Date: 02/12/2018
 
 Issue Date: 18/03/2018

अदित्य कुमार खरे  
 Aditya Kumar Khare  
 जन्म तिथि/DOB: 18/02/1990  
 पुरुष/ MALE

**6798 9506 9083**  
 VID : 9113 7457 9240 3160

मेरा आधार, मेरी पहचान

*Khare*




पता:  
 संवापित: जयंती कुमार खरे, 645A/ 200, जानकी  
 विहार, मदीयाव रोड, जानकीपुरावम सेक्टर-आई,  
 लखनऊ, लखनऊ,  
 उत्तर प्रदेश - 226021

**Address:**  
 S/O: Jayanti Kumar Khare, 645A/ 200,  
 Jankivihar, madion road, Jankipuram  
 Sector-I, Lucknow, Lucknow,  
 Uttar Pradesh - 226021



**6798 9506 9083**  
 VID : 9113 7457 9240 3160

1947 | help@uidai.gov.in | www.uidai.gov.in



We don't wish to Undergo TMT test as it's taking  
too much of a Time.

Shree





# MODERN PATHOLOGY & DIAGNOSTIC CENTRE

DIAGNOSTIC CENTRE

Dr. R. P. Rastogi  
M.B.B.S., M.D. (Path & Bact)



CLINIC :  
1/4A, Vineet Khand, (Opp Jaipuria Management)  
Gomti Nagar, Lucknow - 226 010  
Ph.: 0522-4008184, 4308184 • 8112323230  
Mob.: 7618884441, 9450389932, 8177063877

|        |                          |     |           |
|--------|--------------------------|-----|-----------|
| Date   | : 23-Dec-2023            |     |           |
| Name   | : Mr. ADITYA KUMAR KHARE | Age | : 33 Yrs. |
| Ref.By | : APOLLO HEALTH          | Sex | : Male    |

|             |      |     |         |
|-------------|------|-----|---------|
| Haemoglobin | 14.0 | gm% | 14 - 17 |
|-------------|------|-----|---------|

|                       |      |             |            |
|-----------------------|------|-------------|------------|
| Total Leucocyte Count | 7900 | Cells/cumm. | 4000-11000 |
|-----------------------|------|-------------|------------|

|                                     |    |   |         |
|-------------------------------------|----|---|---------|
| <b>Differential Leucocyte Count</b> |    |   |         |
| Polymorphs                          | 53 | % | 45 - 70 |
| Lymphocytes                         | 42 | % | 20 - 45 |
| Eosinophils                         | 01 | % | 0 - 6   |
| Monocytes                           | 04 | % | 0 - 8   |
| Basophils                           | 00 | % | 0 - 1   |

|  |      |               |         |
|--|------|---------------|---------|
| <b>Erythrocyte Sedimentation Rate (Wintrobe)</b> |      |               |         |
| ESR  | 04   | mm in 1st Hr. | 0 - 9   |
| PCV  | 44.0 | cc%           | 40 - 52 |
| Corrected ESR                                    | 02   | mm in 1st Hr. | 0 - 9   |

|                |      |            |           |
|----------------|------|------------|-----------|
| Platelet Count | 1.83 | lakh/cumm. | 1.5 - 4.0 |
|----------------|------|------------|-----------|

|                 |      |             |              |
|-----------------|------|-------------|--------------|
| Red Cells Count | 4.58 | million/cmm | 3.90 to 5.80 |
|-----------------|------|-------------|--------------|

|                        |      |        |         |
|------------------------|------|--------|---------|
| <b>Absolute values</b> |      |        |         |
| MCV                    | 96.1 | fL     | 77 - 97 |
| MCH                    | 30.5 | pg     | 27 - 31 |
| MCHC                   | 31.7 | gm /dl | 31 - 34 |

Dr. Sanjay Rastogi  
M.B.B.S., D.C.C. (BARC)

Dr. Smith Rastogi  
M.B.B.S., DCP

Results, adhering to W.H.O. and International Federation of Clinical Chemists Quality Control Standards.

SAMPLE COLLECTION FACILITY AVAILABLE

Report needs clinicopathological correlation ♦ Not for Medico Legal Purpose

e-mail : mpdcgn@gmail.com ♦ For online reports - www.modernpath.in

♦ Please ask for your computerized bill ♦ Pay only the printed collection charges



# MODERN PATHOLOGY & DIAGNOSTIC CENTRE

**CLINIC :**  
1/4A, Vineet Khand, (Opp Jaipuria Management)  
Gomti Nagar, Lucknow - 226 010  
Ph.: 0522-4008184, 4308184 • 8112323230  
Mob.: 7618884441, 9450389932, 8177063877

**Dr. R. P. Rastogi**  
M.B.B.S., M.D. (Path & Bact)



|        |                                 |     |           |
|--------|---------------------------------|-----|-----------|
| Date   | : 23-Dec-2023                   |     |           |
| Name   | : <b>Mr. ADITYA KUMAR KHARE</b> | Age | : 33 Yrs. |
| Ref.By | : APOLLO HEALTH                 | Sex | : Male    |

## General Blood Picture

**RBCs** RBCs are Normocytic & Normochromic.  
No Normoblasts are seen.

**WBCs** TLC is within normal range.  
DLC shows normal counts.  
No immature cells of WBC seen.

**PLATELETS** Platelets are adequate in number and morphology.

**OTHERS** No haemoparasites are seen.

**IMPRESSION** Normal GBP

**Dr. Sanjay Rastogi**  
M.B.B.S., D.C.P., D.C.B.(BARC)

**Dr. Smita Rastogi**  
M.B.B.S., DCP

Results, adhering to W.H.O. and International Federation of Clinical Chemists Quality Control Standards.

SAMPLE COLLECTION FACILITY AVAILABLE

Report needs clinicopathological correlation ♦ Not for Medico Legal Purpose

e-mail : [mpdcgn@gmail.com](mailto:mpdcgn@gmail.com) ♦ For online reports - [www.modernpath.in](http://www.modernpath.in)

♦ Please ask for your computerized bill ♦ Pay only the printed collection charges



# MODERN PATHOLOGY & DIAGNOSTIC CENTRE

Dr. R. P. Rastogi  
M.B.B.S., M.D. (Path & Bact)



**CLINIC :**  
1/4A, Vineet Khand, (Opp Jaipuria Management)  
Gomti Nagar, Lucknow - 226 010  
Ph.: 0522-4008184, 4308184 • 8112323230  
Mob.: 7618884441, 9450389932, 8177063877

Date : 23-Dec-2023  
Name : **Mr. ADITYA KUMAR KHARE** Age : 33 Yrs.  
Ref.By : APOLLO HEALTH Sex : Male

Blood Group & Rh "AB" Positive

Urine Sugar (Fasting) NIL

Urine Sugar (PP) NIL

Serum Gamma G.T. 16 IU/L 11 - 50

Plasma Glucose - F 104 mg/dl 70 - 110  
GOD-POD Method

Plasma Glucose - PP 125 mg/dl 110 - 170  
GOD POD Method

### LFT T&D

|                    |           |      |              |
|--------------------|-----------|------|--------------|
| Total Bilirubin    | 0.40      | mg%  | 0.2 - 1.0    |
| Direct Bilirubin   | 0.28      | mg%  | 0.0 to 0.40  |
| Indirect Bilirubin | 0.12      | mg%  | 0.10 to 0.90 |
| S.G.P.T            | <b>56</b> | IU/L | 5 - 40       |
| S.G.O.T            | 40        | IU/L | 5 - 50       |
| ALP                | 76        | IU/L | 40 to 129    |

### KFT

|            |      |      |            |
|------------|------|------|------------|
| UREA       | 19.2 | mg % | 15 - 50    |
| CREATININE | 0.93 | mg % | 0.5 - 1.5  |
| URIC ACID  | 4.9  | mg % | 2 - 7      |
| CALCIUM    | 9.6  | mg % | 8.8 - 10.0 |

**Dr. Sanjay Rastogi**  
M.B.B.S., DCP, CRIAT (BARC)

**Dr. Smita Rastogi**  
Contd... M.B.B.S., DCP

Results, adhering to W.H.O. and International Federation of Clinical Chemists Quality Control Standards.

SAMPLE COLLECTION FACILITY AVAILABLE

Report needs clinicopathological correlation ♦ Not for Medico Legal Purpose

e-mail : [mpdcgn@gmail.com](mailto:mpdcgn@gmail.com) ♦ For online reports - [www.modernpath.in](http://www.modernpath.in)

♦ Please ask for your computerized bill ♦ Pay only the printed collection charges



# MODERN PATHOLOGY & DIAGNOSTIC CENTRE

**CLINIC :**  
1/4A, Vineet Khand, (Opp Jaipuria Management)  
Gomti Nagar, Lucknow - 226 010  
Ph.: 0522-4008184, 4308184 • 8112323230  
Mob.: 7618884441, 9450389932, 8177063877

**Dr. R. P. Rastogi**  
M.B.B.S., M.D. (Path & Bact)



|        |                                 |     |           |
|--------|---------------------------------|-----|-----------|
| Date   | : 23-Dec-2023                   |     |           |
| Name   | : <b>Mr. ADITYA KUMAR KHARE</b> | Age | : 33 Yrs. |
| Ref.By | : APOLLO HEALTH                 | Sex | : Male    |

## LIPID PROFILE

|                   |      |     |           |
|-------------------|------|-----|-----------|
| Triglycerids      | 151  | mg% | 70 - 190  |
| S. Cholestrol S.  | 224  | mg% | 130 - 230 |
| S. HDL Cholestrol | 45.8 | mg% | 35 - 75   |
| S. LDL Cholestrol | 148  | mg% | 75 - 150  |
| VLDL              | 30.2 | mg% | 0 - 34    |
| Chol / HDL factor | 4.89 |     |           |
| LDL / HDL Factor  | 3.23 |     |           |

### COMMENTS

- \* Triglycerides (TG) are the main dietary lipids. Cholesterol constitutes a small part of the dietary lipids, it is mostly synthesised in the liver. Both TG and Chol. are transported through the plasma by lipoproteins (Chylomicrons, VLDL, LDL, IDL, HDL).
- \* LDL is the major cholesterol particle in plasma and high levels are strongly implicated in the formation of atheroma. An increase in the LDL leads to hypercholesterolemia, and therefore a risk factor for IHD. LDL increases with age particularly in females. Oestrogen lowers LDL and raises HDL. Raised chol. in females is mostly due to disturbed thyroid function.
- \* Increase in VLDL leads to hyperglyceridaemia. Raised TGs are associated with increased risk of CHD. Very high TGs increase the risk of Pancreatitis. Cholesterol is often raised due to Diabetes, Renal disease, Diuretic or Beta-blocker therapy.

### TYPES OF HYPERLIPOPROTEINEMIAS

|   |  |
|---|--|
| TYPE 1: Normal cholesterol<br>TG greatly raised                         | TYPE 3: Cholesterol increased<br>TG increased  |
| TYPE 2a: Cholesterol increased<br>LDL increased<br>TG normal            | TYPE 4: Cholesterol normal /increased<br>VLDL increased<br>TG increased                |
| TYPE 2b Chol. increased<br>VLDL raised<br>TG increased<br>LDL increased | TYPE 5: Cholesterol increased<br>LDL reduced<br>VLDL increased<br>TG greatly increased |

**Dr. Sanjay Rastogi**  
M.B.B.S., DCP, CRIAT (BARC)

**Dr. Smita Rastogi**  
Contd... M.B.B.S., DCP

Results, adhering to W.H.O. and International Federation of Clinical Chemists Quality Control Standards.

SAMPLE COLLECTION FACILITY AVAILABLE

Report needs clinicopathological correlation ♦ Not for Medico Legal Purpose

e-mail : [mpdcgn@gmail.com](mailto:mpdcgn@gmail.com) ♦ For online reports - [www.modernpath.in](http://www.modernpath.in)

♦ Please ask for your computerized bill ♦ Pay only the printed collection charges





# MODERN PATHOLOGY & DIAGNOSTIC CENTRE

Dr. R. P. Rastogi  
M.B.B.S., M.D. (Path & Bact)



CLINIC :  
1/4A, Vineet Khand, (Opp Jaipuria Management)  
Gomti Nagar, Lucknow - 226 010  
Ph.: 0522-4008184, 4308184 • 8112323230  
Mob.: 7618884441, 9450389932, 8177063877

Date : 23-Dec-2023

Name : Mr. ADITYA KUMAR KHARE

Age : 33 Yrs.

Ref.By : APOLLO HEALTH

Sex : Male

## Urine Examination

### PHYSICAL

|                   |        |
|-------------------|--------|
| Colour            | Straw  |
| Turbidity         | Nil    |
| Deposit           | Nil    |
| Reaction          | Acidic |
| *Specific Gravity | 1.030  |

### CHEMICAL

|                |     |
|----------------|-----|
| * Protein      | Nil |
| Sugar          | Nil |
| *Bile Salts    | Nil |
| *Bile Pigments | Nil |
| Phosphate      | Nil |

### MICROSCOPIC

|                  |     |      |
|------------------|-----|------|
| Pus Cells        | Nil | /hpf |
| Epithelial Cells | 0-1 | /hpf |
| Red Blood Cells  | Nil | /hpf |
| Casts            | Nil |      |
| Crystals         | Nil |      |
| Others           | Nil |      |

Dr. Sanjay Rastogi  
M.B.B.S., DCP, CRIAT (BARC)

Dr. Smita Rastogi  
Contd... M.B.B.S., DCP

Results, adhering to W.H.O. and International Federation of Clinical Chemists Quality Control Standards.

SAMPLE COLLECTION FACILITY AVAILABLE

Report needs clinicopathological correlation ♦ Not for Medico Legal Purpose

e-mail : mpdcgn@gmail.com ♦ For online reports - [www.modernpath.in](http://www.modernpath.in)

♦ Please ask for your computerized bill ♦ Pay only the printed collection charges



# MODERN PATHOLOGY & DIAGNOSTIC CENTRE

**DIAGNOSTIC CENTRE**  
**CLINIC :**  
1/4A, Vineet Khand, (Opp Jaipuria Management)  
Gomti Nagar, Lucknow - 226 010  
Ph.: 0522-4008184, 4308184 • 8112323230  
Mob.: 7618884441, 9450389932, 8177063877

**Dr. R. P. Rastogi**  
M.B.B.S., M.D. (Path & Bact)



Date : 23-Dec-2023  
Name : **Mr. ADITYA KUMAR KHARE** Age : 33 Yrs.  
Ref.By : APOLLO HEALTH Sex : Male

### THYROID TEST

|                                   |      |         |              |
|-----------------------------------|------|---------|--------------|
| Tri-iodothyronine (T3)            | 1.40 | nmol/L  | 0.50 to 2.50 |
| Thyroxine (T4)                    | 7.60 | mcg/dL  | 5.0 to 12.5  |
| Thyroid Stimulating Hormone (TSH) | 3.47 | mIU/ ml | 0.3 to 6.0   |

### COMMENTS

- 1) Primary hyperthyroidism is accompanied by elevated Serum T3 and T4 values along with depressed TSH levels.
- 2) Primary Hypothyroidism is accompanied by depressed serum T3 and T4 values and elevated serum TSH levels.
- 3) Normal T4 levels accompanied by high T3 levels are seen in patients with T3 thyrotoxicosis.
- 4) Slightly elevated T3 levels may be found in pregnancy and estrogen therapy, while depressed levels maybe encountered in severe illness, malnutrition, renal failure and during therapy with drugs like propranolol and propylthiouracil.
- 5) Elevated TSH levels may also be indicative of TSH secreting Pituitary Tumour.

**Dr. Sanjay Rastogi**  
M.B.B.S., DCP, CRIAT (BARC)

**Dr. Smita Rastogi**  
Contd... M.B.B.S., DCP

Results, adhering to W.H.O. and International Federation of Clinical Chemists Quality Control Standards.

SAMPLE COLLECTION FACILITY AVAILABLE

Report needs clinicopathological correlation ♦ Not for Medico Legal Purpose

e-mail : mpdcgn@gmail.com ♦ For online reports - www.modernpath.in

♦ Please ask for your computerized bill ♦ Pay only the printed collection charges



# MODERN PATHOLOGY & DIAGNOSTIC CENTRE

DIAGNOSTIC CENTRE

Dr. R. P. Rastogi  
M.B.B.S., M.D. (Path & Bact)



CLINIC :  
1/4A, Vineet Khand, (Opp Jaipuria Management)  
Gomti Nagar, Lucknow - 226 010  
Ph.: 0522-4008184, 4308184 ☎ 8112323230  
Mob.: 7618884441, 9450389932, 8177063877

|                               |               |
|-------------------------------|---------------|
| Date : 23-Dec-2023            | Age : 33 Yrs. |
| Name : Mr. ADITYA KUMAR KHARE | Sex : Male    |
| Ref.By : APOLLO HEALTH        |               |

## Glycosylated Haemoglobin

| Glycosylated Haemoglobin    | 6.0           | % | 4.5 TO 6.0 |
|-----------------------------|---------------|---|------------|
| =====                       |               |   |            |
| INTERPRETATION AND COMMENTS |               |   |            |
| =====                       |               |   |            |
| NON DIABETIC :              | 4.5 to 6.0    | % |            |
| GOOD CONTROL:               | 6.0 to 7.0    |   |            |
| FAIR CONTROLLED             | 7.0 AND 8.0   |   |            |
| UNCONTROLLED                | 8.0 AND ABOVE |   |            |

Glycosylated haemoglobin is the adducted glucose in the haemoglobin of the red blood cells, this adduction is stable for the life time of the RBC (i.e 120 days). There fore the measure of glycosylated haemoglobin reflects the average blood glucose concentration over the preseding several weeks. The sudden change in blood glucose level would not effect the glycosylated haemoglobin level ,which serves as a better marker of long term metabolic control and the efficacy of therapy.

Dr. Sanjay Rastogi  
M.B.B.S., DCP, CRP (BARC)

Dr. Smita Rastogi  
M.B.B.S., DCP

Results, adhering to W.H.O. and International Federation of Clinical Chemists Quality Control Standards.

SAMPLE COLLECTION FACILITY AVAILABLE

Report needs clinicopathological correlation ♦ Not for Medico Legal Purpose

e-mail : mpdcgn@gmail.com ♦ For online reports - [www.modernpath.in](http://www.modernpath.in)

♦ Please ask for your computerized bill ♦ Pay only the printed collection charges



# MODERN PATHOLOGY & DIAGNOSTIC CENTRE

**DIAGNOSTIC CENTRE**  
**CLINIC :**  
1/4A, Vineet Khand, (Opp Jaipuria Management)  
Gomti Nagar, Lucknow - 226 010  
Ph.: 0522-4008184, 4308184 • 8112323230  
Mob.: 7618884441, 9450389932, 8177063877

Dr. R. P. Rastogi  
M.B.B.S., M.D. (Path & Bact)



|  |                  |                      |
|--|------------------|----------------------|
| TEST REQUEST ID :012312230030                      | SAMPLE DATE      | :23/Dec/2023 10:14AM |
| NAME :Mr. ADITYA KUMAR KHARE                       | SAMPLE REC. DATE | :23/Dec/2023 10:14AM |
| AGE/SEX :33 YRS/MALE                               | REPORTED DATE    | :23/Dec/2023 12:15PM |
| REFERRED BY : Apollo Health and Lifestyle Limited, | BARCODE NO       | :01230030            |

## USG WHOLE ABDOMEN-MALE

**Liver:** is mildly enlarged in size (155 mm). Parenchymal echogenicity is increased. No focal echovariant lesion is seen. Intrahepatic biliary radicles are not dilated.

**Gall Bladder:** is well distended. Lumen is anechoic. Wall is of normal thickness.

**CBD:** is normal in diameter. Portal vein is normal in diameter.

**Pancreas:** is normal in size, shape and echotexture. No focal echovariant lesion is seen. Pancreatic duct is not dilated.

**Spleen:** is normal in size (107 mm), shape and echotexture. No focal echovariant lesion is seen. Splenic vein is normal.

**Both Kidneys:** are normal in size (RK- 96 x 39 mm & LK -99 x 46 mm), shape, position and excursion. Parenchymal echogenicity and echotexture is normal with maintained corticomedullary differentiation. No mass, cyst or calculi is seen. Pelvicalyceal systems are not dilated. Ureters are not dilated.

**Urinary bladder:** is well distended. Lumen is anechoic. Wall is of normal thickness. No mass or calculus is seen.

**Prostate:** is normal in size (38 x 22 x 21 mms, wt = 9.6 gms), shape and echotexture. No focal echovariant lesion is seen. Prostatic capsule appears to be intact. Median lobe is not projecting in UB lumen. Both seminal vesicles appear normal.  
Both iliac fossae are clear. No obvious bowel pathology is noted.  
There is no free fluid in peritoneal cavity.

**OPINION:** MILD HEPATOMEGALY WITH GRADE-III FATTY LIVER

\*\*\* End Of Report \*\*\*

Dr. Sanjay Rastogi  
M.B.B.S., DCP, CRIAT (BARC)

Dr. Smita Rastogi  
M.B.B.S., DCP

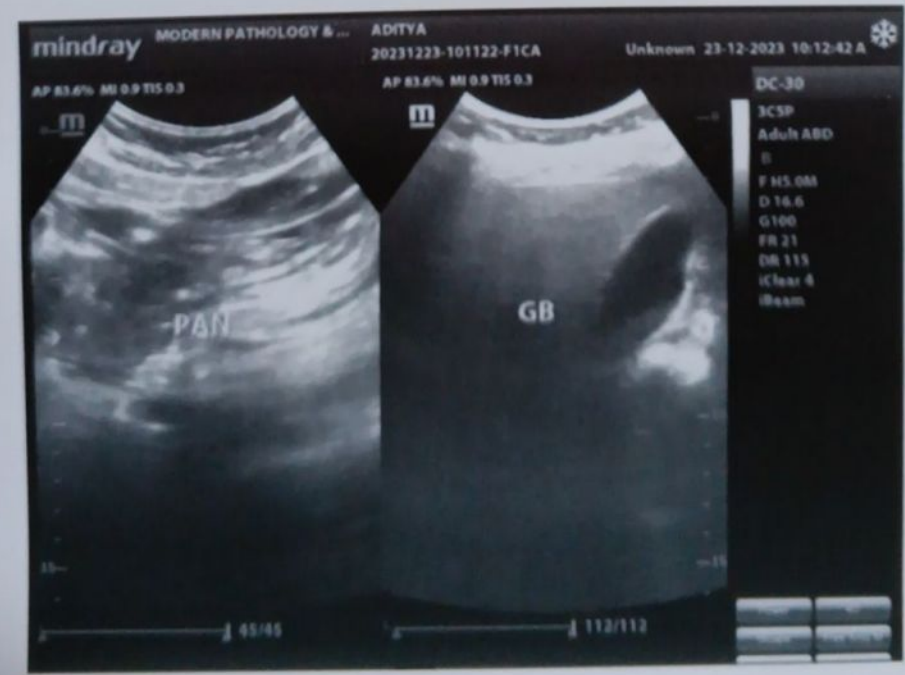
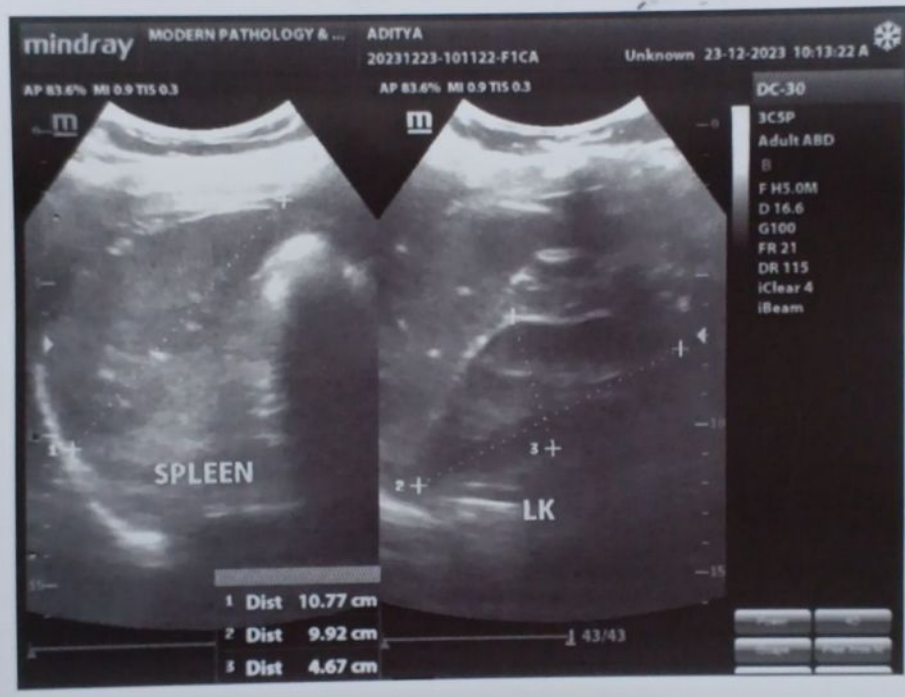
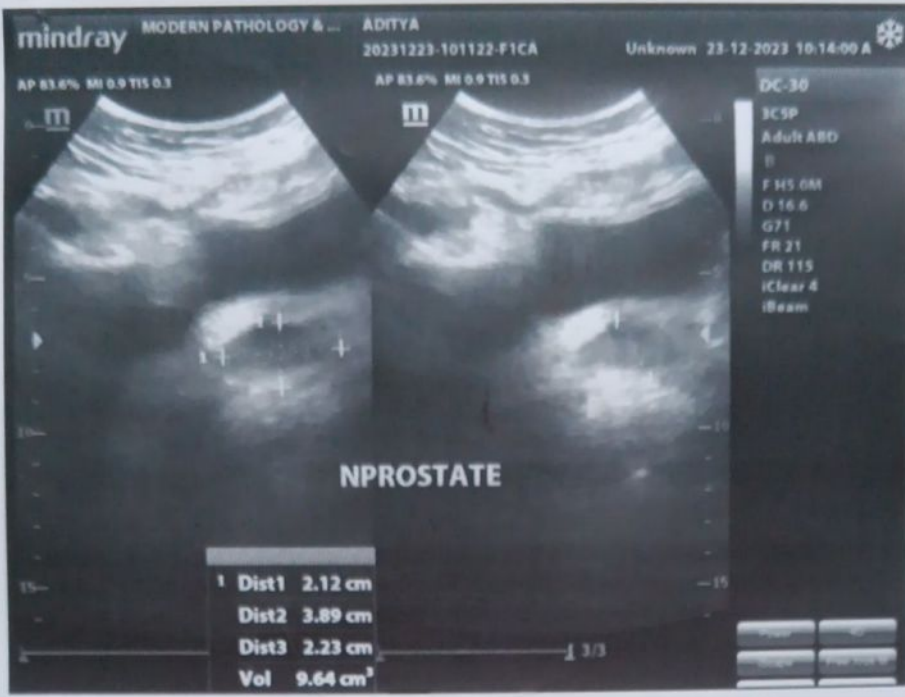
Results, adhering to W.H.O. and International Federation of Clinical Chemists Quality Control Standards.

SAMPLE COLLECTION FACILITY AVAILABLE

Report needs clinicopathological correlation • Not for Medico Legal Purpose

e-mail : mpdcgn@gmail.com • Reports - www.modernpath.in

Checked By: Ashish Singh  
Please ask for your computerized bill • Pay only the printed collection charges





# MODERN PATHOLOGY & DIAGNOSTIC CENTRE

Dr. R. P. Rastogi  
M.B.B.S., M.D. (Path & Bact)



**CLINIC :**

1/4A, Vineet Khand, (Opp Jaipuria Management)  
Gomti Nagar, Lucknow - 226 010  
Ph.: 0522-4008184, 4308184 • 8112323230  
Mob.: 7618884441, 9450389932, 8177063877



|  |                  |                      |
|--|------------------|----------------------|
| TEST REQUEST ID :012312230030                      | SAMPLE DATE      | :23/Dec/2023 10:14AM |
| NAME :Mr. ADITYA KUMAR KHARE                       | SAMPLE REC. DATE | :23/Dec/2023 10:14AM |
| AGE/SEX :33 YRS/MALE                               | REPORTED DATE    | :23/Dec/2023 12:34PM |
| REFERRED BY : Apollo Health and Lifestyle Limited, | BARCODE NO       | :01230030            |

### XRAY CHEST PA

- Trachea is central in position.
- Bilateral lung fields are normally aerated.
- Both hilar shadows are normal.
- Both C.P. angles are clear.
- Cardiac shadow is within normal limits.
- Bony cage appears normal.

### OPINION: NORMAL STUDY.

Please correlate clinically.

\*\*\* End Of Report \*\*\*

**Dr. Sanjay Rastogi**  
M.B.B.S., DCP, CRIAT (BARC)

**DR. PANKAJ UPADHYAYA**

**Dr. Smita Rastogi**  
M.B.B.S., DCP

Results, adhering to W.H.O. and International Federation of Clinical Chemists Quality Control Standards.

Report needs clinicopathological correlation ♦ Not for Medico Legal Purpose



# MODERN PATHOLOGY & DIAGNOSTIC CENTRE

DIAGNOSTIC CENTRE

Dr. R. P. Rastogi  
M.B.B.S., M.D. (Path & Bact)



**CLINIC :**

1/4A, Vineet Khand, (Opp Jaipuria Management)  
Gomti Nagar, Lucknow - 226 010  
Ph.: 0522-4008184, 4308184 • 8112323230  
Mob.: 7618884441, 9450389932, 8177063877

Patient name: Mr Aditya Kumar Khare  
Ref By. Apollo Health

Age/Sex 33/M  
23/12/2023

### E.C.G. REPORT

|                     |   |                |
|---------------------|---|----------------|
| 1. Rhythm           | : | Sinus, Regular |
| 2. Atrial Rate      | : | 82/mt          |
| 3. Ventricular Rate | : | 82/mt          |
| 4. P – Wave         | : | Normal         |
| 5. P R Interval     | : | Normal         |
| 6. Q R S            | : |                |
| Axis                | : | Normal         |
| R/S Ratio           | : | Normal         |
| Configuration       | : | Normal         |
| 7. Q T c Interval   | : | Normal         |
| 8. S-T Segment      | : | Normal         |
| 9. T-Wave           | : | Normal         |

### FINAL IMPRESSION

**E.C.G. is within normal limits.**

*Dr. Sanjay Rastogi*  
Signature of Doctor  
MD  
Reg No. 44550

**Dr. Sanjay Rastogi**  
M.B.B.S., DCP, CRIAT (BARC)

**Dr. Smita Rastogi**  
M.B.B.S., DCP

Results, adhering to W.H.O. and International Federation of Clinical Chemists Quality Control Standards.

SAMPLE COLLECTION FACILITY AVAILABLE

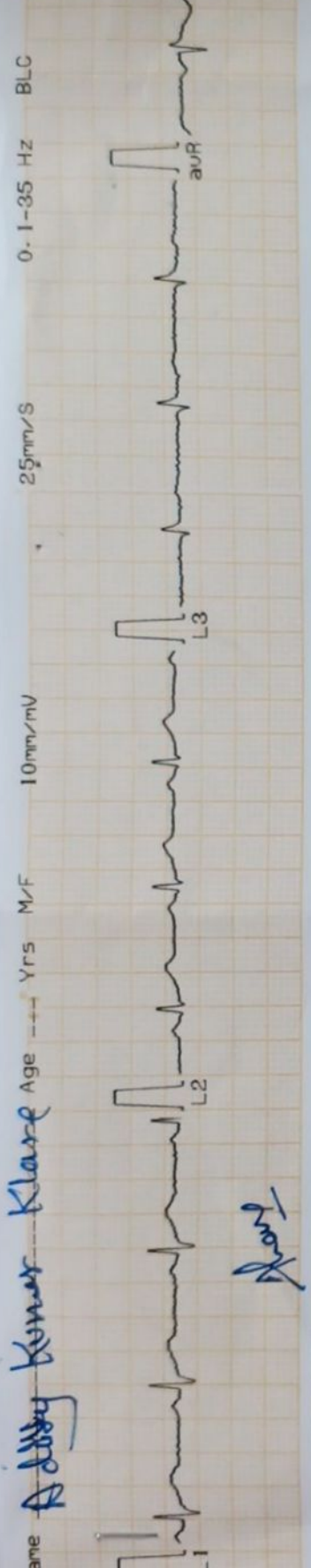
Report needs clinicopathological correlation ♦ Not for Medico Legal Purpose

e-mail : mpdcgn@gmail.com ♦ For online reports - www.modernpath.in

♦ Please ask for your computerized bill ♦ Pay only the printed collection charges

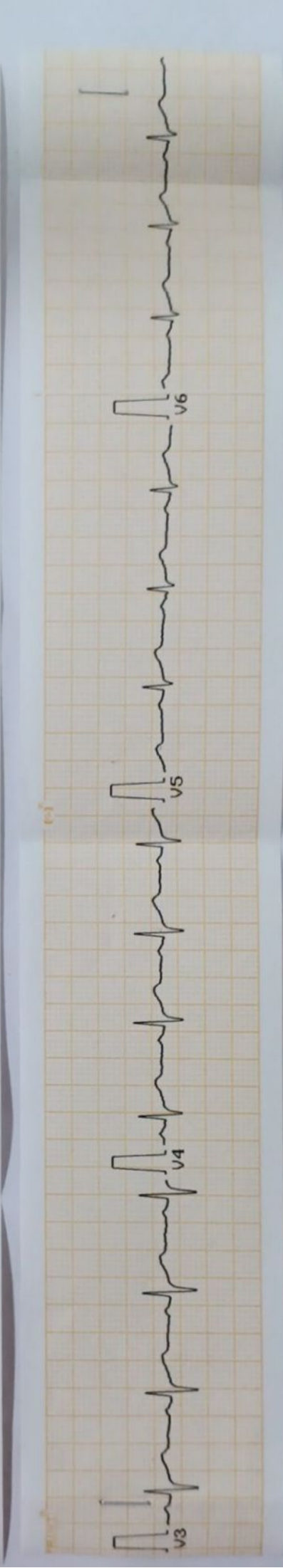
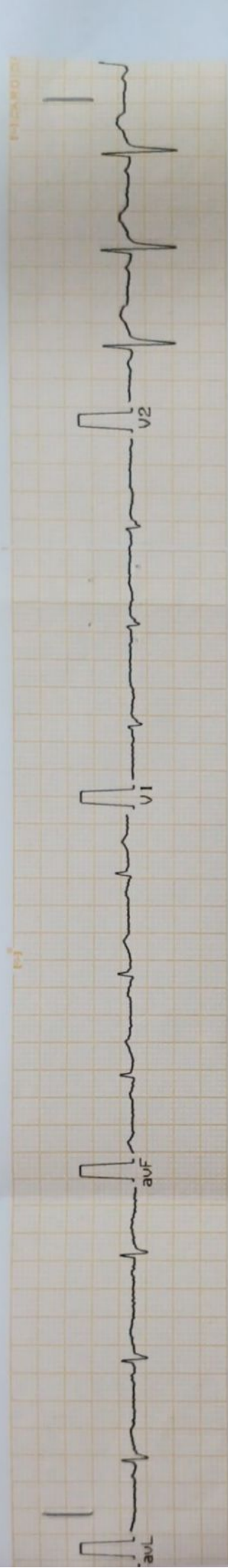
Name Adity Kumar Klasse Age --- Yrs M/F --- 25mm/S 10mm/mV 0.1-35 Hz BLC

ECARDIOPAPER



*Handwritten signature*

Dr. --- Claris tuMed ECG50-1CH



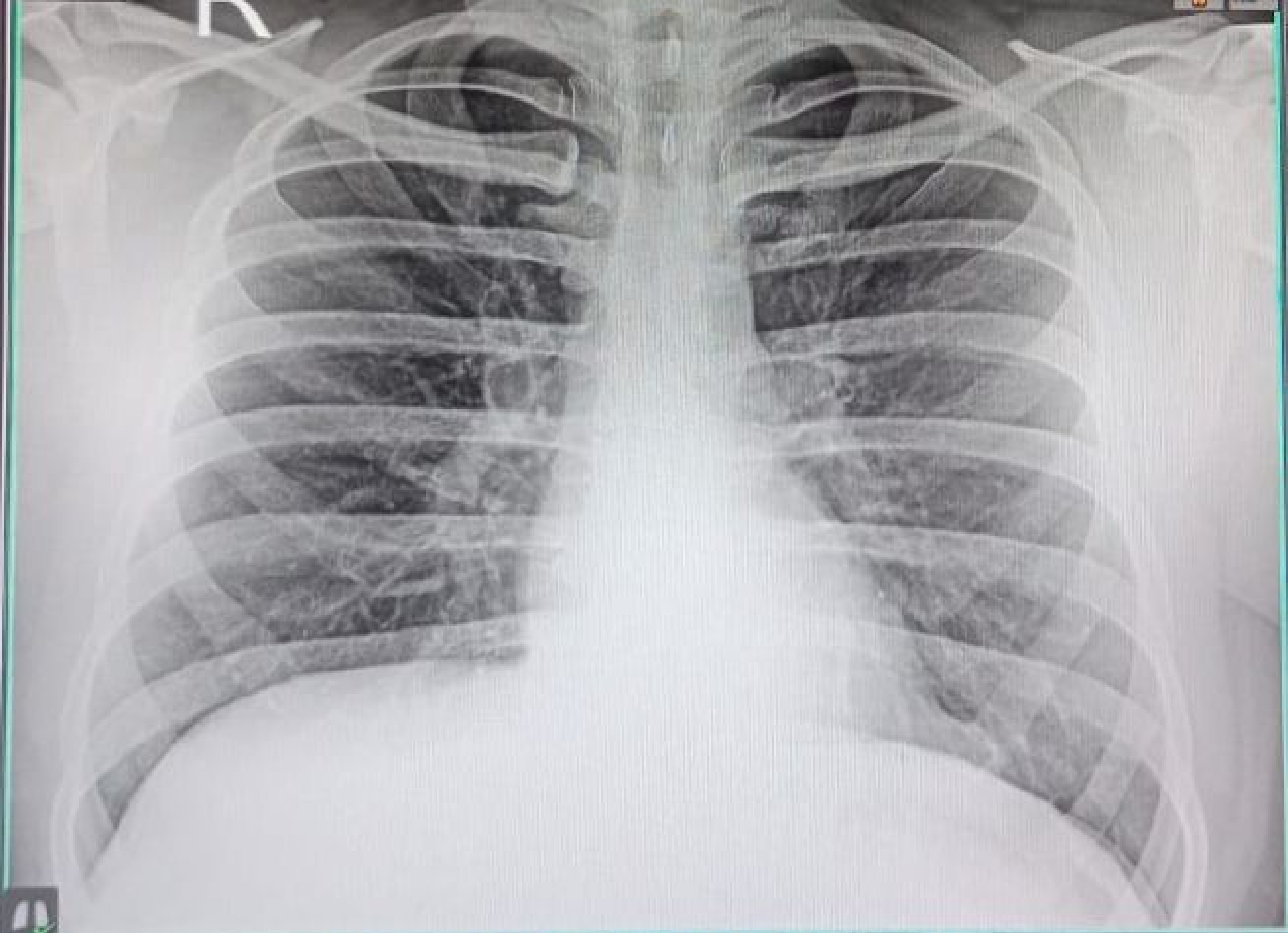
Dr. AMIT MOHAN  
MD  
Reg. No. 14559





R

NEW!



23122302931 MR ADITY 00 YRS M DR SELF CHEST PA  
12/23/2023 MODERN PATHOLOGY & DIAGNOSTIC CENTRE GOMTI NAGAR LUCKNOW