

Name : Mr. SURESH B GANGURDE (40 / M) www.askapollo.com

Date : 27/08/2022

Address : JAYAKHEDA ROAD SHRIPUR VADE NASHIK, NASHIK, NASHIK, MAHARASHTRA,
INDIA

Examined by:

UHID : MHN1.0000124757

Package : MediWheel Full Body Health Checkup Male Above 40

AHC No : NSKAH27438



CHIEF COMPLAINTS

For corporate health checkup
No specific complaints



DRUG ALLERGY

NO KNOWN ALLERGY

:27/08/2022



SYSTEMIC REVIEW

Cardiovascular system

- Nil Significant



Past medical history

Do you have any allergies? - No

Do you have any drug allergies? - No

Past medical history - nil significant

Covid 19 - No



Surgical history

Surgical history - Nil



Personal history

Marital status - Married

No. of children - 01

Diet - Mixed Diet

Alcohol - does not consume alcohol

Smoking - No

Chews tobacco - No

Chews paan - No

Uses snuff - No

Illicit substance use - No

Physical activity - Active



Family history

Father - alive

Aged - 75 yrs

Mother - alive

Aged - 70 yrs

Brothers - 1

Sisters - 1

Coronary artery disease - none

Cancer - None

PHYSICAL EXAMINATION



General

General appearance - normal

Build - normal

Height - 173

Weight - 91.1

BMI - 30.44

Pallor - No

Oedema - no

Temperature - 98

SpO2 - 98



Cardiovascular system

Heart rate (Per minute) - 90

Rhythm - Regular

- B.P. Supine

Systolic(mm of Hg) - 120

Diastolic(mm of Hg) - 80

Heart sounds - S1S2+

Respiratory system

Swaminarayan Nagar, Off Mumbai-Agra Highway,
Panchvati, Nashik - 422 003.

+91 - 253 - 2510250 / 350 / 450 / 550 / 750

apollonashik@apollohospitals.com

www.askapollo.com

QFAHN/BILL/003/V1



Apollo
HOSPITALS
NASHIK

Name : Mr. SURESH B GANGURDE (40 /M)


UHID : MHN1.0000124757

Date : 27/08/2022

Package : MediWheel Full Body Health Checkup Male Above 40

AHC No : NSKAH27438

Breath sounds - Normal vesicular breath sounds

 Abdomen

Organomegaly - No

Tenderness - No



Printed By : Shweta Sharad Shardul

Name : Mr. SURESH B GANGURDE (40 /M)

UHID : MHN1.0000124757

Date : 27/08/2022

Package : MediWheel Full Body Health Checkup Male Above 40

AHC No : NSKAH27438

URINE ROUTINE (CUE)

Test Name	Result	Unit	Level	Range
Specific Gravity	1.030 *		●	1.016-1.026
Color,:	PALE YELLOW			
Transparency:	Clear			
Reaction:	Acidic			7.2-7.8
Protein :	Nil			
Sugar:	Nil			
pH	5.5		●	4.6-8
Blood:	Negative			
Ketone	Negative			
Bile Pigments:	Negative			
Bile Salts :	Negative			
Urobilinogen	Normal			
Nitrite	Negative			
RBC	0	/hpf	●	0-2
WBC/Pus Cells	0-1/hpf	/hpf		
Tc/Sqc(Transitional/Squamous epithelial cells)	1-2/hpf	/hpf		

Eosinophils	3.3	%	●	1-6
Monocytes	3.3	%	●	1-10
ERYTHROCYTE SEDIMENTATION RATE (ESR)	15 *	mm/1st hr	●	0-10

BLOOD GROUPING AND TYPING (ABO and Rh)

Test Name	Result	Unit	Level	Range
ABO Group:	O			
Rh (D) Type:	POSITIVE			

LIVER FUNCTION TEST (PACKAGE)

Test Name	Result	Unit	Level	Range
ALT(SGPT) - SERUM / PLASMA	20 *	U/L	●	30-65
ALBUMIN - SERUM	4.8	g/dL	●	3.5-5
GLOBULIN - SERUM: (Calculated)	3.6	g/dL	●	1.8-3.6
ALBUMIN:GLOBULIN - SERUM(RATIO) (Calculated)	1.3		●	1.1-1.8
ALKALINE PHOSPHATASE - SERUM/PLASMA	80	U/L	●	0-100
AST (SGOT) - SERUM	16	U/L	●	15-37
BILIRUBIN, TOTAL - SERUM	1.1 *	mg/dL	●	0.0-1.0

C B C WITH ESR (AUTOMATION + STANDARD METHOD)

Test Name	Result	Unit	Level	Range
Hemoglobin	16.2	g/dl	●	13.0-18.0
Haematocrit	51	%	●	39.0-54.0
RBC COUNT	5.6	Million/ul	●	4.2-6.5
MCV	90.7	fl	●	75.0-95.0
MCH	28.8	pg	●	26.0-32.0
MCHC	31.7	g/dl	●	31.0-36.0
RDW	16.2 *	%	●	11-16
Platelet Count(Optical/Impedance)	235	10 ³ /m ³	●	140-440
TLC Count	11.2 *	10 ³ /m ³	●	4.0-11.0
Neutrophils	55.7	%	●	45-75
Lymphocytes	41	%	●	20-45

LIPID PROFILE TEST (PACKAGE)

Test Name	Result	Unit	Level	Range
Total Cholesterol	205 *	mg/dL	●	0-200

CREATININE - SERUM / PLASMA

Test Name	Result	Unit	Level	Range
CREATININE - SERUM / PLASMA	1.0	mg/dL	●	0.8-1.3

LIVER FUNCTION TEST (PACKAGE)

Test Name	Result	Unit	Level	Range
GGTP: GAMMA GLUTAMYL TRANSPEPTIDASE - SERUM	32	U/L	●	0-50

GLUCOSE - SERUM / PLASMA (FASTING)

Test Name	Result	Unit	Level	Range
-----------	--------	------	-------	-------

● Within Normal Range ● Borderline High/Low ● Out of Range



Name : Mr. SURESH B GANGURDE (40 /M)

UHID : MHN1.0000124757

Date : 27/08/2022

Package : MediWheel Full Body Health Checkup Male Above 40

AHC No : NSKAH27438

Glucose - Plasma (Fasting) 155 * mg/dL ● 70-100

URINE
GLUCOSE(FASTING):
(Strip Method) Nil

GLUCOSE - SERUM / PLASMA (POST PRANDIAL)

Test Name	Result	Unit	Level	Range
Glucose - Plasma (POST PRANDIAL)	210 *	mg/dL	●	70-140
URINE GLUCOSE(POST PRANDIAL):(Strip Method)	1+			

GLYCOSYLATED HEMOGLOBIN (HbA1C) - WHOLE BLOOD

Test Name	Result	Unit	Level	Range
Glycosylated Hemoglobin (HbA1c)	6.7 *	%	●	0.0-6.0
Mean Plasma Glucose (MPG) Estimate:	161.22	mg/dL		

LIPID PROFILE TEST (PACKAGE)

Test Name	Result	Unit	Level	Range
HDL CHOLESTEROL - SERUM / PLASMA	37 *	mg/dL	●	40-60
TOTAL CHOLESTEROL/HDL CHOLESTEROL RATIO(Calculated)	5.5 *		●	0.0-4.5
LDL Cholesterol (Direct)	160	mg/dL		

LIVER FUNCTION TEST (PACKAGE)

Test Name	Result	Unit	Level	Range
PROTEIN, TOTAL - SERUM / PLASMA	8.4 *	g/dL	●	6.4-8.2

THYROID PROFILE - I(T3,T4 AND TSH)

Test Name	Result	Unit	Level	Range
TOTAL T3: TRI IODOTHYRONINE - SERUM	187	ng/dL	●	Healthy Adults: 69 - 215
TOTAL T4: THYROXINE - SERUM	11.1	µg/dL	●	Healthy Adults:5.2-12.7

LIPID PROFILE TEST (PACKAGE)

Test Name	Result	Unit	Level	Range
Triglycerides - Serum	169 *	mg/dL	●	0-150

THYROID PROFILE - I(T3,T4 AND TSH)

Test Name	Result	Unit	Level	Range
TSH: THYROID STIMULATING HORMONE - SERUM	6.7 *	uIU/mL	●	Euthyroid: 0.3 - 4.5 Hypothyroid: 7.1 - >75

UREA - SERUM / PLASMA

Test Name	Result	Unit	Level	Range
UREA - SERUM / PLASMA	15	mg/dL	●	15-38
UREA NITROGEN SERUM/PLASMA: (Calculated)	7	mg/dL	●	7-18

URIC ACID - SERUM

Test Name	Result	Unit	Level	Range
URIC ACID - SERUM	5.1	mg/dL	●	3.5-7.2

LIVER FUNCTION TEST (PACKAGE)

Test Name	Result	Unit	Level	Range
BILIRUBIN CONJUGATED (DIRECT) - SERUM	0.3	mg/dL	●	0.0-0.3
BILIRUBIN UNCONJUGATED - SERUM(Calculated)	0.8 *	mg/dL	●	0.0-0.7

PROSTATIC SPECIFIC ANTIGEN (PSA TOTAL)

Test Name	Result	Unit	Level	Range
PROSTATIC SPECIFIC ANTIGEN (PSA TOTAL)	1.1	ng/mL	●	0.16-1.7

CARDIAC STRESS TEST - (TMT)

ECG

ULTRASOUND - WHOLE ABDOMEN

Mild prostatomegaly.

No other significant abnormality is detected.

Suggest : Clinical correlation.

X-RAY CHEST PA

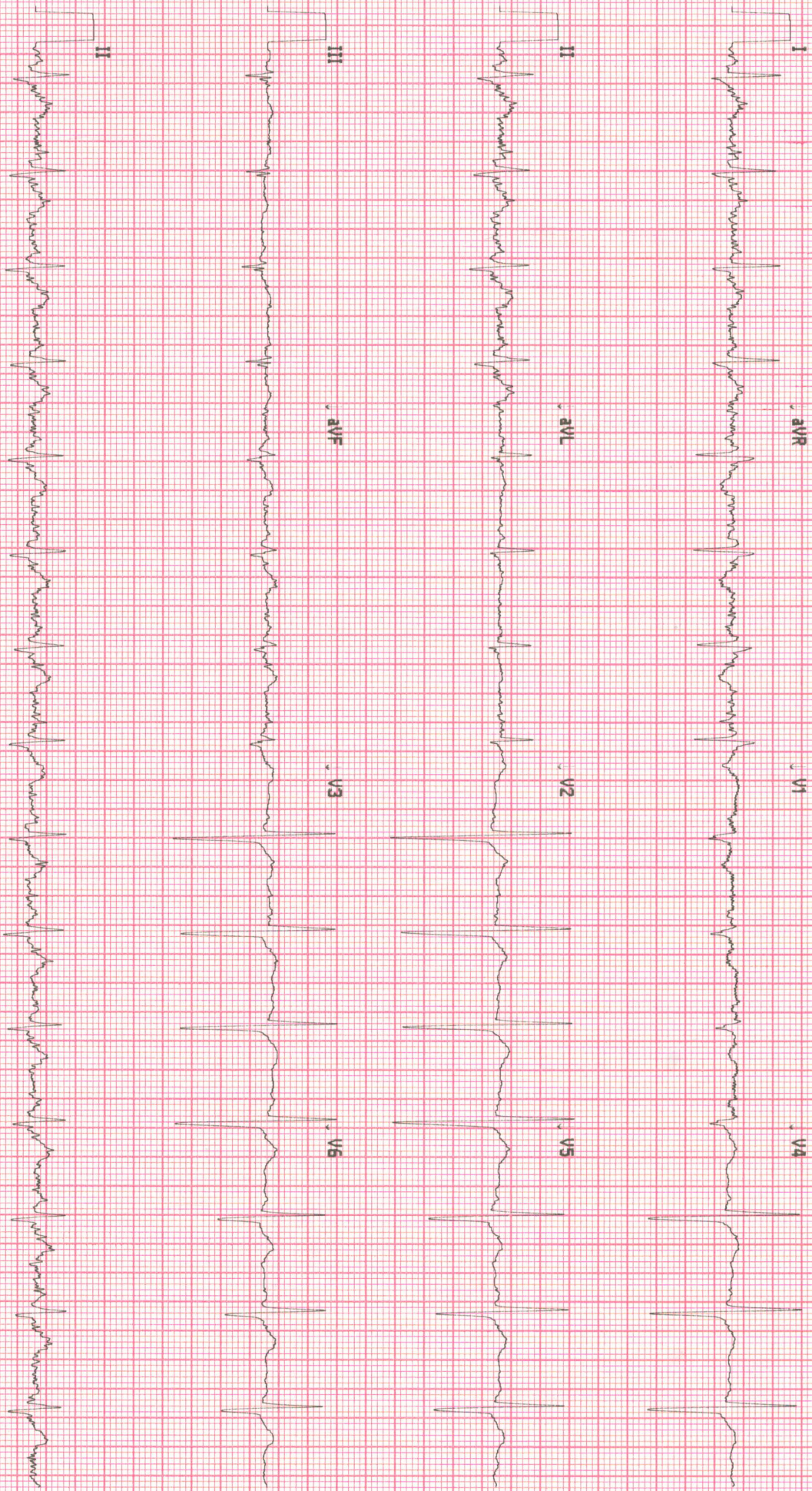
● Within Normal Range ● Borderline High/Low ● Out of Range

Gangurde, Surresh
ID:
DOB:
41yr, Male

27-Aug-2022 10:48:05

Vent rate: 90 BPM
PR int: 150 ms
QRS dur: 95 ms
QT/QTc: 344/392 ms
P-R-T axes: 49 0 46

SINUS RHYTHM
NORMAL ECG
UNCONFIRMED REPORT



113500188213

No Site Name

Site # 0 Cart # 2 Version 2.0.4.0 Sequence #19927 25mm/s 10mm/mV 0.05-40 Hz



Screening Echocardiography Report

Name: - Mr. SURESH B GANGURDE
UHID No: - MHN1. 0000124757
Referred by: -
Echo window: - Good


Age/Sex: 49/M
DATE: 27/08/2022
Echo No: -30262

Concentric LVH.
Normal LV systolic function. No RWMA at rest.
Normal RV systolic function.
LV diastolic dysfunction.
AO/LA= 36 mm/ 40 mm, LVIDd/LVIDs= 44 mm/ 29 mm, IVS/PW= 14 mm/12 mm.
No PAH.
No Clot/ Vegetation/Pericardial effusion.
No Coarctation.

Normal Echo Study.


Impression: -

Concentric LVH.
Normal LV systolic function. No RWMA at rest.
Normal RV systolic function.
LV diastolic dysfunction.
No PAH.
No clot/ vegetation/pericardial effusion.
No Coarctation.


DR.Niramal Kolate.



Radiology

Patient Details : Mr. SURESH B GANGURDE | Male | 40Yr 0Mth 0Days
UHID : MHN1.0000124757 **Patient Location:** AHC
Patient Identifier: NSKAH27438 
DRN : 222019145 **Completed on :** 27-AUG-2022 12:43
Ref Doctor : DR. Rajashri Dhongade

ULTRASOUND - WHOLE ABDOMEN

LIVER : Normal in size and measures 16cm. Echotexture is uniform and normal. No I.H.B.D./ focal lesions.

PORTAL VEIN: Normal in size.

GALL BLADDER: Partially distended. No calculi/pericholecystic fluid.

COMMON BILE DUCT: Normal in size.

PANCREAS : Visualized portion of head and body of pancreas appears normal in size and echotexture. Rest of the pancreas is obscured due to bowel gases.

AORTA, IVC and para aortic areas are normal.

SPLEEN : Normal in size (12cm) and echotexture.

KIDNEYS: Both kidneys are normal in site, size and echotexture.

No evidence of calculi/ hydronephrosis.

Right kidney measures : 11 x 5.3 cm.

Left kidney measures : 11 x 4.7 cm.

URINARY BLADDER: Well distended with normal walls.

No evidence of calculi/ growth/ diverticula .

PROSTATE : Mildly enlarged in size with homogenous echogenicity. No evidence of calcification within.

Prostate measures :4.2 x 4.0 x 3.9 cm = 35gms.

Seminal vesicles are normal.

H Swaminarayan Nagar, Off Mumbai-Agra Highway,
Panchvati, Nashik - 422 003.

+91- 253 - 2510250 / 350 / 450 / 550 / 750

apollonashik@apollohospitals.com

www.askapollo.com

QFAHN/BILL/003/V1



Mr. SURESH B GANGURDE

MHN1.0000124757

NSKAH27438

ULTRASOUND - WHOLE ABDOMEN

Visualized bowel loops appear grossly normal.

No evidence of any free fluid in the peritoneal cavity.

Impression

Mild prostatomegaly.


No other significant abnormality is detected.

Suggest : Clinical correlation.

--- END OF THE REPORT ---

Dr. Harshal S Dhongade

Consultant - Radiology





Radiology

Patient Details : Mr. SURESH B GANGURDE | Male | 40Yr 0Mth 0Days

UHID : MHN1.0000124757 **Patient Location:** AHC

Patient Identifier: NSKAH27438



DRN : 122032537 **Completed on :** 27-AUG-2022 10:45

Ref Doctor : DR. Rajashri Dhongade

X-RAY CHEST PA

Mild rotation.

Right fibrotic strands are noted in right upper zone extending at hilar region.

Rest of the lung fields are clear.

Costophrenic angles are clear.

Cardiac size and contour are within normal limits.

Rib cage is normal.

Soft tissues are normal.

Suggest : Clinical correlation.

Impression

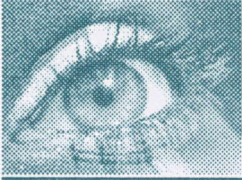
..

---- END OF THE REPORT ----

Dr.Gorakhnath T

CONSULTANT-RADIOLOGY

Bullion



OPHTHALMOLOGY



Name : Mr. Suresh Gangwade
 Occupation : _____
 Age : 41 Sex : Male Female S/M/W/D
 Address : NISIK
 _____ Tel. No. _____

Date 27/08/22 UNIT _____
 Room No. _____ Out Patient
 Ref. Physician : _____
 Copies to : _____

REPORT ON OPHTHALMIC EXAMINATION

HISTORY : _____
Sp-ten of both eyes at age of 9 yrs.

PRESENT COMPLAINT : No Complaint

PAST HISTORY : DM / HTN / ALLERGY

ON EXAMINATION

VISION :

		RE RIGHT				LE LEFT			
		SPH	CYL	AXIS	VA	SPH	CYL	AXIS	VA
DIST		<u>VA No m</u>				<u>VA No m</u>			
NEAR									

AR / Retinoscopy :

RIGHT			LEFT		
SPH	CYL	AXIS	SPH	CYL	AXIS
<u>_____</u>			<u>_____</u>		

Refraction or Acceptance :

		RIGHT				LEFT			
		SPH	CYL	AXIS	VA	SPH	CYL	AXIS	VA
DIST		<u>_____</u>				<u>_____</u>			
NEAR		<u>_____</u>				<u>_____</u>			

CONSULTANT OPTOMETRIST


[Signature]

Anterior Sigmoid :

RE

Rn ptosis bulbar

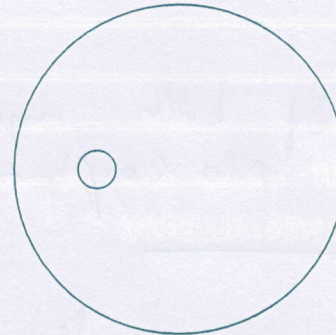

LE



Fundus :

RE

LE



Diagnosis :

Rn Bulbar eye -

Advise / Rx:

• hb with prepapillary exudates

CONSULTANT OPHTHALMOLOGIST

H Swaminarayan Nagar, Off Mumbai-Agra Highway,
Panchvati, Nashik - 422 003.

+91- 253 - 2510250 / 350 / 450 / 550 / 750

apollonashik@apollohospitals.com

www.askapollo.com

QFAHN/BILL/003/V1



27/1/22

Mr. Suresh. Gangwade

Dr. Prayank

IM.

9096986290


8275015672

- missing \bar{c} multiple teeth.

- supra & subgingival plaque & stains present.

- Class I malocclusion unilaterally.

Adv. - FPD \bar{c} missing.
IOPA.



[Handwritten signature]