

# MALIK RADIX HEALTHCARE PVT LTD

UNI-EMC-217/218 NIRMAN VIHAR VIKAS MARG

DELHI 110092

ANU GUPTA

ID: 1516

AGE/SEX: 32 Yr F

HT/WT: /

DATE: 14-04-2023 09:05:44-AM

REF BY: Dr.

MACHINE INTERPRETATION: Old Septal Myocardial Infarct. Sinus Rhythm.

RATE: 71 bpm

BP: N/A

P Axis: 40 deg.

QRS Axis: 67 deg.

T Axis: 49 deg.

P Duration: 96 ms

PR Duration: 178 ms

QRS Duration: 69 ms

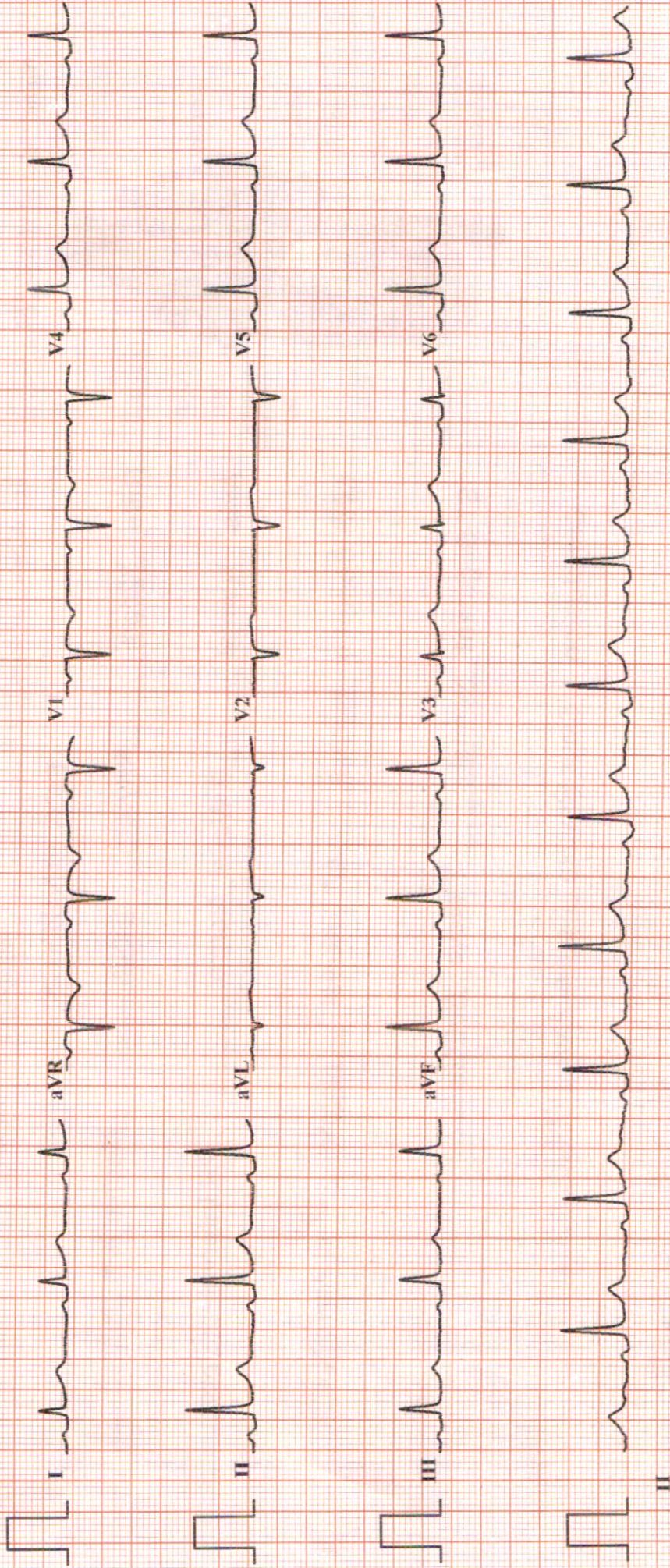
QT Interval: 363 ms

QTc Interval: 386 ms

Linked Median

Speed: 25 mm/s

Sensitivity: 10 mm/mV





# Malik Radix HealthCare.

## ELECTROCARDIOGRAM

Name: MRS. ANU GUPTA

Age & Sex: 32YR/FEMALE

Ref by: MEDIWHEEL

Date: 14/04/2023

### ECG FINDINGS:

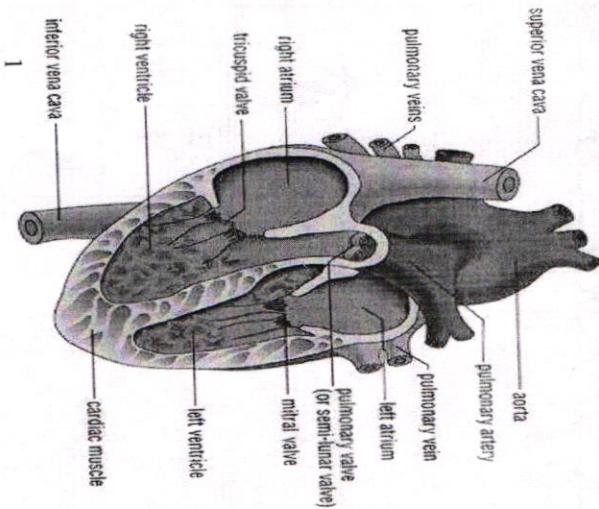
Rate 72bpm Rhythm Sinus Mechanism Normal

Axis Normal P Wave Normal PR Interval 0.17/Sec

QRS Complex Normal QT Interval Normal Q Wave Normal

ST Segment Normal T Wave Normal

Conclusion Sinus Rhythm, Normal Axis, TWNL.



Doctors Signature: SHEIKH AHMED

M.D. "Physician"

PGDCC

DMC-46499



## Echocardiogram Report

Patient Name	MRS. ANU GUPTA
Date of Test	14/04/2023
Age	32YRS/ FEMALE
Ref. by	MEDI WHEEL

Dimensions	Result	Normal Range
AO (ed)	2.6 cm	( 2.1 -3.7cm)
LA (es)	2.9 cm	(2.1 -3.7cm)
RVID (ed)	2.3 cm	(1.1-3.0cm)
LVID (ed)	3.6 cm	(3.6 – 5.5 cm)
LVID (es)	2.5 cm	(2.3-3.9cm)
IVS (ed)	1.0 cm	(0.6 – 1-2 cm)
LVPW (ed)	1.0 cm	(0.6 – 1-2 cm)
EF	60 %	
FS	31 %	(28 % - 42 %)

### Impression

NO REGIONAL WALL MOTION ABNORMALITY SEEN.

LVEF= 60 %

NORMAL CHAMBER DIMENSIONS.

NORMAL MIP.

NORMAL COLOR FLOW.

NO INTRA CARDIAC CLOT/MASS/ VEGETATION/PERICARDIAL EFFUSION SEEN.

Dr. Nishant Tyagi

(M.D. Medicine. DNB Cardiology)

(Senior Consultant,Cardiology)

Dr. Sheikh Nazir Ahmed

M.D. "Physician" PGDCC

(Consultant Non – Invasive Cardiologist)

### Facilities Available

- Multispeciality Hospital - 24 Hours Emergency - X-Ray/ ECG/ Ultrasound/ CT Scan - Dental - Fully Equipped Operation Theatre  
- Fully Functional Lab - 24/7 Casualty/ ICU-Nursery 24/7 Pharmacy - Labour Room - All Speciality OPD - Laproscopic Surgery -  
ECHO - Plastic Surgery





**LAB REPORT**

Reg. Date	14/04/2023	Patient Id	2304140002	DOB.	21/11/1990
Name	MRS. ANU GUPTA	Gender	F	Perm. ID	
Age	32 Yrs. 4 Mn. 23 Day	Panel	MEDIWHEEL	Reported	14/04/2023 16:29:46
Ref. By	MEDIWHEEL				

Test Name	Result	Units	Ref. Range
<b>MEDIWHEEL F BELOW 40</b>			
<b><u>HAEMATOLOGY</u></b>			
<b><u>COMPLETE HAEMOGRAM</u></b>			
HAEMOGLOBIN (HB%)	12.5	gm/dl	12 - 15
TOTAL LEUCOCYTE COUNT (TLC)	6,400	/cumm	4000 - 11000
<b><u>DIFFERENTIAL LEUCOCYTE COUNT (DLC)</u></b>			
NEUTROPHIL	61	%	40 - 80
LYMPHOCYTE	32	%	28 - 55
MONOCYTE	05	%	02 - 10
EOSINOPHIL	02	%	01 - 06
BASOPHIL	00	%	0 - 0
ESR (WESTEGREN'S METHOD)	12	mm/1st hr.	0 - 15
R B C COUNT	4.53	Millions/cmm	4.247 - 5.4
P.C.V / HAEMATOCRIT	40.5	%	35 - 45
M C V	89.4	fl.	80 - 100
M C H	27.6	Picogram	27.0 - 31.0
M C H C	30.9	gm/dl	33 - 37
PLATELET COUNT	2.35	Lakh/cu mm	1.50 - 4.50
Urine Routine Examination			
<b><u>PHYSICAL EXAMINATION</u></b>			
QUANTITY	10	ml.	
COLOUR	Pale Yellow		Pale Yellow
TRANSPARENCY	Clear		
SPECIFIC GRAVITY	1.010		
PH	6.0		

Checked by : \_\_\_\_\_  
Page 1 Contd...2

If test results are alarming or unexpected, patient is advised to contact the laboratory immediately for possible remedial action.

**Facilities Available**

- Multispeciality Hospital - 24 Hours Emergency - X-Ray/ ECG/ Ultrasound/ CT Scan - Dental - Fully Equiped Operation Theatre  
- Fully Functional Lab - Casualty/ ICU-Nursery - Labour Room - All Speciality OPD - Laproscopic Surgery - ECHO - Plastic Surgery



**LAB REPORT**

Reg. Date	14/04/2023	Patient Id	2304140002	DOB.	21/11/1990
Name	MRS. ANU GUPTA	Gender	F	Perm. ID	
Age	32 Yrs. 4 Mn. 23 Day	Panel	MEDIWHEEL	Reported	14/04/2023 16:29:46
Ref. By	MEDIWHEEL				

Test Name	Result	Units	Ref. Range
<b>CHEMICAL EXAMINATION</b>			
ALBUMIN	Nil		
SUGAR	Nil		
<b>MICROSCOPIC EXAMINATION</b>			
PUS CELLS	1-2	/HPF	
RBC'S	Nil	/HPF	
CASTS	Nil		
CRYSTALS	NIL		
EPITHELIAL CELLS	0-1	/HPF	
BACTERIA	Nil		
OTHERS	Nil		
Stool Examination Report			
BLOOD GROUP ABO	" B "		
RH TYPING	Positive		
BLOOD SUGAR FASTING	76.58	mg/dl	70 - 100
BLOOD SUGAR PP	<b>87.41</b>	mg/dl	90 - 140
<b>HBA1C</b>	4.51	%	

**Interpretation**

Non Diabetic	: 4-6%
Good Diabetic Control	: 6-8%
Fair Control	: 8-10%

Checked by : \_\_\_\_\_  
Page 2 Contd...3

If test results are alarming or unexpected, patient is advised to contact the laboratory immediately for possible remedial action.

**Facilities Available**

- Multispeciality Hospital - 24 Hours Emergency - X-Ray/ ECG/ Ultrasound/ CT Scan - Dental - Fully Equiped Operation Theatre  
- Fully Functional Lab - Casualty/ ICU-Nursery - Labour Room - All Speciality OPD - Laproscopic Surgery - ECHO - Plastic Surgery





**LAB REPORT**

Reg. Date	14/04/2023	Patient Id	2304140002	DOB.	21/11/1990
Name	MRS. ANU GUPTA	Gender	F	Perm. ID	
Age	32 Yrs. 4 Mn. 23 Day	Panel	MEDIWHEEL	Reported	14/04/2023 16:29:46
Ref. By	MEDIWHEEL				

Test Name	Result	Units	Ref. Range
Poor Control	: >10%		

The Glycosylated haemoglobin assay has been validated as a reliable indicator Of mean blood glucose levels for a period of 8-12 week period. ADA recommended the testing twice a year in patients with stable blood glucose and quarterly. If treatment change, or if blood glucose levels are unstable.

**TO BE CORRELATED CLINICALLY.**

**THYROID PROFILE**

Free T3 ELFA	2.01	ng/ml	02 - 04
Free T4 ELFA	1.41	ug/dl	0.8 - 2.7
TSH Serum/ELFA	2.850	uIU/ml	0.25 - 5.50 uIU/ml

**Interpretation**

**Clinical Use**

- Diagnose Hypothyroidism and Hyperthyroidism
- Monitor T4 replacement or T4 suppressive Therapy
- Quantify TSH levels in the subnormal range

Increased Levels : Primary Hypothyroidism Subclinical Hypothyroidism, TSH dependent, Thyroid Hormone Resistance.

Decreased Levels : Grave's Disease, Autonomous Thyroid Hormone Secretion, TSH Deficiency

**LIPID PROFILE**

TOTAL CHOLESTEROL	122.50	mg/dL	130.0 - 200.0 (<200)
-------------------	--------	-------	----------------------

Checked by : \_\_\_\_\_  
Page 3 Contd...4

If test results are alarming or unexpected, patient is advised to contact the laboratory immediately for possible remedial action.

**Facilities Available**

- Multispeciality Hospital - 24 Hours Emergency - X-Ray/ ECG/ Ultrasound/ CT Scan - Dental - Fully Equipped Operation Theatre
- Fully Functional Lab - Casualty/ ICU-Nursery - Labour Room - All Speciality OPD - Laproscopic Surgery - ECHO - Plastic Surgery





**LAB REPORT**

Reg. Date	14/04/2023	Patient Id	2304140002	DOB.	21/11/1990
Name	MRS. ANU GUPTA	Gender	F	Perm. ID	
Age	32 Yrs. 4 Mn. 23 Day	Panel	MEDIWHEEL	Reported	14/04/2023 16:29:46
Ref. By	MEDIWHEEL				

Test Name	Result	Units	Ref. Range
TRIGLYCERIDES	85.00	mg/dL	80.5 - 150.0 (<150)
H D L CHOLESTEROL DIRECT	37.82	mg/dL	42.0 - 60.0 (<40->59)
V L D L	17.0	mg/dL	4.0 - 30. (23-45)
L D L CHOLESTEROL	67.7	mg/dL	50.0 - 150.0 (50-150)
TOTAL CHOLESTEROL / HDL RATIO	3.2		3.3 - 5.1
LDL / HDL CHOLESTEROL RATIO	1.8		1.5 - 3.5
SERUM URIC ACID	3.65	mg/dl	2.4 - 6.0
BLOOD UREA NITROGEN (BUN)	7.12	mg/dl	6.0 - 21.0
SERUM CREATININE	0.60	mg/dl	0.6 - 1.2
BUN/CREAT RATIO	11.8	mg/dl	
<b><u>LIVER FUNCTION TEST (LFT)</u></b>			
BILIRUBIN TOTAL	0.71	mg/dl	0.2 - 1.2
CONJUGATED (D. BILIRUBIN)	0.10	mg/dl	0.00 - 0.3
UNCONJUGATED (I.D.BILIRUBIN)	0.61	mg/dl	0.2 - 0.9
SGOT / AST	16.58	IU/L	0 - 35
SGPT / ALT	14.19	IU/L	0 - 35
ALKALINE PHOSPHATASE	48.40	U/L	64 - 306
TOTAL PROTEIN	6.75	gm/dl	6.0 - 8.3
ALBUMIN	4.03	gm/dl	3.2 - 5.0
GLOBULIN	2.72	gm/dl	2.5 - 5.6
A/G RATIO	1.48		0.9 - 2.0
GAMMA GT	18.25	IU/L	0.0 - 35.0

10 - 20

**DR. REEMA DAHIYA**  
M.B.B.S, MD (Path.)  
Checked by Malik Radix Healthcare Pvt. Ltd.  
C-217, C-218, Nirman Vihar,  
Delhi-92

**DR. MEENU AGGARWAL**  
M.B.B.S, MD (Path.)

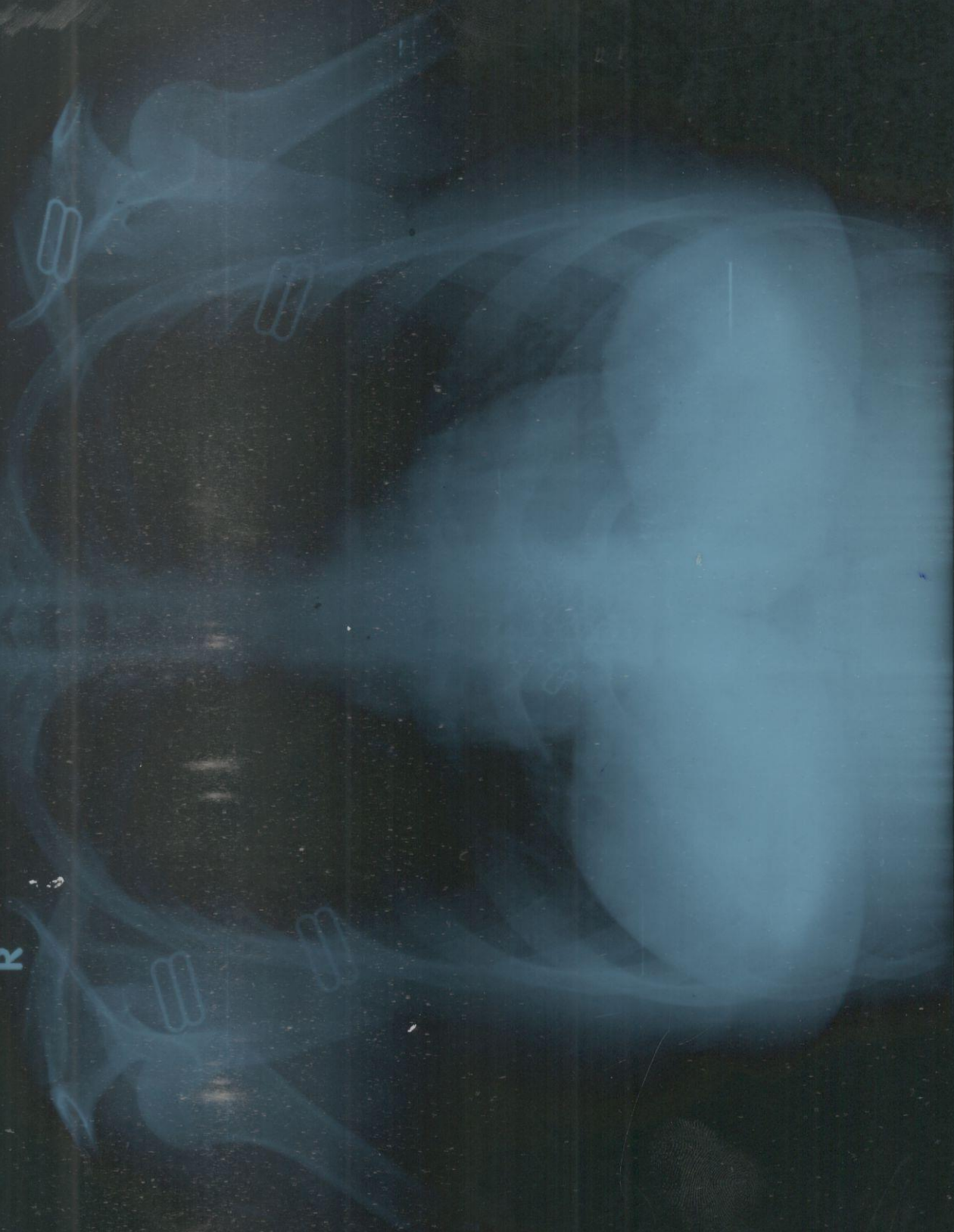
If test results are alarming or unexpected, patient is advised to contact the laboratory immediately for possible remedial action.

**Facilities Available**

- Multispeciality Hospital - 24 Hours Emergency - X-Ray/ ECG/ Ultrasound/ CT Scan - Dental - Fully Equiped Operation Theatre  
- Fully Functional Lab - Casualty/ ICU-Nursery - Labour Room - All Speciality OPD - Laproscopic Surgery - ECHO - Plastic Surgery



R



ANU GUPTA 32 Y/F PT185636 CHEST PA 14/Apr/2023 09:15:00  
RADIHEALTHCARE C-318 NIRMAL VIHAR BH-2201110





UHID	PT185636	LAB No.	XRY2300427
Name	Mrs. ANU GUPTA	Regn. No.	GEN2301568
Age / Sex	32 Yrs / F	Receiving Dt/Time	14/Apr/2023 09:45
		Reporting Dt/Time	14/Apr/2023 11:47 AM



**XRAY**

CHEST (PA)

Both lung fields are normal.

Cp angles are clear.

Hila are normal...

Heart size appears within normal limits.

Soft tissue shadows and bony thorax are normal.

**IMP- NORMAL CHEST X-RAY**

Advised....please correlate clinically.

\*\*\*\*\* END OF REPORT \*\*\*\*\*

**DR. K.K. SINHA**  
M.B.B.S., D.M.R.D.  
SENIOR CONSULTANT  
Reg. No. 25437 (DMC)

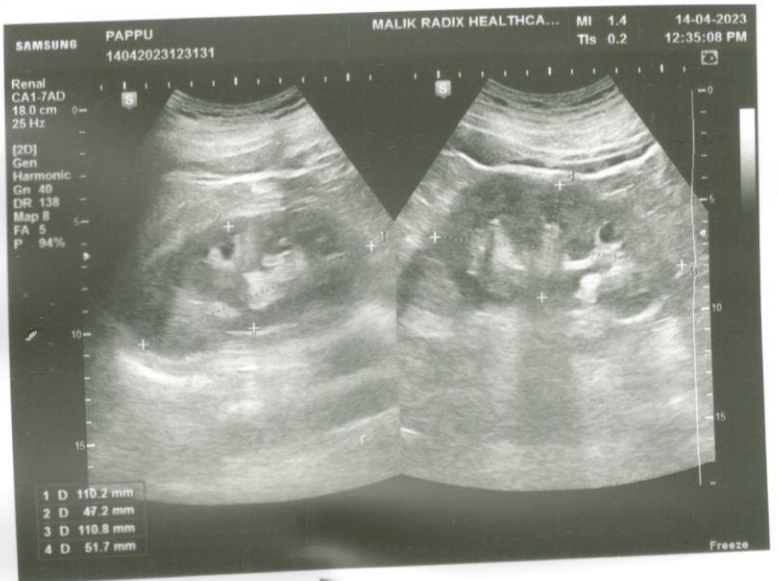
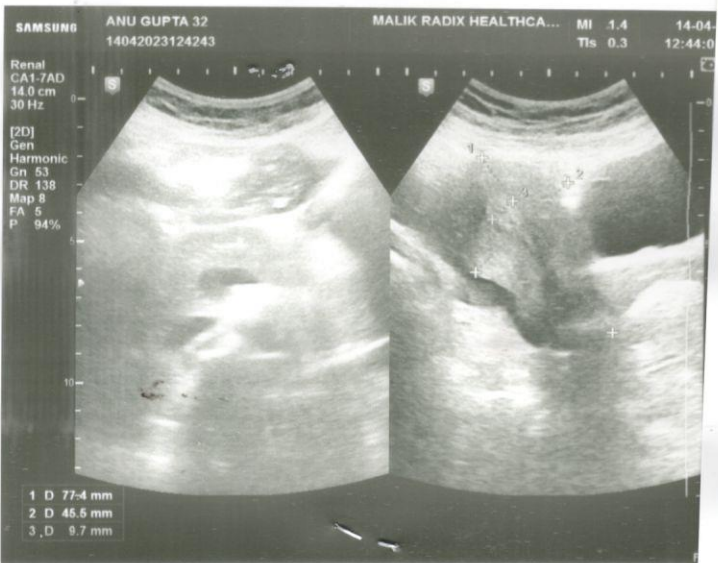
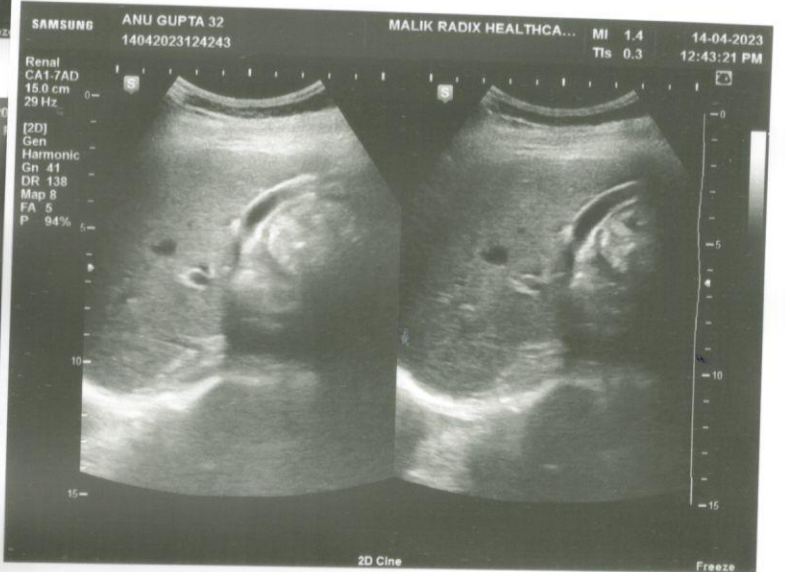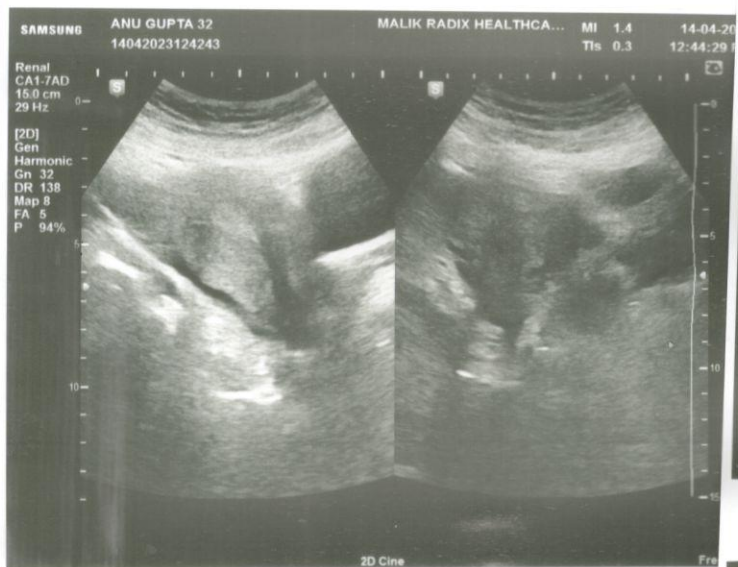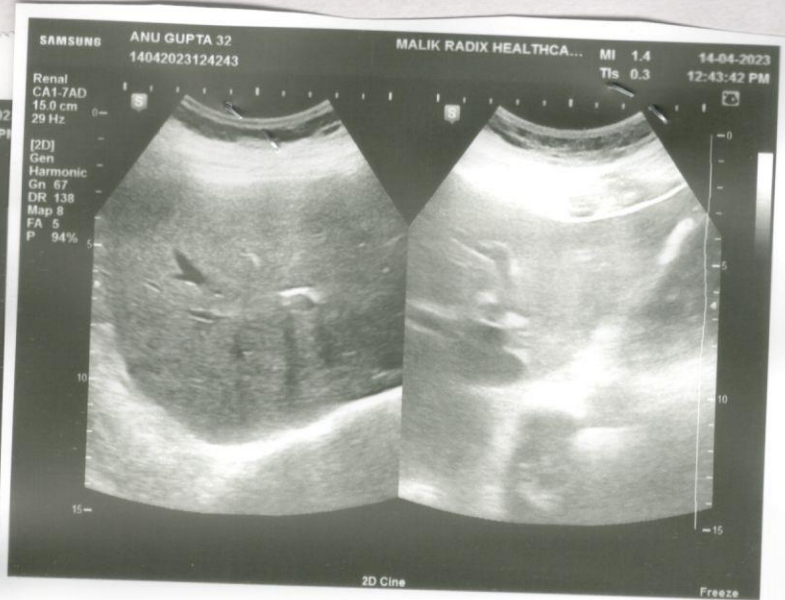
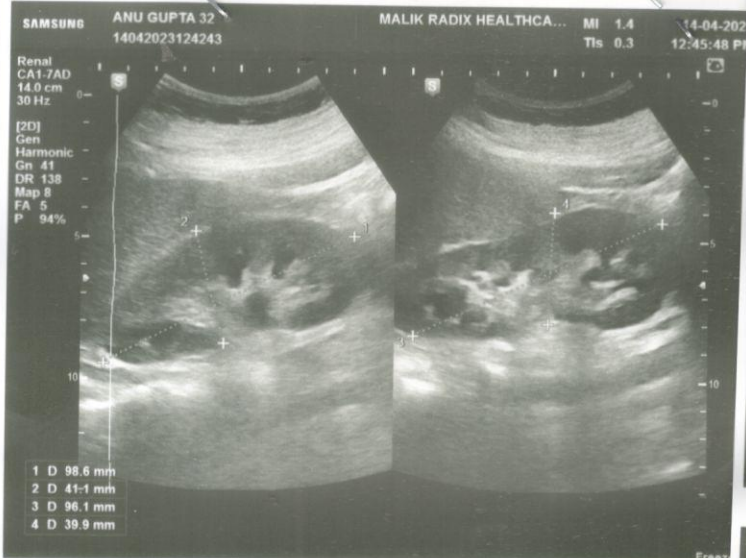
**DR. RAJESH MALHOTRA**  
MBBS, MD (RADIOLOGY)  
CONSULTANT RADIOLOGY  
Reg.No.DMC9299

**DR. T. K VOHRA**  
MD (RADIODIAGNOSIS)  
SENIOR CONSULTANT  
Reg. No. 3272 (DMC)

**DR. MUKESH KOSHAL**  
MBBS, MD (RADIOLOGY)  
CONSULTANT RADIOLOGY  
Reg.No.DMC10407

**Facilities Available**









UHID	PT185636	LAB No.	ULC2300322
Name	Mrs. ANU GUPTA	Regn. No.	GEN2301568
Age / Sex	32 Yrs / F	Receiving Dt/Time	14/Apr/2023 12:47
		Reporting Dt/Time	14/Apr/2023 12:44 PM



**U/S WHOLE ABDOMEN**

Liver appears normal in size with normal echogenicity. No focal lesion seen.

CBD & portal vein normal. .

Gall bladder is normally distended showing no calculi and cholecystitis.

Wall thickness normal.

Pancreas ,para aortic appear normal.

Spleen is normal in size with normal echopattern...

Both kidneys are normal in size shape and echopattern.

No obvious hydronephrosis or stone seen.

Size of right kidney- 98x41mm

Size of left kidney- 96x40mm

Ureters are not dilated.

Urinary bladder is normal.No calculi or mass seen.

Uterus is normal in size shape and echopattern.

Uterus size - 77 X50 x 45 mm ET -9.7 mm

Both ovaries are normal in size .

No evidence of ascites or pleural effusion seen.

No abdominal lymphadenopathy seen.

Mild free fluid seen in POD.

**Imp—Mild free fluid in POD**

**Clinical correlation**

DR. K.K. SINHA  
M.B.B.S., D.M.R.D.  
SENIOR CONSULTANT  
Reg. No. 25437 (DMC)

DR. RAJESH MALHOTRA  
MBBS, MD (RADIOLOGY)  
CONSULTANT RADIOLOGY  
Reg.No.DMC9299

DR. T. K VOHRA  
MD (RADIOLOGY)  
SENIOR CONSULTANT  
Reg. No. 3272 (DMC)

DR MUKESH KOSHAL  
MBBS, MD (RADIOLOGY)  
CONSULTANT RADIOLOGY  
Reg.No.DMC10407