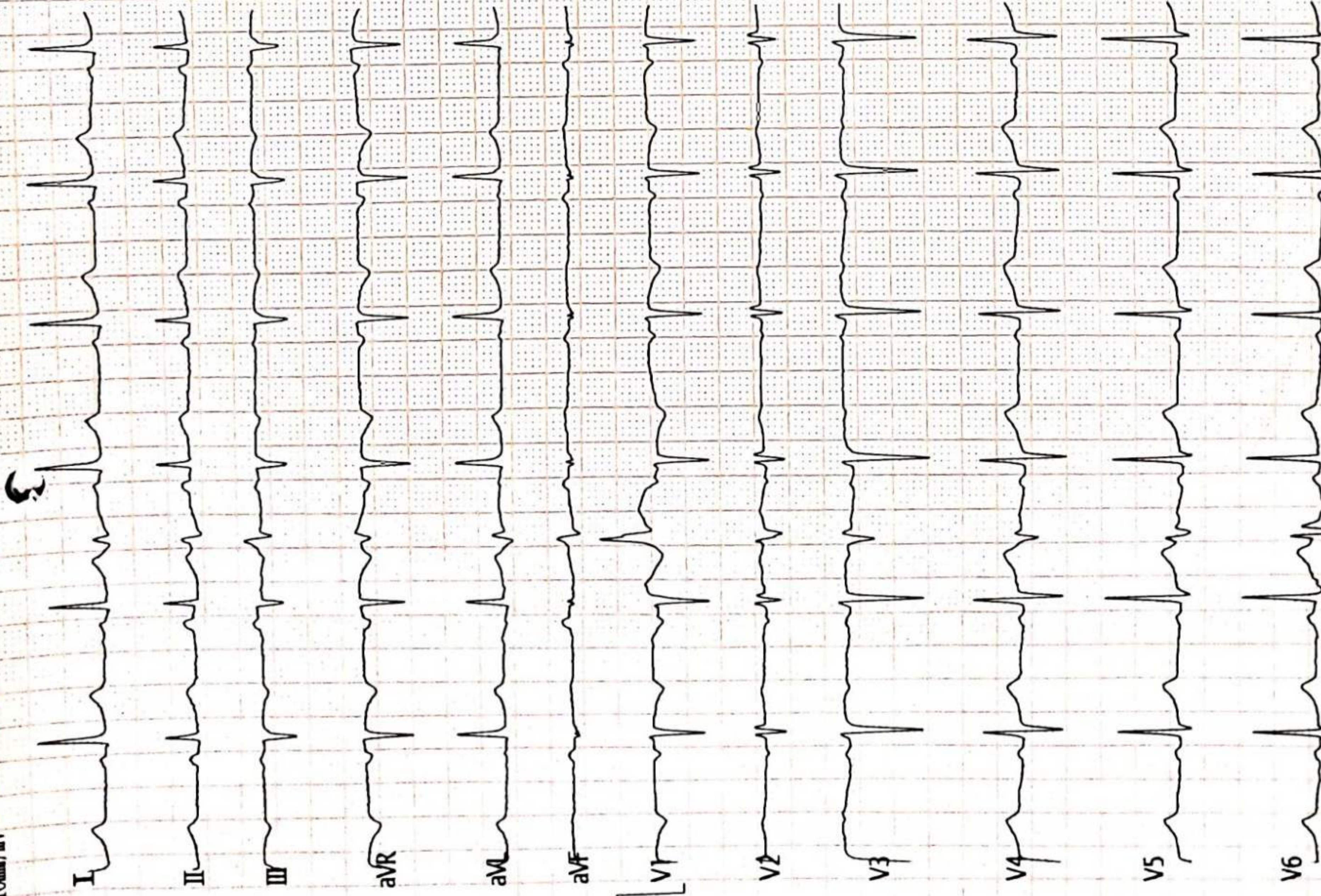


10mm/mV



<ECG Analysis Result>

- 800 Normal Sinus Rhythm
- 701 Poor R Progression
- 500 rSR' Pattern in V1/V2
- 212 Left Axis Deviation
- *** Borderline Normal ECG ***

Vent. Rate(BPM) : 73
 PR Int.(ms) : 132
 P/QRS/T Int.(ms) : 93 87 166
 QT/QTc Int.(ms) : 374 415
 P/QRS/T Axis(Deg.) : 64 -5 9
 RV1/SV5 Amp.(mV) : 0.05 0.15
 RV5/SV1 Amp.(mV) : 0.96 0.73

[Handwritten Signature]

Note : Unconfirmed Report Need to Review.

Dr. Sunil Suryawanshi
 M.D.(Medicine)
 Reg.No.2223

V2.35 Technician :

ST LEVEL(mV)

I	II	III	aVR	aVL	aVF
+0.01	+0.02	+0.00	-0.01	+0.00	+0.01
V1	V2	V3	V4	V5	V6
+0.00	+0.01	+0.02	+0.03	+0.02	+0.01

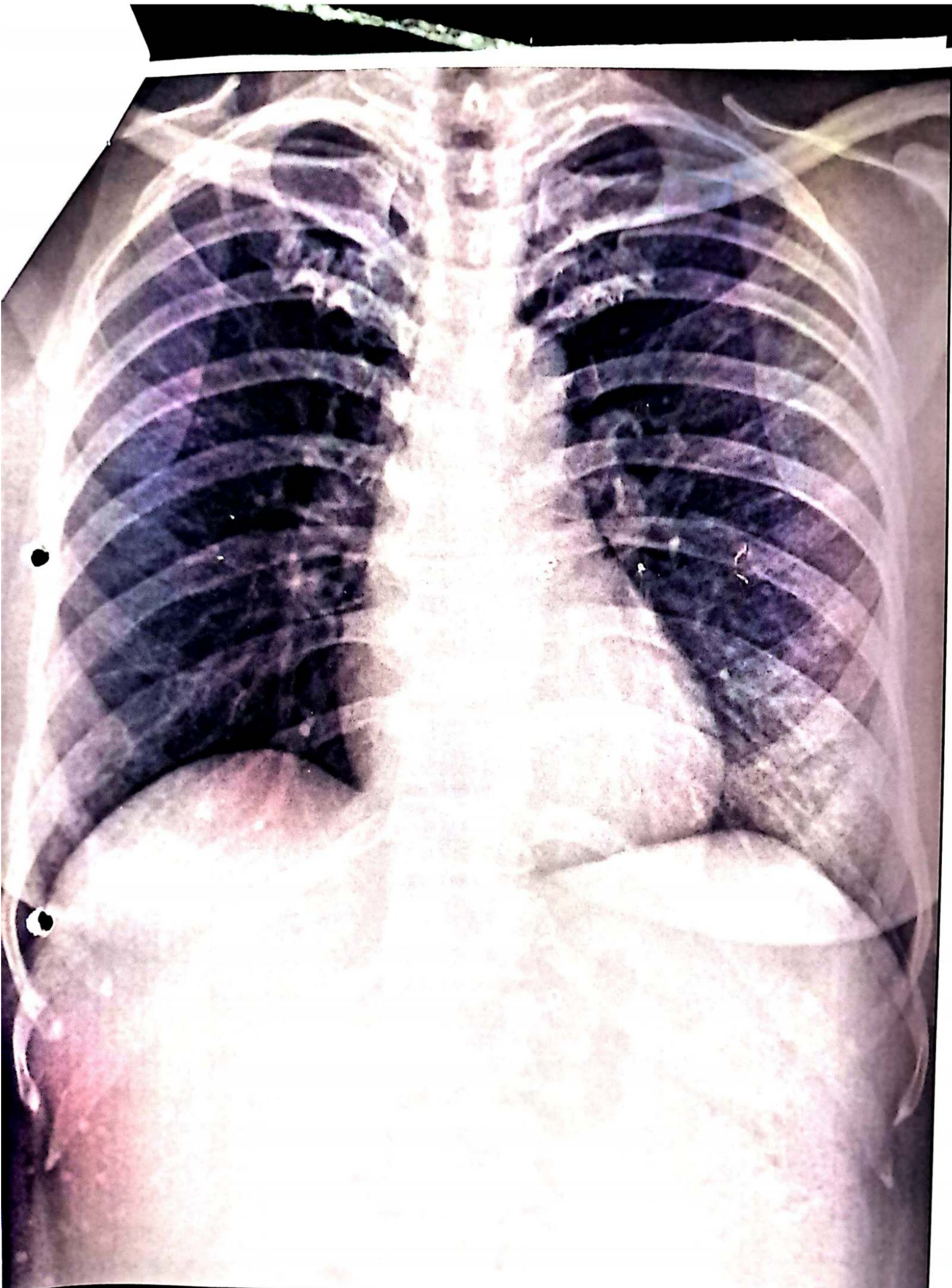
सौ ज्योति सुधाकर शिंदे

<JOTI DOKHE > 37400003391 F 51Y 162/83 cm/Kg 125/79 mmHg

SUJAY HOSPITALPW

25mm/s AC50 EMC ADS 2023-11-27 08:59:38

UNI-CARD ENTERPRISES, PH. NO. 9822002852



JOTI DOKHE 270110202309 CHEST PA 27-Nov-23

SUJAY HOSPITAL AND MATERNITY HOME, JALGAON



SAGAR IMAGING CENTRE

• Whole body sonography • Colour doppler • Digital X-ray

54-B, Onkar Nagar, Near Parikhpark, Jalgaon - 425001. Phone : 0257-2237634, e-mail : drchetanj@rediffmail.com

DR. CHETAN S. KAKLIYA

M.B.B.S., D.M.R.D. (Sion Hospital, Mumbai University)

• Ex-Consultant Radiologist In Asian Heart Hospital (Mumbai)

• Ex - Radiologist Wockhardt Hospital (Mulund)

Name	: JYOTI DOKHE	Date	: 27-11-2023
Ref By	: SUJAY HOSPITAL	Age/Sex	: 51 / Female

SONOGRAPHY OF BREAST

The skin is seen as homogenous echogenic band. The skin thickness is normal.

The nipple is visualised as well defined nodul, causing distal attenuation of sound beam. The sub areolar tissue is normal. The lactiferous duct is well visualised and is normal in caliber.

The subcutaneous fibro fatty tissue shows normal echo texture and is normal in thickness. There is no evidence of dilated lymphatics.

There is no evidence of enlarged intramammary lymph nodes.

The retromammary region consisting of fat ribs, and muscles is normal.

The axillary fat shows normal thickness and echo texture.

IMPRESSION :

Normal examination of breast.

**Histopathological correlation is suggested for confirmation
REPORT WITH THANKS.**

Clinico pathological correlation is suggested.


DR. CHETAN KAKLIYA





SAGAR IMAGING CENTRE

● Whole body sonography ● Colour doppler ● Digital X-ray

54-B, Onkar Nagar, Near Parikhpark, Jalgaon - 425001. Phone : 0257-2237634, e-mail : drchetanjj@rediffmail.com

DR. CHETAN S. KAKLIYA

M.B.B.S., D.M.R.D. (Sion Hospital, Mumbai University)

● Ex-Consultant Radiologist In Asian Heart Hospital (Mumbai)

● Ex - Radiologist Wockhardt Hospital (Mulund)

Name	: JYOTI DOKHE	Date	: 27-11-2023
Ref By	: SUJAY HOSPITAL	Age/Sex	: 51 / Female

SONOGRAPHY OF ABDOMEN AND PELVIS

The liver is normal in size, shape and has smooth margins. No focal lesion. The portal vein appears normal.

The gall bladder is physiologically distended. No evidence of calculus, wall thickening or mass lesion.

The common bile duct is normal in caliber. No evidence of calculus is noted in common bile duct.

The pancreas is normal in size, shape and echotexture. No focal lesion is noted.

The spleen is normal in size and shape. No evidence of focal lesion is noted.

There is no evidence of enlarged coeliac, mesentric, portal pre or para aortic lymph nodes. No vascular mass lesion. No evidence of ascitis or pleural effusion.

Both kidneys are normal in size and echotexture. No evidence of calculus, hydronephrosis or cortical scarring.

Right kidney measures - 10.4 x 4.2 cms.

Left kidney measures - 10.7 x 4.5 cms.

The urinary bladder is well distended. No evidence of calculus, wall thickening or mass lesion.

Uterus is not visualized (post op status).
No gross pelvic pathology is noted.

IMPRESSION:

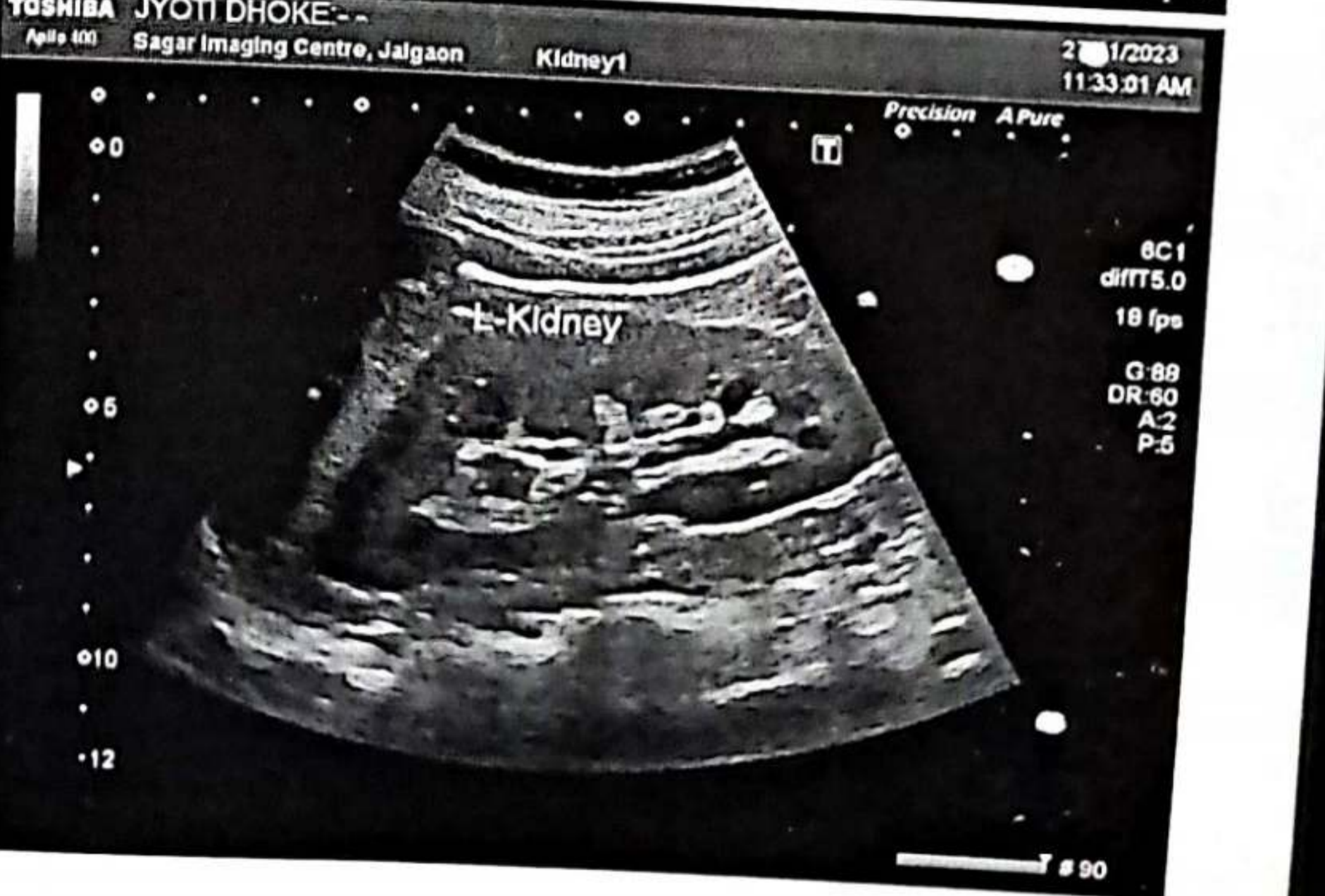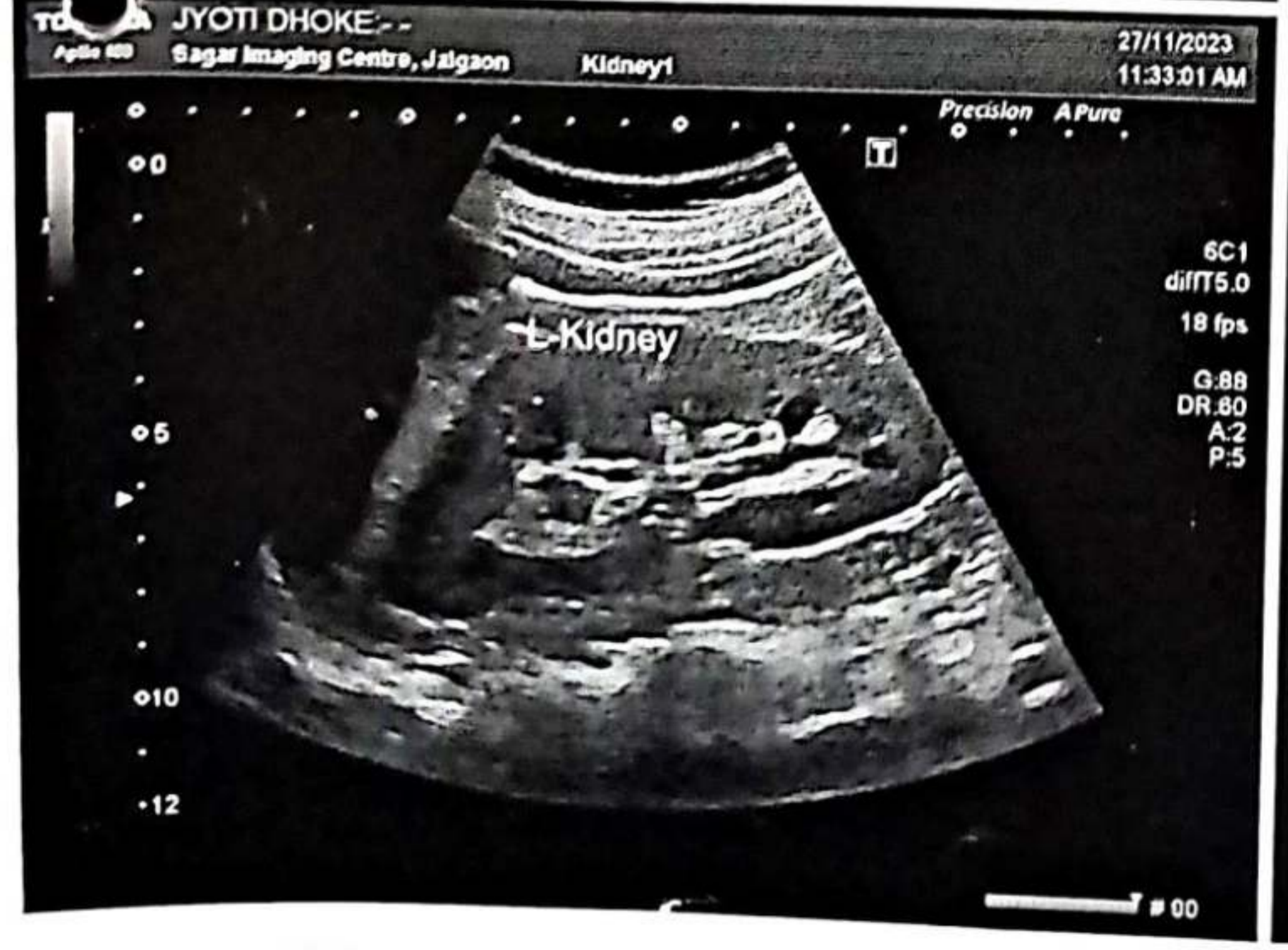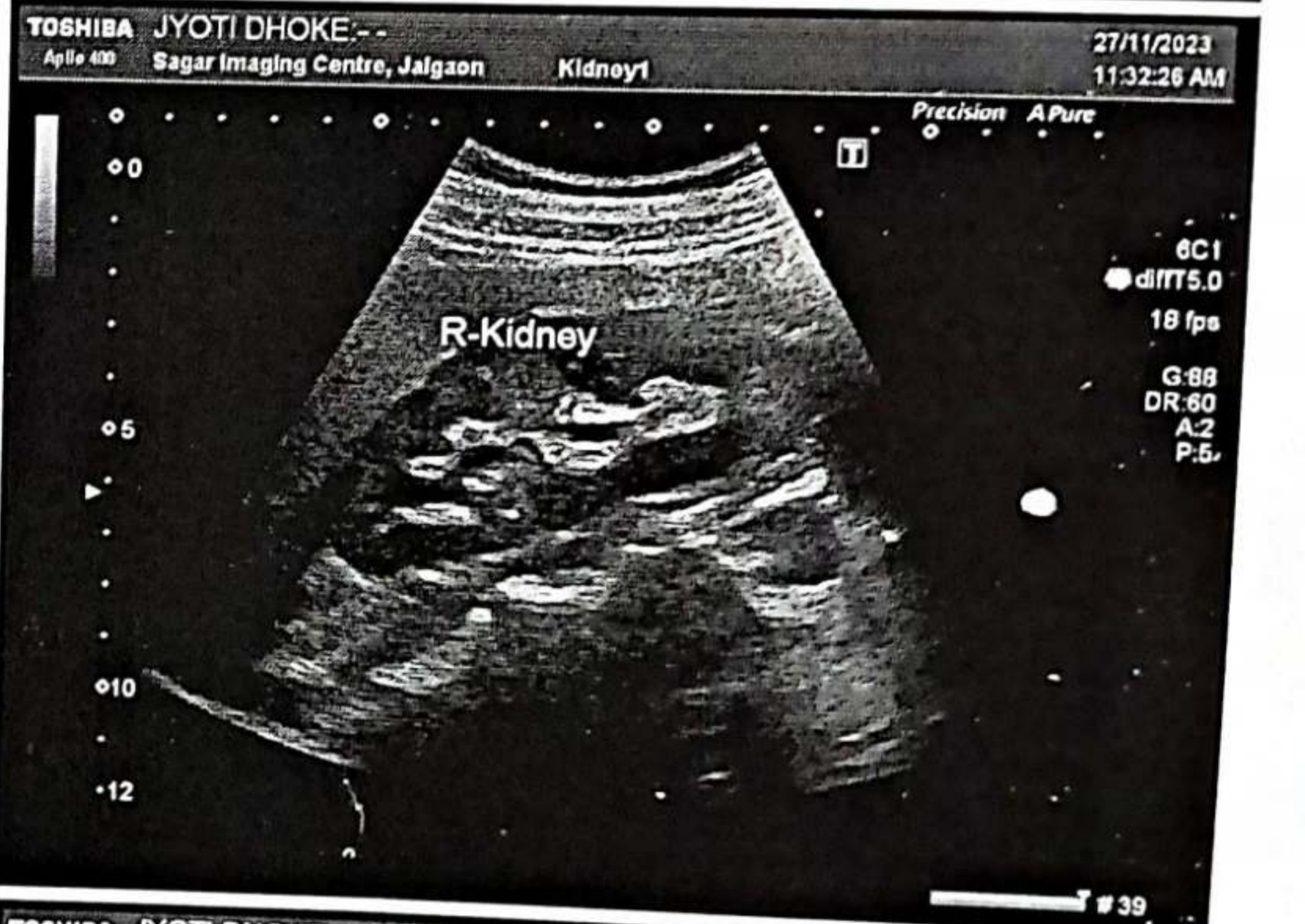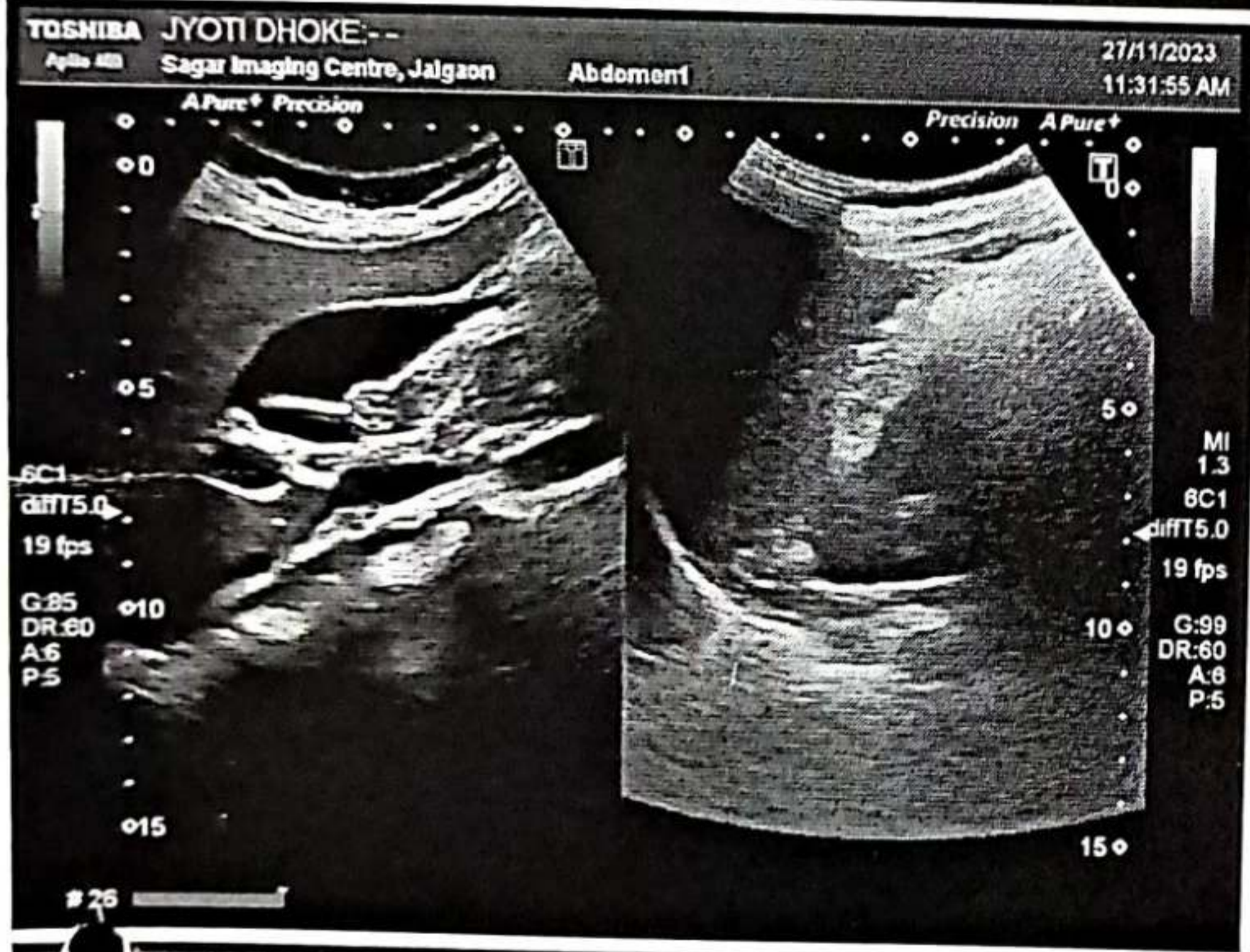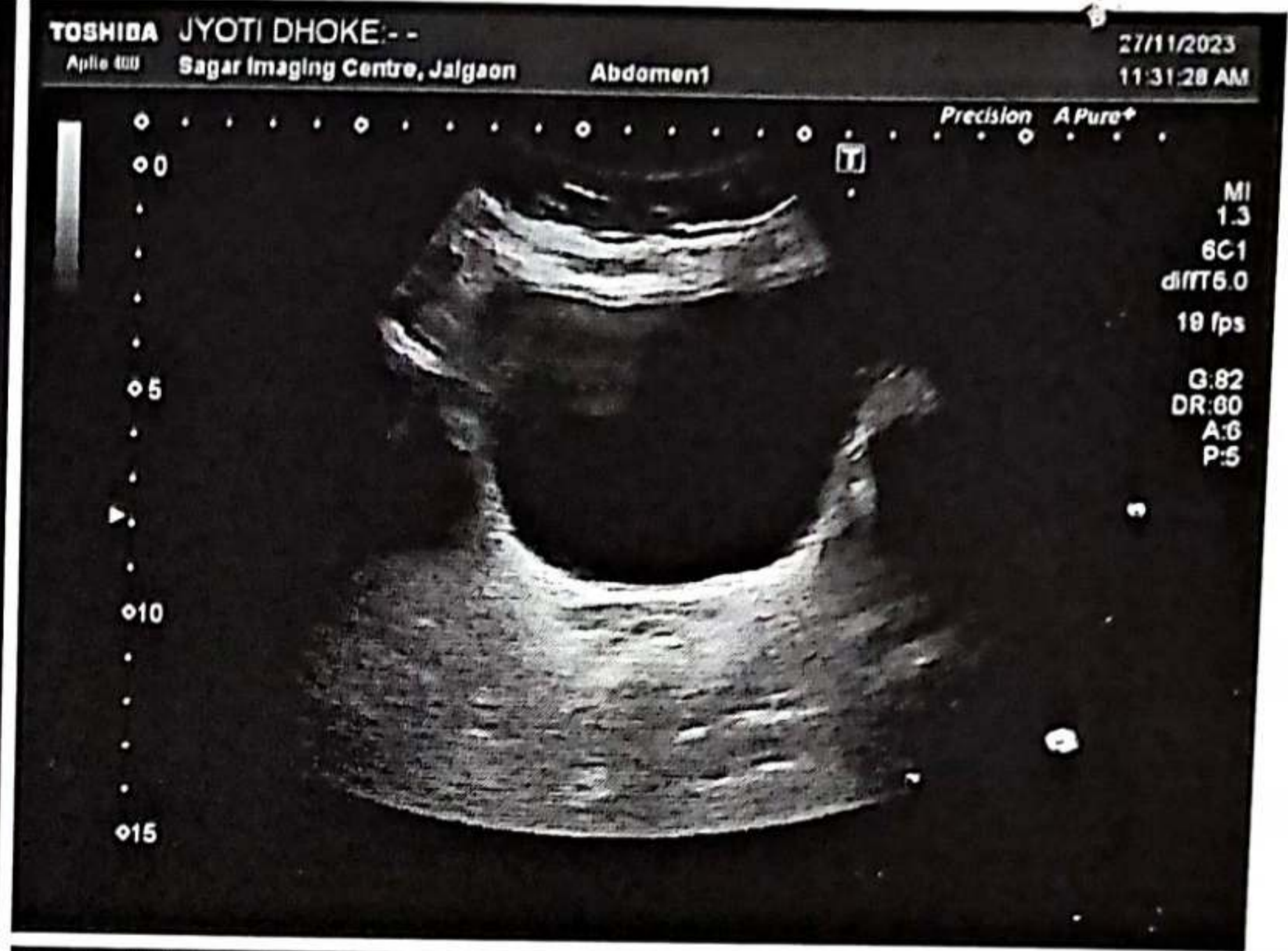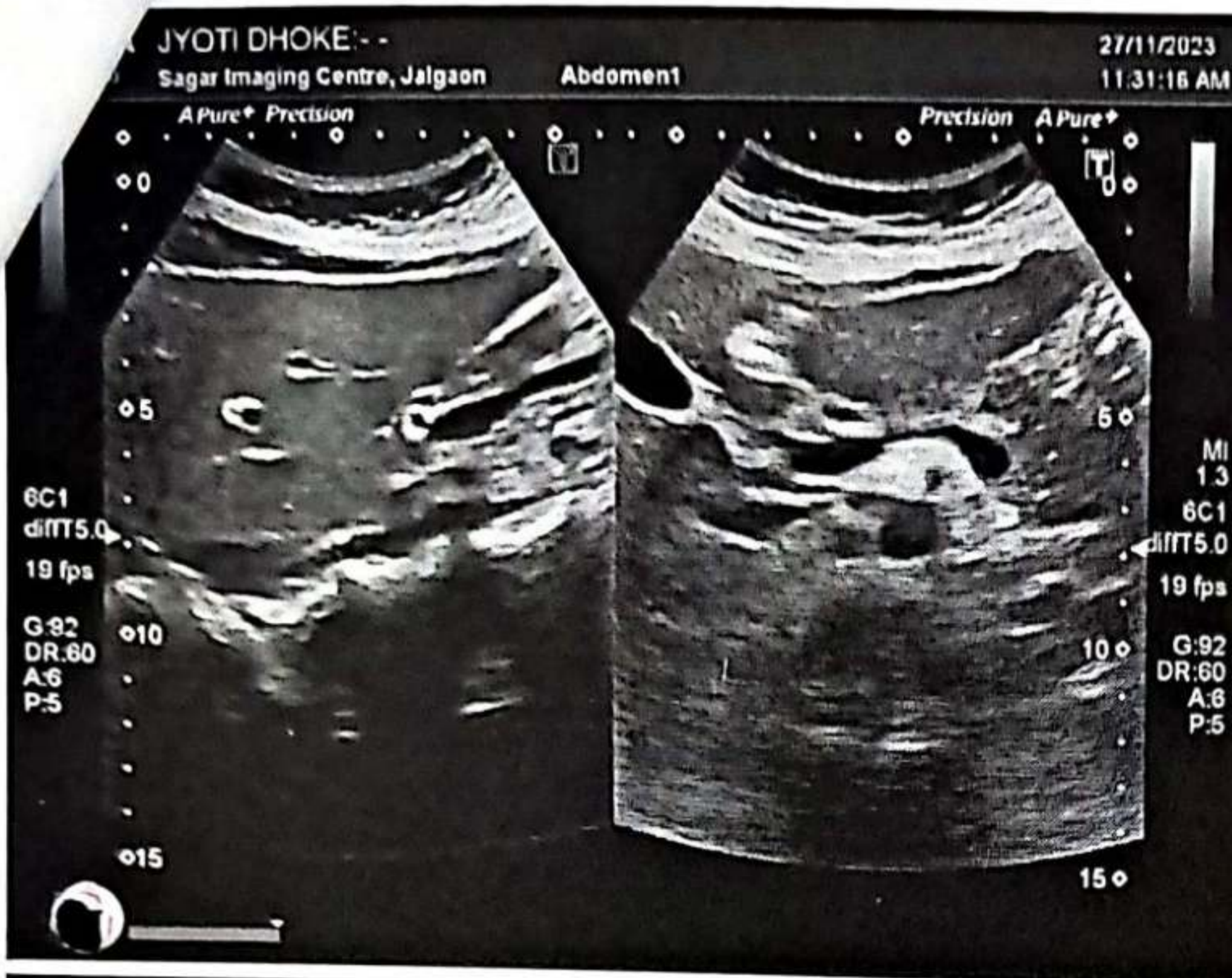No significant abnormality is noted.

REPORT WITH THANKS.

Clinico pathological correlation is suggested.

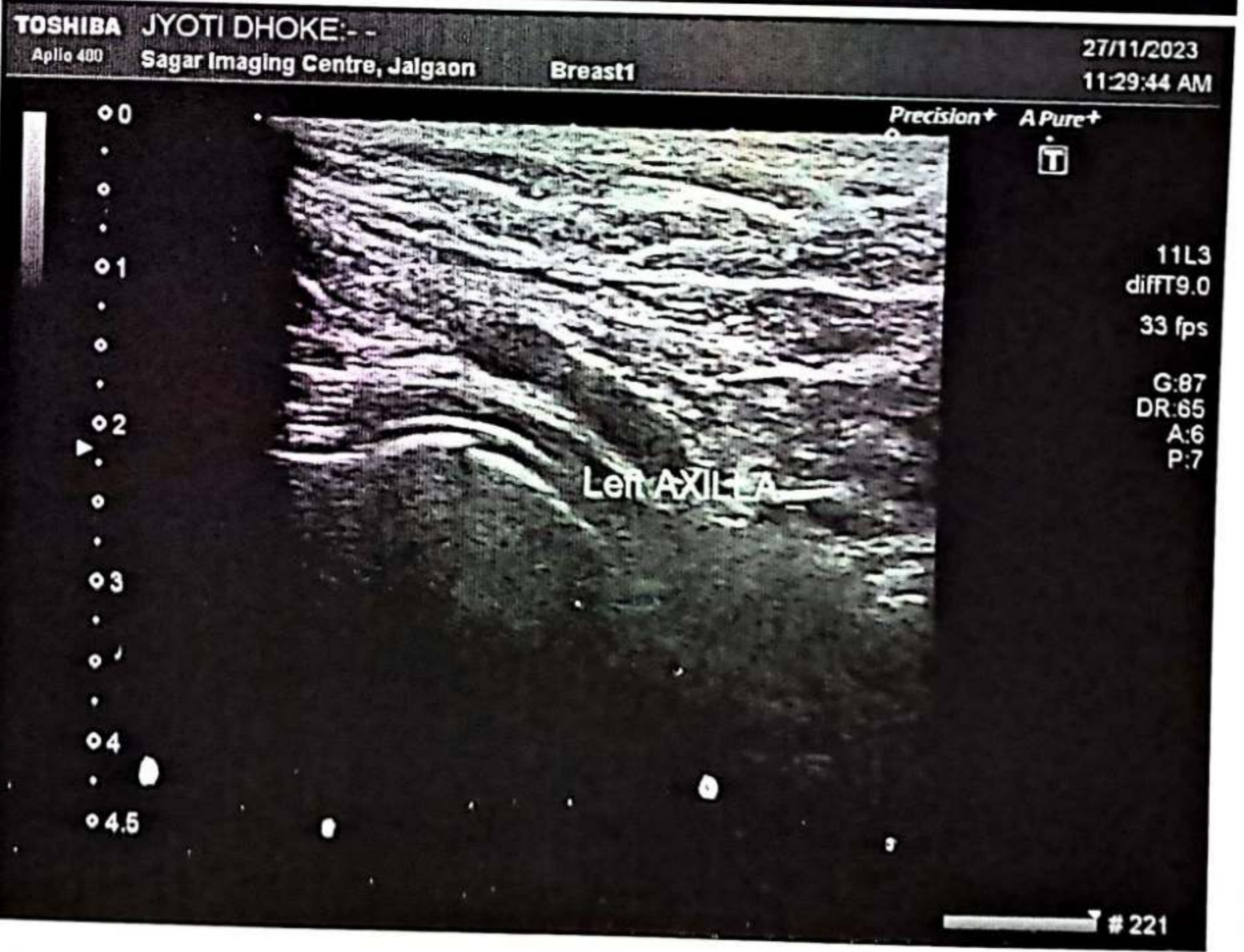
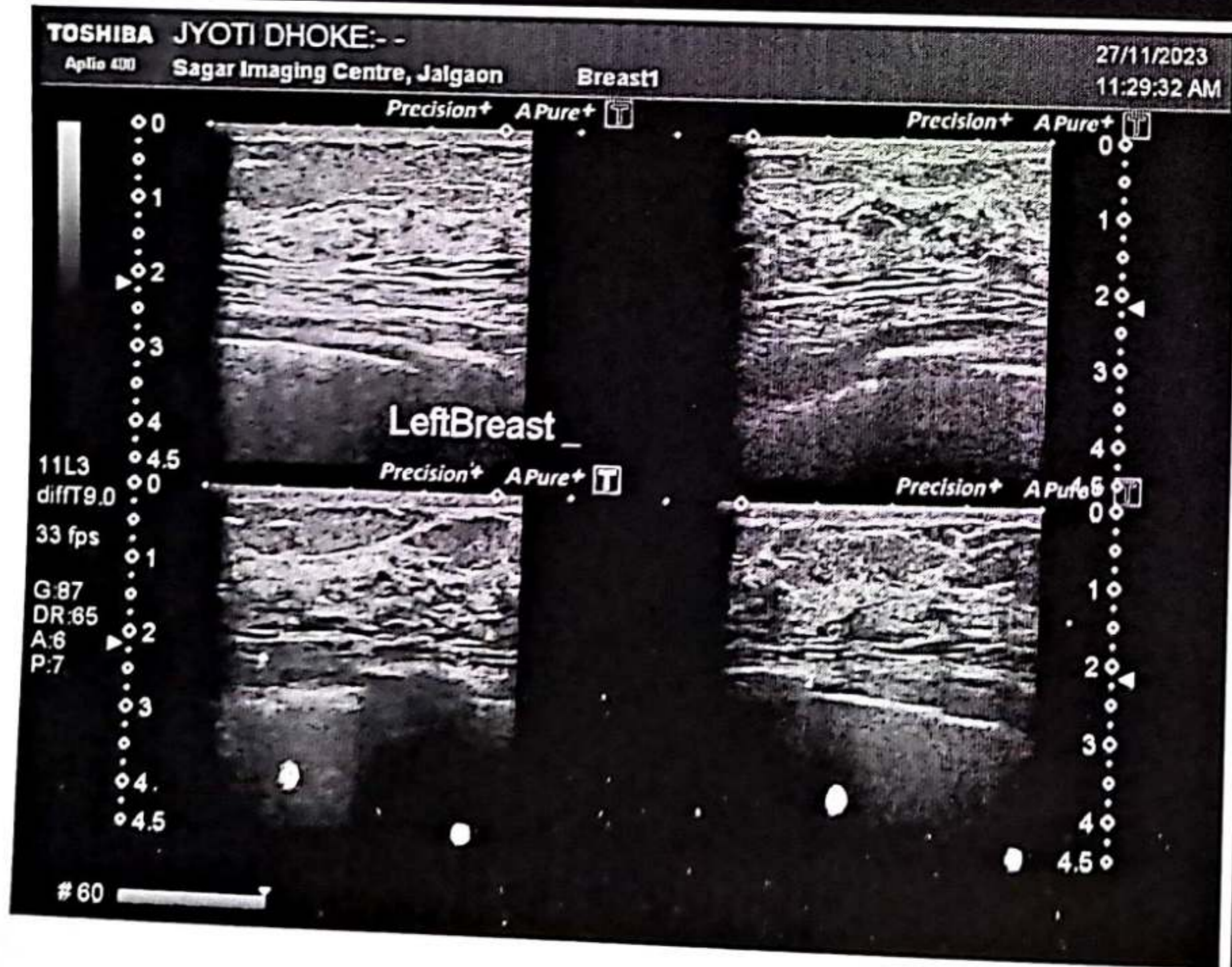
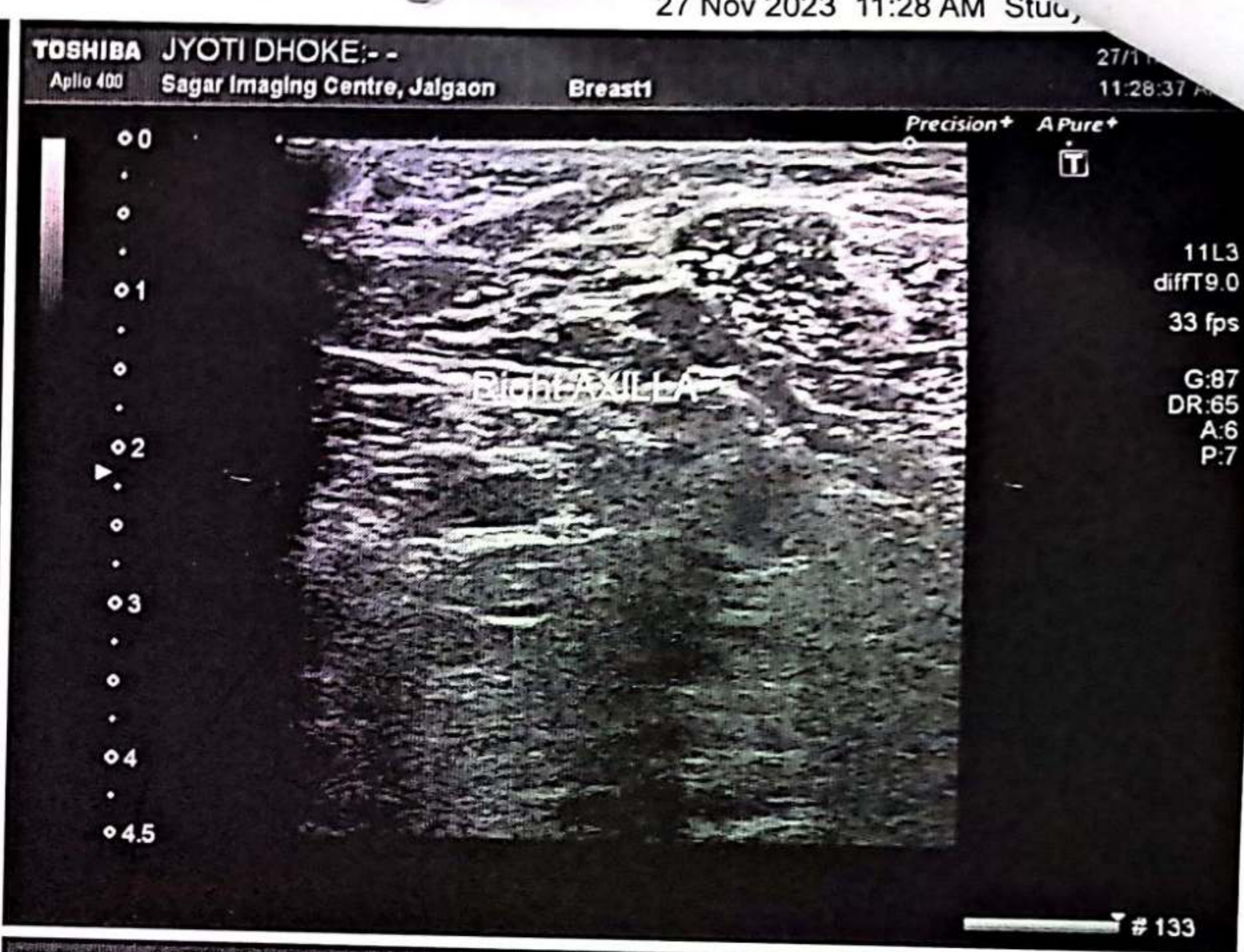
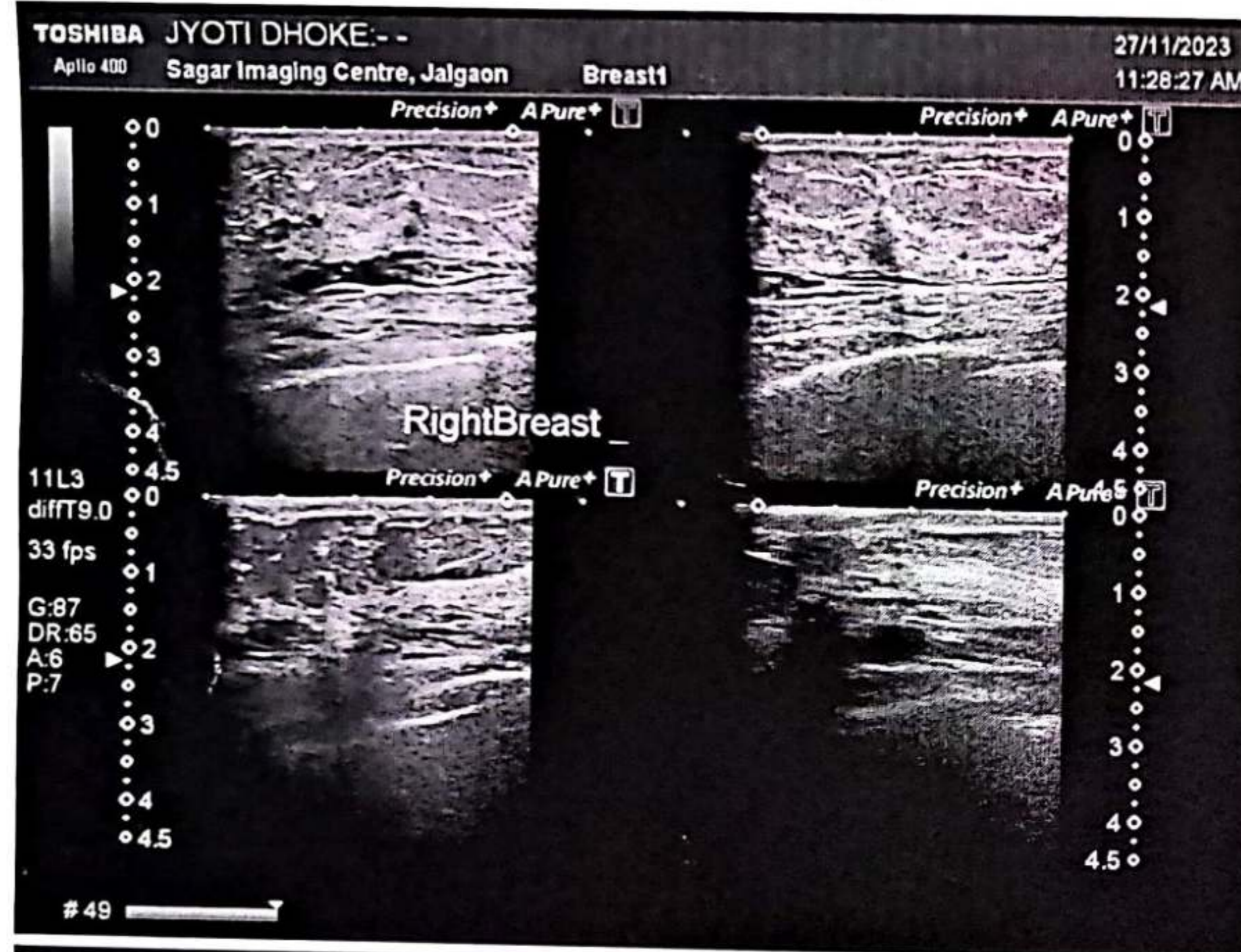
DR. CHETAN KAKLIYA

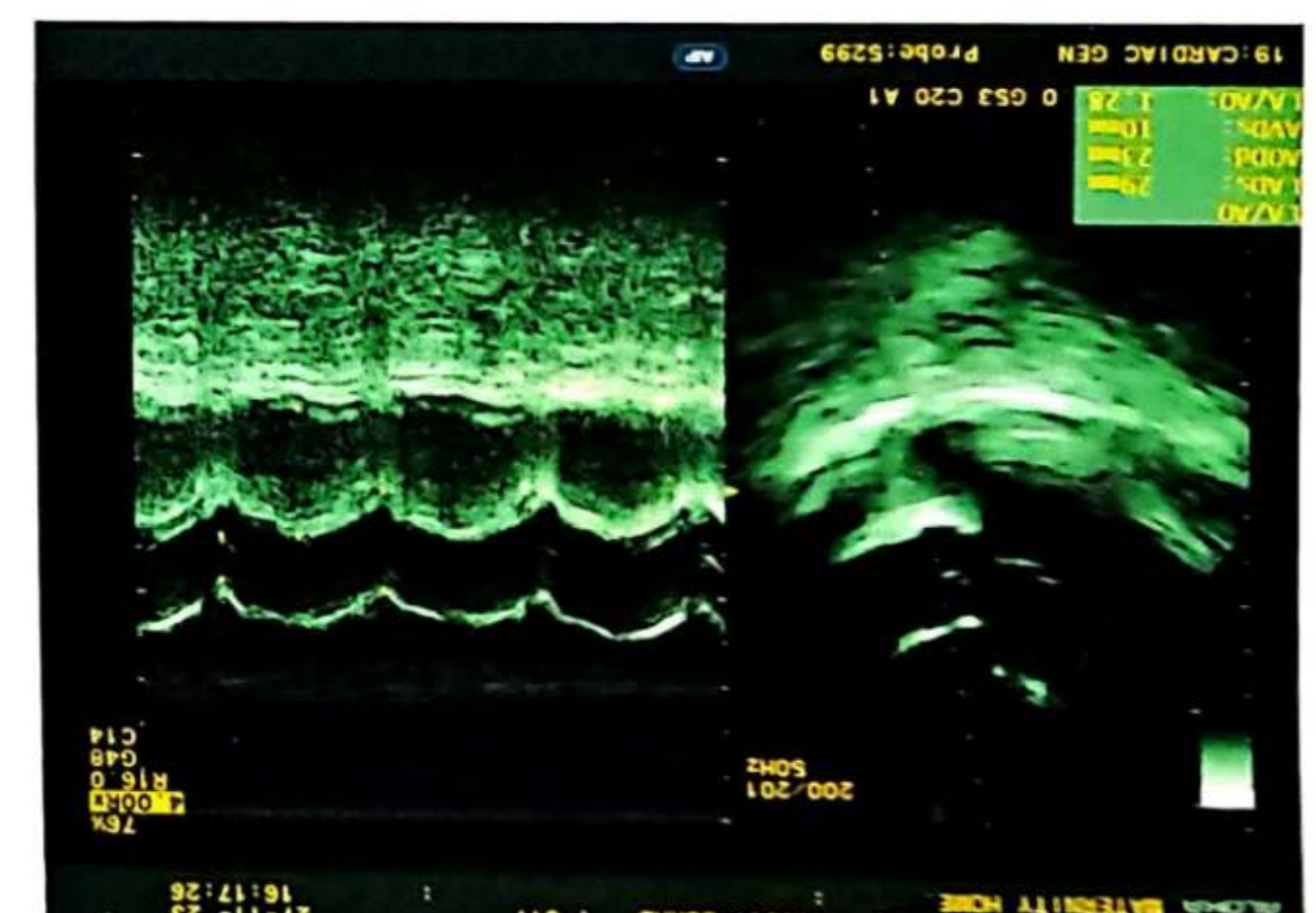
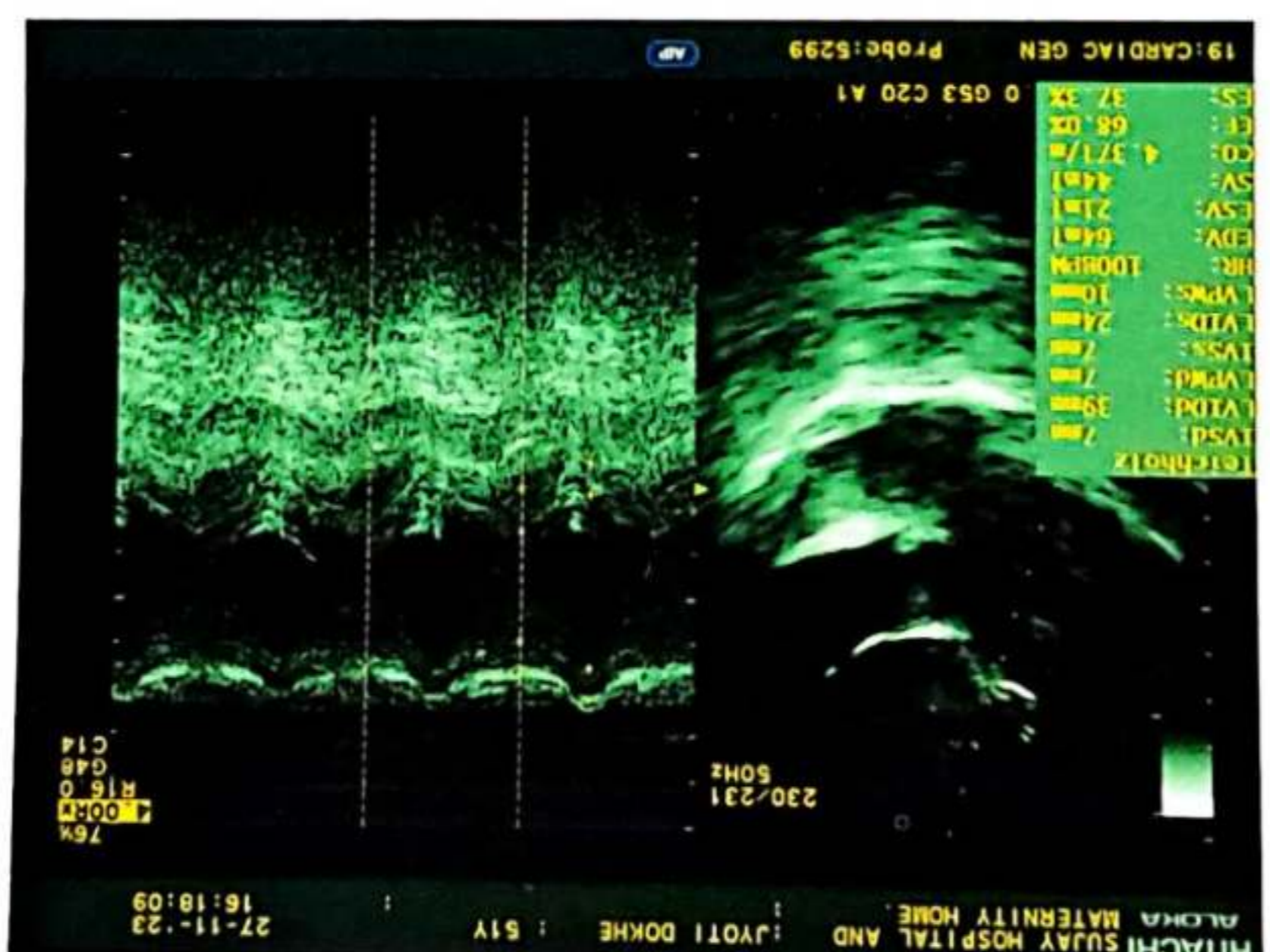
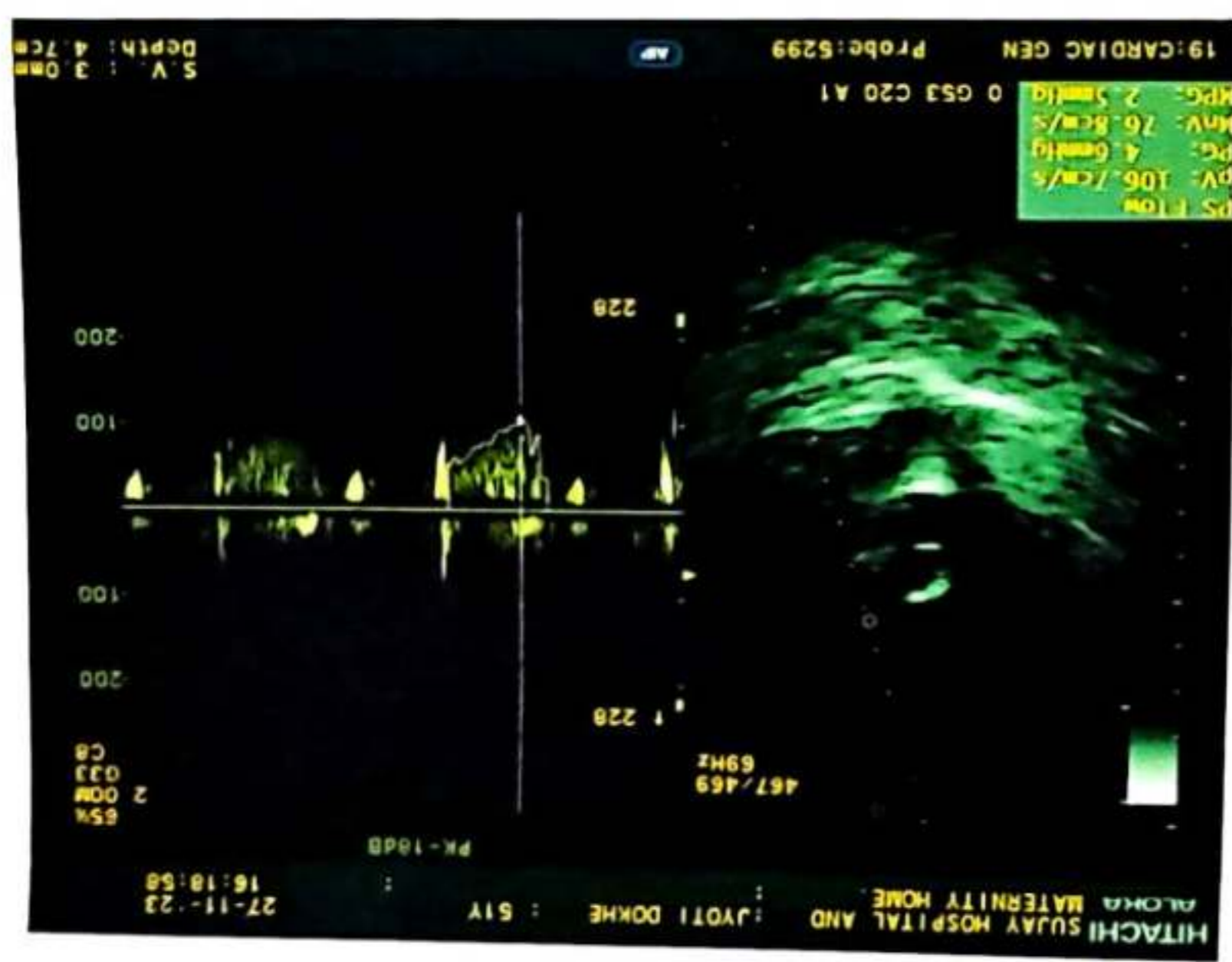
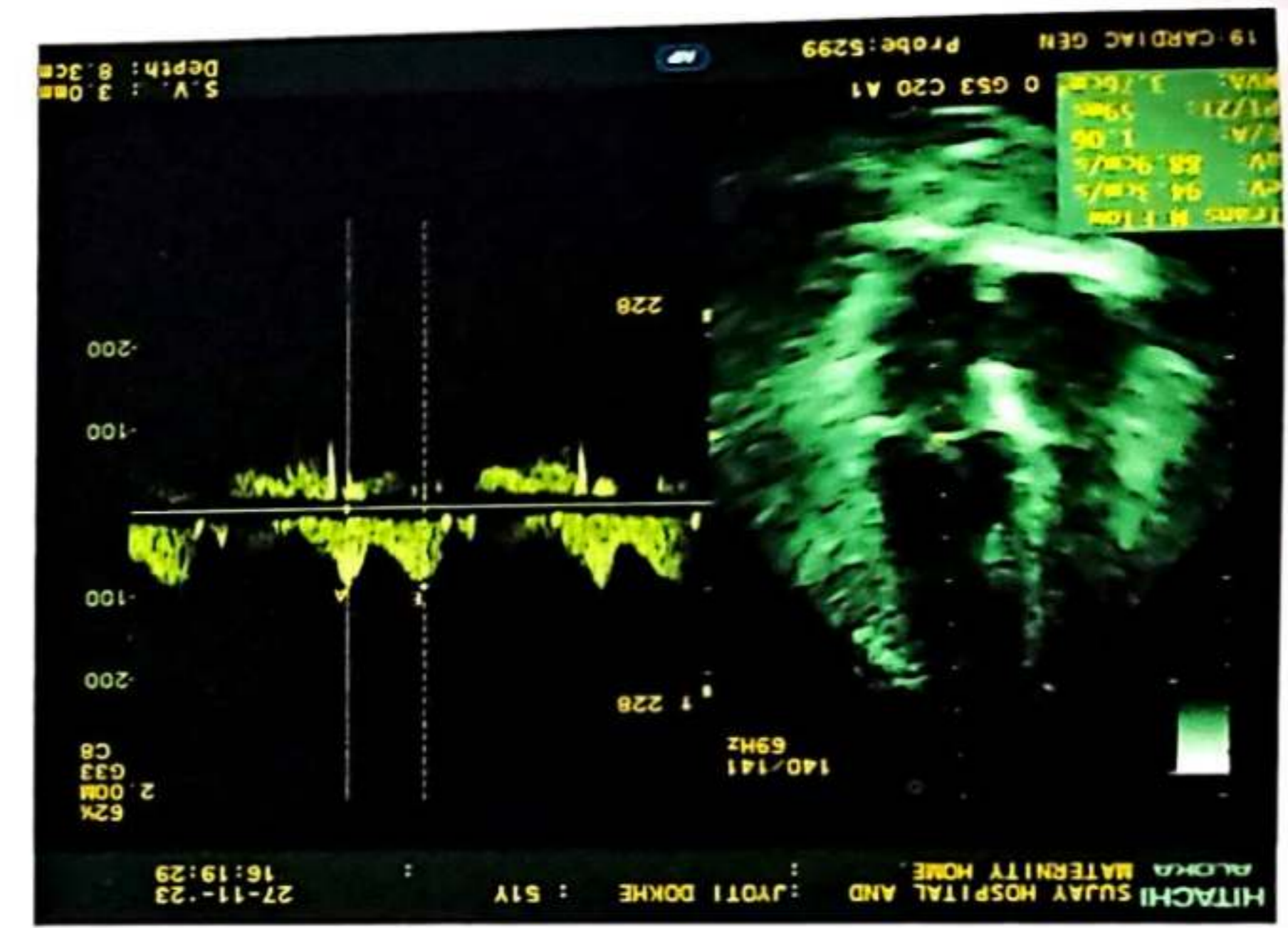
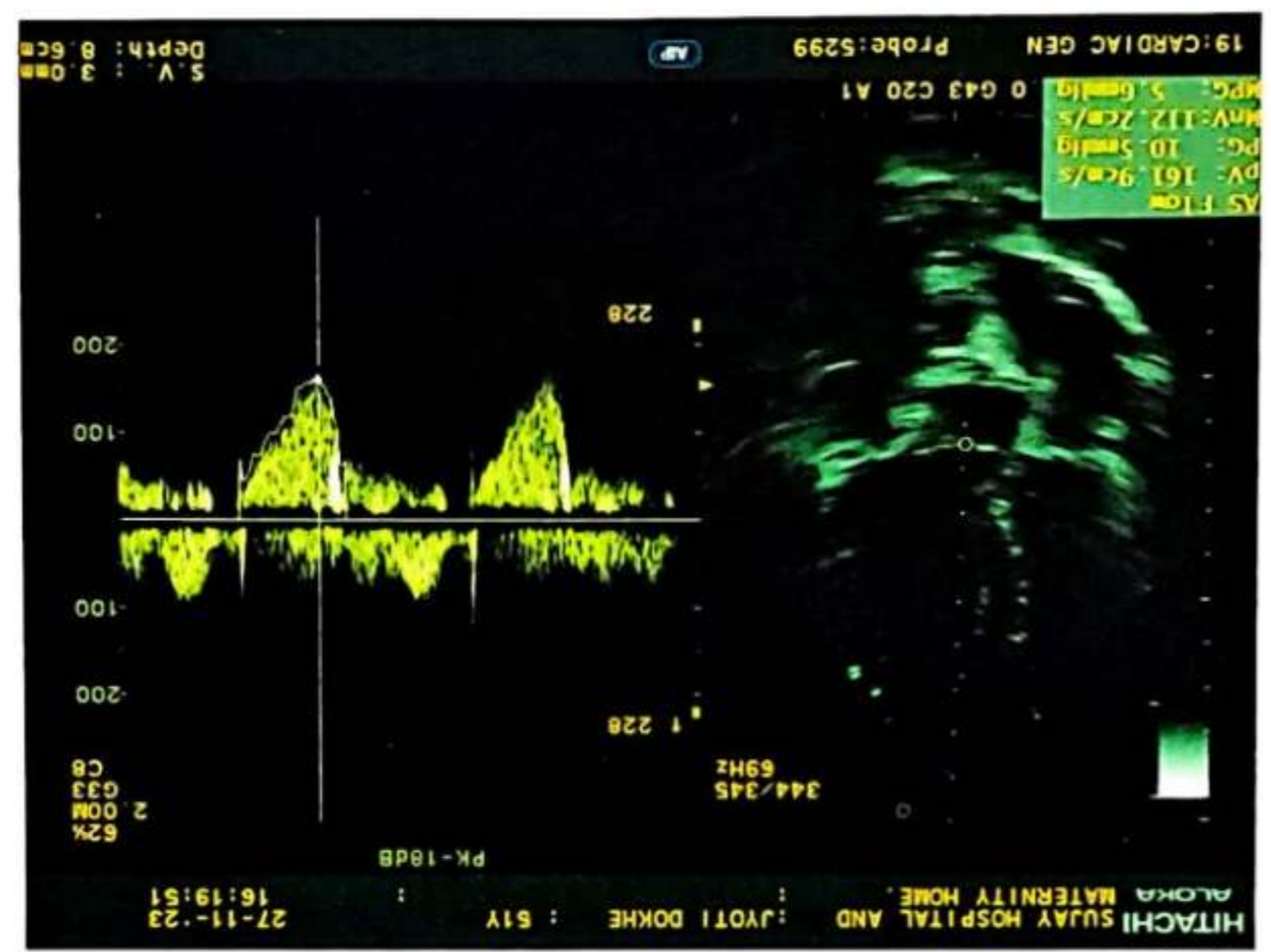
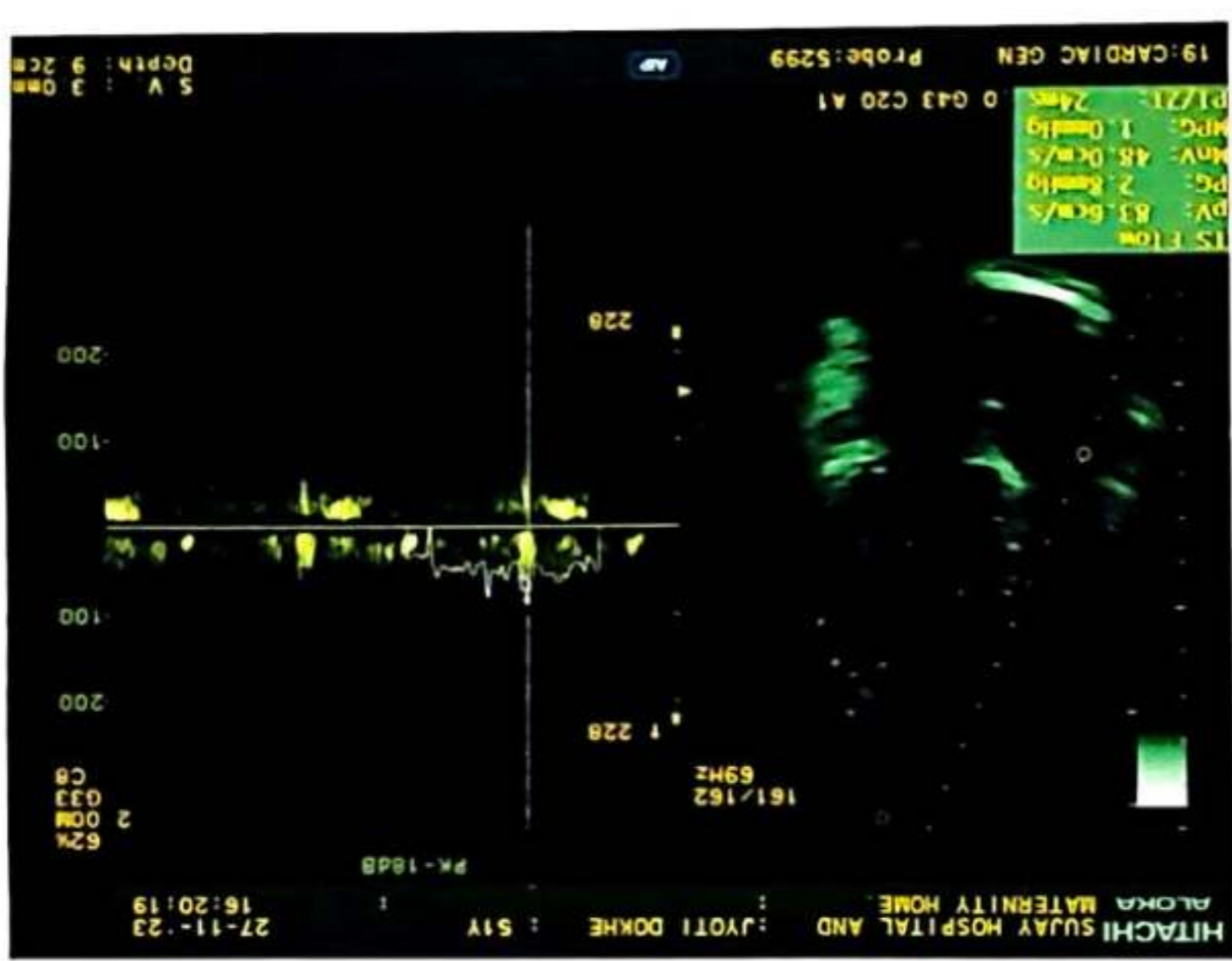




Name : JYOTI DOKHE

27 Nov 2023 11:28 AM Stud





डॉ. सौ. जयश्री सुर्यवंशी
एम.डी.
(स्त्रीरोग व प्रसूतीशास्त्र तज्ञ)
रजि.नं. 3712

डॉ. सुनिल सुर्यवंशी
एम.डी.(मेडिसीन) पुणे
कन्सल्टिंग फिजिशियन
रजि.नं. 2223

पत्ता : मेन टेलिफोन एक्सचेंज समोर, पारिख
पार्क जवळ, नविन बस स्टॅन्डच्या मागे,
जळगाव. फोन : (0257) 2227821

उपलब्ध सुविधा : • एक्स-रे • सोनोग्राफी • इकोकार्डिओग्राफी • सुसज्ज ऑपरेशन थिएटर • कॉम्प्युटराईज्ड इ.सी.जी. • स्ट्रेम टेस्ट • पल्मोनरी फंक्शन टेस्ट

Rx

दि / / २०

2D – ECHOCARDIOGRAPHY

Name – JYOTI DOKHE

Age- 51 Yrs FEMALE

Date – 27/11/2023

IMPRESSION –

NORMAL SIZE CARDIAC CHAMBERS.

STRUCTURALLY NORMAL CARDIAC VALVES.

NORMAL LV SYSTOLIC FUNCTION . EF- 60 %.


NORMAL LV DIASTOLIC FUNCTION .

NO RWMA

NO CLOTS OR VEGETATION.

IAS AND IVS INTACT.

NORMAL PERICARDIUM.


Dr Sunil Suryawanshi
M D medicine.

परत येतांना कागद सोबत आणावा.

सुजाय हॉस्पिटल व मॅटर्निटी होम अतिदक्षता विभाग

डॉ. सौ. जयश्री सुर्यवंशी
एम.बी.
(स्त्रीरोग व प्रसूतीशास्त्र तज्ञ)
रजि.नं. 3712

डॉ. सुनिल सुर्यवंशी
एम.डी. (मेडीसीन) पुणे
कन्सल्टिंग फिजिशियन
रजि.नं. 2223

पत्ता : मेन टेलिफोन एक्सचेंज समोर, पारिख
पार्क जवळ, नविन बस स्टॅण्डच्या मागे,
जळगाव. फोन : (0257) 2227821

उपलब्ध मुविधा : • एक्स-रे • मोनोग्राफी • इकोकार्डिओग्राफी • सुसज्ज ऑपरेशन थिएटर • कॉम्प्युटाईज्ड इ.सी.जी. • स्ट्रेस टेस्ट • एल्फोनी फंक्शन टेस्ट

Rx

दि / / २०

X-RAY CHEST PA VIEW

NAME- JYOTI DOKHE

AGE- 51 YRS FEMALE DATE-27.11.23

SOFT TISSUE AND SKELETON NORMAL.

BOTH HILA ARE NORMAL IN SIZE AND HAVE EQUAL DENSITY.

PROMINENT BRONCHOVASCULAR MARKINGS.

COSTOPHRENIC AND CARDIOPHRENIC ANGLES ARE CLEAR.

THE DOMES OF DIAPHRAGMS ARE NORMAL IN POSITION AND SHOW SMOOTH OUTLINE.

THE PLURAL SPACES ARE NORMAL.

IMPRESSION -

NORMAL XRAY CHEST .

परत येतांना कागद सोबत आणावा.



Manavata

Pathology & Microbiology Laboratory

Dr. Kailash B. Wagh

M.D. Microbiology D.C.P
Reg No. 2001/07/2704

REG NO. : 11-2023-OPD / 8
NAME : Mrs. JYOTI DOKHE
REF BY : Dr . Sunil Suryavanshi (Insurance)
M.D.

AGE : 51 Years
SEX : Female
DATE : 27-Nov-2023

LOCATION :

HAEMOGRAM

TESTS	RESULTS	UNIT	REFERENCE RANGE
Haemoglobin	: 13.3	g/dl	11 - 18
WBC COUNT			
Total WBC Count	: 6900	/cmm	4000 - 11000
DIFFERENTIAL COUNT			
Neutrophil	: 65	%	40 - 74
Lymphocyte	: 30	%	15 - 45
Eosinophil	: 02	%	0 - 7
Monocyte	: 03	%	1 - 10
Basophil	: 00	%	0 - 1
RBC INDICES			
Hct	: 39.9	%	33 - 60
R.B.C. count	: 4.56	mil./cmm.	4.0 - 6.0
Mcv	: 84.2	fL	76 - 94
Mch	: 29.3	pg	25 - 33
Mchc	: 33.1	%	32 - 38
PLATELETS INDICES			
Plt Count	: 185000	/cmm	150000 - 450000
RBC Morphology	: Normocytic Normocytic		
WBC Studies	: Normal Morphology		
Platelet	: Adequate		
ESR	: 12	mm/hr	00 - 20

THANKS FOR REFERRAL



K.B.W.
Dr. Kailash B. Wagh
MD (Micro) DCP

Dr. Kailash B. Wagh
M.D. Microbiology D.C.P.
Reg. No. 2001/07/2704

98 Jilha Peth, Kantai Sabhagruh Road, Near Barde Medical, Jalgaon- 425001

☎ 0257-2970978, 2225322 ☎ 9405887735



Scanned with OKEN Scanner



Manavata

Pathology & Microbiology Laboratory

Dr. Kailash B. Wagh
M.D. Microbiology D.C.P
Reg No. 2001/07/2704

REG NO. : 11-2023-OPD / 8
NAME : Mrs. JYOTI DOKHE
REF BY : Dr . Sunil Suryavanshi (Insurance)
M.D.

AGE : 51 Years
SEX : Female
DATE : 27-Nov-2023

LOCATION :

BLOOD GROUP

TESTS

BLOOD GROUP

RESULTS

UNIT

: "B" Rh Positive

NOTE

: Grouping and cross matching is compulsory before blood transfusion, as errors can occur due to irregular antibodies.

HBA1C

TESTS

HbA1C

RESULTS

UNIT

: 8.9

%

AVERAGE BLOOD SUGAR
(ABG)

: 209

mg/dl

Reference Range :

Below 6.0% - Normal Value
6.0% - 7.0% - Good Control
7.0% - 8.0% - Fair Control
8.0% - 10% - Unsatisfactory Control
Above 10% - Poor Control

Method : Fully Automated H.P.L.C. using Blorad Variant II Turbo, NGSP Certified.

Please correlate with clinical conditions.

KBW
Dr. Kailash B. Wagh
MD (Micro) DCP

THANKS FOR REFERRAL

Dr. Kailash B. Wagh
M.D. Microbiology D.C.P.
Reg. No. 2001/07/2704



98 Jilha Peth, Kantai Sabhagruh Road, Near Barde Medical, Jalgaon- 425001

0257-2970978, 2225322 9405887735



Scanned with OKEN Scanner



Manavata

Pathology & Microbiology Laboratory

Dr. Kailash B. Wagh
M.D. Microbiology D.C.P
Reg No. 2001/07/2704

REG NO. : 11-2023-OPD / 8
NAME : Mrs. JYOTI DOKHE
REF BY : Dr . Sunil Suryavanshi (Insurance)
M.D.

AGE : 51 Years
SEX : Female
DATE : 27-Nov-2023

LOCATION :

BLOOD SUGAR FASTING & POST-PRANDIAL

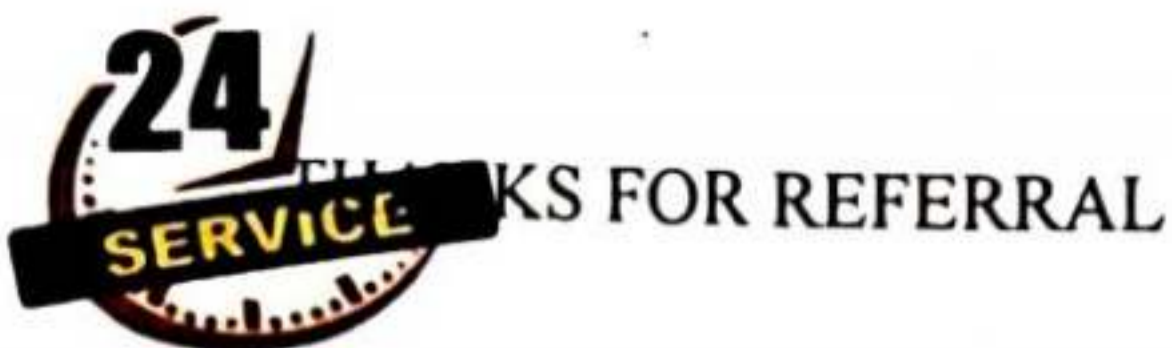<u>TESTS</u>	<u>RESULTS</u>	<u>UNIT</u>	<u>REFERENCE RANGE</u>
BLOOD SUGAR FASTING	: 118	mg/dl	70 - 110
URINE SUGAR FASTING	: Prasant {+}		
BLOOD SUGAR PP	: 224	mg/dl	70 - 140
URINE SUGAR PP	: Prasant{++}		

LIVER FUNCTION TEST

<u>TESTS</u>	<u>RESULTS</u>	<u>UNIT</u>	<u>REFERENCE RANGE</u>
BILIRUBIN- TOTAL	: 0.88	mg/dl	0 - 1.0
BILIRUBIN- DIRECT	: 0.23	mg/dl	0 - 0.3
BILIRUBIN- INDIRECT	: 0.65	mg/dl	0.1 - 1.0
SGPT	: 19	IU/L	0 - 40
SGOT	: 25	IU/L	0 - 45
ALKALINE PHOSPHATASE	: 123	IU/L	25 - 350
TOTAL PROTIEN	: 6.10	gm/dl	6 - 8
ALBUMIN	: 3.84	gm/dl	3.5 - 5
GLOBULIN	: 2.26	gm/dl	2 - 3.5
A/G Ratio	: 2.01		2 - 2.5
GGTP	: 13	IU/l	0 - 25

K.B.W.
Dr. Kailash B. Wagh

MD (Micro) DCP
Dr. Kailash B. Wagh
M.D. Microbiology D.C.P.
Reg. No. 2001/07/2704



98 Jilha Peth, Kantai Sabhagruh Road, Near Barde Medical, Jalgaon- 425001
0257-2970978, 2225322 9405887735



Manavata

Pathology & Microbiology Laboratory

Dr. Kailash B. Wagh
M.D. Microbiology D.C.P
Reg No. 2001/07/2704

REG NO. : 11-2023-OPD / 8
NAME : Mrs. JYOTI DOKHE
REF BY : Dr . Sunil Suryavanshi (Insurance)
M.D.

AGE : 51 Years
SEX : Female
DATE : 27-Nov-2023

LOCATION :

KIDNEY FUNCTION TEST

<u>TESTS</u>	<u>RESULTS</u>	<u>UNIT</u>	<u>REFERENCE RANGE</u>
BLOOD UREA NITROGEN	: 19	mg/dl	5 - 21
CREATININE	: 0.81	mg/dl	0.7 - 1.4
URIC ACID	: 3.14	mg/dl	2.6 - 6.0

LIPID PROFILE

<u>TESTS</u>	<u>RESULTS</u>	<u>UNIT</u>	<u>REFERENCE RANGE</u>
TOTAL CHOLESTEROL	: 197	mg/dl	140 - 250
TRIGLYCERIDES	: 85	mg/dl	40 - 140
HDL- CHOLESTEROL	: 49	mg/dl	32 - 90
LDL- CHOLESTEROL	: 131	mg/dl	80 - 150
VLDL-CHOLESTEROL	: 17	mg/dl	10 - 35
TOTAL CHO/HDL RATIO	: 4.02		0 - 5.1
LDL/HDL RATIO	: 2.67	mg/dl	0 - 3.5
NON HDL CHOLESTEROL	: 148	mg/dl	0 - 160

THANKS FOR REFERRAL

KBW
Dr. Kailash B. Wagh
MD (Micro) DCP

Dr. Kailash B. Wagh
M.D. Microbiology D.C.P.
Reg. No. 2001/07/2704



98 Jilha Peth, Kantai Sabhagruh Road, Near Barde Medical, Jalgaon- 425001

0257-2970978, 2225322 9405887735



Scanned with OKEN Scanner



Manavata

Pathology & Microbiology Laboratory

Dr. Kailash B. Wagh
M.D. Microbiology D.C.P
Reg No. 2001/07/2704

REG NO. : 11-2023-OPD / 8
NAME : Mrs. JYOTI DOKHE
REF BY : Dr . Sunil Suryavanshi (Insurance)
M.D.


AGE : 51 Years
SEX : Female
DATE : 27-Nov-2023

LOCATION :

THYROID TEST

<u>TESTS</u>	<u>RESULTS</u>	<u>UNIT</u>	<u>REFERENCE RANGE</u>
T3	: 115	ng/ml	87 - 178
T4	: 7.89	µg/dl	6.06 - 12.23
ULTRA TSH	: 2.158	µIU/ml	0.34 - 5.6
NOTE	: Test Done On Fully Automated Mindray CL 900i Hormone Assay BY CLIA		

THANKS FOR REFERRAL


Dr. Kailash B. Wagh
MD (Micro) DCP

Dr. Kailash B. Wagh
M.D. Microbiology D.C.P.
Reg. No. 2001/07/2704



9 98 Jilha Peth, Kantai Sabhagruh Road, Near Barde Medical, Jalgaon- 425001
☎ 0257-2970978, 2225322 ☑ 9405887735



Scanned with OKEN Scanner



Manavata

Pathology & Microbiology Laboratory

Dr. Kailash B. Wagh
M.D. Microbiology D.C.P
Reg No. 2001/07/2704

REG NO. : 11-2023-OPD / 8
NAME : Mrs. JYOTI DOKHE
REF BY : Dr . Sunil Suryavanshi (Insurance)
M.D.

AGE : 51 Years
SEX : Female
DATE : 27-Nov-2023

LOCATION :

URINE ANALYSIS REPORT

<u>TESTS</u>	<u>RESULTS</u>	<u>UNIT</u>	<u>REFERENCE RANGE</u>
PHYSICAL EXAMINATION			
QUANTITY	: 10 ml		
COLOUR	: Pale Yellow		
APPEARANCE	: Clear		
DEPOSITS	: Absent		
SPECIFIC GRAVITY	: 1.015		1.002 - 1.030
REACTION (PH)	: Acidic		
CHEMICAL EXAMINATION			
PROTEINS	: Absent		
SUGAR	: Prasant{++}		
KETONE	: Absent		
BILE SALTS/BILE PIGMENTS	: Absent		
MICROSCOPIC EXAMINATION			
RBC	: Absent	/hpf	
PUS CELLS	: 2-3	/hpf	
EPITHELIAL CELLS	: Occasional	/hpf	
CASTS	: Absent		
CRYSTALS	: Absent		
AMORPHOUS DEPOSITS	: Absent		

THANKS FOR REFERRAL

K.B.W.
Dr. Kailash B. Wagh
MD (Micro) DCP

Dr. Kailash B. Wagh
M.D. Microbiology D.C.P.
Reg. No. 2001/07/2704



98 Jilha Peth, Kantai Sabhagruh Road, Near Barde Medical, Jalgaon- 425001

☎ 0257-2970978, 2225322 ☎ 9405887735



Scanned with OKEN Scanner



Manavata

Pathology & Microbiology Laboratory

Dr. Kailash B. Wagh
M.D. Microbiology D.C.P
Reg No. 2001/07/2704

REG NO. : 11-2023-OPD / 8
NAME : Mrs. JYOTI DOKHE
REF BY : Dr . Sunil Suryavanshi (Insurance)
M.D.


AGE : 51 Years
SEX : Female
DATE : 27-Nov-2023

LOCATION :

STOOL EXAMINATION

<u>TESTS</u>	<u>RESULTS</u>	<u>UNIT</u>
PHYSICAL EXAMINATION		
COLOUR	: Brown	
CONSISTENCY	: Soft	
FRANK BLOOD	: Absent	
CHEMICAL EXAMINATION		
REACTION	: Alkaline	
OCCULT BLOOD	: Absent	
REDUCING SUBSTANCES	: Absent	
MICROSCOPIC EXAMINATION		
RBC	: Absent	/hpf
PUS CELLS	: 3-4	/hpf
EPITHELIAL CELLS	: 2-3	/hpf
MACROPHAGES	: Absent	/hpf
OVA/LARVAE	: Nil	
FAT GLOBULES	: Absent	
CYSTS	: Nil	
Veg. cells / Fibres	: Nil	/hpf
Bacteria	: Nil	

THANKS FOR REFERRAL


Dr. Kailash B. Wagh
MD (Micro) DCP

Dr. Kailash B. Wagh
M.D. Microbiology D.C.P.
Reg. No. 2001/07/2704



98 Jilha Peth, Kantai Sabhagruh Road, Near Barde Medical, Jalgaon- 425001
0257-2970978, 2225322 9405887735



Scanned with OKEN Scanner

सुजय हॉस्पिटल व मॅटर्निटी होम

अतिदक्षता विभाग

डॉ. सौ. जयश्री सुर्यवंशी
एम.डी.
(स्त्रीरोग व प्रसूतीशास्त्र तज्ञ)
रजि.नं. 3712

डॉ. सुनिल सुर्यवंशी
एम.डी.(मेडिसीन) पुणे
कनराल्टींग फिजिशियन
रजि.नं. 2223

पत्ता : मेन टेलिफोन एक्सचेंज समोर, पारिख
पार्क जवळ, नयिन बस स्टॅन्डच्या मागे,
जळगांव. फोन : (0257) 2227821

उपलब्ध सुविधा : • एक्स-रे • सोनोग्राफी • इकोकार्डिओग्राफी • सुसज्ज ऑपरेशन थिएटर • कॉम्प्युटाईज्ड इ.सी.जी. • स्ट्रॅम टेस्ट • पल्मोनरी फंक्शन टेस्ट

Rx

दि 27 / 11 / 2023

PHYSICIAN CONSULTATION

MRS JYOTI DOKHE, 51 YRS FEMALE

● NO CARDIORESPIRATORY COMPLAINTS.

● K/C/O DM UNDER RX

NOT A K/C/O HT, IHD, ASTHAMA

NO ALLERGY TO ANY MEDICATIONS. NO ADDICTION.

HYSTERECTOMY 2011

P-72/ MIN, BP-120/70 mmHg

RS/CVS/PA/CNS- NORMAL

● DENTAL CONSULTATION- NORMAL

● EYE CHECK UP- NORMAL .

ENT CHECK UP- NORMAL.

DIET- BALANCED DAIBETIC DIET

BMI- 24.7


Jyoti


परत येतांना कागद मोलत आणायला



Scanned with OKEN Scanner



 **GPS Map Camera**



Jalgaon, Maharashtra, India

A4/1321, RR School Rd, Old B J Market, Omkar Nagar, Sbi Colony, Jalgaon, Maharashtra 425001, India

Lat 21.006357°

Long 75.566927°

27/11/23 09:17 AM GMT +05:30


आयकर विभाग
INCOME TAX DEPARTMENT



भारत सरकार
GOVT. OF INDIA



स्थायी लेखा संख्या कार्ड
Permanent Account Number Card
ANQPD4255R



नाम / Name
JYOTI SUDHAKAR DOKHE

पिता का नाम / Father's Name
HIRAMAN PARSHURAM PATIL

जन्म की तारीख /
Date of Birth
15/03/1972

डॉ. ज्योति सुधाकर डोके

हस्ताक्षर / Signature



Blood test
ECG
X-R

Client Contact No: 9403384515
Agent contact No:

Name/नाव- श्री शोभा रघुवाकर डोरे

Personal information (वैयक्तिक माहिती)

Age/ वय- 51 age/जन्मतारीख 15/03/1972

Any habit/सवयी - NO

Identification Mark:- दाया बाजूला बाळाकर Tab 8 years => Tab Glimstar 1B.D

Any disease like diabetes, blood pressure, /आजार डायबेटीज, ब्लड प्रेशर, इतर

Any surgery/ operation/ accident during last 5 years/मागच्या 5 वर्षांत एखादे ऑपरेशन

Family history/कुटुंबाविषयी माहिती

Father/वडील श्रीराम पद्मराज प्रिण्ठ

8 => 29 yrs
Gr A2L1R2
1 still birth
Myterectomy. in 2011.

✓ Live/हयात Age/वय 65 Disease/काहीआजार नाही

Death/मृत ✓

Age When died/त्यावेळेस वय Cause/कारण

Mother/आई सावित्री श्रीराम प्रिण्ठ

Live/हयात Age/वय Cause/कारण

Age When died/ त्यावेळेस वय Cause/कारण

Brother/भाऊ Age/वय

Disease/ health/आजार/निरोग

Sister/बहीण Age/वय

Disease/health/आजार/निरोगी

covid vaccine type
1 st dose ✓ covid shikwa

2nd dose ✓

education 10th पास

occupation घरकाम

married

Signature: [Signature]

[Signature]

HOSPITAL USE ONLY
Height: 148
Weight: 54.
Chest: 82
Abdomen: 77
Blood Pressure: 120/70 80/min

• ENT - Normal
• Dental Normal
• Eye Normal
• Diet: low fat low carbohydrate diet