

GULATI HOSPITAL

169, Sarojini Colony, Near Bus Stand,
YAMUNA NAGAR - 135 001

Dr. J.K. Gulati

M.D., D.N.B. (AIIMS, New Delhi)
Consultant Physician & Heart Specialist

Dr. Sarita Gulati

D.G.O., DCH (Gynaecologist)
Ex. SMO, Civil Hospital, YNR.

Ravi Mehal 45 M

11.09.22

General Exam - NAD

• No specific complaints

• Pulse - 84/min

• BP = 130/80

• No anaemia / conjunctiva / Tarsal / edema

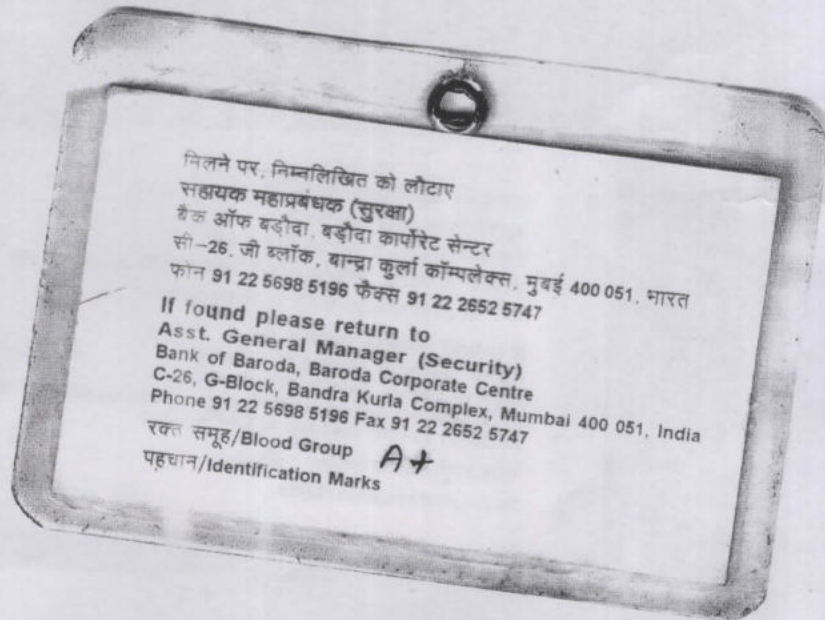

Chest - 6/6 vesicular breathing

CVS - S₁, S₂ AB

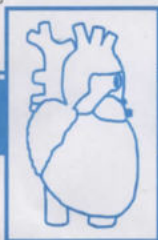Abd - NAD

Lungs - no abnormalities

DR. J.K. GULATI
MC, DNB
GULATI HOSPITAL
Near Bus Stand, Yamuna Nagar



Dr. J.K. Gulati
DR. J.K. GULATI
MD, DNB
GULATI HOSPITAL
Near Bus Stand, Yamuna Nagar



GULATI HOSPITAL

169, Sarojini Colony, Near Bus Stand,
YAMUNA NAGAR - 135 001

Dr. J.K. Gulati

M.D., D.N.B. (AIIMS, New Delhi)
Consultant Physician & Heart Specialist

Dr. Sarita Gulati

D.G.O., DCH (Gynaecologist)
Ex. SMO, Civil Hospital, YNR.

ULTRASONOGRAPHY

NAME MR RAVI NAGPAL , AGE & SEX 45 M 11.09.22

LIVER

Liver shows normal echopattern with normal vasculature and intrahepatic biliary radical pattern. No mass or abscess is seen.

GALL BLADDER

It shows normal echopattern with normal smooth wall. No evidence of hyperechoic shadow or acoustic shadow is seen in the region.

PANCREAS

Pancreas shows normal echo pattern.

KIDNEYS

Both kidneys show normal echotexture with well demarcated corticomedullary Junction. Left kidney shows a calculus measuring 5.2 MM in the middle calyx.. Right kidney shows a cortical cyst measuring 25x22 mm..

SPLEEN

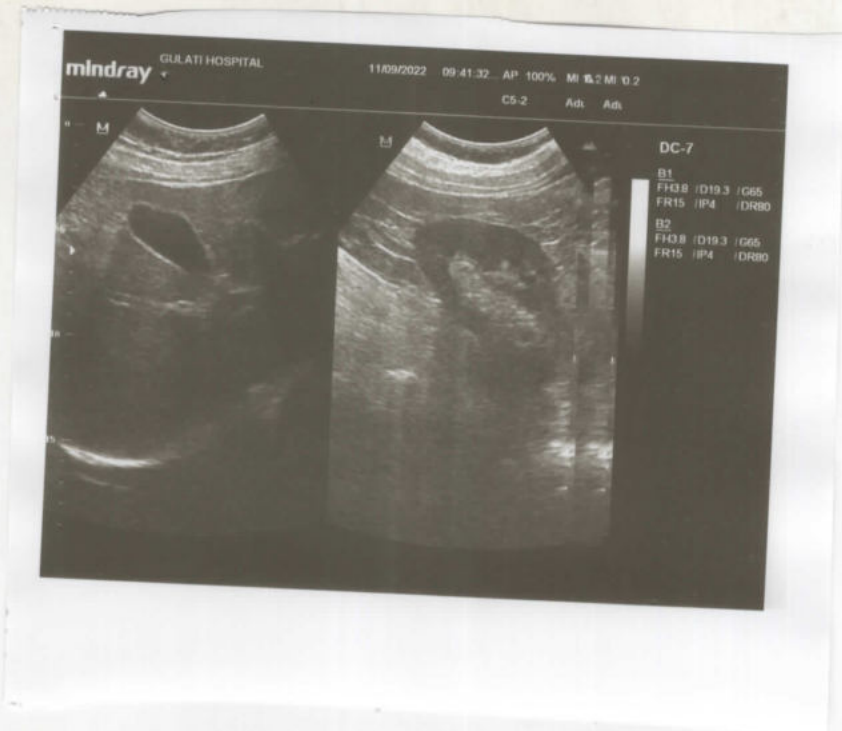No abnormal echoes detected from the splenic area.

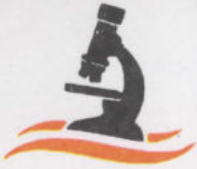URINARY BLADDER

Well distended with slightly smooth wall.

CONCLUSION :LEFT RENAL CALCULUS, RIGHT RENAL CYST


DR. J.K. GULATI
MD, DNB
GULATI HOSPITAL
Near Bus Stand, Yamuna Nagar





K.V. CLINICAL COMPUTERISED LABORATORY

Inside

GULATI HOSPITAL

169, Sarojini Colony, Phase-I, YAMUNA NAGAR - 135 001

Equipped with Latest Computerised Analyzer (CBA-300)

NAME MR. RAVI NAGPAL

DATE 11.09.2022

BLOOD PROFILE

TEST	RESULT	NORMAL VALUE
B. Sugar-F	85.0mg%	70-110mg%
B. Sugar-PP	105.0mg%	70-140mg%
HbA1C	4.8 %	<6 %
Blood Group	'A' +VE	
S.CREATININE	1.1mg%	0.1 -1.5mg%
B.U N	16.0mg%	10-20mg%
S. Uric Acid	5.8mg%	3.0-7.0mg%
S. BILIRUBIN	0.8 mg%	0.2- 1.0mg%
DIRECT	0.1 mg%	0.0 -0.2 mg%
INDIRECT	0.7mg%	0.1 - 1.0 mg%
SGOT	35 IU/L	5-40 IU/L
SGPT	25 IU/L	5 -35 IU/L
GGTP	42 IU/L	M 11-49U/L F 7-32 U/L
Alkaline Phosphatate	150.0 U/L	70-270 U/L
TOTAL PROTEINS	7.5gm/dl	5.5 - 8.0 gm/dl
ALBUMIN	4.5 gm/dl	3.5 -5.5 gm/dl
GLOBULIN	3.0 gm/dl	2.5 -3.5 gm/dl
TOTAL CHOLESTROL	188mg%	(130- 200)
L D L	125mg%	< 150)
H D L	42 mg%	(30 - 55)
V L D L	21mg%	(5- 35)
TRIGLYCERIDES	105mg%	(65- 170)
CHOLESTROL / HDL RATIO	4.4	

URINE EXAMINATION

Reaction	Acidic	Acidic
Albumin	Nil	Nil
Sugar F	Nil	Nil
Sugar PP	Nil	Nil
Specific gravity	1014	1008-1025
M/E		
Pus cell	Nil	/HPF
RBCs	Nil	/HPF
Epithelial Cell	Not Seen	/HPF
Crystals	Nil	/HPF
Casts	Nil	/HPF
Any other finding	Nil	/HPF

Amf
DR. J.K. GULATI
 MD, DNB
 GULATI HOSPITAL
 Near Bus Stand, Yamuna Nagar

R
 Lab Incharge

THIS REPORT IS STRICTLY NOT VALID FOR MEDICO-LEGAL PURPOSE.

IN CASE ANY MISPRINTING OR ABNORMAL RESULT FOR ANY MISTAKE PLEASE CONTACT TO US IMMEDIATELY

(Wishing for your speedy recovery)



K.V. CLINICAL COMPUTERISED LABORATORY

Inside **GULATI HOSPITAL**

169, Sarojini Colony, Phase-I, YAMUNA NAGAR - 135 001

Equipped with Latest Computerised Analyzer (CBA-300)

NAME. MR. RAVI NAGPAL Age/Sex:-45/M DATE :-11.09.2022

COMPLETE HAEMOGRAM

Normal Values

Hb	13.5 gm%	12 – 17 gm%
RBC COUNT	5.50m/cu mm	4 – 5.5 m / cu mm
WBC COUNT	10,000cu/ mm	4000-11000 /cu mm
PLATELET COUNT	1.96Lac/ cu mm	1.5 –4 lac/ cu mm
DLC		
Polymorph	80	40-70%
Lymphocytes	16	20-45%
Monocytes	02	2-19%
Eosinophils	02	01-06%
Basophils	00	0.0-0.1%
MCH	34.0 pg	28-35pg/cell
MCV	91.0 fl	86-98 fl
MCHC	33.02%	32- 36 gm%
HAEMATOCRIT	50.0%	42- 52 %
ESR	06mm/hr	0.0-10mm/hr


DR. J.K. GULATI
MD, DNB
GULATI HOSPITAL
Near Bus Stand, Yamuna Nagar


Lab Incharge

THIS REPORT IS STRICTLY NOT VALID FOR MEDICO-LEGAL PURPOSE.

IN CASE ANY MISPRINTING OR ABNORMAL RESULT FOR ANY MISTAKE PLEASE CONTACT TO US IMMEDIATELY
(Wishing for your speedy recovery)




K.V. CLINICAL COMPUTERISED LABORATORY
Inside **GULATI HOSPITAL**

169, Sarojini Colony, Phase-I, YAMUNA NAGAR - 135 001

Equipped with Latest Computerised Analyzer (CBA-300)

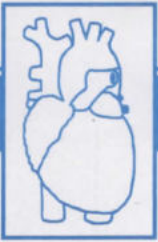
MR.RAVI NAGPAL	AGE 45 /MALE		DATE 11.09.2022
TEST NAME	RESULTS	UNITS	BIO.REF.INTERVAL
THYROID PROFILE,TOTAL,SERUM (CLIA)			
T3.TOTAL	1.40	ng/mL	0.60-1.81
T4.TOTAL	10.34	ug/dL	5.01-12.45
TSH	4.50	uIU/mL	0.35-5.50


DR. J.K. GULATI
MD, DNB
GULATI HOSPITAL
Near Bus Stand, Yamuna Nagar


Lab Incharge

THIS REPORT IS STRICTLY NOT VALID FOR MEDICO-LEGAL PURPOSE.

IN CASE ANY MISPRINTING OR ABNORMAL RESULT FOR ANY MISTAKE PLEASE CONTACT TO US IMMEDIATELY
(Wishing for your speedy recovery)



HOS. 260633
RES. 261633

GULATI HOSPITAL

169, Sarojini Colony, Near Bus Stand,
YAMUNA NAGAR - 135 001

Dr. J.K. Gulati

M.D., D.N.B. (AIIMS, New Delhi)
Consultant Physician & Heart Specialist

Dr. Sarita Gulati

D.G.O., DCH (Gynaecologist)
Ex. SMO, Civil Hospital, YNR.

X - RAY Chest PA

Date:-11/09/2022

Name:-Ravi Nagpal

Age/Sex:-43 Y/M

Skin and soft tissue normal

Bony and skeleton normal

Trachea is central

Mediastinum is normal

Heart size and shape Normal

DR. J.K. GULATI
MD, DNB
GULATI HOSPITAL
Near Bus Stand, Yamuna Nagar

RAVI NAGPAL

ID Ravi Nagpal

10 mm/mV 25 mm/S

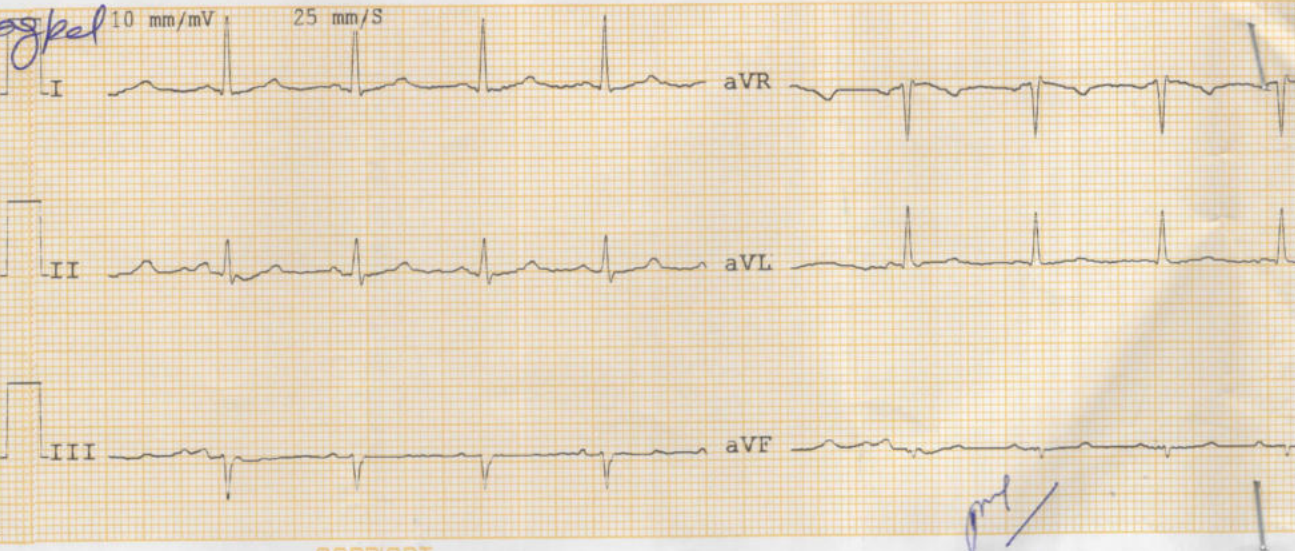
Name :
Age : Years
Gender :

BP : (mmHg)
Weight : Kgs

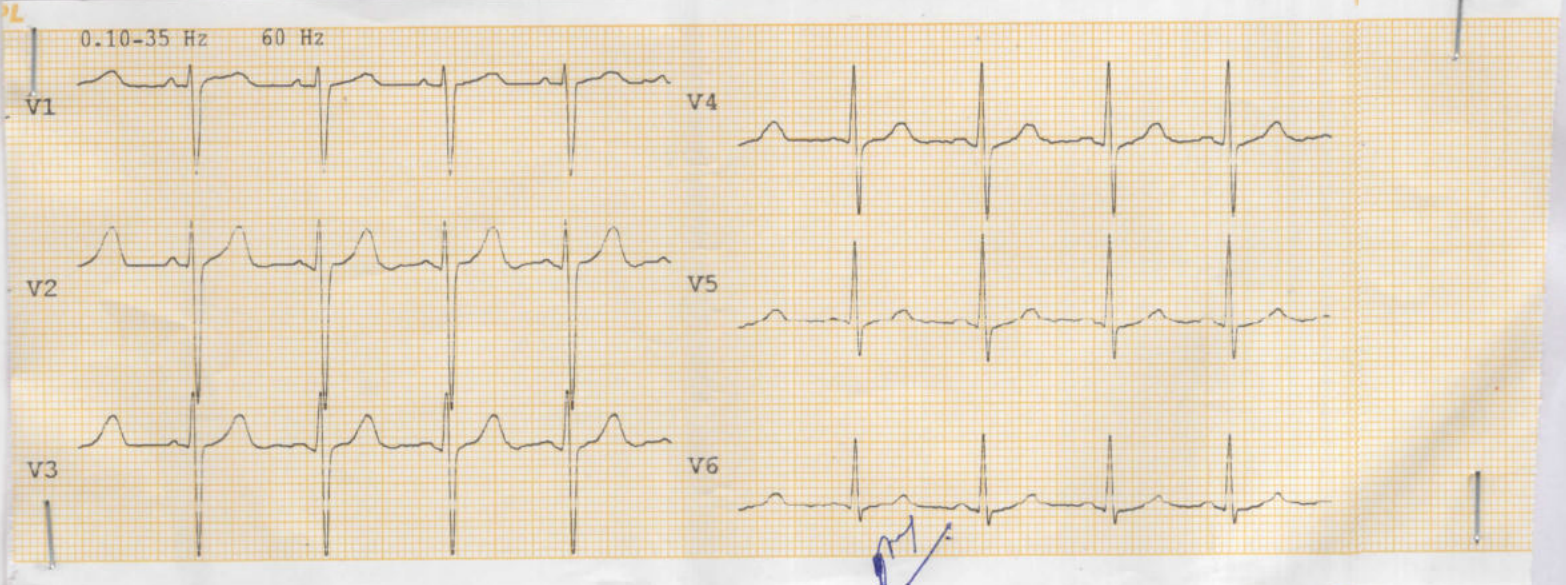
Date : 11/09/22

Note :

VESTA 3011
(Ver 3.15.31PC)
www.rmsindia.com



CARDIART

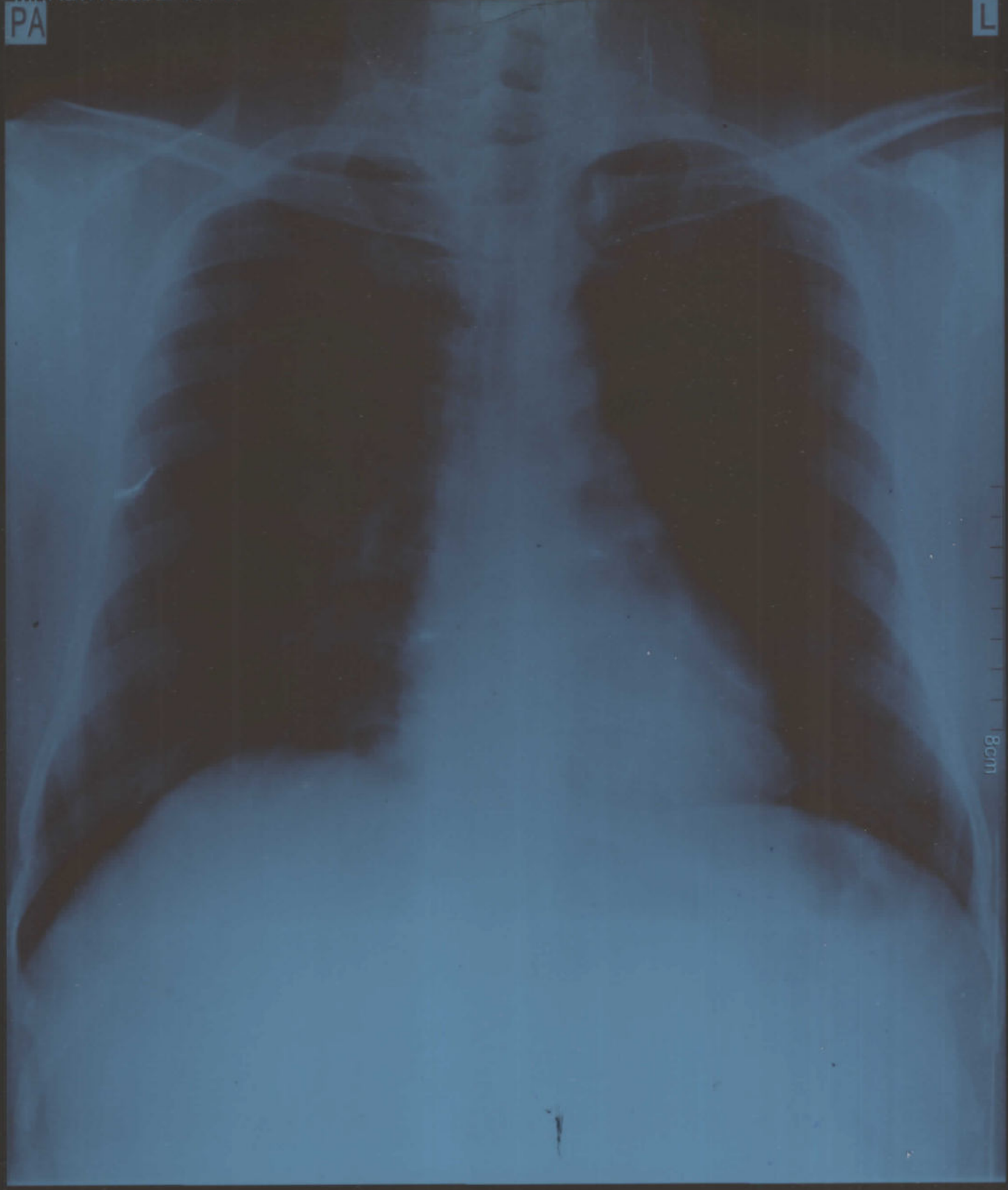

ECG REPORT:- Within Normal Limits

[Signature]
Signature
DR. J.K. GULATI
MD, DNB
GULATI HOSPITAL
Near Bus Stand, Yamuna Nagar

PA

L



8cm

8cm