

Shubham Imaging & ALC Diagnostic Center

ISO 9001:2015 Certified center

(A Unit of P.K. Arogyam Health & Wellness Center)

E-95, P.C. Colony, Near Sai Netryalaya Transformer, Kankarbagh, Patna - 20

alcdiagnostics@gmail.com

www.pkarogyamhealthcheckup.com

7050037694, 8271206196

OPINION MUST BE CORRELATES WITH CLINICALLY & OTHER INVESTIGATION FOR FINAL DIAGNOSIS. NOT FOR MEDICO LEGAL PURPOSE

Pt. Name :- RINKI KUMARI
Ref. By :- DR. / MEDIWHEEL

Date:- 23-Sep-23
Age / Sex - 26 Yrs. F.

REAL TIME U.S.G. OF WHOLE ABDOMEN Thanks for your kind referral

(Report.)

- LIVER** :- Measures 15.25 cm. Mild Enlarged in shape , size and echo texture fatty change seen in liver parenchyma .I.H.B.R. are not dilated. Hepatic veins are normal. No SOL seen
- G.BL. :- Lumen is echo free. Wall thickness appears normal.
- C.B.D. :- Measures 3.5 mm in diameter with echo free lumen. No calculi or mass seen.
- P.V. :- Measures 7.6 mm in diameter. Appears normal. No thrombus seen.
- PANCREAS :- Normal in shape, size and echo texture. No calcification mass seen.
- SPLEEN** :- Measures 13.26 cm. Mild enlarge in shape, size and echo texture. No SOL seen.
- KIDNEY :- Both kidney shows normal shape, size & echotexture. C.M.D.intact. P.C.S.is not dilated. No calculi, cyst or hydronephrosis seen on either side.
Right Kidney :- Measures 9.05 X 4.3 cm.
Left Kidney :- Measures 10.06 X 4.5 cm.
- URETER :- Not dilated .No apparent calculi seen.
- U.BLADDER:- Shows normal in outline with echo free lumen. No calculi or mass seen.
Pre void - 330 ml. Post void - is in significant
- UTERUS** :- Is Enlarged and bulky in size measures 9.42 X 5.91cm and Anteverted in Position Echogenicity of Myometeriam is increased. Endometrial thickness is 8.2 mm. No focal mass lesion seen . Cervix appear normal .
- ADNEXA** :- Both ovary appears normal in size and shape.
Rt Ovary Measures - 2.44 cm Lt Ovary Measures 2.18 cm
- P.O.D** :- Mild collection seen in P.O.D.
- R.I.F. :- Son graphically no appendicular mass or collection seen.
- OTHERS** :- Excess Gasses bowel distention seen in Abdomen .No Ascites No Lymph Adenopathy, No pleural Effusion seen on either side

IMPRESSION

- Mild Hepatomegaly With Fatty Liver G-I
- Mild Splenomegaly
- Enlarged Bulky Uterus With Mild Collection Seen In POD -? PID
- Excess Gasses Bowel Distention Seen In Abdomen .
- Adv:- Further Work Up Other Investigation
Otherwise son graphically normal scan. of rest organs .

23/9/23

Consultant Radiologist

ESTB BY:-

Dr. P. K. Tiwari
MD, M.Sc (Radio Imaging)
Ph.D (AlI Nuclear Medicine)
Consultant Imagianologist & Sonologist

Dr. S. Kumar
MD (Pat)
Consultant Pathologist

Dr. Abhishek Kumar
MBBS, MD
Consultant Neuropatho Physiologist

Dr. Kumari Suman
MBBS, DGO, MD
Consultant (TVS & HSG Specialist)

Dr. A. K. Singh
MBBS, PGDMCH
Consultant Radiologist & Sonologi



Shubham Imaging & ALC Diagnostic Center

ISO 9001:2015 Certified center

(A Unit of P.K. Arogyam Health & Wellness Center)

E-95, P.C. Colony, Near Sai Netryalaya Transformer, Kankarbagh, Patna - 20

alcdiagnostics@gmail.com

www.pkarogayamhealthcheckup.com

7056037694, 8271206196

OPINION MUST BE CORRELATES WITH CLINICALLY & OTHER INVESTIGATION FOR FINAL DIAGNOSIS. NOT FOR MEDICO LEGAL PURPOSE

Pt. Name :- RINKI KUMARI
Ref. By :- DR. /MEDIWHEEL

Date:- 23-Sep-23
Age / Sex -26 Yrs. F.

Thanks for your kind referral

(Report)

X-RAYCHEST (P.A.VIEW)

- The lungs on the either side show equal translucency.
- The peripheral pulmonary vasculature is normal.
- No focal lung lesion is seen.
- The pleural spaces are normal.
- Both hila are normal in size, have equal density and bear normal relationship.
- The heart and trachea are central in position and no mediastinal abnormality is visible.
- The cardiac size is normal.
- The domes of the diaphragms are normal in position, and show smooth outline.

IMPRESSION

- NO EVIDENCE OF PULMONARY OR CARDIAC PATHOLOGY IS NOTED.

23/9/23

ESTB BY:-

Consultant Radiologist

Dr. P. K. Tiwari
MD, M.Sc (Radio Imaging)
Ph.D (Alf Nuclear Medicine)
Consultant Imagiologist & Sonologist

Dr. S. Kumar
MD (Pat)
Consultant Pathologist

Dr. Abhishek Kumar
MBBS, MD
Consultant Neuropatho Physiologist

Dr. Kumari Suman
MBBS, DGO, MD
Consultant (TVS & HSG Specialist)

Dr. A. K. Singh
MBBS, PGDMCH
Consultant Radiologist & Sonologist

PRINTING MISTAKE SHOULD BE REPORTED BACK IMMEDIATELY/ यहाँ जन्म से पहले भ्रुण का लिंग जाँच नहीं होता है ।

CARDIOPRINT

ID 1753 CASE RINKI KUMARI
AGE 26Y 0M 0D FEMALE
156Cms 68KG

23/09/2023 13:00:12
ALC ADVANCE IMAGING DIAGNOSTICS
E95 PC COLONY KANKARBAGH PATNA

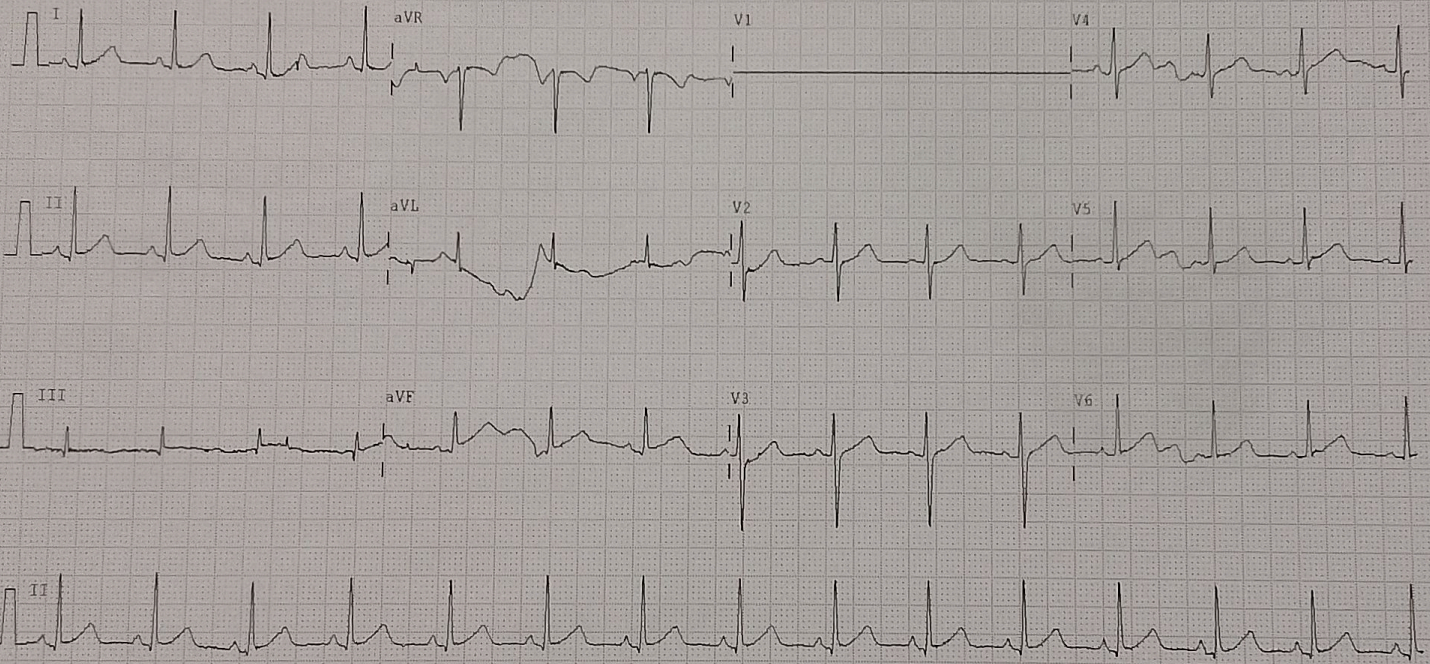
RATE : 86 bpm SINUS RHYTHM
R-R : 693 ms LEAD(S) UNSUITABLE FOR ANALYSIS: V1
P-R : 122 ms
QRS : 76 ms
QT : 360 ms
QTc : 406 ms


--AXIS--
P : 20°
QRS : 40° NORMAL ECG BASED ON AVAILABLE LEADS
T : 48°

12 SL. REPORT FORMAT 3x4+1L SQ

REF. DR BOB

Dr DR ABHISHEK KUMAR MD





Shubham Imaging & ALC Diagnostic Center

ISO 9001-2015 Certified center

(A Unit of P.K. Arogyam Health & Wellness Center)

E-95, P.C. Colony, Near Sai Netryalaya Transformer, Kankarbagh, Patna - 20

alcdiagnostics@gmail.com

www.pkarogayamhealthcheckup.com

7050037694, 8271206196

OPINION MUST BE CORRELATES WITH CLINICALLY & OTHER INVESTIGATION FOR FINAL DIAGNOSIS. NOT FOR MEDICO LEGAL PURPOSE

ECHOCARDIOGRAPHY & COLOR DOPPLER REPORT

Patient's Name: RINKI KUMARI

Age/Sex: 26 Yrs / F

Ref. by - Dr. / MEDIWHEEL

Date : 23-Sep-23

ECHO CARDIOGRAPHIC WINDOW : Good

2D & M MODE ECHOCARDIOGRAPHY

Left ventricle

EDD:	43	mm (20 - 28 mm / m ²)	ESD:	28	mm(13 - 21 mm / m ²)
IVS :	09	mm (6 - 11 mm)	PW:	10	mm(6 - 11 mm)
Ejection fraction:	62%	(67 ± 8%)	FS:	41	%(34 - 44 %)

Left atrium/ Aorta 35/25 mm

Right ventricle Normal

Right atrium Normal

Pericardium Normal with no pericardial effusion

2D: Normal LA & LV Size and normally contracting left ventricle. No, RWMA, No LVH

Mitral valve

AML/ PML: Normal

Tricuspid valve Normal

Aortic valve Normal

Pulmonary valve Normal

Continuous & Pulse Wave Doppler study

Valve	Velocity (m/sec)			Gradient (mmHg)			Valve area (PHT Method)	Regurg
	Peak	Mean	EDV	Peak	Mean	EDG		
Mitral	E=0.6 A=1.0			4.0	2.0			Nil
Tricuspid	E=0.5 A=0.3			1	0.2			Trivial
Aortic	1.12			5.0	2.5			Nil
Pulmonary	0.9			3.5	1.7			Nil

ESTB BY:-

Dr. P. K. Tiwari

MD, M.Sc (Radio Imaging)

Ph.D (Alt Nuclear Medicine)

Consultant Imagiologist & Sonologist

Dr. S. Kumar

MD (Pat)

Consultant Pathologist

Dr. Abhishek Kumar

MBBS, MD

Consultant Neuropatho Physiologist

Dr. Kumari Suman

MBBS, DGO, MD

Consultant (TVS & HSG Specialist)

Consultant Radiologist

Dr. A. K. Singh

MBBS, PGDMCH

Consultant Radiologist & Sonologist

PRINTING MISTAKE SHOULD BE REPORTED BACK IMMEDIATELY/ यहाँ जन्म से पहले भ्रुण का लिंग जाँच नहीं होता है ।

Shubham Imaging & ALC Diagnostic Center

ISO 9001:2015 Certified center

(A Unit of P.K. Arogyam Health & Wellness Center)

E-95, P.C. Colony, Near Sai Netryalaya Transformer, Kankarbagh, Patna - 20

diagnostics@gmail.com

www.pkarogayamhealthcheckup.com

7050037694, 8271206196

OPINION MUST BE CORRELATES WITH CLINICALLY & OTHER INVESTIGATION FOR FINAL DIAGNOSIS. NOT FOR MEDICO LEGAL PURPOSE

Colour Flow Imaging

No PR/AR/MR, Trivial TR,
No shunt flow


COMMENTS :

- ◆ Normal LA & LV Size
- ◆ Normal LV filling Pressure
- ◆ No RWMA , No LVH
- ◆ Normal LV systolic function
- ◆ Global LVEF = 63%
- ◆ Diastolic function Normal in Limits
- ◆ All cardiac valves are normal
- ◆ No MS / TS / AS / PS/PR
- ◆ No clot / vegetation / pericardial effusion
- ◆ Trivial TR, No PAH

IMPRESSION:

Normal LV Size & normally Contracting
Normal LV/RV systolic function, LVEF – 63%
Trivial TR, No PAH

Please correlate clinically


DR. RANJEET KUMAR
MBBS, PGDCC, CCEBDM
CONSULTANT CARDIOLOGIST
EX- SENIOR REGISTRAR, RTIICS, KOLKATA

ESTB BY:-

Consultant Radiologist

Dr. P. K. Tiwari
MD, M.Sc (Radio Imaging)
Ph.D (Alt Nuclear Medicine)
Consultant Imaginationist & Sonologist

Dr. S. Kumar
MD (Pat)
Consultant Pathologist

Dr. Abhishek Kumar
MBBS, MD
Consultant Neuropatho Physiologist

Dr. Kumari Suman
MBBS, DGO, MD
Consultant (TVS & HSG Specialist)

Dr. A. K. Singh
MBBS, PGDMCH
Consultant Radiologist & Sonologist

PRINTING MISTAKE SHOULD BE REPORTED BACK IMMEDIATELY/ यहाँ जन्म से पहले भुण का लिंग जाँच नहीं होता है ।



Shubham Imaging & ALC Diagnostic Center

ISO 9001:2015 Certified center

(A Unit of P.K. Arogyam Health & Wellness Center)

E-95, P.C. Colony, Near Sai Netryalaya Transformer, Kankarbagh, Patna - 20

alcdiagnostics@gmail.com

www.pkarogayamhealthcheckup.com

7050037694, 8271206196

OPINION MUST BE CORRELATES WITH CLINICALLY & OTHER INVESTIGATION FOR FINAL DIAGNOSIS. NOT FOR MEDICO LEGAL PURPOSE

PATIENT NAME : Mrs. RINKI KUMARI PATIENT ID: 1753
 COL DATE : 23/09/2023 REPORTING DATE: 23/09/2023 AGE SEX : 26 YRS/F
 REF.BY : DR. / MEDIWHEEL

TEST NAME	RESULT	Unit	REF.RANGE
BLOOD SUGAR (F)	102.0	mg/dl	70 - 110 mg/dl
BLOOD SUGAR (PP)	157.0	mg/dl	70 - 140 mg/dl

LIPID PROFILE:-

TOTAL CHOLESTROL	162.1	mg/dl	130 -250 mg/dl
TRIGLYCERIDE	158.6	mg/dl	50 -160 mg/dl
HDL CHOLESTROL	42.0	mg/dl	30 - 60 mg/dl
LDL CHOLESTROL	88.4	mg/dl	80 -130 mg/dl
VLDL CHOLESTROL	31.7	mg/dl	15 - 40 mg/dl
T.CH./HDL RATIO	3.8 : 1		Upto 5 :1
LDL /HDL RATIO	2.1 : 1		2 - 4:1

[Signature]
 23/09/2023

Consultant Radiologist

ESTB BY:-

Dr. P. K. Tiwari
 MD, M.Sc (Radio Imaging)
 Ph.D (Alf Nuclear Medicine)
 Consultant Imagonologist & Sonologist

Dr. S. Kumar
 MD (Pat)
 Consultant Pathologist

Dr. Abhishek Kumar
 MBBS, MD
 Consultant Neuropatho Physiologist

Dr. Kumari Suman
 MBBS, DGO, MD
 Consultant (TVS & HSG Specialist)

Dr. A. K. Singh
 MBBS, PGDMCH
 Consultant Radiologist & sonologist

PRINTING MISTAKE SHOULD BE REPORTED BACK IMMEDIATELY/ यहाँ जन्म से पहले भुण का लिंग जाँच नहीं होता है ।

Shubham Imaging & ALC Diagnostic Center

ISO 9001:2015 Certified center

(A Unit of P.K. Arogyam Health & Wellness Center)

E-95, P.C. Colony, Near Sai Netryalaya Transformer, Kankarbagh, Patna - 20

alcdiagnostics@gmail.com

www.pkarogayamhealthcheckup.com


7050037694, 8271206196

OPINION MUST BE CORRELATES WITH CLINICALLY & OTHER INVESTIGATION FOR FINAL DIAGNOSIS. NOT FOR MEDICO LEGAL PURPOSE
PATIENT NAME : Mrs. RINKI KUMARI PATIENT ID: 1753

COL DATE : 23/09/2023 REPORTING DATE: 23/09/2023 AGE SEX:- 26 YRS/F

REF.BY : DR. / MEDIWHEEL .

TEST NAME	RESULT	Unit	REF.RANGE
LFT:-			
SGPT	145.0	IU/L	5 - 40 IU/L
SGOT	87.6	IU/L	5 - 40 IU/L
ALKALINE PHOSPHATASE	92.2	IU/L	M - 53 - 165 IU/L F - 42 - 136 IU/L
TOTAL PROTIN	7.1	g/dl	6.0 - 8.7 g/dl
SERUM ALBUMIN	4.3	g/dl	3.5 - 5.4 g/dl
SERIUM GLUBLINE	2.8	g/dl	2.3 - 3.6 g/dl
AG RATIO	1.5: 1		1.0 - 2.3 g/dl
BILIRUBIN			
TOTAL	0.71	mg/dl	0.1 - 1.1 mg/dl
DIRECT	0.23	mg/dl	0.0 - 0.32 mg/dl
INDIRECT	0.48	mg/dl	0.0 - 0.78 mg/dl
GGTP(GGT)	27.3	iu/L	8 - 38 iu/L
KFT/RFT			
URIC ACID	4.1	mg/dl	3.2 - 7.0 mg/dl
SERUM CREATNINE	0.8	mg/dl	0.6 - 1.5 mg/dl
BLOOD URIA	29.6	mg/dl	5 - 45 mg/dl
BLOOD URIA NITROZEN(BUN).	13.8	mg/dl	5 - 23 mg/dl


23/09/2023

Consultant Radiologist

ESTB BY:-

Dr. P. K. Tiwari
MD, M.Sc (Radio Imaging)
Ph.D (Alr Nuclear Medicine)
Consultant Imagionologist & Sonologist

Dr. S. Kumar
MD (Pat)
Consultant Pathologist

Dr. Abhishek Kumar
MBBS, MD
Consultant Neuropatho Physiologist

Dr. Kumari Suman
MBBS, DGO, MD
Consultant (TVS & HSG Specialist)

Dr. A. K. Singh
MBBS, PGDMCH
Consultant Radiologist & Sonologist

PRINTING MISTAKE SHOULD BE REPORTED BACK IMMEDIATELY/ यहाँ जन्म से पहले भुण का लिंग जाँच नहीं होता है ।

Shubham Imaging & ALC Diagnostic Center

ISO 9001:2015 Certified center

(A Unit of P.K. Arogyam Health & Wellness Center)

E-95, P.C. Colony, Near Sai Netryalaya Transformer, Kankarbagh, Patna - 20

alcdiagnostics@gmail.com

www.pkarogyamhealthcheckup.com

7050037694, 8271206196

OPINION MUST BE CORRELATES WITH CLINICALLY & OTHER INVESTIGATION FOR FINAL DIAGNOSIS. NOT FOR MEDICO LEGAL PURPOSE

PATIENT NAME : Mrs. RINKI KUMARI

PATIENT ID:1753

COL DATE : 23/09/2023

REPORTING DATE: 23/09/2023

AGE SEX:- 26 YRS/F

REF.BY

: DR. / MEDIWHEEL .

TEST NAME	RESULT	Unit	REF.RANGE
ESR	14 mm/hr		<20 mm/hr
CBC			
Total W.B.C. Count	5,700 /cumm		4000 - 11,000 /cumm
R B C COUNT	4.24 Million/ CUmm		4 - 7 Million/ CUmm
Platelets count	1.47 Lakh/ cumm		1.5 - 5.0 Lakh/ cumm
Differential Count of W.B.C.			
Neutrophils	63 %		40 -70%
Lymphocytes	31 %		25 - 40%
Eosinophils	04 %		01 - 05%
Mnonocytes	02 %		00 - 02%
Basophiles	00 %		00 - 0%
HAEMOGLOBIN	12.4 gm/dl (84.9 %)		14.6 gm/dl = 100%
PCV	38.3 %		35 - 47 %
MCV	90.4 fl		76 - 96 fl
MCH	29.3 pg		29 - 35 pg
MCHC	32.4 %		30 - 38 %

[Signature]
23/09/2023

Consultant Radiologist

ESTB BY:-

Dr. P. K. Tiwari
MD, M.Sc (Radio Imaging)
Ph.D (Alt Nuclear Medicine)
Consultant Imagonologist & Sonologist

Dr. S. Kumar
MD (Pat)
Consultant Pathologist

Dr. Abhishek Kumar
MBBS, MD
Consultant Neuropatho Physiologist

Dr. Kumari Suman
MBBS, DGO, MD
Consultant (TVS & HSG specialist)

Dr. A. K. Singh
MBBS, PGDMCH
Consultant Radiologist & Sonologist

PRINTING MISTAKE SHOULD BE REPORTED BACK IMMEDIATELY/ यहाँ जन्म से पहले भुण का लिंग जाँच नहीं होता है ।

Shubham Imaging & ALC Diagnostic Center

ISO 9001:2015 Certified center

(A Unit of P.K. Arogyam Health & Wellness Center)

E-95, P.C. Colony, Near Sai Netryalaya Transformer, Kankarbagh, Patna - 20

alcdiagnostics@gmail.com

www.pkarogayamhealthcheckup.com

7050037694, 8271206196

OPINION MUST BE CORRELATES WITH CLINICALLY & OTHER INVESTIGATION FOR FINAL DIAGNOSIS. NOT FOR MEDICO LEGAL PURPOSE

PATIENT NAME : Mrs. RINKI KUMARI


PATIENT ID : 1753

COL DATE : 24/09/2023 REPORTING DATE: 24/09/2023 AGE SEX : 26 YRS/F

REF.BY : DR./ MEDIWHEEL.

GLYCOSYLATED HEMOGLOBIN

TEST NAME	RESULT	Unit	REF.RANGE
HbA1c	5.5 %		Below 5.7 % : Normal 5.7 – 6.4 % : Prediabetic > = 6.5 % : Diabetic
AVERAGE PLASMA GLUCOSE	117.0 mg/dl		90 – 120 mg/dl : Good Control 121 – 150 mg/dl : Fair Control 151- 180 mg/dl: Unsatisfactory Control >180 mg/dl : Poor Control


29/09/2023
Consultant Radiologist

ESTB BY:-

Dr. P. K. Tiwari
MD, M.Sc (Radio Imaging)
Ph.D (Alr Nuclear Medicine)
Consultant Imagonologist & Sonologist

Dr. S. Kumar
MD (Pat)
Consultant Pathologist

Dr. Abhishek Kumar
MBBS, MD
Consultant Neuropatho Physiologist

Dr. Kumari Suman
MBBS, DGO, MD
Consultant (TVS & HSG Specialist)

Dr. A. K. Singh
MBBS, PGDMCH
Consultant Radiologist & Sonologist

PRINTING MISTAKE SHOULD BE REPORTED BACK IMMEDIATELY/ यहाँ जन्म से पहले भुण का लिंग जाँच नहीं होता है ।

Shubham Imaging & ALC Diagnostic Center

ISO 9001:2015 Certified center

(A Unit of P.K. Arogyam Health & Wellness Center)

E-95, P.C. Colony, Near Sai Netryalaya Transformer, Kankarbagh, Patna - 20

diagnostics@gmail.com

www.pkarogayamhealthcheckup.com

7050037694, 8271206196

OPINION MUST BE CORRELATES WITH CLINICALLY & OTHER INVESTIGATION FOR FINAL DIAGNOSIS. NOT FOR MEDICO LEGAL PURPOSE

PATIENT NAME : Mrs. RINKI KUMARI

PATIENT ID: 1753

COL DATE : 23/09/2023 REPORTING DATE: 23/09/2023 AGE SEX : 26 YRS/F

REF.BY : DR. / MEDIWHEEL.

TEST NAME	RESULT	Unit	REF.RANGE
-----------	--------	------	-----------

BLOOD GROUP : 'A'

Rh Typing : POSITIVE

Note: Do always cross – matching before blood transfusion

AKS
23/09/2023

Consultant Radiologist

ESTD BY:-

Dr. P. K. Tiwari
MD, M.Sc (Radio Imaging)
Ph.D (Art Nuclear Medicine)
Consultant Imacionologist & Sonologist

Dr. S. Kumar
MD (Pat)
Consultant Pathologist

Dr. Abhishek Kumar
MBBS, MD
Consultant Neuropatho Physiologist

Dr. Kumari Suman
MBBS, DGO, MD
Consultant (TVS & HSG Specialist)

Dr. A. K. Singh
MBBS, PGDMCH
Consultant Radiologist & Sonologist

Shubham Imaging & ALC Diagnostic Center

ISO 9001:2015 Certified center

(A Unit of P.K. Arogyam Health & Wellness Center)

E-95, P.C. Colony, Near Sai Netryalaya Transformer, Kankarbagh, Patna - 20

diagnostics@gmail.com

www.pkarogayamhealthcheckup.com

7050037694, 8271204196

OPINION MUST BE CORRELATES WITH CLINICALLY & OTHER INVESTIGATION FOR FINAL DIAGNOSIS. NOT FOR MEDICO LEGAL PURPOSE

PATIENT NAME : Mrs. RINKI KUMARI

PATIENT ID: 1753

COL DATE : 23/09/2023 REPORTING DATE: 23/09/2023 AGE SEX : 26 YRS/F

REF.BY : DR. / MEDIWHEEL..

ROUTINE EXAMINATION OF URINE

PHYSICAL EXAMINATION


Quantity	40 ml	Colour....	Strow
Appearance...	Clear	Sediment ...	Nil
Specific gravity....	1.010		

CHEMICAL EXAMINATION

Reaction	6.0	Nitrite.....	Not done
Sugar	Nil	Bile Pigment ...	Not done
Albumin	Nil	Urobilinogen....	Not done
Excess of Phosphate....	Nil	Chile.....	Not done
Bile Salt	Not Done	Acetone...	Not done

MICROSCOPIC EXAMINATION

Erythrocytes....	Nil	Casts	Nil
Leucocytes	1-5 / HPE	Crystals....	Nil
Epith. Cell	A, Few	Others	Nil


Consultant Radiologist

ESTB BY:-

Dr. P. K. Tiwari
MD, M.Sc (Radio Imaging)
Ph.D (Alt Nuclear Medicine)

Dr. S. Kumar
MD (Pat)
Consultant Pathologist

Dr. Abhishek Kumar
MBBS, MD
Consultant Neuropatho Physiologist

Dr. Kumari Suman
MBBS, DGO, MD
Consultant (TVS & HSG Specialist)

Dr. A. K. Singh
MBBS, PGDMCH
Consultant Radiologist & Sonologist

Consultant Imagionologist & Sonologist

PRINTING MISTAKE SHOULD BE REPORTED BACK IMMEDIATELY/ यहाँ जन्म से पहले भ्रुण का लिंग जाँच नहीं होता है ।

Shubham Imaging & ALC Diagnostic Center

ISO 9001:2015 Certified center

(A Unit of P.K. Arogyam Health & Wellness Center)

E-95, P.C. Colony, Near Sai Netryalaya Transformer, Kankarbagh, Patna - 20

radiagnostics@gmail.com

www.pkarogyamhealthcheckup.com

7050037694, 8271206196

OPINION MUST BE CORRELATES WITH CLINICALLY & OTHER INVESTIGATION FOR FINAL DIAGNOSIS. NOT FOR MEDICO LEGAL PURPOSE

PATIENT NAME : Mrs. RINKI KUMARI

PATIENT ID : 1573

COL DATE : 23/09/2023 REPORTING DATE: 23/09/2023 AGE SEX : 26 YRS/F

REF.BY : DR. / MEDIWHEEL.

Investigation	Result	Normal Range
Total Triiodothyronin T3	1.29 ng/mL	0.80 - 2.00 μ ng/mL
Total Thyroxin T4	7.37 ug/mL	5.10 - 14.10 ug/dL
Serum TSH	2.28 μ g/mL	0.27 - 4.20 μ g/mL

THYROID DISORDER (>: Increase: < Decrease: n Normal

1. T3(n) T4(n) TSH(n) :EUTHYROID STATE:
2. T3(>) T4(>) TSH(<): HYPERTHYROIDISM:
3. T3(<)T4(<) TSH(>): HYPOTHYROIDISM:
4. T3(n)T4(n) TSH(>) : SUB-CLINICAL HYPO-THYROIDISM:
5. T3(n)T4(n) TSH(<): SUB-CLINICAL HYPER-THYROIDISM:
6. T3(>) T4(n) TSH(<): T3 THYROTOXICOSIS:

Total T3/T4 level is dependent on Level:

So determination of free T3/T4is a better MARKER of Thyroid Function.

*FREE T3/T4 ESTIMATION FACILITY IS AVAILABALE ON REQUEST.:

ESTB BY:-

Dr. P. K. Tiwari
MD, M.Sc (Radio Imaging)
Ph.D (Alt Nuclear Medicine)
Consultant Imacionologist & Sonologist

Dr. S. Kumar
MD (Pat)
Consultant Pathologist

Dr. Abhishek Kumar
MBBS, MD
Consultant Neuropatho Physiologist

Dr. Kumari Suman
MBBS, DGO, MD
Consultant (TVS & HSG Specialist)

Dr. A. K. Singh
MBBS, PGDMCH
Consultant Radiologist & Sonologist

ATD
22/09/2023
Consultant Radiologist

PRINTING MISTAKE SHOULD BE REPORTED BACK IMMEDIATELY/ यहाँ जन्म से पहले भ्रूण का लिंग जाँच नहीं होता है ।