

DAKSH HOSPITAL

396 - 397, Gandhi Nagar, Scheme No. 8, ALWAR -301001

Ref. No.

Date.....

MEDICAL EXAMINATION REPORT

Mediwheel (BOB)

Name: Mrs. Rani

Age: 36 yrs

Sex: Female

Date: 09/03/2024

General Physical Examination

Height : 154cm
Pulse : 70 /mt
Respiration : 18 /mt

Weight : 71 Kg
BP : 90/60 mm/hg
BMI : 29.9 kg/m²

Systemic Exam:-

NORMAL

Dental Check up :-

NORMAL

Eye check-up :-

NORMAL

Skin Check up:-

NORMAL

ENT Check up:-

NORMAL

Gynae Check up:-

MN- 3/30 days on-P2NO
Lmp 9/3/24 LP- 3yr

Pap smear after period

Impression:-

Eosinophilia

Recommendation:-

TO CONSULT Physician for Eosinophilia evaluate

Dr. Mukesh Kumar Gupta
MD Gen. Medicine
Reg. No 5423/16262

डॉ० मुकेश गुप्ता
M.D.F.C.C.S.
फिजिशियन एवं मधुमेह रोग विशेषज्ञ
दक्ष हॉस्पिटल, अलवर
रजि० नं०-5423/16262

Results

Run Date 09/03/2024 09:56:07 AM

Operator DAKSH

Last Name

Sample ID 12

First Name MRS RANI

Department

Gender Female

Age

Physician DR. MUKESH GUPTA M.D

Patient ID AUTO_PID20055

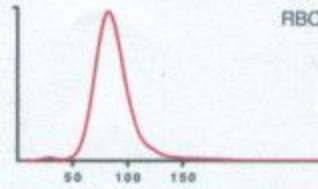
Type Woman

Date of birth


Sample comments

Susp. Pathologies
Eosinophilia

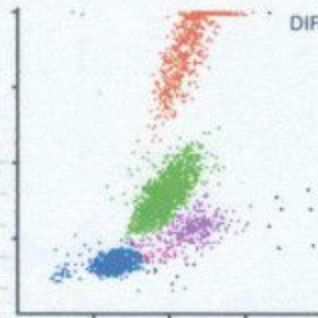
			Range
RBC	4.28	10 ⁶ /μL	3.80 - 5.50
HGB	12.0	g/dL	11.5 - 15.2
HCT	37.3	%	35.0 - 46.0
MCV	87.2	μm ³	77.0 - 97.0
MCH	28.0	pg	26.0 - 34.0
MCHC	32.1	g/dL	32.0 - 35.0
RDW-CV	16.4	%	11.0 - 17.0
RDW-SD	56.2	μm ³	37.0 - 49.0



			Range
PLT	286	10 ³ /μL	150 - 450
PCT	0.32	%	0.15 - 0.40
MPV	11.2	μm ³	8.0 - 11.0
PDW	21.4	μm ³	11.0 - 22.0
P-LCC	117	10 ³ /μL	44 - 140
P-LCR	40.8	%	18.0 - 50.0



			Range
WBC	6.50	10 ³ /μL	3.50 - 10.00
	#	Range	%
NEU	3.18	1.60 - 7.00	49.1
LYM	2.02	1.00 - 3.00	31.2
MON	0.13	0.20 - 0.80	2.0
EOS	1.09	0.00 - 0.50	16.7
BAS	0.07	0.00 - 0.15	1.0
LIC	0.01	0.00 - 0.10	0.2



Dr. R.S. Gupta
Dr. R.S. GUPTA
 MD (Pathology) (MAHE)
 RMC No. 7924/19778


Date :-09/03/2024

Name :- MRS. RANI

Age & Sex :- 36 Yrs/ Female

Refd. :- Dr Mukesh Gupta M.D.

	TEST NAME	RESULT	REFERENCE RANGE	
	ESR	15	00 -20 mm/hrs	
	Blood Group & Rh Factor	B * POSITIVE		
	HbA1C	4.8	4 - 5.6%	
	Blood Sugar (R)	83.1	<150 mg/dl	
	Blood Sugar (PP)	-	< 140 mg/dl	
	Urine Sugar (F)	NIL	-	
	Urine Sugar (PP)	Nil	-	
LIVER	S.Bilirubin Total	0.90	0.30 - 1.20 mg/dl	
	S.Bilirubin Direct	0.20	0.10 - 0.30 mg/dl	
	S.Bilirubin Indirect	0.70	0.30 - 0.90 mg/dl	
	S.G.O.T.	17	> 37 u/l	
	S.G.P.T.	25	25 > 40 u/l	
	S.Alk. Phosp.	209	80 - 306 u/l	
	G.G.T.	25.1	5 -40 u/l	
	Total Protein	6.7	6.5 - 8.5 gm/dl	
	Albumin	3.6	3.8 - 5.4 gm/dl	
	Globulin	3.1	2.3 - 3.5 gm/dl	
A/G Ratio	1.1	-		
AST/ALT Ratio	0.68	-		
KIDNEY	Blood Urea	27.1	15 -45 mg/dl	
	S.Creatinine	0.98	0.60 - 1.30 mg/dl	
	BUN	21.1	6 -24 mg/dl	
	S.Uric Acid	5.3	M 3.1 - 7.0, F 2.5 - 5.6 mg/dl	
	BUN/Creatinine Ratio	27.1	-	
LIPID PROFILE	Total Cholesterol	125.1	Up to 200 mg/dl	
	S.HDL	43.1	30 - 70 mg/dl	
	S.LDL	62.1	Up to 170 mg/dl	
	S.VLDL	20.1	5.0 - 40 mg/dl	
	S. Triglycerides	100.1	Up to 170 mg/dl	
	LDL/HDL Ratio	1.4	-	
Total Cholesterol/ HDL Ratio	2.9	-		
THYROID	T3	108	40 - 181 ng/dl	
	T4	6.3	4.6 - 10.5 µg/dl	
	TSH	7.41	0.30 - 5.0 mIU/l	
	URINE EXAMINATION		<i>Microscopic Examination:</i>	
General/Chemical Examination:	Colour	Pale Yellow	RBC	Absent
	Reaction	Acidic	WBC	2 -3
	Specific Gravity	QNS	Epithelial Cells	1 -2
	Appearance	Clear	Cast	Absent
	Albumin	Nil	Crystal	Absent
	Sugar	Nil	Spermatozoa	Absent
			Amorphous Sediments	Absent
		Other	Absent	
X-RAY CHEST	NORMAL STUDY			
	STOOL EXAMINATION		<i>Microscopic Examination:</i>	
General/ Chemical			RBC	-


Dr. R.S. GUPTA
 MD (Pathology) (MAHE)
 Doctor
 BMC No. 7924/19778

TECHNOLOGIST

All investigations have their own limitations regarding the sensitivity & specificity of individual assay procedures. Isolated laboratory investigations never confirm the final diagnosis of the disease. They only help in arriving at a diagnosis in conjunction with clinical presentation and other related investigations. Report is not valid for medico-legal purpose subject to ALWAR jurisdiction only.

Date :- 09/03/2024

Name :- Mrs. Rani

Refd. :- Dr Mukesh Gupta MD

Age & Sex :- 36Yrs/ Female

CYTO-PATHOLOGY

PAP SMEAR

1. Specimen type	Received two conventional smears.
2. Specimen adequacy	Smears are satisfactory for evaluation.
3. Microscopic finding	Smears are moderately cellular comprises of predominantly intermediate with mature superficial squamous epithelial cells arranged in clusters & scattered singly.
4. Inflammation	Not seen
5. Bacilli	Not seen
6. Endocervical cells	Not seen
7. Koilocytic changes	Not seen
8. Trichomonas	Not seen
9. Dysplasia	Nil
10. Neoplasia	Nil
11. Endometrial cells	Nil

Impression:- Negative for intraepithelial lesion or malignancy


Dr. R.S. GUPTA
MD (Pathology) (MAHE)
MNC No. 7924/19778
Doctor


TECHNOLOGIST

All investigation have their own limitations regarding the sensitivity & specificity of individual assay procedures. Isolated laboratory investigations never confirm the final diagnosis of the disease. They only help in arriving at a diagnosis in conjunction with clinical presentation and other related investigations. Report is not valid for medico-legal purpose subject to ALWAR jurisdiction only.



दक्ष हॉस्पिटल

396, गाँधी नगर स्कीम नं.8, अलवर (राज०) ☎ 0144-2703340

Sonography / 2D Echo Cardiography / Doppler Report

2D/ ECHO REPORT

Name: - Mrs RANI

Age: - 36 Yrs

Date: - 9-Mar-24

Reg. No.: - Alw/2009/04

BOB health checkup

PROCEDURES:

M-MODE/2D/DOPPLER/COLOR/CONTRAST B.A.S. M²

MEASUREMENT:		NORMAL		DOPPLER:		NORMAL (cm/sec.)	
AOD	23	(20- 37mm)		MV	0.7	(0.8- 1.3)	MR No
LA	22	(19- 40mm)		AV	1.7	(1.2- 1.8)	AR No
AVO	15.5	(12- 25mm)		TV	0.6	(0.3- 0.8)	TR No
RVDd.	9	(03- 09mm)		PV	0.8	(0.7- 1.1)	PR No
LVDd	45	(37- 56mm)		MITRAL VALVE-			
LVDs	27.8	(22- 40mm)				AML	Normal
IVS d	6.5	(06- 12mm)				PML	Normal
IVS s	10			AORTIC VALVE			
PWd	5	(05- 10mm)					Normal
LV FUNCTION				TV & PV are normal.			
M- E- S Separation		<0.9cm					
Minor		24.42%					
LV Ejection Fraction	70%	65 +/- 12%					

MITRAL E>A

LV WALL MOTION: NO RWMA

ALL CARDIAC CHAMBERS ARE NORMAL

ALL VALVES ARE NORMAL

NO CLOT, VEGETATION, PERICARDIAL EFFUSION

Adv: - Follow up/ review at higher center for confirmation

Note:- Please Correlate clinically. Due to technical limitations as well as inaccuracies inherent in the laboratory and statistical analysis of biological process. Diagnostic accuracy of ECHO is up to 95% only. Report is not valid for medico-legal purpose.


DR. MUKESH GUPTA
 PHYSICIAN
Dr. Mukesh Kumar Gupta
 Physician & Sonologist
 RM 5423/16262



"भ्रूण लिंग परीक्षण की शिकायत 104 टोल फ्री सेवा पर भी की जा सकती है"

भ्रूण लिंग परीक्षण की शिकायत 104 टोल फ्री सेवा पर भी की जा सकती है।



दक्ष हॉस्पिटल

396, गाँधी नगर स्कीम नं.8, अलवर (राज०) ☎ 0144-2703340

Sonography / 2D Echo Cardiography / Doppler Report

NAME :- MRS RANI/F/36 YRS

9-Mar-24

BOB HEALTH CHECKUP

U.S.G. OF ABDOMEN & PELVIS

LIVER

Liver is normal in size shape with normal echo-texture. Intra hepatic biliary radicals Are not dilated. No evidence of focal or diffuse lesion.

GALL BLADDER

Gall bladder is normal.

PANCREAS

Pancreas is normal in size, shape & echo-texture. No evidence of focal or diffuse lesion. MPD not dilated.

SPLEEN

Normal in size with normal shape & echo- texture. Spleen vein is normal. No evidence of focal or diffuse lesion

KIDNEY

Both kidneys are normal.

URINARY BLADDER

UB is normally distended, visualized lumen appear clear.

UTERUS:

Uterus is normal in size (8.6x3.5x4.7cm) with homogenous echo-texture. Endometrial 10 mm in thickness & echo genicity

OVARIES:

Both ovaries are normal.

Advice- follow up/ hormonal study review at higher center for confirmation

Please correlate clinically. USG accuracy is 95 % due to technical limitations as well as inaccuracies inherent in the laboratory and statistical analysis biological process. This report is not valid for medico-legal cases



DR. MUKESH GUPTA
SONOLOGIST

Dr. Mukesh Kumar Gupta

Physician & Sonologist

RM 5423/16262



"भ्रूण लिंग परीक्षण की शिकायत
104 टोल फ्री सेवा पर भी की
जा सकती है"

भ्रूण लिंग परीक्षण की शिकायत 104 टोल फ्री सेवा पर भी की जा सकती है।

11-01-2024 06:00:55 AM

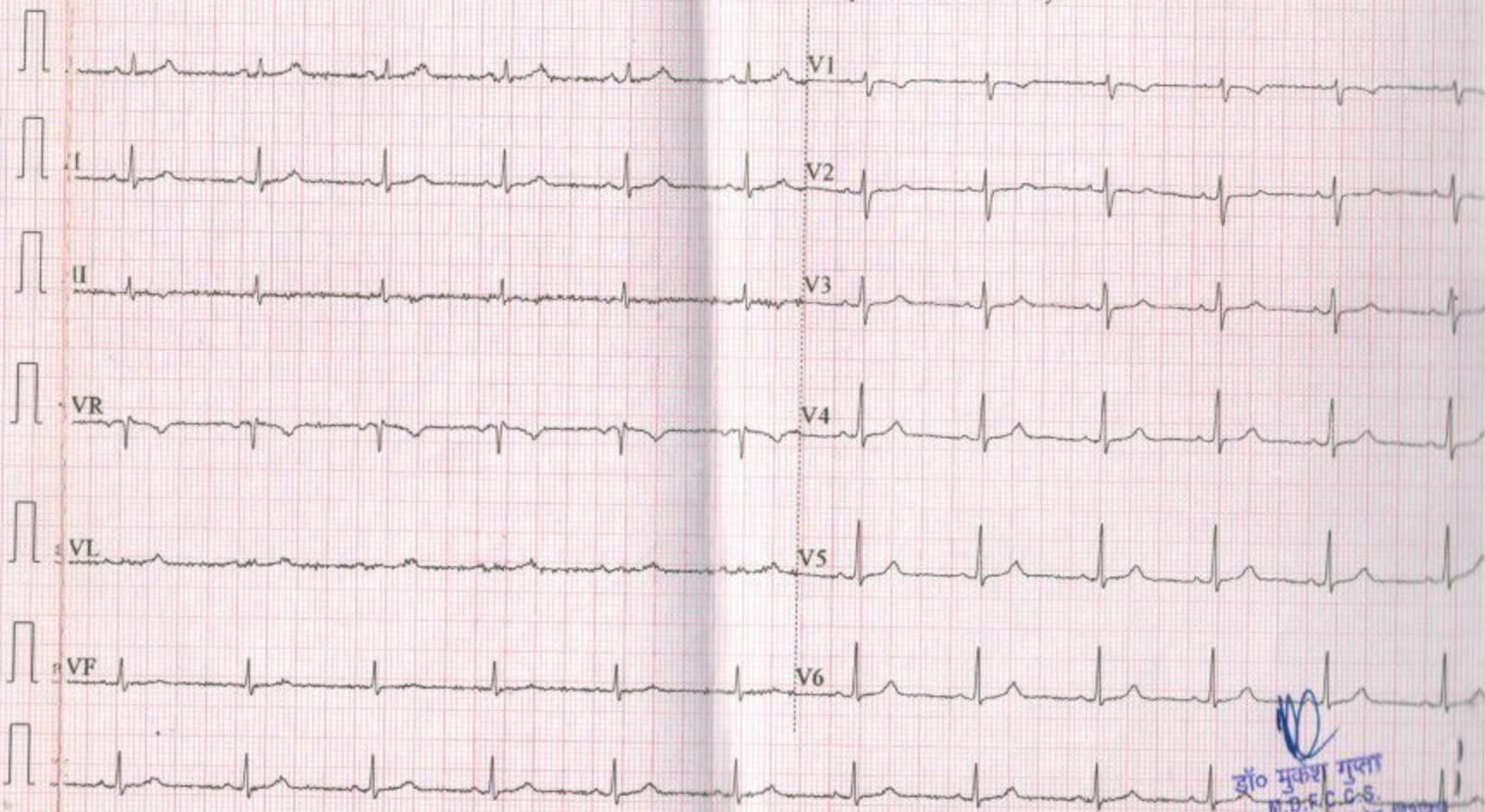
ID: ..

Sex: /c Years

HR : 74 bpm
 P : 80 ms
 PR : 121 ms
 QRS : 70 ms
 QT/QTc : 345/383 ms
 P/QRS/T : 16/37/20 °
 RV5/SV1 : 0.939/0.269 mV

Diagnosis Information:
 Sinus Rhythm
 Normal ECG

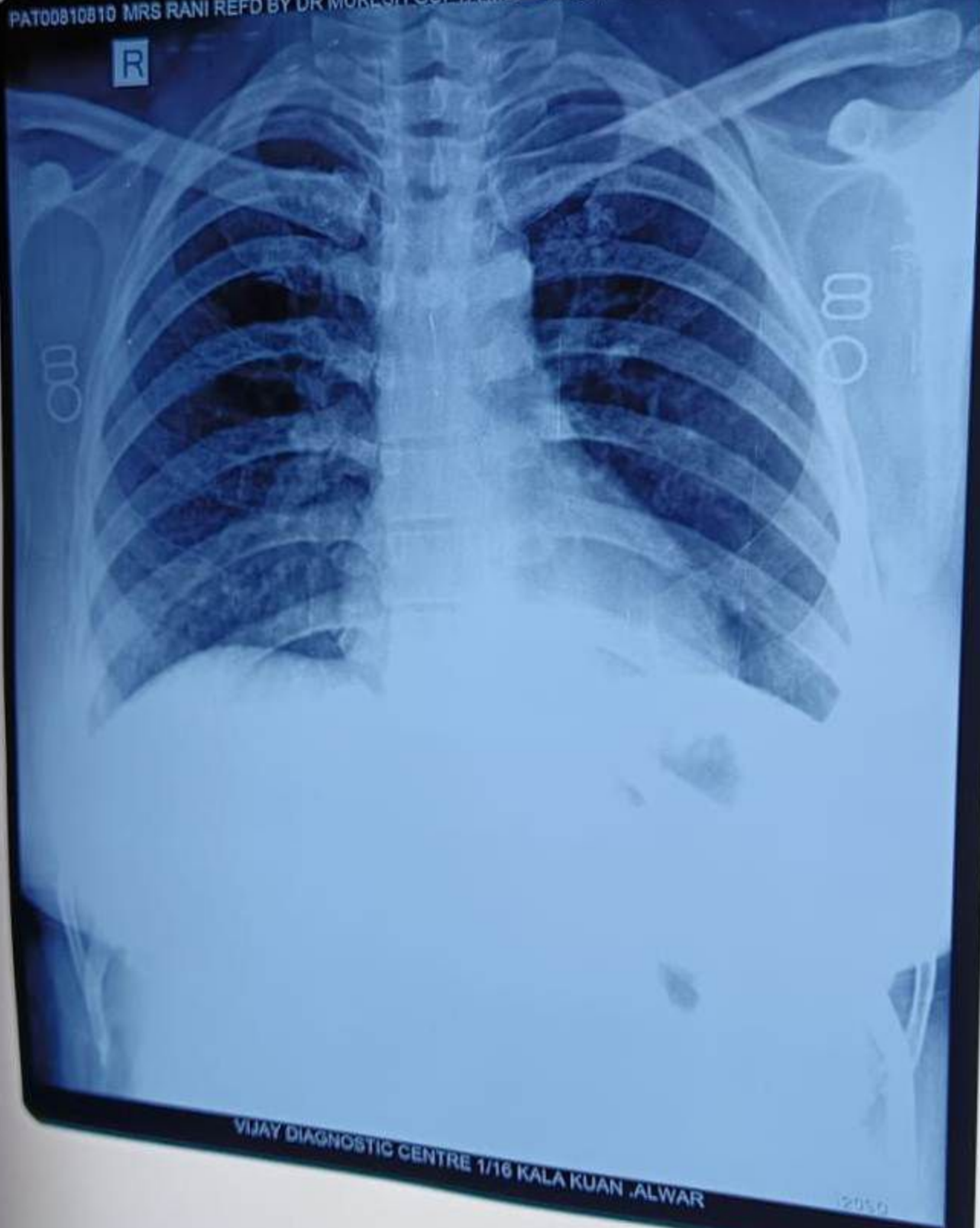Report Confirmed by:



डॉ० मुकेश गुप्ता
 M.D.F.C.C.S.
 फिजिशियन एवं मधुमेह रोग विशेषज्ञ
 दक्ष हॉस्पिटल, जयपुर
 रजि० नं०-5423/16262

PAT00810810 MRS RANI REFD BY DR MUKESH GUPTA MD CHEST 09.03.2024

R



VIJAY DIAGNOSTIC CENTRE 1/16 KALA KUAN, ALWAR

2024