



MC-5837

PATIENT NAME : MR.RAJESH PATIL

REF. DOCTOR :

CODE/NAME & ADDRESS : C000045507
FORTIS VASHI-CHC -SPLZD
FORTIS HOSPITAL # VASHI,
MUMBAI 440001

ACCESSION NO : **0022WL004432**
PATIENT ID : FH.12197511
CLIENT PATIENT ID: UID:12197511
ABHA NO :

AGE/SEX : 51 Years Male
DRAWN : 23/12/2023 13:01:00
RECEIVED : 23/12/2023 13:02:26
REPORTED : 23/12/2023 14:24:17

CLINICAL INFORMATION :

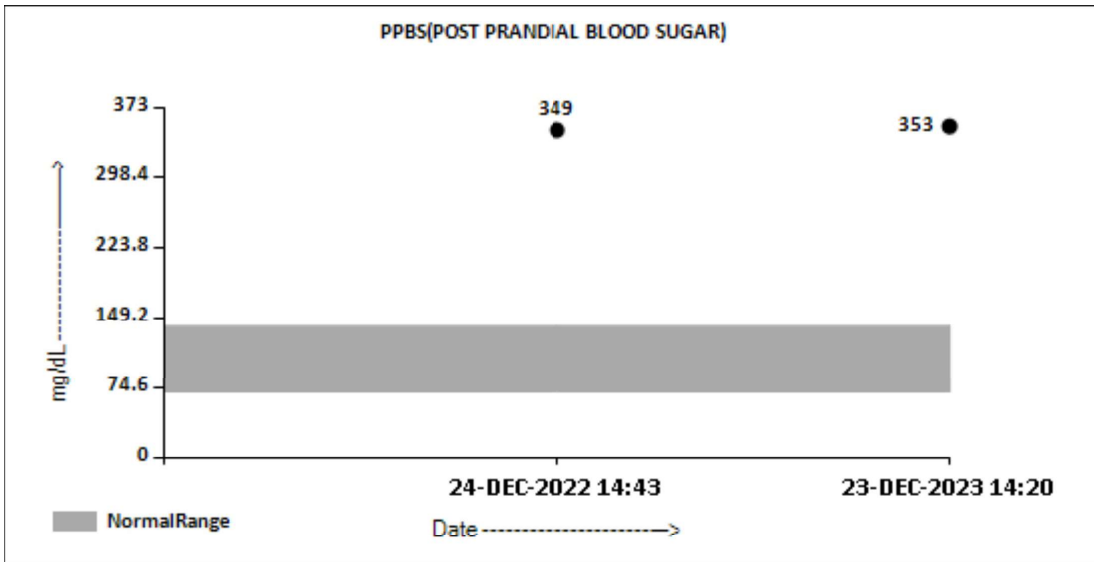
UID:12197511 REQNO-1642214
CORP-OPD
BILLNO-150123OPCR072113
BILLNO-150123OPCR072113

Test Report Status	Final	Results	Biological Reference Interval	Units
--------------------	-------	---------	-------------------------------	-------

BIOCHEMISTRY

GLUCOSE, POST-PRANDIAL, PLASMA

PPBS(POST PRANDIAL BLOOD SUGAR)	353 High	70 - 140	mg/dL
METHOD : HEXOKINASE			



Interpretation(s)

GLUCOSE, POST-PRANDIAL, PLASMA-High fasting glucose level in comparison to post prandial glucose level may be seen due to effect of Oral Hypoglycaemics & Insulin treatment, Renal Glycosuria, Glycaemic index & response to food consumed, Alimentary Hypoglycemia, Increased insulin response & sensitivity etc.Additional test HbA1c

****End Of Report****

Please visit www.agilusdiagnostics.com for related Test Information for this accession

Dr. Akshay Dhotre, MD
(Reg,no. MMC 2019/09/6377)
Consultant Pathologist



View Details



View Report

PERFORMED AT :

Agilus Diagnostics Ltd.
Hiranandani Hospital-Vashi, Mini Seashore Road, Sector 10,
Navi Mumbai, 400703
Maharashtra, India
Tel : 022-39199222,022-49723322,
CIN - U74899PB1995PLC045956
Email : -



Patient Ref. No. 2200000892352

Hiranandani Healthcare Pvt. Ltd.

Mini Sea Shore Road, Sector 10-A, Vashi, Navi Mumbai - 400703.

Board Line: 022 - 39199222 | Fax: 022 - 39133220

Emergency: 022 - 39199100 | Ambulance: 1255

For Appointment: 022 - 39199200 | Health Checkup: 022 - 39199300

www.fortishealthcare.com | vashi@fortishealthcare.com

CIN: U85100MH2005PTC 154823

GST IN : 27AABCH5894D1ZG

PAN NO : AABCH5894D

(For Billing/Reports & Discharge Summary only)



Patient Name	: Rajesh Patil	Patient ID	: 12197511
Sex / Age	: M / 51Y 1M 17D	Accession No.	: PHC.7182152
Modality	: US	Scan DateTime	: 23-12-2023 14:50:31
IPID No	: 73440/23/1501	ReportDatetime	: 23-12-2023 16:09:10

US – WHOLE ABDOMEN

Very suboptimal scan due to gaseous abdominal distension and body habitus.

LIVER is normal in size and shows raised echogenicity. Intrahepatic portal and biliary systems are normal. No focal lesion is seen in liver. Portal vein appears normal.

GALL BLADDER is partially distended, however visualised lumen appears clear.

CBD appears normal in caliber.

SPLEEN is normal in size and echogenicity.

BOTH KIDNEYS are normal in size and echogenicity. The central sinus complex is normal. No evidence of calculi/hydronephrosis.

Right kidney measures 10.8 x 5.9 cm.

Left kidney measures 11.8 x 6.1 cm.

PANCREAS is obscured due to bowel gas.

URINARY BLADDER is normal in capacity and contour. Bladder wall is normal in thickness. No evidence of intravesical mass/calculi.

PROSTATE is normal in size & echogenicity. It measures ~ 19.3 cc in volume.

No evidence of ascites.

IMPRESSION:

- **Grade I fatty infiltration of liver.**

DR. YOGESH PATHADE
(MD Radiologist)



DEPARTMENT OF RADIOLOGY

(For Billing/Reports & Discharge Summary only)

Name: Mr. Rajesh Patil

UHID | Episode No : 12197511 | 73440/23/1501

Age | Sex: 51 YEAR(S) | Male

Order No | Order Date: 1501/PN/OP/2312/152378 | 23-Dec-2023

Order Station : FO-OPD

Admitted On | Reporting Date : 23-Dec-2023 13:40:06

Bed Name :

Order Doctor Name : Dr.SELF .

X-RAY-CHEST- PA

Findings:

Both lung fields are clear.

The cardiac shadow appears within normal limits.

Trachea and major bronchi appears normal.

Both costophrenic angles are well maintained.

Bony thorax are unremarkable.

Impression:

- No significant abnormality is detected.

DR. CHETAN KHADKE

M.D. (Radiologist)