







Patient Name : Ms.SWAYAM SIDDHA JENA	Collected : 09/Nov/2024 09:24AM
Age/Gender : 38 Y 9 M 8 D/F	Received : 09/Nov/2024 04:20PM
UHID/MR No : CSAR.0000146280	Reported : 09/Nov/2024 08:31PM
Visit ID : CSAROPV361563	Status : Final Report
Ref Doctor : Self	Sponsor Name : ARCOFEMI HEALTHCARE LIMITED
Emp/Auth/TPA ID : 22E37655	

**DEPARTMENT OF BIOCHEMISTRY**

**ARCOFEMI - MEDIWHEEL - FULL BODY HEALTH ANNUAL PLUS CHECK - FEMALE - 2D ECHO - PAN INDIA - FY2324**

Test Name	Result	Unit	Bio. Ref. Interval	Method
GLUCOSE, FASTING , NAF PLASMA	94	mg/dL	70-100	HEXOKINASE


**Comment:**

As per American Diabetes Guidelines, 2023

Fasting Glucose Values in mg/dL	Interpretation
70-100 mg/dL	Normal
100-125 mg/dL	Prediabetes
≥126 mg/dL	Diabetes
<70 mg/dL	Hypoglycemia

**Note:**

- 1.The diagnosis of Diabetes requires a fasting plasma glucose of > or = 126 mg/dL and/or a random / 2 hr post glucose value of > or = 200 mg/dL on at least 2 occasions.
2. Very high glucose levels (>450 mg/dL in adults) may result in Diabetic Ketoacidosis & is considered critical.

  
**Dr Priya Murthy**  
 M.B.B.S.,M.D(Pathology)  
 Consultant Pathologist



Patient Name : Ms.SWAYAM SIDDHA JENA	Collected : 09/Nov/2024 01:59PM
Age/Gender : 38 Y 9 M 8 D/F	Received : 09/Nov/2024 08:18PM
UHID/MR No : CSAR.0000146280	Reported : 09/Nov/2024 08:53PM
Visit ID : CSAROPV361563	Status : Final Report
Ref Doctor : Self	Sponsor Name : ARCOFEMI HEALTHCARE LIMITED
Emp/Auth/TPA ID : 22E37655	


**DEPARTMENT OF BIOCHEMISTRY**


**ARCOFEMI - MEDIWHEEL - FULL BODY HEALTH ANNUAL PLUS CHECK - FEMALE - 2D ECHO - PAN INDIA - FY2324**

Test Name	Result	Unit	Bio. Ref. Interval	Method
<b>GLUCOSE, POST PRANDIAL (PP), 2 HOURS , SODIUM FLUORIDE PLASMA (2 HR)</b>	102	mg/dL	70-140	HEXOKINASE

**Comment:**

It is recommended that FBS and PPBS should be interpreted with respect to their Biological reference ranges and not with each other.  
 Conditions which may lead to lower postprandial glucose levels as compared to fasting glucose levels may be due to reactive hypoglycemia, dietary meal content, duration or timing of sampling after food digestion and absorption, medications such as insulin preparations, sulfonylureas, amylin analogues, or conditions such as overproduction of insulin.

  
 Dr.Govinda Raju N L  
 MSc,PhD(Biochemistry)  
 Consultant Biochemistry

  
 Dr Priya Murthy  
 M.B.B.S,M.D(Pathology)  
 Consultant Pathologist



SIN No: SAR241100545

This test has been performed at Apollo Health & Lifestyle Ltd, RRL BANGALORE Laboratory

APOLLO HEALTH AND LIFESTYLE LIMITED - RRL BANGALORE

APOLLO Health and Lifestyle Limited

APOLLO CLINIC'S NETWORK

Telangana: Hyderabad | AS Rao Nagar | Chanda Nagar | Korlapur | Halakurki | Nizampet | Varadola | Uppal | Andhra Pradesh: Vijaya Vittala | Karnataka: Bangalore | Basavanagudi | Solunika | Electronic City | Frazer Town | HSR Layout | Indira Nagar | IT Park | Jalahalli | Outer Ring Road | Mysore: New Village, Tumkur: Saktheshwari | Kerala: Kochi | Madhya Pradesh: Indore | Odisha: Bhubaneswar | West Bengal: Kolkata | Maharashtra: Pune | Tamil Nadu: Chennai | Karnataka: Mysore | Karnataka: Bangalore

Uttar Pradesh: Ghaziabad | Uttar Pradesh: Gurgaon | Ahmedabad: Sola | Faridkot: Amritsar | Chandigarh: Haryana: Panipat | Telangana: Secunderabad

























Patient Name : Ms.SWAYAM SIDDHA JENA	Collected : 09/Nov/2024 01:48PM
Age/Gender : 38 Y 9 M 8 D/F	Received : 10/Nov/2024 02:28PM
UHID/MR No : CSAR.0000146280	Reported : 12/Nov/2024 10:03AM
Visit ID : CSAROPV361563	Status : Final Report
Ref Doctor : Self	Sponsor Name : ARCOFEMI HEALTHCARE LIMITED
Emp/Auth/TPA ID : 22E37655	

**DEPARTMENT OF CYTOLOGY**

**ARCOFEMI - MEDIWHEEL - FULL BODY HEALTH ANNUAL PLUS CHECK - FEMALE - 2D ECHO - PAN INDIA - FY2324**

**LBC PAP SMEAR , CERVICAL BRUSH SAMPLE**

	<b>CYTOLOGY NO.</b>	24528/24
<b>I</b>	<b>SPECIMEN</b>	
<b>a</b>	SPECIMEN ADEQUACY	ADEQUATE
<b>b</b>	<b>SPECIMEN TYPE</b>	LIQUID-BASED PREPARATION (LBC)
	SPECIMEN NATURE/SOURCE	CERVICAL SMEAR
<b>c</b>	ENDOCERVICAL-TRANSFORMATION ZONE	ABSENT
<b>d</b>	COMMENTS	SATISFACTORY FOR EVALUATION
<b>II</b>	<b>MICROSCOPY</b>	Superficial and intermediate squamous epithelial cells with benign morphology.  Inflammatory cells, predominantly neutrophils.  Negative for intraepithelial lesion/malignancy.
<b>III</b>	<b>RESULT</b>	
<b>a</b>	<b>EPITHELIAL CELL</b>	
	SQUAMOUS CELL ABNORMALITIES	NOT SEEN
	GLANDULAR CELL ABNORMALITIES	NOT SEEN
<b>b</b>	<b>ORGANISM</b>	NIL
<b>IV</b>	<b>INTERPRETATION</b>	NEGATIVE FOR INTRAEPITHELIAL LESION OR MALIGNANCY

Pap Test is a screening test for cervical cancer with inherent false negative results. Regular screening and follow-up is recommended (Bethesda-TBS-2014) revised

**\*\*\* End Of Report \*\*\***

Result/s to Follow:  
PERIPHERAL SMEAR

Dr. Reshma Stanly  
M.B.B.S, DNB(Pathology)  
Consultant Pathologist



SIN No: SAR241100541

This test has been performed at Apollo Health & Lifestyle Ltd, Global Reference Laboratory, Hyderabad

Regd. Office: 102/202, A Block, Rajaganga 4th Cross, 4th Floor, Rajanganga, Hyderabad, Telangana - 500016  
www.apolloclinics.com | Email ID: enquiry@apolloclinics.com, Ph: No: 040-6661 7777, Fax No: 4964 7766

APOLLO CLINICS NETWORK

Telangana: Hyderabad (45 Rao Nagar) | Chandigarh (Sector 22) | Karnataka: Bangalore (Banashankari) | Kerala: Kochi (Marine Drive) | Maharashtra: Mumbai (Bandra) | Odisha: Bhubaneswar (Bhubaneswar) | Punjab: Chandigarh (Sector 22) | Rajasthan: Jaipur (Bani Park) | Tamil Nadu: Chennai (Anna Nagar) | Uttar Pradesh: Lucknow (Sector 10) | West Bengal: Kolkata (Park Street) | Andhra Pradesh: Hyderabad (Banjara Hills) | Assam: Guwahati (Dibrugarh) | Bihar: Patna (Patna) | Gujarat: Ahmedabad (Vastrapur) | Haryana: Gurgaon (Sector 29) | Himachal Pradesh: Shimla (Sector 17) | Jharkhand: Ranchi (Sector 1) | Madhya Pradesh: Bhopal (Sector 1) | Madhya Pradesh: Indore (Sector 1) | Madhya Pradesh: Jabalpur (Sector 1) | Madhya Pradesh: Bhopal (Sector 1) | Madhya Pradesh: Indore (Sector 1) | Madhya Pradesh: Jabalpur (Sector 1) | Madhya Pradesh: Bhopal (Sector 1) | Madhya Pradesh: Indore (Sector 1) | Madhya Pradesh: Jabalpur (Sector 1)







Patient Name : Age : --  
UHID : OP Visit No. :  
Printed On : Invalid date Advised/Pres Doctor : --  
Department : Radiology Qualification : --  
Referred By : -- Registration No. : --

---

**DEPARTMENT OF RADIOLOGY**

---

No Reports Available

---End Of The Report---

--  
--  
--

Radiology

Provisional  
Report



Patient Ms. SWAYAM SIDDHA JENA  
Age/Gender 38Y | Female  
UHID CSAR.0000146280

Appt ID CSARAPT6486  
Consult Date 14 Nov 2024  
Order Bill ID CSAR-OCR-49781  
Visit Display ID CSAROPV361563

## VITALS

Weight : 63Kgs  
Pulse : 73 BPM  
BP : 122 / 78 MmHg  
Temperature : 98.6 °F

Height : 149Cms  
Spo2 : 98%  
Respiratory Rate : 22 BPM



Patient Ms. SWAYAM SIDDHA JENA  
Age/Gender 38Y | Female  
UHID CSAR.0000146280

Appt ID CSARAPT6487  
Consult Date 14 Nov 2024  
Order Bill ID CSAR-OCR-49781  
Visit Display ID CSAROPV361563

## VITALS

Weight : 63Kgs  
Pulse : 73 BPM  
BP : 122 / 78 MmHg  
Temperature : 98.6 °F  
Height : 149Cms  
Spo2 : 73%  
Respiratory Rate : 22 BPM

Patient Name	: Ms. SWAYAM SIDDHA JENA	Age	: 38Yrs 9Mths 9Days
UHID	: CSAR.0000146280	OP Visit No.	: CSAROPV361563
Printed On	: 09-11-2024 06:55 AM	Advised/Pres Doctor	: --
Department	: Cardiology	Qualification	: --
Referred By	: Self	Registration No.	: --
Employer Id	: 22E37655		

## DEPARTMENT OF CARDIOLOGY

### Observation :-

1. Normal Sinus Rhythm.
2. Heart rate is Normal
3. No pathological Q wave or ST-T changes seen.
4. Normal P,QRS,T waves and axis.
5. No evidence of chamber, hypertrophy or enlargement seen.

### Impression:-

NORMAL RESTING ECG.

**NOTE:-**KINDLY TAKE A PHOTOCOPY OF THE GRAPH FOR FUTURE REFERENCE IF NEEDED

---End Of The Report---



Dr. SUMANJITA BORA  
MBBS, PGDCC  
MCI-IMR-13/903  
Cardiology

Patient Name : Age : --  
UHID : OP Visit No. :  
Printed On : Invalid date Advised/Pres Doctor : --  
Department : Radiology Qualification : --  
Referred By : -- Registration No. : --

---

**DEPARTMENT OF RADIOLOGY**

---

No Reports Available

---End Of The Report---

--  
--  
--

Radiology

Provisional  
Report



Patient Ms. SWAYAM SIDDHA JENA  
Age/Gender 38Y | Female  
UHID CSAR.0000146280

Appt ID CSARAPT6488  
Consult Date 14 Nov 2024  
Order Bill ID CSAR-OCR-49781  
Visit Display ID CSAROPV361563

## VITALS

Weight : 63Kgs  
Pulse : 73 BPM  
BP : 122 / 78 MmHg  
Temperature : 98.6 °F  
Height : 149Cms  
Spo2 : 98%  
Respiratory Rate : 22 BPM



Patient Ms. SWAYAM SIDDHA JENA  
Age/Gender 38Y | Female  
UHID CSAR.0000146280

Appt ID CSARAPT6489  
Consult Date 14 Nov 2024  
Order Bill ID CSAR-OCR-49781  
Visit Display ID CSAROPV361563

## VITALS

Weight : 63Kgs  
Pulse : 73 BPM  
BP : 122 / 78 MmHg  
Temperature : 98.6 °F

Height : 149Cms  
Spo2 : 98%  
Respiratory Rate : 22 BPM





Patient Ms. SWAYAM SIDDHA JENA  
Age/Gender 38Y | Female  
UHID CSAR.0000146280

Appt ID CSARAPT6490  
Consult Date 14 Nov 2024  
Order Bill ID CSAR-OCR-49781  
Visit Display ID CSAROPV361563

## VITALS

Weight : 63Kgs  
Pulse : 73 BPM  
BP : 122 / 78 MmHg  
Temperature : 98.6 °F

Height : 149Cms  
Spo2 : 98%  
Respiratory Rate : 22 BPM

**APOLLO CLINIC  
CONSENT FORM**

Patient name Swayam Siddhayera Age 32 1/2

UHID Number 146280 Company Name Mediwheel.

Company want to inform u that I am ~~not~~ interested in getting Opthal Died ~~STOP~~,

fitness by g.p. <sup>eyneology.</sup> And I claim the above statement in my full Consciousness.

Patient signature Siddhayera S. S. Date 9/1/24

1912

1912	1913	1914	1915
1916	1917	1918	1919

1920	1921	1922	1923	1924	1925
1926	1927	1928	1929	1930	1931
1932	1933	1934	1935	1936	1937

Name : Ms. SWAYAM SIDDHA JENA

Age : 38Y 9M 8D

UHID : CSAR.0000146280

Address : Carmelaram Bangalore Rural Karnataka INDIA 560035

sex : Female



CSAR.0000146280

Plan : ARCOFEMI MEDIWHEEL FEMALE AHC  
CREDIT PAN INDIA OP AGREEMENT

OP No: CSAROPV361563

Bill No: CSAR-OCR-49781

Date: Nov 9th, 2024, 9:13 AM

Sno.	Service Type/Service Name	Department
1	ARCOFEMI - MEDIWHEEL - FULL BODY HEALTH ANNUAL PLUS CHECK - FEMALE - 2D ECHO - PAN INDIA - FY2324	
✓ 2	ULTRASOUND - WHOLE ABDOMEN - 18. 12.00pm	Ultrasound Radiology
2	OPHTHAL BY GENERAL PHYSICIAN - Tolishti	Consultation
3	URINE GLUCOSE(POST PRANDIAL)	Clinical Pathology
4	GAMMA GLUTAMYL TRANSFERASE (GGT)	Biochemistry
5	HbA1c, GLYCATED HEMOGLOBIN	Biochemistry
6	GYNAECOLOGY CONSULTATION - 6 12.00pm	Consultation
7	DIET CONSULTATION - 6	General
8	BODY MASS INDEX (BMI)	General
9	ECG	Cardiology
10	THYROID PROFILE (TOTAL T3, TOTAL T4, TSH)	Biochemistry
11	2 D ECHO - 18	Cardiology
12	BLOOD GROUP ABO AND RH FACTOR	Blood Bank
✓ 13	X-RAY CHEST PA - 9	X Ray Radiology
14	URINE GLUCOSE(FASTING) - 6	Clinical Pathology
15	LBC PAP TEST- PAPSURE - After report	Histopathology
16	FITNESS BY GENERAL PHYSICIAN	Consultation
17	GLUCOSE, POST PRANDIAL (PP), 2 HOURS (POST MEAL)	Biochemistry
18	GLUCOSE, FASTING	Biochemistry
19	ENT CONSULTATION - 3	Biochemistry
20	LIPID PROFILE	Consultation
21	DENTAL CONSULTATION - 15	Biochemistry
22	HEMOGRAM + PERIPHERAL SMEAR	Consultation
23	PERIPHERAL SMEAR	Haematology
24	COMPLETE URINE EXAMINATION	Haematology
25	RENAL PROFILE/RENAL FUNCTION TEST (RFT/KFT)	Clinical Pathology
26	LIVER FUNCTION TEST (LFT) - vit @/ln level	Biochemistry

Alabama - 09

BMI - 28.0 kg/m<sup>2</sup> WT - 63 kg

Ht - 150 cm 151cm

LBC  
Papsure  
9/11/2024

BP - 122/78 mmHg

P - 73 bpm

Curd  
- olivants 3/1  
- Sur - 10ml  
- Ex - 20ml

c. Vit  $\textcircled{5}$  604/uk  $\times 10$  uk <sup>Sur</sup>  
c. Neurolio Fort  $\textcircled{1}$ /D  $\times 40$

# ORAL EXAMINATION FORM



Date: 9/11/2024

Patient ID: 146280

MHC

Patient Name: Ms. Suwayam Siddha J. Age: 38

Sex: Male  Female

Chief Complaint: Pt visited for general checkup

Medical History :

Drug Allergy :

Medication currently taken by the Guest :

Initial Screenign Findings :

Dental Caries : 1/8

Missing Teeth :

Impacted Teeth :

Attrition / Abrasion :

Bleeding :

Pockets / Recession :

Calculus / Stains :

Mobility :

Restored Teeth :

Non - restorable Teeth for extraction /  
Root Stumps :

Malocclusion :

Others :

Advice :- filling 1/8

Doctor Name & Signature: Dr. Prishita

For Appontments,  
Call Us at  
Mob-8870032885



Ms. Swayam Siddha Jena

Age: - 3 yrs

Dr MAHUR. M. MADK

M.B.B.S MS (ENT)

(54722)

9/11/24

Height :	Weight :	BMI :	Waist Circum :
Temp :	Pulse :	Resp :	B.P :

General Examination / Allergies  
History

N/C

No complaints

O/E

Nose → mucosally congested

Bk Ea → TM intact & normal

Recesses < Bk postna

webers → central

D → A/R

tend neck  
↳ NAD

Clinical Diagnosis & Management Plan

Acute

- Ms. Pharyngitis - FS once before bed time < 1 month

Follow up date: R 5/5



Doctor Signature



S. NO.	NAME OF DRUG & STRENGTH (Generic Name and in CAPITAL)	A MEDICATION DOSAGE	B				C NO. OF DAYS	(A*B*C) TOTAL QTY.	INSTRUCTIONS FOR ADMINISTERING DOSAGE		
			MORNING	AFTERNOON	EVENING	NIGHT			Before Meal	After Meal	Others
1											
2											
3											
4											
5											
6											
7											
8											
9											

### RECOMMENDED INVESTIGATIONS

#### BIO CHEMISTRY

- ALANINE AMINOTRANSFERASE (ALT/SGPT), SERUM
- CALCIUM, SERUM
- CREATININE, SERUM
- FERRITIN - SERUM
- FREE T4 - SERUM
- GLUCOSE (FASTING)
- GLUCOSE (POST PRANDIAL)
- GLUCOSE, FASTING (F) AND POST PRANDIAL (PP)
- GLUCOSE, RANDOM
- HbA1c
- IgE (TOTAL)
- LIPID PROFILE
- LIVER FUNCTION TESTS (LFT)
- PROLACTIN - SERUM
- SERUM ELECTROLYTES
- THYROID FUNCTION TEST, TOTAL
- TOTAL BETA- HCG (TB-HCG)
- TSH: THYROID STIMULATING HORMONE-SERUM-FREE
- UREA - SERUM / PLASMA
- URIC ACID - SERUM
- VITAMIN B12 -SERUM
- VITAMIN D3

#### SEROLOGY

- C-REACTIVE PROTEIN (Qualitative)
- DENGUE IgM
- DENGUE IgM & IgG
- DENGUE NS1 ANTIGEN
- HIV I AND II ANTIBODIES
- MALARIAL ANTIGEN ( VIVAX AND FALCIPARUM)
- RHEUMATOID FACTOR -SERUM
- TYPHI DOT - M
- WIDAL TEST

#### HEMATOLOGY

- ABSOLUTE EOSINOPHIL COUNT
- BLOOD GROUP ABO & Rh FACTOR
- COMPLETE BLOOD COUNT
- ERYTHROCYTE SEDIMENTATION RATE (ESR)
- HEMOGRAM (CBP+ ESR)
- PERIPHERAL SMEAR FOR MALARIAL PARASITE (MP)
- PLATELET COUNT

#### RADIOLOGY

- ULTRASOUND - ABDOMEN AND PELVIS
- ULTRASOUND - WHOLE ABDOMEN
- ULTRASOUND EARLY PREGNANCY (WITHIN 10 WEEKS)
- X-RAY CERVICAL SPINE AP AND LAT
- X-RAY CHEST PA
- X-RAY LUMBAR SPINE AP AND LAT
- X-RAY PNS

#### CARDIOLOGY

- 2D-ECHO WITH COLOUR DOPPLER
- CARDIAC STRESS TEST - (TMT)
- ECG

#### CLINICAL PATHOLOGY & MICRO BIOLOGY

- URINE ROUTINE (CUE)
- CULTURE AND SENSITIVITY [ URINE ]
- URINE ROUTINE AND MICROSCOPY

#### OTHER

- PULMONARY FUNCTION TEST

#### Additional Investigation Recommended:

In case of emergency or any rash or other allergic complaints, please call 1066 or come directly to emergency room of the hospital

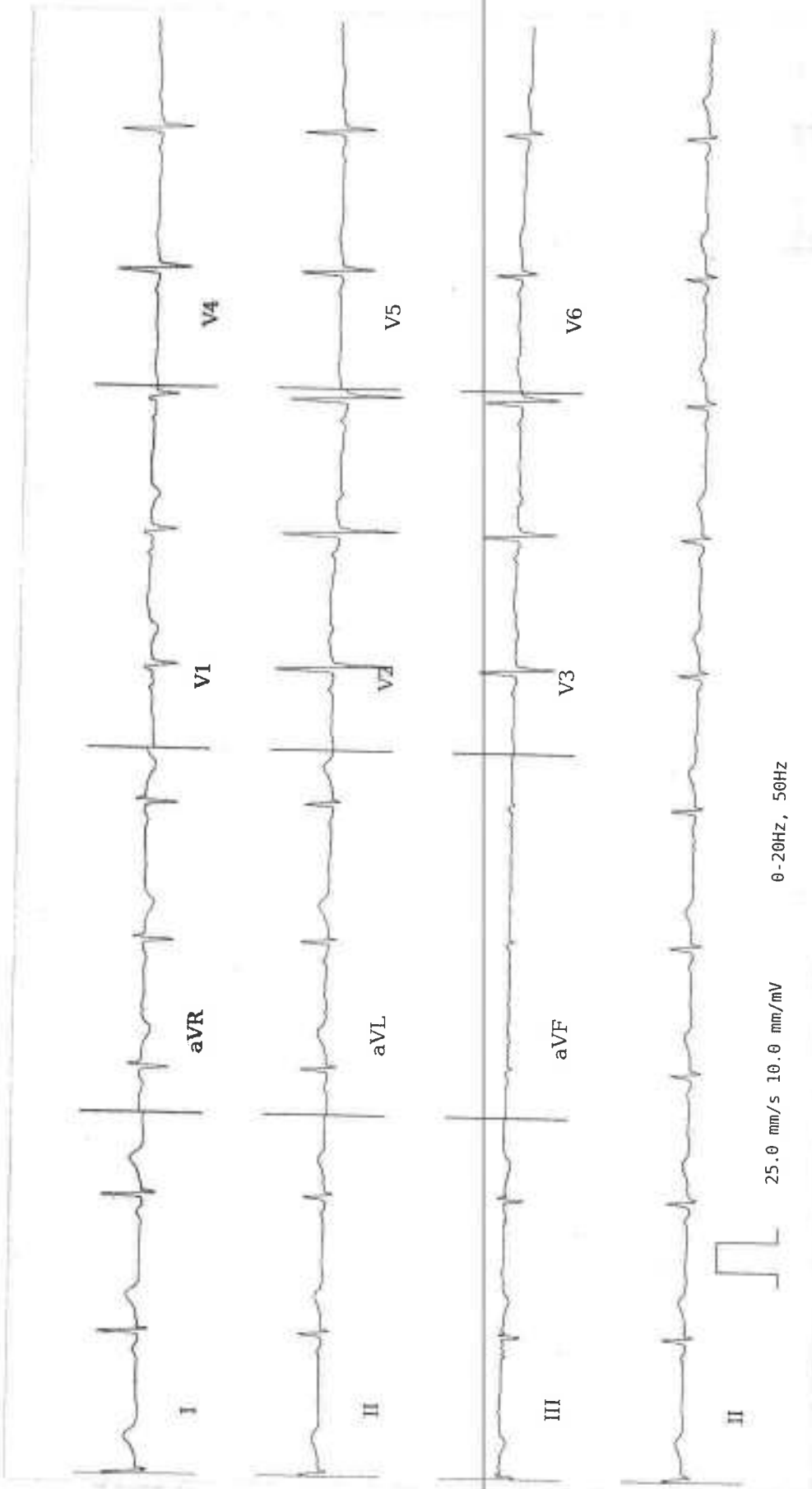
Convenient & reliable. Complete diagnostic services for the entire family. All under one roof.



**Apollo Clinic, Kaikondrahalli**

Age / Gender: 38/Female  
Patient ID: SWAYAM

Date and Time: 9th Nov 24 11:08 AM



AR: 67bpm    VR: 68bpm    QRS: 76ms    QT: 352ms    QTcB: 375ms    PRI: 138ms    P-R-T: 10° 8° NA

**Sinus Rhythm, Non-specific ST/T Wave Changes.LA-LL lead reversal suspected. Please correlate clinically.**

REPORTED BY

Dr A - Saras Monikta

Disclaimer: Analysis in this report is based on ECG alone and should only be used as an adjunct to clinical history, symptoms and results of other invasive and non-invasive tests and must be interpreted by a qualified physician



## 2D ECHO CARDIOGRAPHY REPORT

PATIENT NAME: MS.SWAYAM SIDDHA JENA

AGE : 38 YEARS/FEMALE

Date: 09/11/2024

### M-MODE MEASUREMENTS

AORTA : 2.4cm      LV (D) 4.4cm      IVS (D) : 1.1cm  
LA : 3.4cm      LV (S) : 2.5cm      PW (S): 1.0 cm  
EF :61%

### VALVES

MITRAL VALVE : NORMAL  
AORTIC VALVE : NORMAL  
TRICUSPID VALVE : NORMAL  
PULMONARY VALVE : NORMAL

### CHAMBERS

LEFT ATRIUM : NORMAL SIZED  
RIGHT ATRIUM : NORMAL SIZED  
LEFT VENTRICLE : NORMAL SIZED, NORMAL LV SYSTOLIC FUNCTION  
RIGHT VENTRICLE : NORMAL SIZED, TAPSE-20 MM, NORMAL RV FUNCTION

### SEPTAE

IAS : INTACT  
IVS : INTACT

### GREAT ARTERIES

AORTA : NORMAL  
PULMONARY ARTERY : NORMAL

PERICARDIUM :NORMAL

### DOPPLER FLOW VELOCITIES

MITRAL FLOW - E/A 0.9/0.6 m/sec, Normal LV Diastolic function, MR- Trivial  
AORTIC FLOW PG-08 mmHg  
TRICUSPID FLOW PASP -26 mmHg, TR-Trivial  
PULMONARY FLOW PG-04 mmHg

REGIONAL WALL MOTION: NO RWMA

### **Apollo Health and Lifestyle Limited**

(CIN - U85110TG2000PLC115819)

Regd. Office: 1-10-60/62, Ashoka Raghupathi Chambers, 5th Floor, Begumpet, Hyderabad, Telangana - 500 016.

Ph No: 040-4904 7777, Fax No: 4904 7744 | Email ID: enquiry@apollohl.com | www.apollohl.com

### **APOLLO CLINICS NETWORK KARNATAKA**

**Bangalore** (Basavanagudi | Bellandur | Electronic City | Fraser Town | HSR Layout | Indira Nagar | JP Nagar | Kundalahalli | Koramangala | Sarjapur Road) **Mysore** (VV Mohalla)

Online appointments: www.apolloclinic.com

TO BOOK AN APPOINTMENT

 **1860 500 7788**



**OTHER FINDINGS**

IVC -14 MM, NORMAL SIZED, COLLAPSING, NORMAL RA PRESSURE

**IMPRESSION**

**NORMAL CHAMBER DIMENSIONS**  
**NORMAL VALVES**  
**NORMAL PA PRESSURE**  
**NO REGIONAL WALL MOTION ABNORMALITY**  
**NORMAL LV SYSTOLIC FUNCTION**  
**NO CLOT / EFFUSION / VEGETATION**

**DR .SAIKAT KANJILAL**  
**CONSULTANT INTERVENTIONAL CARDIOLOGY**

**PRASAD.B**  
**CARDIAC SONOGRAPHER**

Note: investigations have their limitations solitary pathological/ Radiological and investigations never confirm the final diagnosis they are help in diagnosing the disease in correlation to clinical symptoms and other related tests. Please interpret accordingly ,this report is not for medico-legal Purpose

**Apollo Health and Lifestyle Limited**

(CIN - U85110TG2000PLC115819)

Regd. Office: 1-10-60/62, Ashoka Raghupathi Chambers, 5th Floor, Begumpet, Hyderabad, Telangana - 500 016.  
Ph No: 040-4904 7777, Fax No: 4904 7744 | Email ID: enquiry@apollohi.com | www.apollohi.com

**APOLLO CLINICS NETWORK KARNATAKA**

**Bangalore** (Basavanagudi | Bellandur | Electronic City | Fraser Town | HSR Layout | Indira Nagar | JP Nagar | Kundalahalli | Koramangala | Sarjapur Road) **Mysore** (VV Mohalla)

Online appointments: www.apolloclinic.com

TO BOOK AN APPOINTMENT

 **1860 500 7788**





बैंक ऑफ बरोडा  
Bank of Baroda



नाम : **SWAYAMSIDDHA JENA**  
Name:

कर्मचारी कूट क्र.

E.C. No **108252**

*bmb*

जारीकर्ता प्राधिकारी-उप महाप्रबंधक  
Issuing Authority - D.G.M.  
Odisha Region

*Swayamsiddha Jena*

जारीकर्ता

Signature of holder





Outlook

**Fw: Your appointment is confirmed**

From Swayam Siddha Jena <SWAYAMSIDDHA.JENA@bankofbaroda.com>

Date Sat 09-11-2024 09:14

To Sarjapur Apolloclinic <sarjapur@apolloclinic.com>

Get [Outlook for Android](#)

From: noreply@apolloclinics.info <noreply@apolloclinics.info>

Sent: Thursday, November 7, 2024 5:20:54 PM

To: Swayam Siddha Jena <SWAYAMSIDDHA.JENA@bankofbaroda.com>

Cc: sarjapur@apolloclinic.com <sarjapur@apolloclinic.com>; Irfanali.s@apolloclinic.com <Irfanali.s@apolloclinic.com>; syamsunder.m@apollohl.com <syamsunder.m@apollohl.com>

Subject: Your appointment is confirmed

You don't often get email from noreply@apolloclinics.info. [Learn why this is important](#)

ने दी गयी लिंक पर क्लिक ना करें या अटैचमेंट ना खोलें

I. DO NOT CLICK ON LINKS OR OPEN ATTACHMENTS UNLESS YOU KNOW THE SENDER.

Dear **MS. SWAYAM SIDDHA JENA**,

Greetings from Apollo Clinics,

Your corporate health check appointment is confirmed at **SARJAPUR ROAD** clinic on **2024-11-09 at 08:00-08:15**.

Payment Mode	
Corporate Name	<b>ARCOFEMI HEALTHCARE LIMITED</b>
Agreement Name	<b>[ARCOFEMI MEDIWHEEL FEMALE AHC CREDIT PAN INDIA OP AGREEMENT]</b>
Package Name	<b>[ARCOFEMI - MEDIWHEEL - FULL BODY HEALTH ANNUAL PLUS CHECK - FEMALE - 2D ECHO - PAN INDIA - FY2324]</b>

"Kindly carry with you relevant documents such as HR issued authorization letter and or appointment confirmation mail and or valid government ID proof

